

INFOGRAPHICS IN ANESTHESIOLOGY

Complex Information for Anesthesiologists Presented Quickly and Clearly

Ultrasound Insights into Neonatal Fasting: Get in the NP-Know



Current ASA guidelines for neonatal fasting vary by type of intake.

Normally infants feed every 2.5 to 3 h.

Preoperative fasting can lead to hypoglycemia and dehydration.



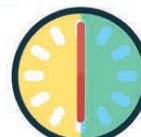ASA Practice Guidelines



Clears
2 h



Breastmilk
4 h

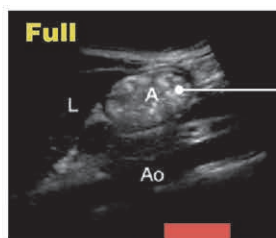


Formula
6 h

Lee *et al.*¹ evaluated 46 healthy neonates ages 0 to 5 days. Serial gastric antrum ultrasounds every 15 min after formula feeding determined gastric emptying times.

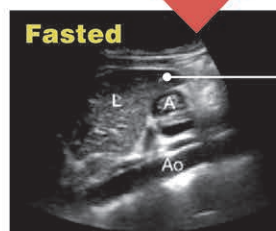
Emptying times ranged from 45 to 150 min and averaged 93 min (95% CI, 80 to 106).

No differences were found between sex and delivery type. Amount ingested and gastric emptying time were not correlated.



Full

Thick fluid in the stomach appears hyperechoic and heterogenous, with peristalsis.²



Fasted

An empty stomach is collapsed and flat with a thick, multi-layered wall.

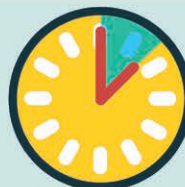ASA Practice Guidelines

Formula: 6 h



Study Observations

Formula: 93 min



These data suggest that healthy term neonates can be safely anesthetized 3 h after formula feeding and current guidelines may be too stringent.³

ASA, American Society of Anesthesiologists.

Infographic created by Jonathan P. Wanderer, Vanderbilt University Medical Center, and James P. Rathmell, Brigham and Women's Health Care/Harvard Medical School. Illustration by Annemarie Johnson, Vivo Visuals. Address correspondence to Dr. Wanderer: jon.wanderer@vumc.org.

1. Lee JJ, Price JC, Duren A, Shertzer A, Hannum R III, Akita FA, Wang S, Squires JH, Panzer O, Herrera J, Sun LS, Davis NA: Ultrasound evaluation of gastric emptying time in healthy term neonates after formula feeding. *ANESTHESIOLOGY* 2021;134:845–51
2. El-Boghdady K, Kruisselbrink R, Chan VWS, Perlas A: Images in anesthesiology: Gastric ultrasound. *ANESTHESIOLOGY* 2016; 125:595
3. Vutskits L: Neonatal preoperative fasting: Time for a change? *ANESTHESIOLOGY* 2021;134:823–5