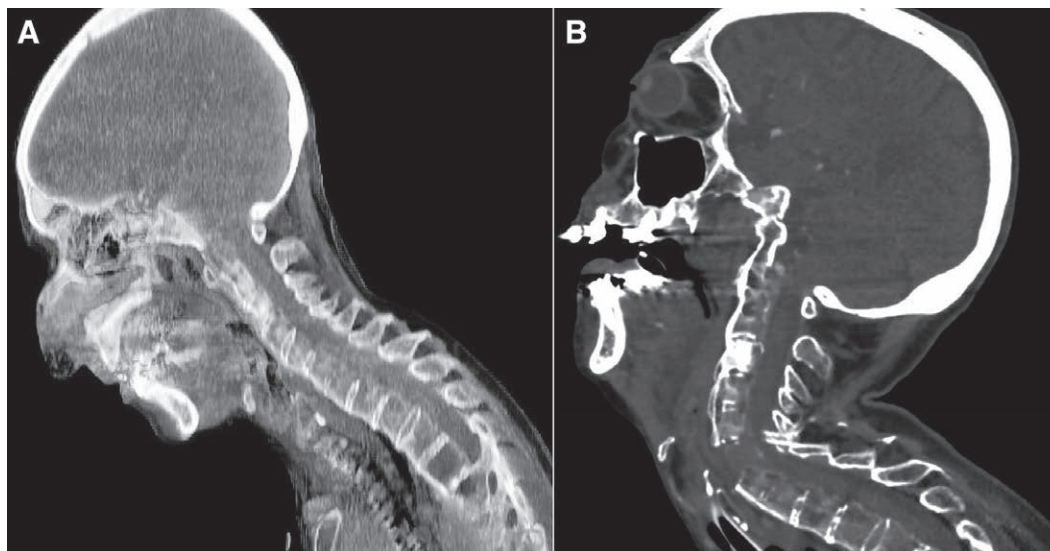


# Dramatic Cervical Spine Injury Secondary to Videolaryngoscopy in a Patient Suffering from Ankylosing Spondylitis

Alexandre Epaud, M.D., Eric Levesque, M.D., Ph.D., Simon Clariot, M.D.



An 84-yr-old woman with a history of ankylosing spondylitis was scheduled for lymph node biopsy under general anesthesia. Preoperative anesthetic assessment mentioned a potential difficult intubation owing to a rigid cervical flexion deformity with limited range of motion. The patient was alert with a normal neurologic exam. Preoperative imaging showed evidence of bamboo spine without any underlying fracture (panel A). Both videolaryngoscopy and fiberoptic intubation were considered for airway management.

Videolaryngoscopy was preferred because the operator was more familiar with this technique. The videolaryngoscope was inserted using an in-line traction. The operator did not succeed in introducing the tracheal tube because of cervical rigidity and difficulties in exposing the epiglottis. Using a bougie, the patient was intubated after two attempts.

During the postoperative course, hypotension and acute respiratory failure occurred. Neurologic exam showed a left hemiparesis. A computed tomography scan with a sagittal neck reconstruction revealed a C5–C6 dislocation fracture (panel B).

The increased propensity of fractures in ankylosing spondylitis must be considered during intubation.<sup>1</sup> Hyperextension is the most common injury mechanism and can lead to severe cervical injury, even with safer techniques such as videolaryngoscopy. As a teaching point, we believe that videolaryngoscopy or fiberoptic intubation should be chosen by the operator depending on expertise with both techniques. However, although fiberoptic intubation has progressively been replaced by videolaryngoscopy, this technique remains useful for challenging intubations because it does not require any cervical traction. It could have been used to avoid devastating neurologic injury in such a scenario.<sup>2,3</sup>

## Competing Interests

The authors declare no competing interests.

## Correspondence

Address correspondence to Dr. Clariot: [simon.clariot@gmail.com](mailto:simon.clariot@gmail.com)

Published online first on June 28, 2021. From the Department of Anaesthesia and Surgical Intensive Care, Assistance Publique - Hôpitaux de Paris, Henri Mondor Hospital, Créteil, France (A.E., E.L., S.C.), and Paris-Est Créteil University, Créteil, France (E.L., S.C.).

Copyright © 2021, the American Society of Anesthesiologists. All Rights Reserved. Anesthesiology 2021; 135:495–6. DOI: 10.1097/ALN.0000000000003866

## References

1. Kouyoumdjian P, Guerin P, Schaelderle C, Asencio G, Gille O: Fracture of the lower cervical spine in patients with ankylosing spondylitis: Retrospective study of 19 cases. *Orthop Traumatol Surg Res* 2012; 98:543–51
2. Woodward LJ, Kam PC: Ankylosing spondylitis: Recent developments and anaesthetic implications. *Anaesthesia* 2009; 64:540–8
3. Heidegger T: Management of the difficult airway. *N Engl J Med* 2021; 384:1836–47