

ANESTHESIOLOGY

Effects of Serratus Anterior Plane Block on Early Recovery from Thoracoscopic Lung Resection: A Randomized, Blinded, Placebo-controlled Trial

Jacob C. Jackson, M.D., Kay See Tan, Ph.D., Alessia Pedoto, M.D., Bernard J. Park, M.D., Valerie W. Rusch, M.D., David R. Jones, M.D., Hao Zhang, M.D., Dawn Desiderio, M.D., Gregory W. Fischer, M.D., David Amar, M.D.

ANESTHESIOLOGY 2024; 141:1065–74



EDITOR'S PERSPECTIVE

What We Already Know about This Topic

- Minimally invasive thoracic lung surgery (*e.g.*, video-assisted or robotic-assisted thoracoscopic surgeries) is associated with fewer postoperative pulmonary complications and faster postoperative recovery when compared with patients who undergo thoracic lung surgery *via* open thoracotomy.
- Patients who undergo minimally invasive thoracic surgery have multiple post-site incisions that may cause significant chest wall pain without intraoperative and postoperative pain management.
- Enhanced recovery protocols for thoracic surgeries exist at many hospitals and typically include a multimodal approach to pain management. Some centers include placing a serratus anterior fascial plane block after surgery.
- It remains unclear whether placing a serratus anterior plane block at the end of lung surgery adds significantly to pain control achieved with intraoperative intravenous medications and intercostal blocks placed at the end of surgery.

What This Article Tells Us That Is New

- This study is a single-center prospective randomized clinical trial of 99 patients who underwent minimally invasive thoracic lung surgery.
- All patients received intraoperative intravenous fentanyl, dexamethasone, dexmedetomidine, acetaminophen, and ketorolac and

ABSTRACT

Background: The efficacy of serratus anterior plane block for treatment of pain after minimally invasive thoracic surgery remains unclear. This trial assesses the impact of serratus anterior plane block on postoperative opioid consumption and on measures of early recovery after thoracoscopic lung resection.

Methods: Patients undergoing minimally invasive anatomic lung resection at a single center were randomized to undergo serratus anterior plane block with 40 ml injectate containing bupivacaine 0.25%, clonidine 100 µg, and dexamethasone 4 mg (serratus anterior plane block group) or sham block with 40 ml normal saline (placebo group) at the conclusion of surgery. The primary outcome was cumulative intravenous morphine equivalents during the first 24 h postoperatively. Secondary outcomes were intravenous morphine equivalents, pain scores at rest and with cough, inspiratory volume on incentive spirometry, incidence of nausea or vomiting during the first 48 h postoperatively, Quality of Recovery–15 score on postoperative day 7, and length of stay.

Results: Using the protocol-specified intention-to-treat analysis, the median (interquartile range) intravenous morphine equivalents was 10.6 (5.0 to 27.1) mg in serratus anterior plane block patients ($n = 46$) *versus* 18.8 (9.9 to 29.6) mg in placebo patients ($n = 46$; 32% reduction; ratio, 0.68 [95% CI, 0.44 to 1.06]; $P = 0.085$). Of the secondary outcomes, only the composite pain with cough scores differed significantly in the serratus anterior plane block group by a coefficient of -0.41 (95% CI, -0.81 to -0.01 ; $P = 0.044$). A sensitivity as-treated analysis reported median (interquartile range) intravenous morphine equivalents of 10.0 (5.0 to 27.2) mg in serratus anterior plane block patients ($n = 44$) *versus* 19.9 (10.4 to 29.0) mg in placebo patients ($n = 48$; 36% reduction; ratio, 0.64 [95% CI, 0.41 to 1.00]; $P = 0.048$).

Conclusions: The protocol-specified intention-to-treat analysis demonstrated that serratus anterior plane block did not result in a significant reduction in opioid consumption when added to a multimodal analgesic regimen after thoracoscopic anatomic lung resection. The sensitivity as-treated analysis showed a significant and modest clinical reduction in the primary outcome that warrants further investigation.

(ANESTHESIOLOGY 2024; 141:1065–74)

postoperative intercostal blocks. Patients were randomized to additionally receive a serratus anterior plane block at the end of surgery or to receive a placebo serratus anterior plane block.

- The primary study outcome was cumulative intravenous morphine equivalents received in the first 24 h after surgery.
- Intention-to-treat analysis found that 24-h postoperative intravenous morphine equivalents were not significantly increased for the placebo group compared with the intervention group. An additional as-treated analysis found that the intravenous morphine equivalents received by the placebo group were significantly but modestly higher at 24 h after surgery than the intravenous morphine equivalents received by the serratus anterior plane block group.
- Future studies may be warranted to further explore potential benefit of serratus anterior plane blocks in minimally invasive thoracic lung surgery patients.

This article is featured in "This Month in Anesthesiology," page A1.

Copyright © 2024 American Society of Anesthesiologists. All Rights Reserved. ANESTHESIOLOGY 2024; 141:1065–74. DOI: 10.1097/ALN.0000000000005224

Minimally invasive approaches to lung resection, such as video-assisted thoracoscopic surgery and robotic-assisted thoracoscopic surgery, have been associated with lower rates of pulmonary complications and faster recovery compared with open thoracotomy.^{1–3} However, pain after minimally invasive thoracic surgery can still be severe.⁴ The pain syndrome after thoracic surgery is multifactorial, with components of inflammation from local tissue trauma, nociceptive somatic pain, visceral pain, neuropathic pain from nerve injury and irritation, and referred pain from diaphragmatic and mediastinal manipulation.^{5,6} Thus, the current paradigm for the treatment of postoperative chest wall pain involves a multimodal approach, including regional and neuraxial techniques, to address the multiple mechanisms of pain. Thoracic epidural analgesia has historically been the reference standard for management of thoracotomy pain, although ultrasound-guided truncal fascial plane block has emerged as an effective alternative.⁷ The incorporation of regional analgesia in the management of patients undergoing minimally invasive thoracic surgery is also a matter of current interest in anesthesiology owing to the opioid epidemic.^{8,9} Although evidence supporting regional techniques that reduce the risk of chronic postoperative opioid use is somewhat lacking,¹⁰ the increased adoption of such approaches promises to reduce opioid exposure in the acute postoperative period and may help to avoid the common

side effects of opioids, such as sedation, dizziness, nausea, vomiting, constipation, and respiratory depression.

One such regional technique, the serratus anterior plane block, involves injecting local anesthetic into a fascial plane adjacent to the serratus anterior muscle.¹¹ Somatic pain relief is most likely mediated by an effect on the lateral cutaneous branches of the intercostal nerves, which bring sensation from the chest wall.¹² Serratus anterior plane block has been studied in patients undergoing thoracotomy and video-assisted thoracoscopic surgery and was found to have beneficial effects on analgesia and quality of recovery.^{13–15} Serratus anterior plane block has also been compared with thoracic epidural analgesia,^{16,17} paravertebral block,^{18–20} and erector spinae plane block^{21,22} in patients undergoing thoracic surgery. In a 2023 practice advisory for regional anesthesia in thoracic surgery,⁷ an expert panel cited that serratus anterior plane block is noninferior to paravertebral block but inferior to erector spinae plane block. This creates confusion regarding analgesic efficacy between options for the anesthesiologist. High-quality studies that consider the existing practice of multimodal analgesia within enhanced recovery pathways are needed to inform clinical practice on the benefits of truncal fascial blocks for minimally invasive thoracic surgery.

We hypothesized that serratus anterior plane block would be associated with lower acute postoperative opioid requirements and improved measures of early recovery after minimally invasive anatomic lung resection. The trial was conducted in the context of an established enhanced recovery pathway that already included surgeon-administered intercostal nerve blocks and multimodal analgesia.

Materials and Methods

The Institutional Review Board at Memorial Sloan Kettering Cancer Center (New York, New York) approved the study protocol (Institutional Review Board No. 19-470) on December 18, 2019, and all patients gave written informed consent before inclusion in the trial. The trial was registered before patient enrollment at ClinicalTrials.gov (NCT04238455; principal investigator: Jacob Jackson, M.D.; date of registration: January 23, 2020). Patients were enrolled from February 4, 2020, to June 28, 2022. The study followed Consolidated Standards of Reporting Trials guidelines.

Patients who were 18 yr or older, weighed 50 kg or more, and were scheduled to undergo elective unilateral minimally invasive anatomic lung resection were eligible for the study. Patients who underwent wedge resection(s) in addition to their primary segmentectomy or lobectomy were eligible according to their primary procedure, as were segmentectomy patients who underwent multiple segmentectomies (trisegmentectomy; $n = 1$) or lobectomy patients who underwent an additional lobectomy (bilobectomy; $n = 1$). No enrolled patients underwent pneumonectomy. Exclusion criteria were a history of ipsilateral thoracic surgery, a history of anaphylaxis or contraindication to local anesthetics, chronic sustained-release opioid use for more

Submitted for publication December 19, 2023. Accepted for publication September 9, 2024. Published online first on September 16, 2024.

Jacob C. Jackson, M.D.: Department of Anesthesiology and Critical Care Medicine, Memorial Sloan Kettering Cancer Center, New York, New York; Department of Anesthesiology, Weill Cornell Medical College, New York, New York.

Kay See Tan, Ph.D.: Department of Anesthesiology and Critical Care Medicine, Memorial Sloan Kettering Cancer Center, New York, New York.

Alessia Pedoto, M.D.: Department of Anesthesiology and Critical Care Medicine, Memorial Sloan Kettering Cancer Center, New York, New York; Department of Anesthesiology, Weill Cornell Medical College, New York, New York.

Bernard J. Park, M.D.: Thoracic Service, Department of Surgery, Memorial Sloan Kettering Cancer Center, New York, New York; Department of Surgery, Weill Cornell Medical College, New York, New York.

Valerie W. Rusch, M.D.: Thoracic Service, Department of Surgery, Memorial Sloan Kettering Cancer Center, New York, New York; Department of Surgery, Weill Cornell Medical College, New York, New York.

David R. Jones, M.D.: Thoracic Service, Department of Surgery, Memorial Sloan Kettering Cancer Center, New York, New York; Department of Surgery, Weill Cornell Medical College, New York, New York.

Hao Zhang, M.D.: Department of Anesthesiology and Critical Care Medicine, Memorial Sloan Kettering Cancer Center, New York, New York.

Dawn Desiderio, M.D.: Department of Anesthesiology and Critical Care Medicine, Memorial Sloan Kettering Cancer Center, New York, New York; Department of Anesthesiology, Weill Cornell Medical College, New York, New York.

Gregory W. Fischer, M.D.: Department of Anesthesiology and Critical Care Medicine, Memorial Sloan Kettering Cancer Center, New York, New York; Department of Anesthesiology, Weill Cornell Medical College, New York, New York.

David Amar, M.D.: Department of Anesthesiology and Critical Care Medicine, Memorial Sloan Kettering Cancer Center, New York, New York; Department of Anesthesiology, Weill Cornell Medical College, New York, New York.

than 2 weeks' duration during the 30 days before surgery, significant cognitive impairment or documented psychologic impairment, pregnancy, and American Society of Anesthesiologists Physical Status greater than III.

Randomization and Blinding

Randomization using the Memorial Sloan Kettering Clinical Research Database was performed intraoperatively, at the time of removal of the surgical specimen from the patient, to avoid postrandomization exclusions. Patients were randomized to either the serratus anterior plane block group or the placebo group, with a 1:1 allocation ratio. Randomization was stratified by segmentectomy or lobectomy and by video-assisted thoracoscopic surgery or robotic-assisted thoracoscopic surgery. Only the investigational pharmacists involved in the study had access to the patient allocation in the Clinical Research Database; they prepared blinded syringes for the anesthesiologist who administered the study block. The patient, surgeon, anesthesiologist, nurses, investigators performing patient assessment after surgery, and study statistician were blinded to treatment group allocation. Group allocation was concealed until the trial was closed to accrual and the final patient had finished the study period of 30 days from the day of surgery.

Perioperative Management

Patients with an Apfel score of 3 or greater (1 point each for female sex, nonsmoker, history of postoperative nausea and vomiting, and use of postoperative opioids) or a history of severe postoperative nausea or vomiting were administered the antiemetic aprepitant, a substance P/neurokinin-1 receptor antagonist, during the preoperative period as part of the institutional enhanced recovery pathway for nausea and vomiting prophylaxis. All patients received 4 mg intravenous dexamethasone intraoperatively, also for nausea and vomiting prophylaxis. The anesthetic management and other aspects of perioperative care were performed in a routine manner, including standard monitoring, induction of general anesthesia with propofol, maintenance of general anesthesia with sevoflurane, neuromuscular blockade with rocuronium or vecuronium, lung isolation with a left-sided double-lumen tube, and placement of a radial arterial line. Fentanyl, dexmedetomidine, acetaminophen, and ketorolac were administered intraoperatively; however, ketamine and opioids other than fentanyl were not permitted intraoperatively for study patients. Wound infiltration with local anesthetic by the surgical team was also not permitted. Video-assisted thoracoscopic surgery was conducted with three ports; robotic-assisted thoracoscopic surgery was conducted with five ports. All patients received a single 18-French chest tube. Anesthesiologist investigators who were blinded to group allocation performed the serratus anterior plane block or sham block postoperatively, as described below. In the postanesthesia care unit (PACU), patients recovered in accordance

with the institutional enhanced recovery pathway. There were no study restrictions on medications, including analgesics, or interventions used to aid in the recovery process. Our institutional enhanced recovery analgesic regimen for the postoperative phase consisted of intravenous and oral opioids, intravenous and oral acetaminophen, intravenous ketorolac, and lidocaine patches placed on the ipsilateral chest wall near the chest tube. Patients who took gabapentinoids at home were allowed to continue them postoperatively.

Intercostal Nerve Blocks

After the completion of the lung resection, the surgical team followed their existing practice of performing internal intercostal nerve blocks under thoracoscopic visualization. The intercostal nerve blocks were standardized to 3 ml bupivacaine 0.25% injected in the fifth through the eighth intercostal spaces (six intercostal spaces) for a total volume of 18 ml and a total dose of 45 mg. All study patients received internal intercostal nerve blocks.

Serratus Anterior Plane Block

Serratus anterior plane block was performed by the anesthesiology team after closure of the skin incisions but before the patient's emergence from general anesthesia. The patient was already in the lateral decubitus position from the procedure and had been prepped and draped in a sterile fashion. Sonographic landmarks were identified along the posterior axillary line, including the latissimus dorsi muscle, serratus anterior muscle, intercostal muscles, ribs, and pleura. A 22-gauge, 50-mm echogenic block needle (SonoBlock II, Pajunk Medical Systems, USA) was advanced under ultrasound guidance (Sonosite S2; Fujifilm Sonosite, USA) and in plane with a parasagittally positioned linear 13-6 MHz ultrasound transducer (L25 transducer; Fujifilm Sonosite) at the level of the nipple line until the fifth rib was contacted. In the fascial plane deep to the serratus anterior muscle, 20 ml bupivacaine 0.25% with 2 mg dexamethasone and 50 µg clonidine was injected (serratus anterior plane block group). Aspiration at 5-ml intervals was performed to avoid intravascular injection. A second injection of 20 ml identical injectate was performed using the same technique at the eighth rib, just cephalad to the chest tube site. The total doses administered were 100 mg bupivacaine 0.25%, 4 mg dexamethasone, and 100 µg clonidine for each patient in the study group. For patients in the placebo group, the syringes contained normal saline. The total volume injected in both groups was 40 ml. The serratus anterior plane block procedure was tailored to be performed in approximately 5 min. Afterward, the anesthesiology team emerged the patient from general anesthesia, extubated the patient, and transported the patient to the PACU when stable.

Outcome Measures

The primary outcome was cumulative intravenous morphine equivalents during the first 24 h after arrival to the

PACU. Secondary outcomes were cumulative intravenous morphine equivalents during the first 48 h after arrival to the PACU and 11-point numerical rating scale pain scores, where 0 indicates “no pain” and 10 indicates “the worst pain imaginable.” Pain scores were measured at rest and during cough as part of routine nursing assessments at the following timepoints: every 2 h postoperatively until 12 h and then at 24 h, 36 h, and 48 h, if the patient had not yet been discharged from the hospital. For incentive spirometry, the highest achieved volume, to the nearest 250 ml, during a maximal inspiratory maneuver was measured as the best of three attempts, with patients sitting upright, using a handheld volumetric incentive spirometer (Vyair AirLife, Cardinal Health, USA). Measurements were recorded preoperatively on the day of surgery (baseline) and again on postoperative days 1 and 2, unless the patient had already been discharged from the hospital. The incidence of nausea and vomiting was ascertained by in-person interview on postoperative days 1 and 2; the administration of a rescue antiemetic (e.g., ondansetron) during the first 48 h postoperatively was considered a positive incidence of nausea, regardless of the patient response at the time of the interview with research staff. The Quality of Recovery–15 (QoR–15) questionnaire²³ was administered at the time of research consent (baseline, usually within 1 week before surgery) and on postoperative day 7, either in person or by telephone interview with research staff. Three attempts were made to contact patients *via* telephone for the postoperative assessment before the patient was deemed to be unreachable. Although it was not prespecified as a secondary outcome, length of hospital stay was also collected for all patients from hospital records and was compared between the two groups. Other analyzed measures included the use of postoperative nonopioid analgesics during the first 48 h postoperatively and the occurrence of serious adverse events within 30 days of the procedure.

Statistical Analysis

The sample size calculation was based on the primary outcome, using the ratio of means. This choice was motivated by the relevance of the hypothesis as a percentage reduction in intravenous morphine equivalents with serratus anterior plane block (ratio of two means), rather than the difference of two actual amounts in their original scale (difference of two means), and addresses the right-skewed distribution of opioid requirements.²⁴ Existing literature supported a hypothesized ratio of 0.65 of study group to placebo group mean postoperative intravenous morphine equivalents.¹⁴ Assuming a two-sided α of 0.05, a total sample size of 92 evaluable patients would yield 80% power to detect a ratio of 0.65 of study group to placebo group mean intravenous morphine equivalents (i.e., a mean opioid reduction of 35%), with a coefficient of variation of 0.85. The sample size calculation was conducted using the East 6 program (Cytel, USA).

The primary outcome was analyzed using a linear regression model for log-transformed postoperative opioid consumption in morphine milligram equivalents during the first 24 h after arrival in the PACU, including group assignment and stratification factors. Pain scores recorded over time were analyzed using mixed-effects linear regression models, with patient-level mixed effects and fixed effects of group assignment, stratification factors, and timepoint of measurement. Postoperative inspiratory volume on incentive spirometry at the patient level was analyzed using linear regression, with group assignment, stratification factors, and adjustment for baseline volume as covariates. The odds of postoperative nausea and vomiting between the two groups were quantified using logistic regression, with group assignment and stratification factors. The change in global QoR–15 score (postoperative day 7 minus baseline) was summarized for each patient and compared between the two groups using linear regression, with group assignment and stratification factors. All major comparisons between the groups were performed according to the intention-to-treat principle. Although it was not prespecified in the protocol, a sensitivity analysis of the primary outcome and of the secondary outcome of cumulative postoperative intravenous morphine equivalents during the first 48 h postoperatively was also performed. All statistical tests were two-sided, and $P < 0.05$ was considered to indicate statistical significance. Statistical analyses were conducted using Stata 18.0 (StataCorp, USA) and R 4.1.2 (R Core Team, Austria).

Results

A total of 99 patients were consented to the study (fig. 1). Four patients who were consented chose to withdraw before surgery and randomization. Two patients who were consented could not be randomized for other reasons: one patient’s surgical case was delayed late into the evening, when research staff were no longer available, and one patient underwent surgery during the height of the COVID–19 pandemic, when research workflows were disrupted. The remaining 93 patients were enrolled and randomized. Of the 47 patients in the placebo group, 1 patient could not be included for analysis because of bleeding upon arrival to the PACU, which required immediate return to the operating room for thoracotomy. Data on 92 patients were included in the final analysis (46 patients per group). Within the study group, logistic errors occurred for two patients: one patient did not receive any block because of a technical issue with the randomization software that prevented timely creation of the block syringes by the investigational pharmacy, and one patient received a sham block with normal saline because of an error by the investigational pharmacy (summarized in fig. 1). Therefore, in the sensitivity analysis, two patients who experienced logistic errors were analyzed with the placebo group instead of the serratus anterior plane block group (fig. 1) to reflect an as-treated analysis. Demographic data, comorbid

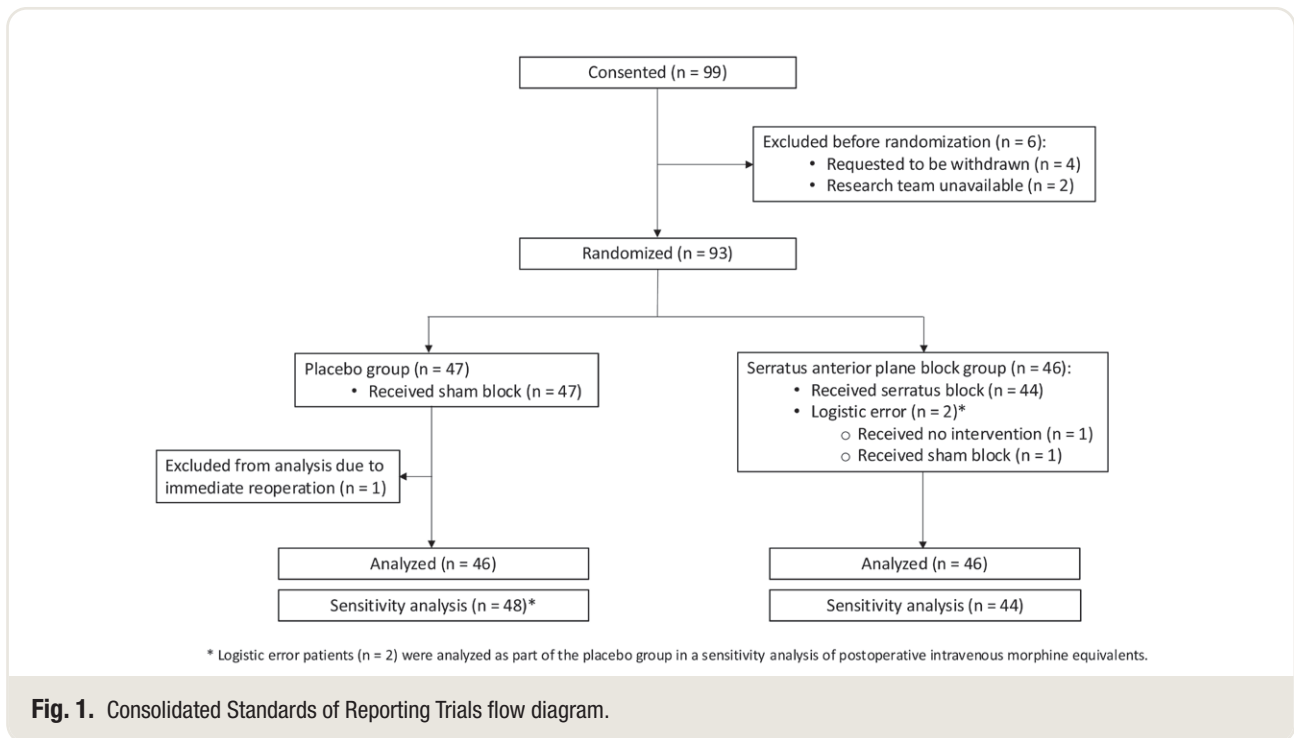


Fig. 1. Consolidated Standards of Reporting Trials flow diagram.

conditions, and operative details for these study subjects are detailed in table 1.

In the intention-to-treat analysis of the primary outcome, median (interquartile range) cumulative 24-h intravenous morphine equivalents was not significantly different between the groups after adjustment for stratification factors (serratus anterior plane block, 10.6 [5.0 to 27.1] mg; placebo, 18.8 [9.9 to 29.6] mg; a reduction of 32% [ratio, 0.68 (95% CI, 0.44 to 1.06)]; $P = 0.085$; table 2). The cumulative 48-h postoperative intravenous morphine equivalents was also not significantly different between the groups after adjustment for stratification factors (serratus anterior plane block, 16.3 [6.3 to 38.8] mg; placebo, 26.7 [14.6 to 37.3] mg; a reduction of 35% [model-based ratio, 0.65 (95% CI, 0.41 to 1.03)]; $P = 0.068$; table 2). In the sensitivity analysis, using the as-treated approach, cumulative 24-h intravenous morphine equivalents was lower in the serratus anterior plane block group after adjustment for stratification factors (serratus anterior plane block, 10.0 [5.0 to 27.2] mg; placebo, 19.9 [10.4 to 29.0] mg; a reduction of 36% [ratio, 0.64 (95% CI, 0.41 to 1.00)]; $P = 0.048$; table 2). The cumulative 48-h postoperative intravenous morphine equivalents was also lower in the serratus anterior plane block group after adjustment for stratification factors (serratus anterior plane block, 15.6 [5.6 to 38.3] mg; placebo, 26.8 [14.7 to 38.6] mg; a reduction of 40% [ratio, 0.60 (95% CI, 0.38 to 0.97)]; $P = 0.036$; table 2).

Median pain scores at rest or with cough were not significantly different between groups when compared at any of the timepoints. Using a composite of all available pain scores, pain scores at rest were lower over time in

the serratus anterior plane block group, but the difference was not statistically significant (coefficient, -0.22 [95% CI, -0.59 to 0.14]; $P = 0.2$; fig. 2A). Composite pain scores with cough were lower in the serratus anterior plane block group (coefficient, -0.41 [95% CI, -0.81 to -0.01]; $P = 0.044$; fig. 2B). Of note, no patients were discharged within the first 24 h postoperatively. Four patients were discharged within the first 48 h postoperatively, three of whom were in the serratus anterior plane block group.

After surgery, the decrease in inspiratory volume on incentive spirometry from baseline was similar between the groups after adjustment for stratification factors and baseline value (postoperative day 1: coefficient, 80 [95% CI, -116 to 276]; $P = 0.4$; postoperative day 2: coefficient, 84 [95% CI, -125 to 292]; $P = 0.4$; table 3). The odds of experiencing postoperative nausea and/or vomiting on postoperative days 1 and 2 were not statistically significantly different between the groups (odds ratio, 1.2 [95% CI, 0.35 to 3.91]; $P = 0.8$; table 3), nor were QoR-15 global scores statistically significantly different on postoperative day 7, after adjustment for stratification factors and baseline score (coefficient, 3.7 [95% CI, -2.10 to 9.45]; $P = 0.2$; table 3). The length of hospital stay was shorter in the serratus anterior plane block group by 25%, but this difference was not statistically significant (ratio, 0.75 [95% CI, 0.53 to 1.05]; $P = 0.1$; table 3). The use of nonopioid analgesics during the first 48 h postoperatively was similar between the groups (table 4). Serious adverse events within 30 days of the procedure in the placebo group included one case each of urosepsis requiring intensive care unit (ICU) admission, splenic

Table 1. Patient Characteristics and Operative Details

Patient and Operative Characteristic	Placebo Group (n = 46)	Serratus Anterior Plane Block Group (n = 46)
Age, yr	69 (62–75)	66 (56–73)
Female sex	24 (52)	32 (70)
Body mass index, kg/m ²	28 (23–32)	26 (23–29)
ASA Physical Status		
II	2 (4)	10 (22)
III	44 (96)	36 (78)
Race or ethnic group		
White	42 (91)	39 (85)
Non-White	4 (9)	7 (15)
Apfel score ≥ 3	21 (46)	31 (67)
Hypertension	16 (35)	21 (46)
Diabetes mellitus	2 (4)	7 (15)
Ischemic heart disease	3 (7)	5 (11)
Smoking status		
Never smoker	16 (35)	16 (35)
Former smoker	23 (50)	27 (59)
Current smoker	7 (15)	3 (7)
COPD	5 (11)	8 (17)
FEV ₁ , % predicted	90 (74–109)	96 (79–105)
Preoperative numerical rating scale pain score at rest > 0	3 (7)	3 (7)
Video-assisted thoracic surgery	19 (41)	21 (46)
Robotic-assisted thoracic surgery	27 (59)	25 (54)
Segmentectomy	18 (39)	15 (33)
Lobectomy	28 (61)	31 (67)
Surgical side right	23 (50)	30 (65)
Duration of surgery, h	3.2 (2.8–3.8)	3.2 (2.6–3.9)

Data are median (interquartile range) or n (%).

ASA, American Society of Anesthesiologists; COPD, chronic obstructive pulmonary disease; FEV₁, forced expiratory volume in 1 s.

laceration requiring embolization, and possible ethanol withdrawal syndrome concurrent with pneumonia leading to ICU admission. One patient in the placebo group presented to an outside hospital for possible transient ischemic attack in the setting of new-onset atrial fibrillation. In the serratus anterior plane block group, serious adverse events within 30 days of the procedure included one case of pneumothorax after discharge requiring return to the hospital for chest tube placement. Two patients developed pneumonia, one of whom required ICU admission; the other patient was diagnosed after hospital discharge and required readmission. There were no complications directly associated with serratus anterior plane block or sham block in the trial.

Discussion

Incorporation of serratus anterior plane block into a multimodal analgesia treatment plan for patients undergoing minimally invasive anatomic lung resection was not associated with a significant reduction in the primary outcome of intravenous morphine equivalents in the first 24 h postoperatively. Despite a 44% reduction in median intravenous

morphine equivalents in the serratus anterior plane block group, and a 32% reduction after adjustment for stratification factors, the difference was not statistically significant between groups. Interestingly, the sensitivity analysis did reveal a 50% reduction in median intravenous morphine equivalents, and a 36% reduction after adjustment for stratification factors, which was statistically significant as per our hypothesis. When assessing the intravenous morphine equivalents reduction during the first 48 h postoperatively, there was a similar reduction in the serratus anterior plane block group that was not statistically significant except in the sensitivity analysis. The other notable finding was a statistically significant reduction in composite pain with cough score in the serratus anterior plane block group, despite similar results between groups at individual timepoints for both pain at rest and pain with cough scores.

In our study, serratus anterior plane block had several favorable features. Serratus anterior plane block has previously been shown to have minimal risks,^{13–15} and the technique did not result in any block-related complications in the current study. On average, the block was performed in less than 5 min, concurrent with the patient's emergence from general anesthesia and with the patient already in the lateral decubitus position. Because of its ease of administration, serratus anterior plane block had a short learning curve at our institution, even among anesthesiologists with no previous formal training in ultrasound or regional anesthesia. Additionally, serratus anterior plane block is better visualized than deeper blocks in patients with a large body habitus and more likely to be safe to perform in situations where a deeper block may be considered too risky (*e.g.*, because of anticoagulation or bleeding diathesis concerns). Together, these qualities may recommend serratus anterior plane block over other fascial plane blocks of the chest for patients undergoing minimally invasive thoracic surgery without a thoracic epidural.

The serratus anterior plane block technique used in this study was informed by the existing literature. In the original description by Blanco *et al.*,¹¹ superficial serratus anterior plane block (*i.e.*, injection in the fascial plane superficial to the serratus anterior muscle) had a longer duration and greater area of sensory loss on the hemithorax than injection deep to the serratus anterior muscle when evaluated in four healthy volunteers. However, in a cadaveric study by Biswas *et al.*,²⁵ a deep injection technique was shown to provide a comparable injectate spread to a superficial injection technique. Furthermore, the same study showed that a double-injection technique (40 ml *vs.* 20 ml) doubled the area of injectate spread.²⁵ A retrospective review of patients with postmastectomy pain²⁶ and a retrospective cohort study of patients who underwent ambulatory breast cancer surgery²⁷ also suggested that injection in the fascial plane deep to the serratus anterior muscle was as effective as superficial injection. In our experience, the superficial plane can be difficult to identify at the level of the eighth rib because of the thinner latissimus dorsi and serratus anterior

Table 2. Postoperative Opioid Consumption

Analysis, Period	Placebo Group	Serratus Anterior Plane Block Group	Serratus Anterior Plane Block:Placebo Ratio (95% CI)	Opioid Reduction	P Value
Intention to treat*					
0–24 h	18.8 (9.9–29.6)	10.6 (5.0–27.1)	0.68 (0.44–1.06)	32%	0.085
24–48 h	5.0 (2.5–13.3)	5.0 (0–10.0)	0.73 (0.44–1.19)	27%	0.2
0–48 h	26.7 (14.6–37.3)	16.3 (6.3–38.8)	0.65 (0.41–1.03)	35%	0.068
As treated†					
0–24 h	19.9 (10.4–29.0)	10.0 (5.0–27.2)	0.64 (0.41–1.00)	36%	0.048‡
24–48 h	5.0 (2.5–14.2)	3.8 (0–10.0)	0.67 (0.41–1.09)	33%	0.11
0–48 h	26.8 (14.7–38.6)	15.6 (5.6–38.3)	0.60 (0.38–0.97)	40%	0.036‡

Data are median (interquartile range) in intravenous morphine equivalents.

*Placebo group, n = 46; serratus anterior plane block group, n = 46. †Placebo group, n = 48; serratus anterior plane block group, n = 44. ‡P < 0.05.

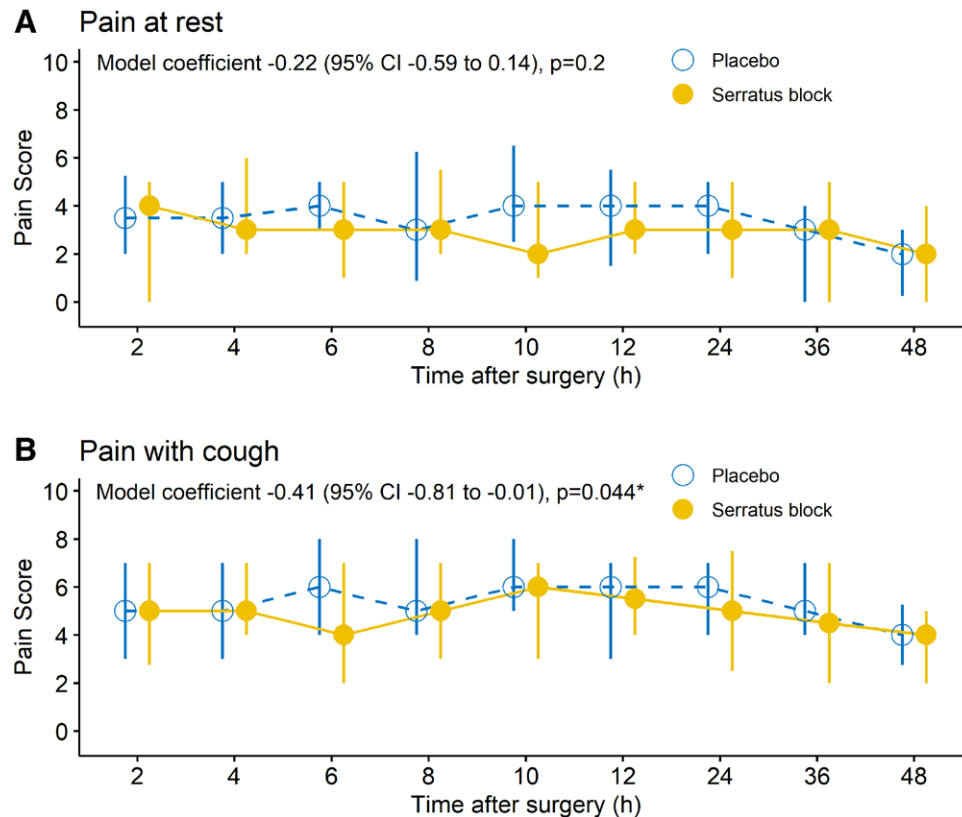


Fig. 2. Postoperative numerical rating scale pain scores at rest (A) and with cough (B). The data are shown as median (circles) with interquartile range (error bars). The model coefficients quantify the differences in composite numerical rating scale pain scores for the serratus anterior plane block group versus the placebo group using mixed-effects linear regression models with patient-level random effects and fixed effects of group assignment, stratification factors, and timepoint of numerical rating scale measurement. *P < 0.05.

muscle bodies when moving caudally along the posterior axillary line. Also, the deep injection technique is easier to perform because of tactile feedback from contacting the rib with the block needle. We located the injections in the posterior axillary line, instead of the midaxillary line, because

of the posterior location of a port for robotic-assisted procedures and our own experience with patient discomfort at this location after receipt of serratus anterior plane block in the midaxillary line. The adjuvants used in the block were added to improve the quality of the block and to extend

Table 3. Secondary Outcomes

Outcome	Placebo Group	Serratus Anterior Plane Block Group	Coefficient (95% CI)	P Value
Inspiratory volume on incentive spirometry, ml				
Baseline	2,250 (2,000–3,000)	2,000 (1,500–2,500)		
Postoperative day 1	1,250 (1,000–1,500)	1,250 (1,000–1,500)	80* (–116 to 276)	0.4
Postoperative day 2	1,500 (1,000–2,000)	1,500 (1,000–1,600)	84* (–125 to 292)	0.4
Nausea and/or vomiting, postoperative days 1 and 2	6 (13)	7 (15)	1.2† (0.35 to 3.91)	0.8
Quality of Recovery–15 global score				
Baseline	140 (133–147)	144 (128–148)		
Postoperative day 7	128 (114–136)	134 (117–138)	3.7‡ (–2.10 to 9.45)	0.2
Length of hospital stay, d	3.0 (2.0–8.0)	3.0 (2.0–5.0)	0.75§ (0.53 to 1.05)	0.1

Data are median (interquartile range) or n (%).

*The coefficient compares the serratus anterior plane block group versus the placebo group using linear regression with group assignment, stratification factors, and adjustment for baseline volume as a covariate. †This value is an odds ratio rather than a coefficient. ‡Change in global Quality of Recovery–15 score (postoperative day 7 minus baseline) was summarized for each patient, then compared for the serratus anterior plane block group versus the placebo group using linear regression with group assignment and stratification factors. §This value is a ratio of the serratus anterior plane block group to the placebo group rather than a coefficient.

Table 4. Postoperative Nonopioid Analgesic Use (0 to 48 h)

Analgesic	Placebo Group	Serratus Anterior Plane Block Group	P Value
Acetaminophen, mg	4,875 (4,875–5,850)	4,875 (4,875–4,975)	0.3
Ibuprofen, mg	1,800 (0–3,000)	1,800 (0–3,000)	0.6
Ketorolac, mg	15 (0–45)	15 (0–60)	0.8
Gabapentin, mg	0 (0–300)	0 (0–400)	0.3
Use of lidocaine patches	20 (43)	20 (43)	1.0

Data are median (interquartile range) or n (%).

the duration. Clonidine is an α -2 receptor agonist commonly used for this purpose,²⁸ and dexamethasone is a corticosteroid that has been used specifically to prolong and enhance serratus anterior plane block in patients undergoing video-assisted thoracoscopic surgery.²⁹ The decision to perform the block postoperatively allowed us to minimize disruptions to workflow, avoid delaying surgery start time, perform intraoperative randomization, and synchronize the timing of serratus anterior plane block for all study patients.

The strengths of this study are (1) the clearly defined and randomized patient population (with stratification to procedure type and approach), (2) the inclusion of a sham block control, and (3) the analysis of patient-centered outcome measures. First, previous studies of serratus anterior plane block have included diverse types of thoracic procedures (e.g., lung resection, esophagectomy, lung volume reduction) and varying degrees of lung resection, from wedge resection to pneumonectomy, without discrimination. In this study, we not only focused on a discrete group of patients undergoing minimally invasive lung resection but also used stratification methods to ensure balance across important clinical factors in our trial cohorts. Second, a sham control group reduced

bias regarding treatment allocation and the assessment of subjective outcomes modified by treatment. The purpose of the sham block control was to preserve adequate blinding of the study patient, the investigators, and the care providers, all of whom could have noticed the block injection sites or other unforeseen differences between the study groups. In addition, from a physiologic standpoint, a sham block helped eliminate any confounding effect that needling or stretch of the fascial plane from the injectate may have had on sensation in the hemithorax. Finally, in addition to analgesic outcomes, we analyzed a baseline and a postoperative QoR–15 assessment. The QoR–15 score is internationally recognized as a valid, extensive, and yet efficient means of assessing patients’ quality of recovery after surgery, covering measures of physical and mental well-being.^{29,30} Although previous studies of serratus anterior plane block have used quality of recovery as the primary outcome measure, we were less optimistic about finding a significant difference between groups who were both receiving “usual care” according to an enhanced recovery pathway and elected to analyze quality of recovery as a secondary outcome. At least one previous study failed to use a baseline QoR–15 score as a reference, and as such, this may explain discrepancies in the effect of serratus anterior plane block on QoR–15 scores in the existing literature.²² Interestingly, Kim *et al.*¹⁵ found that serratus anterior plane block was associated with quality of recovery in patients undergoing video-assisted thoracoscopic surgery; however, they used the long-version QoR–40 assessment and performed the assessment earlier in the recovery period (at 24 h instead of 7 days after surgery).

Our study has several limitations. First, the study population was from a single center. Despite a large catchment area, the patient population was not diverse in terms of age or race. Second, the study was powered to detect a difference only in the primary outcome, leaving the study underpowered to detect differences in the secondary outcomes. Larger, more-tailored studies may be required to further elucidate the effects of serratus anterior plane block on respiratory function,

postoperative nausea and vomiting, and other early recovery outcomes. Third, we were limited in our ability to collect some secondary outcome data points later during recovery. However, we navigated these issues with statistical methods that accounted for the numerous collected data points and attempted to mitigate the effect of missing data points.

In conclusion, serratus anterior plane block did not result in a significant reduction in postoperative opioid consumption when added to a multimodal regimen for acute pain management after thoracoscopic anatomic lung resection. Serratus anterior plane block was associated with a statistically significant reduction in composite pain with cough score. The sensitivity as-treated analysis showed a significant and modest clinical reduction in the primary outcome that warrants further investigation.

Acknowledgments

The authors thank David B. Sewell, M.A., M.F.A. (Department of Surgery, Memorial Sloan Kettering Cancer Center, New York, New York), for his help with preparation of the manuscript.

Research Support

This study was supported, in part, by the National Institutes of Health (Bethesda, Maryland)/National Cancer Institute (Bethesda, Maryland; Cancer Support Grant P30 CA008748).

Competing Interests

Dr. Park serves as a consultant for Intuitive Surgical (Orange, Connecticut), Ceevra (San Francisco, California), Medtronic (Minneapolis, Minnesota), and Becton Dickinson (Franklin Lakes, New Jersey). Dr. Jones is a member of the advisory council for AstraZeneca (Cambridge, United Kingdom) and the advisory committee for MORE Health (San Mateo, California), has been a speaker for DAVA Oncology (Plano, Texas), and receives research grant support from Merck (Rahway, New Jersey). The other authors declare no competing interests.

Reproducible Science

Full protocol available at: jacksoj1@mskcc.org. Raw data available at: jacksoj1@mskcc.org.

Correspondence

Address correspondence to Dr. Jackson: Memorial Sloan Kettering Cancer Center, 1275 York Avenue, Suite C-309, New York, New York 10065. jacksoj1@mskcc.org

References

1. Scott WJ, Allen MS, Darling G, et al.: Video-assisted thoracic surgery versus open lobectomy for lung

- cancer: A secondary analysis of data from the American College of Surgeons Oncology Group Z0030 randomized clinical trial. *J Thorac Cardiovasc Surg* 2010; 139:976–81; discussion 981
2. Falcoz PE, Puyraveau M, Thomas PA, et al.; ESTS Database Committee and ESTS Minimally Invasive Interest Group: Video-assisted thoracoscopic surgery versus open lobectomy for primary non-small cell lung cancer: A propensity-matched analysis of outcome from the European Society of Thoracic Surgeon database. *Eur J Cardiothorac Surg* 2016; 49:602–9
3. Nwogu CE, D'Cunha J, Pang H, et al.; Alliance for Clinical Trials in Oncology: VATS lobectomy has better perioperative outcomes than open lobectomy: CALGB 31001, an ancillary analysis of CALGB 140202 (Alliance). *Ann Thorac Surg* 2015; 99:399–405
4. Rizk NP, Ghanie A, Hsu M, et al.: A prospective trial comparing pain and quality of life measures after anatomic lung resection using thoracoscopy or thoracotomy. *Ann Thorac Surg* 2014; 98:1160–6
5. De Cosmo G, Aceto P, Gualtieri E, Congedo E: Analgesia in thoracic surgery: Review. *Minerva Anestesiol* 2009; 75:393–400
6. Mesbah A, Yeung J, Gao F: Pain after thoracotomy. *BJA Educ* 2016; 16:1–7
7. Makkad B, Heinke TL, Sheriffdeen R, et al.: Practice advisory for preoperative and intraoperative pain management of thoracic surgical patients: Part 1. *Anesth Analg* 2023; 137:2–25
8. Scholl L, Seth P, Kariisa M, Wilson N, Baldwin G: Drug and opioid-involved overdose deaths – United States, 2013–2017. *MMWR Morb Wkly Rep* 2019; 67:1419–27
9. Lim TY, Stringfellow EJ, Stafford CA, et al.: Modeling the evolution of the US opioid crisis for national policy development. *Proc Natl Acad Sci U S A* 2022; 119:e2115714119
10. Kharasch ED, Avram MJ, Clark JD: Rational perioperative opioid management in the era of the opioid crisis. *ANESTHESIOLOGY* 2020; 132:603–5
11. Blanco R, Parras T, McDonnell JG, Prats-Galino A: Serratus plane block: A novel ultrasound-guided thoracic wall nerve block. *Anaesthesia* 2013; 68:1107–13
12. Mayes J, Davison E, Panahi P, et al.: An anatomical evaluation of the serratus anterior plane block. *Anaesthesia* 2016; 71:1064–9
13. Okmen K, Okmen BM: The efficacy of serratus anterior plane block in analgesia for thoracotomy: A retrospective study. *J Anesth* 2017; 31:579–85
14. Park MH, Kim JA, Ahn HJ, Yang MK, Son HJ, Seong BG: A randomized trial of serratus plane block for analgesia after thoracoscopic surgery. *Anaesthesia* 2018; 73:1260–4
15. Kim DH, Oh YJ, Lee JG, Ha D, Chang YJ, Kwak HJ: Efficacy of ultrasound-guided serratus plane block on postoperative quality of recovery and analgesia

- after video-assisted thoracic surgery: A randomized, triple-blind, placebo-controlled study. *Anesth Analg* 2018; 126:1353–61
16. Khalil AE, Abdallah NM, Bashandy GM, Kaddah TA: Ultrasound-guided serratus anterior plane block versus thoracic epidural analgesia for thoracotomy pain. *J Cardiothorac Vasc Anesth* 2017; 31:152–8
 17. Elsabeeny WY, Ibrahim MA, Shehab NN, Mohammed A, Wadod MA: Serratus anterior plane block and erector spinae plane block versus thoracic epidural analgesia for perioperative thoracotomy pain control: A randomized controlled study. *J Cardiothorac Vasc Anesth* 2021; 35:2928–36
 18. Saad FS, El Baradie SY, Abdel Aliem MAW, Ali MM, Kotb TAM: Ultrasound-guided serratus anterior plane block versus thoracic paravertebral block for perioperative analgesia in thoracotomy. *Saudi J Anaesth* 2018; 12:565–70
 19. Hanley C, Wall T, Bukowska I, et al.: Ultrasound-guided continuous deep serratus anterior plane block versus continuous thoracic paravertebral block for perioperative analgesia in videoscopic-assisted thoracic surgery. *Eur J Pain* 2020; 24:828–38
 20. Wang L, Wang Y, Zhang X, Zhu X, Wang G: Serratus anterior plane block or thoracic paravertebral block for post-operative pain treatment after uniportal video-assisted thoracoscopic surgery: A retrospective propensity-matched study. *J Pain Res* 2019; 12:2231–8
 21. Ekinici M, Ciftci B, Golboyu BE, Demiraran Y, Bayrak Y, Tulgar S: A randomized trial to compare serratus anterior plane block and erector spinae plane block for pain management following thoracoscopic surgery. *Pain Med* 2020; 21:1248–54
 22. Finnerty DT, McMahon A, McNamara JR, Hartigan SD, Griffin M, Buggy DJ: Comparing erector spinae plane block with serratus anterior plane block for minimally invasive thoracic surgery: A randomized clinical trial. *Br J Anaesth* 2020; 125:802–10
 23. Stark PA, Myles PS, Burke JA: Development and psychometric evaluation of a postoperative quality of recovery score: The QoR-15. *ANESTHESIOLOGY* 2013; 118:1332–40
 24. Van Belle G, Martin DC: Sample size as a function of coefficient of variation and ratio of means. *Am Stat* 1993; 47:165–7
 25. Biswas A, Castanov V, Li Z, et al.: Serratus plane block: A cadaveric study to evaluate optimal injectate spread. *Reg Anesth Pain Med* 2018; 43:854–8
 26. Piracha MM, Thorp SL, Puttanniah V, Gulati A: A tale of two planes: Deep versus superficial serratus plane block for postmastectomy pain syndrome. *Reg Anesth Pain Med* 2017; 42:259–62
 27. Abdallah FW, Cil T, MacLean D, et al.: Too deep or not too deep? A propensity-matched comparison of the analgesic effects of a superficial versus deep serratus fascial plane block for ambulatory breast cancer surgery. *Reg Anesth Pain Med* 2018; 43:480–7
 28. Pöpping DM, Elia N, Marret E, Wenk M, Tramèr MR: Clonidine as an adjuvant to local anesthetics for peripheral nerve and plexus blocks: A meta-analysis of randomized trials. *ANESTHESIOLOGY* 2009; 111:406–15
 29. Chen JQ, Chen JR, Wang S, et al.: Effect of perineural dexamethasone with ropivacaine in continuous serratus anterior plane block for postoperative analgesia in patients undergoing video-assisted thoracoscopic surgery. *J Pain Res* 2022; 15:2315–25
 30. Myles PS, Boney O, Botti M, et al.: Systematic review and consensus definitions for the Standardised Endpoints in Perioperative Medicine (StEP) initiative: Patient comfort. *Br J Anaesth* 2018; 120:705–11