

An Autopsy Case of Troglitazone-Induced Fulminant Hepatitis

AKITAKA SHIBUYA, MD
MASAAKI WATANABE, MD
YOSHIKUNI FUJITA, MD
KATSUNORI SAIGENJI, MD

SADAHITO KUWAO, MD
HISAO TAKAHASHI, MD
HARUO TAKEUCHI, MD

OBJECTIVE — To study an autopsy case of troglitazone-induced fulminant hepatitis.

CASE REPORT — A 58-year-old man contracted severe hepatitis 2 months after administration of troglitazone for the treatment of type 2 diabetes. Liver damage progressed gradually, even after withdrawal of the agent. Despite intensive therapy, the hepatitis became fulminant and the patient died 8 weeks after the onset of liver damage. Autopsy revealed massive hepatic necrosis and cholestasis with inflammatory cell infiltration. The pathological findings and the positive result of the drug-induced lymphocyte stimulation test for troglitazone indicated that the liver damage was mediated by hypersensitivity to troglitazone.

CONCLUSIONS — One report has attributed troglitazone-induced liver damage in less severe cases to idiosyncratic reactions. However, the present case indicates that troglitazone can induce hypersensitivity resulting in fulminant hepatitis. Careful monitoring of serum liver enzymes during troglitazone therapy is therefore essential.

Diabetes Care 21:2140–2143, 1998

Troglitazone is a newly developed hypoglycemic agent that differs from conventional oral hypoglycemic agents in its pharmacological mode of action. This agent is metabolized in the liver, mainly by sulfation but partially by glucuronidation, and is then discharged into the feces with the bile (1). It improves insulin resistance, reduces insulinemia, lowers hepatic glucose production, and improves both fasting and postprandial glycemia in type 2 diabetic subjects (2–5). Thus, troglitazone has great therapeutic potential for the treatment of type 2 diabetes. In clinical trials of troglitazone, 48 of 1,134 (1.9%) patients in the U.S. and 6 of 1,111 patients (0.54%) in Japan showed elevations of serum alanine aminotransferase (ALT) levels after treatment with troglitazone, but the changes were only

mild (6–8). However, in late December 1997, 9 months after the agent became commercially available, the Japanese Ministry of Welfare issued a memorandum entitled “Urgent warning on pharmaceutical and medical device safety” that reported that four patients had died of fulminant hepatic failure.

Although Watkins et al. (8) suggested idiosyncratic reaction as a possible mechanism in less severe cases, the mechanism of troglitazone-induced fulminant hepatitis remains obscure. We present herein the first autopsy case of troglitazone-induced fulminant hepatitis in which hypersensitivity may have played an important role in the development of liver damage.

CASE REPORT — A 58-year-old Japanese male was admitted to the hospital

because of fulminant hepatitis. Four months before admission, he had been diagnosed as having type 2 diabetes. He was therefore placed on a diet of 1,800 kcal/day with 400 mg of troglitazone and 5.0 mg of glibenclamide daily in divided doses starting 22 July 1997. On 7 September 1997 glibenclamide was discontinued, because his HbA_{1c} had improved to 7.0%. In late September 1997, he experienced epigastric discomfort and general malaise. In the following week, jaundice with low-grade fever developed and became progressively worse. The patient was admitted to another hospital on 14 October 1997, by which time he had taken a total of ~33,600 mg of troglitazone. He was a shipping agent, with no family history of diabetes or liver disease. He seldom drank alcohol and had no history of drug allergy. On examination, the patient was alert but icteric. No rash, pruritus, or lymphadenopathy was detected. The liver and spleen were not palpable. The results of laboratory tests were as follows: white blood cell count, 5,800/ml (normal, 4,000–9,000) with 1.4% eosinophils; hemoglobin, 14.8 g/dl (normal, 12.5–17.0); platelet count, 10.3×10^4 /ml (normal, $15.0\text{--}35.0 \times 10^4$); prothrombin time, 14.2 s (normal, 10.8–12.6); total protein, 5.1 g/dl (normal, 6.5–8.1); albumin, 2.9 g/dl (normal, 3.8–5.2); total bilirubin, 143.6 mmol/l (normal, 3.4–17.1); direct bilirubin, 109.4 mmol/l (normal, <6.8); aspartate aminotransferase, 699 U/l (normal, 10–35); ALT, 1,655 U/l (normal, 5–40); and alkaline phosphatase, 378 U/l (normal, 96–346). Tests for IgM anti-hepatitis A virus antibody, hepatitis B virus surface (HBs) antigen, anti-HBs antibody, and anti-hepatitis C virus (HCV) antibody were all negative. There was no serological evidence of recent infection with cytomegalovirus or Epstein-Barr virus, and negative results were also obtained for anti-nuclear antibody, anti-mitochondrial antibody, anti-smooth muscle antibody, and anti-liver kidney microsome antibody were also negative. Computed tomography of the abdomen on 14 October 1997 confirmed the presence of ascites; the liver was atrophic and had a diffuse low-density appearance. Drug-induced lymphocyte

From the Departments of Internal Medicine (A.S., M.W., Y.F., K.S.) and Pathology (S.K.), Kitasato University School of Medicine; and Sagamichuo Clinic (H.Taka.) and Sagamino Hospital (H.Take.), Kanagawa, Japan.

Address correspondence and reprint requests to Akitaka Shibuya, MD, Department of Internal Medicine, Kitasato University School of Medicine, 1-15-1, Kitasato, Sagamihara, Kanagawa, 228-8555, Japan. E-mail: shibu-ya@ehp.kitasato-u.ac.jp.

Received for publication 2 June 1998 and accepted in revised form 19 August 1998.

Abbreviations: ALT, alanine aminotransferase; HB, hepatitis B virus.

A table elsewhere in this issue shows conventional and Système International (SI) units and conversion factors for many substances.

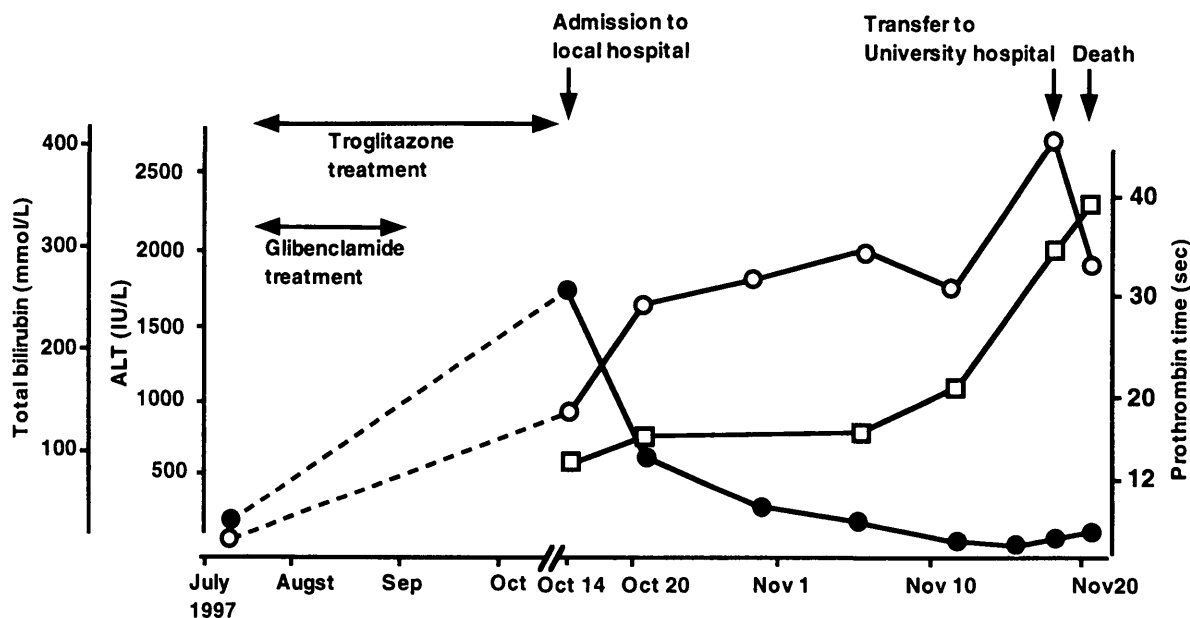


Figure 1—Clinical course during hospitalization. ○, total bilirubin; ●, alanine aminotransferase; □, prothrombin time.

stimulation tests were strongly positive (stimulation index, >200%) for troglitazone but negative for other drugs.

These results suggested troglitazone-induced acute hepatitis, which threatened to develop into fulminant liver failure, even though the patient was conscious. Troglitazone was discontinued immediately. The plasma concentration of troglitazone, measured by high-performance liquid chromatography on 17 October 1997, was below the limit of detection. Therapeutic trials of glucagon-insulin therapy and administration of fresh frozen plasma did not result in a favorable response. The total serum bilirubin concentration continued to increase gradually and the prothrombin time decreased (Fig. 1). Clouding of consciousness with flapping tremors developed on 8 November 1997, and the level of consciousness diminished progressively.

His condition was diagnosed as fulminant hepatitis, and he was transferred to this hospital on 18 November 1997, ~7 weeks after the onset of jaundice. On admission, the patient was semiconscious, incoherent, and uncooperative and showed marked icterus. The recumbent blood pressure was 122/84 mmHg. The pulse was 120, the respiration 20, and the temperature 37.4°C. There was some purpura on the abdomen and lower limbs. Abdominal ultrasonography demonstrated marked liver atrophy with ascites. The total bilirubin concentration had risen to 403.6 mmol, and the

prothrombin time had increased to 39.1 s. The white blood cell count was 9,600/ml with 9.6% eosinophilia (normal, 2.0–7.0). The plasma ammonia level was 161 mmol/l (normal, 11–55). Hepatitis B virus DNA, hepatitis C virus RNA, and hepatitis G virus RNA were not detected with serum polymerase chain reactions. We initiated plasmapheresis and continuous hemofiltration with acetate buffer solution, and also administered 1,000 mg/day of methyl prednisolone. However, liver failure progressed and a deep coma together with a marked tendency to bleed developed. The patient died on 21 November 1997, ~4 months after the initial administration of troglitazone.

Autopsy findings

The body was that of a well-developed, slightly obese, markedly icteric Japanese man. It measured 168 cm in length and weighed 82 kg. There was 4,500 ml of yellowish clear ascites. The liver weighed 520 g with marked yellowish atrophy. On the cut surface, dilated hepatic veins were conspicuous against the surrounding stroma, which had collapsed throughout the liver. Histologically, massive hepatocellular coagulation necrosis with moderate monocytic, neutrophilic, and eosinophilic infiltration was present (Figs. 2 and 3). The normal cord structure of hepatocytes was absent. Prominent ductular proliferation with biliary stasis was observed, though hepatocellular regeneration was not seen. No

granulomatous changes, giant cell transformations, apoptotic bodies, or vanishing bile ducts were observed. There was no copper accumulation in the liver. Acute pancreatic necrosis caused by ischemic change and massive hemorrhage of the retroperitoneal wall was evident.

CONCLUSIONS — Because the liver is the central organ of almost all drug metabolism, drug-induced liver disease is a potential complication of nearly every prescribed medicine (9). Troglitazone appears to have caused fulminant hepatic failure in the case presented here, since other causes of liver failure, such as viral hepatitis, alcohol intake, autoimmune disorders, and Wilson's disease were all excluded. The mechanism of troglitazone-induced hepatitis has been obscure. The clinical and autopsy findings in the present case were very important for understanding the mechanism of the disease.

In general, there are several possible mechanisms of drug-induced liver damage, such as direct toxic reactions, idiosyncratic reactions, hypersensitive reactions, cholestatic reactions, granulomatous reactions, etc. (9). In less severe cases of troglitazone-induced hepatitis, liver biopsies were performed in two patients (including one with jaundice) and confirmed the hepatocellular nature of the injury, which was consistent with an idiosyncratic drug reaction (8). The liver damage healed after the discontinuation of troglitazone in these

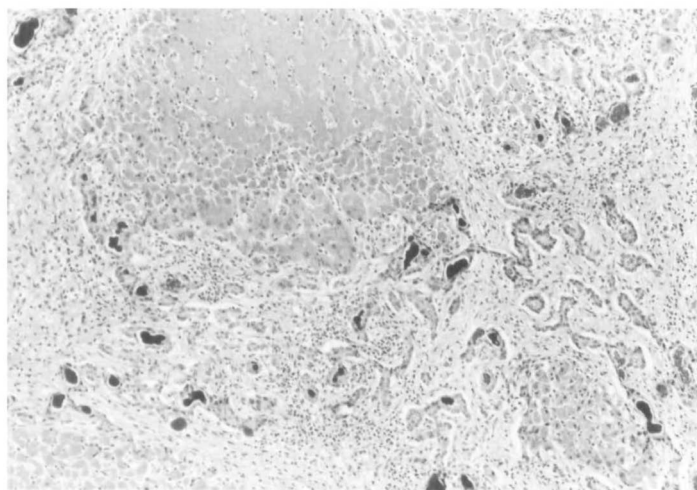


Figure 2—Microscopic findings of autopsied liver. There is extensive hepatic architectural derangement resulting from massive parenchymal necrosis and collapse. Prominent ductular proliferation with cholestasis is seen. (Hematoxylin and eosin stain, original magnification $\times 25$)

cases, but in the case presented here, the liver damage was progressive even after withdrawal of the agent, and ultimately developed into liver failure.

The patient had taken the appropriate daily dose (400 mg) of troglitazone. The plasma glucose level was well controlled and hypoglycemia did not occur. These observations suggest that the unfortunate outcome was not due to an overdose of troglitazone, and this is consistent with the fact that the plasma concentration of troglitazone measured 3 days after discontinuation of the drug was below the detection limit.

The results of the drug-induced lymphocyte stimulation test and the presence of eosinophilia suggest that hypersensitivity to troglitazone was the underlying cause of the fulminant hepatitis, although the patient did not have any skin rash or lymphadenopathy. The lymphocyte stimulation test is a generally accepted procedure for the detection of T cells whose activation by drugs that provoke cultured T lymphocytes to undergo a mitogenic response is suspected. Although the sensitivity of this in vitro test is low, several reports do show successful use of the test to detect hypersensitivity reactions in the liver (10–12). The belief is that the test often gives false-negative results, but only rarely false-positive results in cases of drug hypersensitivity, so that a positive result should establish the presence of drug hypersensitivity (11).

Any contributing role of glibenclamide in the development of hepatotoxicity, for example, in interactive hepatotoxicity of troglitazone and glibenclamide, would be

an important discovery. Indeed, according to the recent urgent report issued by Japanese Ministry of Welfare, three of four cases of troglitazone-induced fulminant hepatitis were treated concurrently with glibenclamide. Thus, investigations of drug interactions between troglitazone and glibenclamide are necessary to elucidate the mechanisms of the hepatotoxicity.

However, we believe that glibenclamide was not a major causative factor, even if it played any role in the development of hepatotoxicity in the present case, because its administration was discontinued 3 weeks before the development of clinical symp-

toms of liver dysfunction. Furthermore, the lymphocyte stimulation test clearly gave a negative result for glibenclamide and a positive result for troglitazone.

The autopsy findings were massive hepatic necrosis and severe cholestasis with monocytic, neutrophilic, and eosinophilic infiltration. These findings were also consistent with an allergic reaction. A marked increase in serum bilirubin appears to point to a devastating degree of hepatic necrosis and the resultant inability of the remaining hepatocytes to eliminate bilirubin.

Most types of drug-induced acute hepatitis, particularly in cases in which a drug causes liver injury by an allergic mechanism, respond promptly to withdrawal of the suspected agent. However, in the present case, the liver damage progressed, following a subacute course. According to the Japanese Ministry of Welfare, fulminant hepatitis developed also in another patient who received troglitazone, and took a subacute course even after the drug was withdrawn. More cases need to be investigated to determine whether the subacute course is a clinical feature of troglitazone-induced fulminant hepatitis.

Because the mortality rate of troglitazone-induced fulminant hepatitis is very high, orthotopic liver transplantation should be considered in such cases. However, liver transplantation has never been performed from a cadaver in Japan, a fact that raises various technical considerations about the feasibility of this therapy in this country. In cases of liver damage caused by

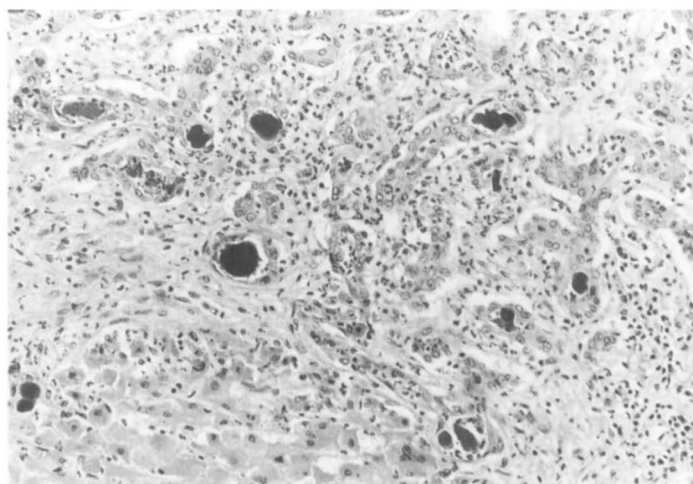


Figure 3—Hepatocellular coagulation necrosis and ductular proliferation in the periportal region. Neutrophil, eosinophil, and monocyte infiltration are observed among them. (Hematoxylin and eosin stain, original magnification $\times 100$)

troglitazone, the drug should be discontinued at an early stage, and careful immunosuppressive therapy may then be effective, since immunoallergic reaction to troglitazone appears to be one mechanism of liver damage in such cases.

In conclusion, the clinicopathological features of this case strongly suggest that troglitazone induces fulminant hepatitis through induction of hypersensitivity; consequently, monitoring of serum liver enzymes during troglitazone therapy is essential. Additional investigation of troglitazone metabolism is necessary to elucidate the mechanism(s) of hepatotoxicity of this agent.

References

1. Shibata H, Arai S, Kobayashi M, Izumi T, Maeda E, Sasahara K, Yamaguchi K, Morita A, Nishiwaki A: Phase I study of a new hypoglycemic agent CS-045 in healthy volunteers (in Japanese). *Rinsho Iyaku* 9:1519–1537, 1993
2. Iwamoto Y, Kuzuya T, Matsuda A, Awata T, Kumakura S, Inooka G, Shiraiishi I: Effect of new oral antidiabetic agent CS-045 on glucose tolerance and insulin secretion in patients with NIDDM. *Diabetes Care* 14:1083–1086, 1991
3. Suter SL, Nolan JJ, Wallace P, Gumbiner B, Olefsky JM: Metabolic effects of new oral hypoglycemic agent CS-045 in NIDDM subjects. *Diabetes Care* 15:193–203, 1992
4. Mimura K, Umeda F, Hiramatsu S, Taniguchi S, Ono Y, Nakashima N, Kobayashi K, Masakado M, Sako Y, Nawata H: Effects of a new oral hypoglycaemic agent (CS-045) on metabolic abnormalities and insulin resistance in type 2 diabetes. *Diabet Med* 11:685–691, 1994
5. Iwamoto Y, Kosaka K, Kuzuya T, Akanuma Y, Shigeta Y, Kaneko T: Effects of troglitazone: a new hypoglycemic agent in patients with NIDDM poorly controlled by diet therapy. *Diabetes Care* 19:151–156, 1996
6. Kosaka K, Kuzuya T, Akanuma Y, Shigeta Y, Kaneko T: Clinical evaluation of a new oral hypoglycemic drug CS-045 in patients with non-insulin-dependent diabetes mellitus poorly controlled by diet alone: a double-blind, placebo-controlled study (in Japanese). *Rinsho Iyaku* 9:61–93, 1993
7. Akanuma Y, Kosaka K, Kuzuya T, Shigeta Y, Kaneko T: Long-term study of a new oral hypoglycemic agent CS-045 in patients with non-insulin dependent diabetes mellitus (in Japanese). *Rinsho Iyaku* 9:127–149, 1993
8. Watkins P, Whitcomb R: Hepatic dysfunction associated with troglitazone. *N Engl J Med* 338:916–917, 1997
9. Lee WM: Drug-induced hepatotoxicity. *N Engl J Med* 333:1118–1127, 1995
10. Paronetto F, Popper H: Lymphocyte stimulation induced by halothane in patients with hepatitis following exposure to halothane. *N Engl J Med* 283:277–280, 1970
11. Houwerzijl J, DeGast G, Nater J, Esselink M, Nieweg H: Lymphocyte stimulation tests and patch tests in carbamazepine hypersensitivity. *Clin Exp Immunol* 29:272–277, 1977
12. Maria V, Pinto L, Victorino R: Lymphocyte reactivity to ex-vivo drug antigens in drug-induced hepatitis. *J Hepatol* 21:151–158, 1994