

Microscopic (R1) and macroscopic (R2) residual disease in patients with resected non-small cell lung cancer

H.S. Hofmann^{a,*}, C. Taege^b, C. Lautenschläger^c, H. Neef^a, R.E. Silber^a

^aDepartment of Cardio-Thoracic Surgery, Martin Luther University, E.-Grube Straße 40, 06097 Halle, Germany

^bInstitute of Pathology, Martin Luther University, Halle-Wittenberg, Halle, Germany

^cInstitute of Medical Statistics, Martin Luther University, Halle-Wittenberg, Halle, Germany

Received 20 August 2001; received in revised form 3 January 2002; accepted 4 January 2002

Abstract

Objectives: This retrospective study evaluates the probability of survival in patients who had undergone resection for non-small cell lung cancer (NSCLC) and in whom residual disease at the resection margins was found. **Methods:** During a period of 6 years, 596 patients with NSCLC were operated upon with curative intention. Residual disease at the resection margin was divided into microscopic (R1) and macroscopic (R2). **Results:** Twenty-six patients (4.4%) showed R1 and 12 (2%) R2 residual disease. An extrabronchial (thoracic wall, vessels) R1 situation was found in five patients and a bronchial R1 infiltration in 21 cases. The bronchial resection margin was subject to peribronchial infiltration in most cases (16/21). A total of 17/21 (65%) patients with bronchial infiltration had N2 disease. Thirty day lethality was 3.8% in the R1 group. Fifteen patients had postoperative irradiation. The 5-year survival rate for patients with R1 resection was 14%. The differences in survival between patients with extrabronchial vs. bronchial infiltration and N0/N1 vs. N2 were significant using univariate analysis. Adjuvant radiation did not result (especially in N2 disease) in a survival benefit. Among 12 patients with macroscopic residual disease (R2), 3/12 (25%) died within the first 30 days after the operation, and none of the R2 patients survived the first year after the operation. **Conclusions:** Patients with an R1 situation have a survival rate of 14% comparable to curative resected patients (RO) in stage III. Adjuvant radiation had no clear effect on survival. Patients with macroscopic tumor (R2) should receive palliative treatment after the operation depending on their condition. © 2002 Elsevier Science B.V. All rights reserved.

Keywords: Non-small cell lung cancer; Residual disease; Survival

1. Introduction

Surgical resection is the accepted therapy for non-small cell lung cancer (NSCLC) up to stage IIIA. The operation's goal is a complete tumor resection with tumor-free resection margins and radical lymph node dissection. Residual tumor at the resection margin may determine the postoperative course with regard to complications, e.g. bronchus stump insufficiency and locoregional relapse, but also may generally influence the patient's life prognosis negatively. Both functional and technical limits do not allow a complete resection of the tumor in some cases (R2). In other patients a tumor infiltration at the resection margin is only proven during pathological analysis of the removed specimen (R1). A further extensive resection is not possible for most of the patients because of functional reasons. Questions remaining

are the prognosis of residual microscopic and macroscopic tumors and how they should be treated. Although there has been no proof so far concerning an advantage of adjuvant radiation, it is carried out in such cases with the goal of eliminating local remains of tumor.

In the present retrospective study we examined our patients with microscopic (R1) and macroscopic (R2) residual tumors after resecting NSCLC with regard to their postoperative survival rate and possible prognostic factors. Moreover, we evaluated if an adjuvant radiotherapy may result in a survival advantage in these patients.

2. Materials and methods

A total of 596 patients with NSCLC were operated on in our department with curative intention between 1 January 1992 and 31 December 1997. Apart from resection of the tumor, an extended lymph node dissection was performed in all cases. Frozen-section of the resection margin was carried out during the operation. In cases of microscopic and/or

* Corresponding author. Tel.: +49-345-557-2719; fax: +49-345-557-2782.

E-mail address: stefan.hofmann@medizin.uni-halle.de (H.S. Hofmann).

Table 1
Analysis of localization of the residual tumor (R1 group) and the risk of lymph node infiltration ($n = 25$)

R1 group	Localization	N0	N1	N2
Bronchial	Mucosal ($n = 0$)	–	–	–
	Submucosal ($n = 6$)	1	2	3
	Peribronchial ($n = 15$)	0	2	13
Extrabronchial	Vessel ($n = 2$)	1	0	1
	Chest wall ($n = 3$)	2	1	0

macroscopic tumor infiltration of the resection margins we tried to establish a complete tumor-free situation (R0 situation) by further resection, depending on technical and functional possibilities. After the operation, a microscopic residual tumor remained in 26 patients (R1 group) and a macroscopic residual tumor in 12 patients (R2 group). R2 classification [1] in our study was considered as macroscopic locoregional residual tumor at the resection margins, but not distant residual tumor such as unresected metastases. Diagnostic thoracotomies were excluded.

An extrabronchial (vessels, thoracic wall) and a bronchial (resection margin) residual tumor were distinguished, the latter being classified as mucosal, submucosal or peribronchial tumor infiltration.

Fifteen patients in the R1 group received radiotherapy at the infiltrated resection margins. In cases of mediastinal disease (N2) radiation was administered additionally to the mediastinum. The total dose was 50–60 Gy, with the aim of preventing local recurrence. In one case the radiation was stopped after 20 Gy because of deterioration of the patient's condition. Ten patients refused adjuvant irradiation.

In R2 cases with a good condition and macroscopic small amounts of tumor tissue left after resection ($n = 3$) it seemed to be justified to perform radiation of that region. The remaining six R2 patients suffered from deterioration of their condition ($n = 2$) or refused radiation ($n = 4$).

All patients were regularly examined in the outpatient services. An univariate analysis of their survival probability was made according to the Kaplan and Meier method. Multivariate Cox analysis of possible prognosis factors was judged to give no valid results because of small numbers of patients in some groups. Further statistical analysis was performed by the log-rank test.

3. Results

Microscopic residual tumor (R1) was found in 4.4% (26/596) of the resected cases, and a macroscopic residual tumor (R2) was found in 2% (12/596).

3.1. R1 cases

Tissue diagnosis was squamous cell carcinoma in 18 patients, adenocarcinoma in three, large cell carcinoma in

three and adenosquamous cell carcinoma in two patients. In group R1 pneumonectomy was the most frequent operation ($n = 13$), with lobectomy in 12 cases and bilobectomy in one case. The tumor stages were as follows: stage I, one patient; stage II, one patient; stage IIIA, 20 patients; stage IIIB, three patients; and stage IV, one patient. Among the R1 patients, 65% ($n = 17$) had mediastinal lymph node metastases (N2 status), 19% ($n = 5$) had N1 lymph node infiltration and only four patients (15%) had no detectable lymph node metastases (N0). Pathological evaluation showed extra-bronchial microscopic tumors in 19% of cases ($n = 5$) and bronchial microscopic tumors in 81% ($n = 21$) (Table 1). A peribronchial infiltration pattern was the most frequently found ($n = 15$) at the bronchus resection margin. In six patients the infiltration was submucosal. There was no case with mucosal infiltration only. Out of the patients with a peribronchial R1 situation 87% (13/15) had mediastinal lymph node metastases (N2). Only half of the patients with submucosal residual tumor (3/6) were in an N2 situation (Table 1).

The causes of microscopic residual tumor at the bronchus stump were functional inoperability in two patients and technical inoperability in eight patients. There was a discrepancy between the result of the intraoperative frozen-section analysis and final histology in 11 patients (52%). Incorrect negative frozen-section results were most frequently (9/15) found in patients with peribronchial infiltration.

The 30-day lethality among patients with an R1 resection was 3.8% ($n = 1$). During outpatient observation three patients with locoregional relapses and four patients with distant metastases were detected. The 5-year survival rate of patients with an R1 status is 14% (Fig. 1). The univariate analysis of possible risk factors (Table 2) indicated an important survival difference depending on the R1 resection's site and N-status. Patients with an extrabronchial R1 situation had a median survival of 39 months vs. 6

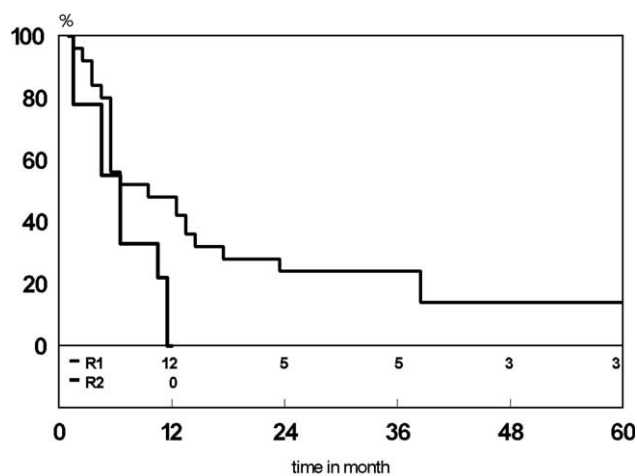


Fig. 1. Survival of patients with microscopic (R1) and macroscopic (R2) residual disease.

Table 2
Prognostic factors of patients with R1 resection ($n = 25$)

Prognostic factors		<i>n</i>	Log-rank
Age (years)	<60	11	0.61
	≥60	14	
Localization	Extrabronchial	4	0.045
	Bronchial	21	
N-status	N0/N1	8	0.0009
	N2	17	
Adjuvant radiotherapy	Yes	15	0.086
	No	10	

months for patients with a bronchial R1 situation ($P = 0.045$). Patients with N0/N1 lymph node status survived longer (median survival 39 months) than patients with N2 disease (median survival 6 months; $P = 0.0009$). The patients' age seems to have no influence on the survival rate. The subgroups were too small to analyze the influence of histology and tumor stage on the outcome. Patients with postoperative irradiation ($n = 15$) had a median survival of 14 months (Fig. 2), and those without adjuvant radiation ($n = 10$) had a median survival of 6 months ($P = 0.086$). For N2 patients with irradiation the median survival time was 6 months, the same as in the irradiation untreated group (Fig. 2).

3.2. R2 cases

The patients with a macroscopic residual tumor (R2) were all in stage III or IV (stage IIIA, $n = 4$; stage IIIB, $n = 6$; stage IV, $n = 2$). Two-thirds of the operations were pneumonectomies and only one-third were lobectomies. In all cases further resection was not possible for technical reasons. Histologically there were squamous cell carcinoma in seven patients, adenocarcinoma in four patients and large cell carcinoma in one patient. The 30-day lethality in the R2 group was at 25% (3/12); none of the remaining patients survived 12 months after the operation (Fig. 1). Also the three patients who had adjuvant irradiation died during the first year.

4. Discussion

Radical surgical resection offers the best survival chances for patients with a NSCLC up to stage IIIA. In spite of improvements in preoperative diagnostics to evaluate tumor spreading and pulmonary function, in some cases total resection of the tumor can not be realized. Depending on the tumor stage the proportion of operations with residual tumor left behind is between 1.1 and 17% [2–7]. For incomplete resections with a macroscopic residual tumor it is reported to be up to 20% [8]. Anatomic and functional limitations are frequently mentioned as possible causes of incomplete resections (40% in our study). A further cause of R1 resection was that the tumor infiltration at the resection margin was not detected during operation because the tumor

was macroscopically removed and an operative frozen-section analysis was renounced [2,7]. Nowadays frozen-section analysis of the resection margin is accepted as obligatory. However, it was found that there was a discrepancy between the frozen-section result during operation and the later final histological result, mostly in cases of peribronchial infiltration [2]. In the present study nine out of 15 (60%) peribronchial tumor infiltrations were not detected by the frozen-section analysis during operation. Causes of this may be of a technical nature when preparing the tissue (overlapping, tearing) and due to misvaluations of tumor spreading with preexisting structures (bronchus glands, inflammation infiltrations).

Facts about a survival prognosis with patients having R1 resections vary largely in the literature [9–11], but they also depend substantially on the site of the R1 resection [9,10], apart from the tumor stage. The 5-year survival rate of 14% achieved in this study is in the expected range, as the proportion of patients with at least a stage IIIA was around 90% of the whole group. Moreover, all patients with a bronchial R1 situation had submucosal and/or peribronchial tumor infiltration. According to Soorae and Stevenson [9] these patients have the worst survival prognosis (a 3-year survival rate of 0%).

Patients with an extrabronchial residual tumor situation have a better survival prognosis (median survival time: 39 months), because their R1 situation is the consequence of continuous tumor growth into the chest wall or the hilum vessels. Patients with bronchial residual tumors were subject to accompanying peribronchial infiltrations linked to mediastinal lymph node metastases in 16 out of 21 cases which worsens the prognosis additionally. In a study by Massard et al. [12] the prognosis of peribronchial infiltrations was similar to N2 disease.

The main cause of death in resected NSCLC is generalized metastasis. Therefore, adjuvant therapies (radiation

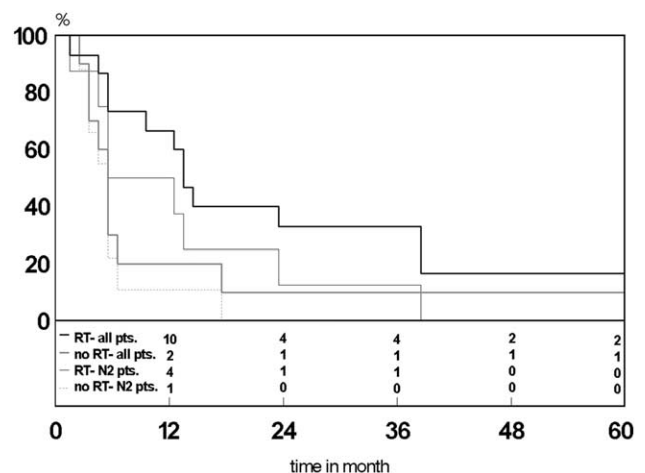


Fig. 2. Survival of all patients and N2 patients with R1 resection in correlation with adjuvant radiation vs. non-radiation (for all patients, $P = 0.086$; for N2 disease patients $P = 0.13$).

and/or chemotherapy) have been added to surgical resection.

Our rationale for adjuvant irradiation of R1 patients was as follows: stage I and II patients with R0 had better survival than R1 patients [2]. Further, patients with N0 and N1 have more local than distant recurrences [13,14], and in particular patients with tumor infiltration at the resection margin have significantly more recurrences (all local) than patients with complete resection [5]. The risk of further infiltration of mediastinal lymphatic pathways is very high in cases with a peribronchial R1 situation (13 of 15 patients with peribronchial infiltration in our study had N2 disease). Although the role of postoperative radiation in the treatment of N2 tumors is not yet clear concerning survival [15], it is still performed in patients with N2 disease, based on the finding that local recurrence may be decreased [16]. According to this policy 15 of 25 patients received irradiation. However, the difference in median survival between radiated and non-radiated patients was moderate (14 vs. 6 months).

Several authors also did not see survival advantages [7,17] nor a lower incidence of local recurrence [5]. Moreover, Massard et al. [12] suggested an adverse impact of radiotherapy on survival in an R1 situation (six of ten unrelated deaths were interpreted as respiratory complications of radiation).

In R1 cases with N2 infiltration there was no difference in median survival (6 vs. 6 months) between the radiated and non-radiated groups. Patients with N2 disease often have distant metastases before local recurrence [13] which obviates the benefits of high extensive resection. Liewald et al. [2] proved that median survival times of stage III patients with microscopic infiltration of the resection margins and without such infiltration hardly differed from each other (9 vs. 11.6 months). Undetected distant metastases exist in a number of these N2 patients at the time of external beam radiation, not being accessible by adjuvant radiotherapy. This may be the main reason for detecting no difference in median survival for N2 disease patients with or without irradiation.

Adjuvant chemotherapy is questionable. A meta-analysis of 52 randomized trials of adjuvant chemotherapy for completely resected N2 NSCLC suggested a small advantage of 3% within 2 years of cisplatin-based chemotherapy regimes given in the adjuvant setting [15]. In a single study of patients with microscopic NSCLC and N2 disease 40% were disease-free at 45 months after adjuvant chemotherapy and radiotherapy [18]. However, the number of cases was very small ($n = 10$).

Patients with a macroscopic residual tumor after resection have both a very high perioperative risk (30-day lethality: 25%) and a very low survival prognosis (1-year survival rate: 0%). As those very sick patients often do not benefit from tumor resection in the sense of a tumor mass reduction, an exact evaluation of tumor spreading during operation should be done. Then the operation should eventually be finished as diagnostic thoracotomy. In three cases adjuvant

radiotherapy was not proven to have any survival advantage. A decision on adjuvant therapy must therefore be made individually.

The incidence of residual tumors at the resection margin after excision of an NSCLC is low due to improved preoperative diagnostics and frozen-section analysis during operation. Microscopic tumor infiltration (especially peribronchial) is frequently linked to mediastinal lymph node metastases, the latter determining the prognosis. In R1 cases with an N0/N1 situation adjuvant radiation should be given to prevent local recurrence. Because of the systemic character of N2 disease an advantage of irradiation is doubtful. The benefit of adjuvant chemotherapy must be evaluated in further studies.

References

- [1] Hermanek P, Wittekind C. The pathologist and the residual tumor (R) classification. *Pathol Res Pract* 1994;190(2):115–123.
- [2] Liewald F, Hatz RA, Dienemann H, Sunder-Plassmann L. Importance of microscopic residual disease at the bronchial margin after resection for non-small-cell carcinoma of the lung. *J Thorac Cardiovasc Surg* 1992;104(2):408–412.
- [3] Kayser K, Anyanwu E, Bauer HG, Vogt-Moykopf I. Tumor presence at resection boundaries and lymph-node metastasis in bronchial carcinoma patients. *Thorac Cardiovasc Surg* 1993;41(5):308–311.
- [4] Dienemann H, Trainer C, Hoffmann H, Bulzebruck H, Muley T, Kayser K, Vogt-Moykopf I. Incomplete resections in bronchial carcinoma: morbidity and prognosis. *Chirurg* 1997;68(10):1014–1019.
- [5] Snijder RJ, Brutel de la Riviere A, Elbers HJ, van den Bosch JM. Survival in resected stage I lung cancer with residual tumor at the bronchial resection margin. *Ann Thorac Surg* 1998;65(1):212–216.
- [6] Wertzel H, Siebert H, Lange W, Swoboda L, Graf E, Hasse J. Results after surgery in stage-I bronchogenic carcinoma. *Thorac Cardiovasc Surg* 1998;46(6):365–369.
- [7] Ghiribelli C, Voltolini L, Paladini P, Luzzi L, Di Bisceglie M, Gotti G. Treatment and survival after lung resection for non-small cell lung cancer in patients with microscopic residual disease at the bronchial stump. *Eur J Cardiothorac Surg* 1999;16(5):555–559.
- [8] Spaggiari L, Regnard JF, Magdeleinat P, Jauffret B, Puyo P, Levasseur P. Extended resections for bronchogenic carcinoma invading the superior vena cava system. *Ann Thorac Surg* 2000;69(1):233–236.
- [9] Soorae AS, Stevenson HM. Survival with residual tumor on the bronchial margin after resection for bronchogenic carcinoma. *J Thorac Cardiovasc Surg* 1979;78(2):175–180.
- [10] Kimura H, Yamaguchi Y. Survival of noncuratively resected lung cancer. *Lung Cancer* 1994;11(3–4):229–242.
- [11] Downey RJ, Martini N, Rusch VW, Bains MS, Korst RJ, Ginsberg RJ. Extent of chest wall invasion and survival in patients with lung cancer. *Ann Thorac Surg* 1999;68(1):188–193.
- [12] Massard G, Doddoli C, Gasser B, Ducrocq X, Kessler R, Schumacher C, Jung GM, Wihlm JM. Prognostic implications of a positive bronchial resection margin. *Eur J Cardiothorac Surg* 2000;17(5):557–565.
- [13] Iacone C, DeMeester TR, Albertucci M, Little AG, Golomb HM. Local recurrence of resectable non-oat cell carcinoma of the lung. A warning against conservative treatment for N0 and N1 disease. *Cancer* 1986;57(3):471–476.
- [14] The Ludwig Lung Cancer Study Group. Patterns of failure in patients with resected stage I and II non-small cell carcinoma of the lung. *Ann Surg* 1987;205(1):67–71.
- [15] Non-Small Cell Lung Cancer Collaborative Group. Chemotherapy in non-small cell lung cancer: a meta-analysis using updated data on

individual patients from 52 randomised clinical trials. *Br Med J* 1995;311(7010):899–909.

- [16] Bardet E, Moro-Sibilot D, Le Chevalier T, Massard G, Douillard JY, Theobald S, Astoul P, Baldeyrou P, Bazelly B, Brechot J, Breton JL, Grivaux P, Jacoulet P, Khalil A, Lemarie E, Martinet Y, Milleron B, Paesmans M, Pujol JL, Quoix AE, Ranfaing E, Riviere A, Sancho-Garnier H, Souquet PJ, Spaeth D, Steebner-Delbarre A, Thiberville L, Touboul E, Vaylet F, Vergnon JM, Westeel V, Depierre A, Lagrange JL. Standards, options and recommendations for the management of locally advanced non small cell lung carcinoma. *Bull Cancer* 2001;88(4):369–387.
- [17] Smolle-Juettner FM, Mayer R, Pinter H, Stuecklschweiger G, Kapp KS, Gabor S, Ratzenhofer B, Hackl A, Friehs G. 'Adjuvant' external radiation of the mediastinum in radically resected non-small cell lung cancer. *Eur J Cardiothorac Surg* 1996;10(11):947–950.
- [18] Wright SE, Sicola VR, Martinez H, Thompson E, Pratt D. Adjuvant chemotherapy and radiation therapy for elimination of residual microscopic non-small cell lung cancer. *Int J Oncol* 1999;14(2):347–351.