

Aberrant Crypt Foci in the Adenoma Prevention with Celecoxib Trial

Nancy L. Cho,¹ Mark Redston,² Ann G. Zauber,⁵ Adelaide M. Carothers,¹ Jason Hornick,² Andrew Wilton,⁷ Stephen Sontag,⁸ Norman Nishioka,⁴ Francis M. Giardiello,⁹ John R. Saltzman,³ Chris Gostout,¹⁰ Craig J. Eagle,⁶ Ernest T. Hawk¹¹ and Monica M. Bertagnolli¹

Abstract

Aberrant crypt foci (ACF) are the earliest visible neoplastic lesions in the colorectum. The natural history of these lesions and their role in the adenoma-carcinoma sequence are unknown. We studied ACF in a subset of patients randomized to placebo ($n = 17$), celecoxib (200 mg twice daily; $n = 15$), or celecoxib (400 mg twice daily; $n = 13$) in the Adenoma Prevention with Celecoxib (APC) trial. Magnification chromoendoscopy was done to identify, count, and biopsy ACF within the rectum at baseline and after 8 to 12 months of treatment. A total of 655 ACF were identified in 45 patients. We examined 70 of these ACF histologically, and all 70 were nondysplastic. Cohort characteristics and APC trial treatment results for substudy patients were similar to those of the overall APC trial. There was no significant modulation of ACF by celecoxib (versus placebo; $P = 0.77$). Immunohistochemical comparison of ACF with adjacent normal mucosa showed that ACF had an increased proliferative index as determined by Ki-67 ($P < 0.0001$), but lacked other features of neoplasia such as increased cyclooxygenase-2 expression and microvessel density, nuclear localization of β -catenin, or decreased expression of the tumor suppressors SMAD4, Estrogen Receptor α , or MGMT. Only baseline SMAD4 expression in ACF correlated with posttreatment adenoma recurrence (independent of treatment arm; $P = 0.01$). The presence or number of nondysplastic ACF did not correlate with a higher risk of synchronous advanced or recurrent adenomas. Our overall results indicated that nondysplastic ACF were not accurate surrogate endpoint biomarkers of recurrent colorectal adenomas in the APC trial.

Colorectal cancer is a major cause of cancer mortality, with ~60,000 deaths per year in the United States alone (1). Colorectal cancer usually takes years to decades to progress from the earliest initiated neoplastic cells to invasive malignancy, and fortunately this process can be interrupted by surgical or endoscopic excision at the relatively early stage of adenomas. Colorectal adenomas can be prevented or regressed by nonsteroidal anti-inflammatory drugs (2–5). Unfortunately, progress in clinical colorectal cancer prevention research proceeds slowly because studies using sporadic adenoma formation as an efficacy endpoint require hundreds of patients and up to a 3-year observation period. Evaluation of potential col-

orectal cancer chemoprevention agents would be facilitated by new surrogate endpoint biomarkers that correlate with clinical response, are modulated by chemopreventive agents within a short period of time, and are relatively simple to measure.

ACF are alterations in the colonic mucosa characterized by clusters of crypts that are larger than normal, have increased pericryptal space, contain a thicker than normal layer of epithelial cells, and show oval or irregularly shaped rather than circular crypt openings (6). ACF are visualized by magnification chromoendoscopy, a procedure that involves staining the colorectal mucosa with a dye, followed by examination under 40 \times power using a specialized endoscope. ACF were first identified in rodent carcinogen-induced tumor models, and are found in humans at risk for colorectal cancer, with the greatest ACF density in the rectosigmoid (6–8).

The relationship of ACF to the adenoma-carcinoma sequence is a matter of debate. In rodents, ACF frequency is modulated by many of the same agents that prevent colorectal adenomas from progressing to more advanced adenomas or carcinomas (9–11). Although several human studies report a strong correlation between ACF frequency and the presence of synchronous adenomas or carcinomas (7, 8), few of these studies examined treatment-associated modulation of ACF. One nonrandomized observational human study found 47% fewer ACF associated with regular aspirin use (versus minimal use) before surgery for colorectal cancer (12). In a small

Authors' Affiliations: Departments of ¹Surgery, ²Pathology, and ³Medicine, Brigham and Women's Hospital; ⁴Department of Medicine, Massachusetts General Hospital, Boston Massachusetts; ⁵Department of Epidemiology and Biostatistics, Memorial Sloan-Kettering Cancer Center; ⁶Pfizer, Inc., New York, New York; ⁷Institute for Clinical Evaluative Sciences, Toronto, Ontario, Canada; ⁸Hines Veteran's Administration Medical Center, Hines, Illinois; ⁹Department of Medicine, The Johns Hopkins School of Medicine, Baltimore, Maryland; ¹⁰Department of Medicine, The Mayo Clinic, Rochester, Minnesota; and ¹¹National Cancer Institute, Bethesda, Maryland
Received 12/17/2007; revised 02/26/2008; accepted 02/26/2008.

Requests for reprints: Monica M. Bertagnolli, Department of Surgery, Brigham and Women's Hospital, 75 Francis Street, Boston, MA 02115. Phone: 617-732-8910; Fax: 617-582-6177; E-mail: mbertagnolli@partners.org.

©2008 American Association for Cancer Research.
doi:10.1158/1940-6207.CAPR-07-0011

prospective study involving ACF patients with variable colorectal cancer risks, a significant decrease in rectal ACF numbers occurred among patients receiving sulindac for 8 to 12 months ($n = 11$) versus control patients ($n = 9$; ref. 8). Coupled with the strong correlation between ACF frequency and synchronous adenomas and carcinomas, these treatment studies led to the hypothesis that modulation of ACF frequency indicates response to chemopreventive agents.

We conducted a prospective, randomized trial of the non-steroidal anti-inflammatory drug, celecoxib, for prevention of sporadic colorectal adenomas (5). In this study, known as the Adenoma Prevention with Celecoxib (APC) trial, a total of 2,035 patients with a history of colorectal adenomas were randomized to receive either placebo, celecoxib 200 mg twice daily, or celecoxib 400 mg twice daily. Celecoxib at either dose significantly reduced the incidence of adenomas detected during a 3-year surveillance interval. A subset of patients on the APC trial also underwent magnification chromoendoscopy for a prespecified substudy involving the identification and biopsy of rectal ACF. We evaluated the frequency and histology of rectal ACF in these APC trial participants to determine whether treatment with celecoxib modulated the natural history of ACF and whether this modulation correlated with the development of colorectal adenomas. We also examined molecular markers associated with adenoma formation to determine their potential associations with ACF and celecoxib effects.

Materials and Methods

Study population

A complete description of the APC trial patient cohort and treatment protocol has previously been published (5). This ACF substudy was a prespecified secondary objective of the APC trial conducted at five clinical sites (of a total of 91 APC trial sites), which had the appropriate equipment and experience to conduct the magnification chromoendoscopies required for ACF evaluation. All APC patients enrolling at these five sites were asked to participate in the ACF substudy. Patient eligibility included the following criteria: a complete colonoscopy to the cecum with removal of all polyps within 3 mo of APC trial enrollment; at least one histologically confirmed adenoma removed at baseline; a high risk of recurrent colorectal adenomas based on a baseline history of either multiple adenomas or removal of a single adenoma >5 mm in diameter; and aspirin use at a dose not exceeding 81 mg/d or 325 mg every other day. Patient exclusion included the following criteria: a history of familial adenomatous polyposis, hereditary nonpolyposis colorectal cancer, inflammatory bowel disease, renal or hepatic disorder, significant bleeding disorder, or invasive cancer; prior large-bowel resection excepting appendectomy; recent treatment for gastrointestinal ulcer; and recent use of high-dose aspirin (exceeding 81 mg/d or 325 mg every other day) or a corticosteroid. Each participating site received human subjects committee approval of the substudy protocol, and all patients provided written consent before study enrollment. An independent data and safety monitoring board reviewed safety data monthly and efficacy data yearly.

Treatment and endpoint assessments

Before beginning APC trial study treatment and at least 1 wk after the colonoscopy leading to enrollment in the APC trial, each substudy patient received a fleet enema prep followed by an examination of the rectosigmoid by magnification chromoendoscopy. Five investigators with prior experience with the magnification chromoendoscopy technique conducted these examinations. At the beginning of the exam, the entire rectum was visualized endoscopically to confirm that no

adenomas or other polyps remained. The endoscopist defined the examination area as the entire rectum up to the rectosigmoid junction, requiring retroflexion of the endoscope to visualize the distal rectum. After the initial visual screen, 0.25% methylene blue (10 mL) was instilled in the rectum and allowed to coat the mucosa. Next, 10 visual fields were chosen at random and examined under $\times 40$ magnification. All ACF within these 10 fields were counted. ACF were identified according to the features described by McLellan and Bird (6): larger than normal clusters of crypts, with increased pericryptal space, a thicker than normal layer of epithelial cells, and oval or irregularly shaped rather than circular crypt openings. These lesions were also recognized as being slightly elevated from the plane of the normal mucosa. A photo of a representative ACF identified at baseline is shown in Fig. 1. Patients who were not regular users of low-dose aspirin also underwent biopsy of ACF and adjacent normal-appearing rectal mucosa. After an initial examination of the rectum, up to five ACF and five sites of normal mucosa were biopsied using a 2-mm endoscopic biopsy forceps. Two samples of each specimen type were placed in formalin and then embedded in paraffin blocks; three samples of each specimen type were frozen immediately in liquid nitrogen. The patients were then started on their study arm treatment, as required by the APC trial protocol. After 8 to 12 mo of treatment, the magnification chromoendoscopy procedure was repeated in a manner identical to that at baseline. In patients not using aspirin, pre- and post-treatment biopsies were obtained in 13 of 17 patients treated with placebo, 12 of 15 patients treated with celecoxib 200 mg twice daily, and 10 of 13 patients treated with celecoxib 400 mg twice

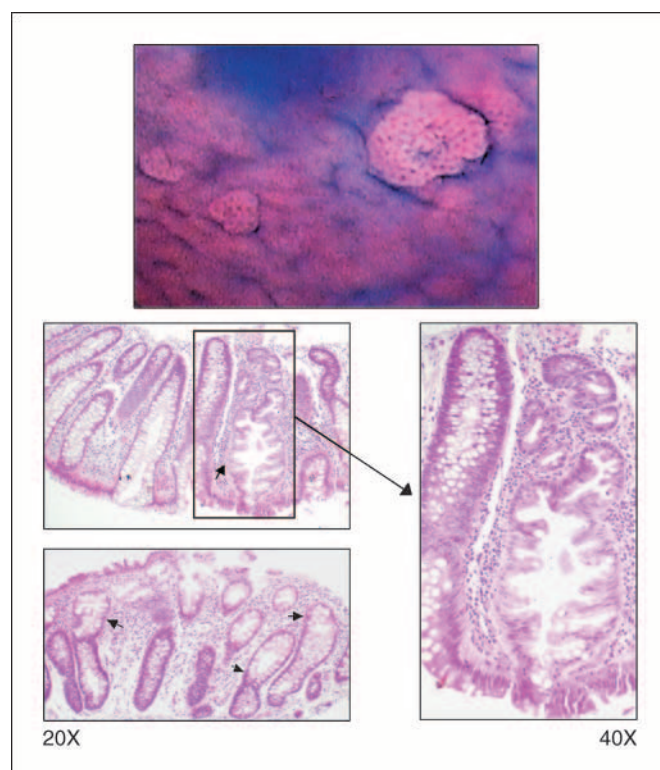
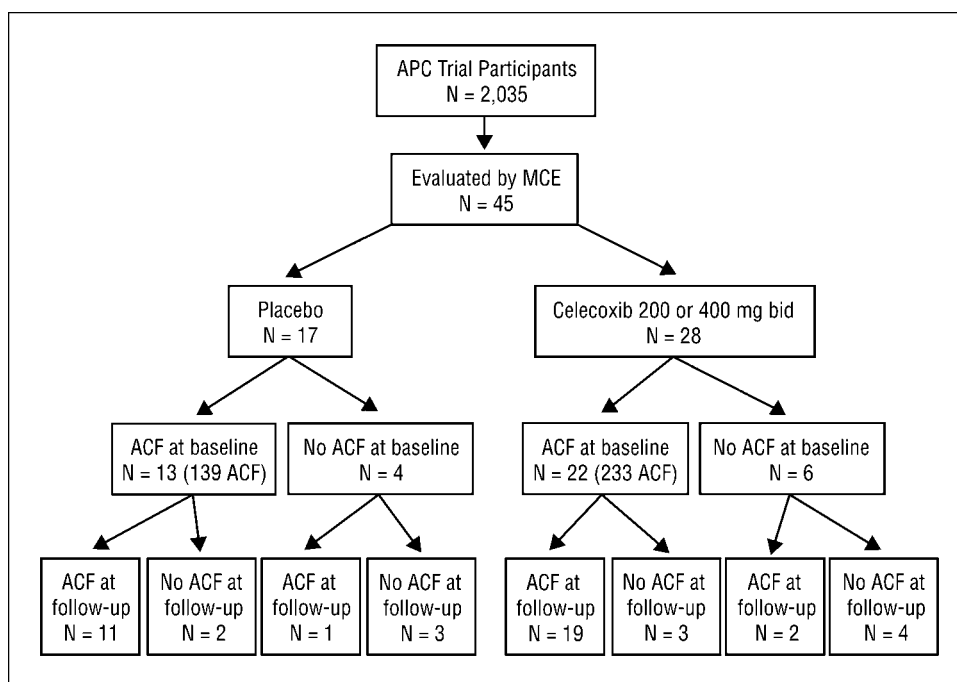


Fig. 1. Top, appearance of ACF shown by magnification chromoendoscopy. ACF are alterations in the colonic mucosa characterized by clusters of crypts that are larger than normal, have increased pericryptal space, contain a thicker than normal layer of epithelial cells, and show oval or irregularly shaped rather than circular crypt openings. These lesions are often in a plane different than that of the surrounding mucosa (either raised or depressed). Image obtained by $\times 40$ magnification endoscopy after treatment of the mucosa with 0.25% methylene blue. Bottom, H&E stains of two hyperplastic ACF showing enlarged crypts and serrated lumen openings.

Fig. 2. Flowchart of patients treated on the APC trial ACF substudy.



daily. To compare the histologic characteristics of dysplastic and nondysplastic ACF, sections of colon containing dysplastic ACF were obtained from archived tissues from patients with familial adenomatous polyposis who underwent prophylactic colectomy.

Histologic examination of biopsies

Seventy formalin-fixed ACF biopsies from 35 non-aspirin-using participants and specimens from 5 patients with familial adenomatous polyposis were reviewed. The paraffin-embedded specimens were serially cut perpendicular to the lumen into 4- μ m sections, mounted onto siliconized slides, and stained with H&E. The histology of each ACF was characterized by a single study pathologist (M.R.), who was blinded to sample timing (baseline versus posttreatment) and treatment assignment. Each ACF was designated as dysplastic, hyperplastic, or nondysplastic/nonhyperplastic, based on standard histologic criteria (6). ACF were classified as hyperplastic if they lacked features of dysplasia, were elongated, and displayed serrated crypt profiles and/or cellular tufting (Fig. 1). Criteria for dysplastic ACF included one or more abnormal cytologic characteristics, such as nuclear enlargement, stratification, pleomorphism, hyperchromasia, and increased nuclear-to-cytoplasmic ratios extending to the surface mucosa, with or without architectural distortion (6). ACF that could not be characterized as either dysplastic or hyperplastic were designated nondysplastic/nonhyperplastic.

Immunohistochemical assays and scoring

ACF and adjacent normal mucosa specimens obtained at baseline and posttreatment endoscopies were examined by immunohistochemistry. An antibody directed against β -catenin (clone 14) was purchased from BD Biosciences. Antibodies recognizing CD31 (clone JC/70A) and Ki-67 (clone MIB-1) and Envision System reagents were purchased from DAKO. The cyclooxygenase-2 (COX-2) monoclonal antibody was obtained from Cayman Chemical Company. Antibodies to SMAD4 (clone B-8) and estrogen receptor α (ER α ; HC-20) were from Santa Cruz Biotech. *O*⁶-Methylguanine-DNA methyltransferase (MGMT) antibody (clone MT3.1) was from Lab Vision Corp. The avidin/biotin blocking kit, normal serum, Vectastain Elite ABC Kit, and biotinylated horse anti-mouse antibody were purchased from Vector Laboratories. Antigen retrieval was done by heating slides immersed in 10 mmol/L citrate buffer (pH 6.0) in a pressure cooker for 2 min.

Endogenous peroxidases were quenched in a methanol H₂O₂ solution. Sections were then blocked in PBS containing 5% serum and avidin blocking reagent for 1 h at room temperature. All reactions with primary antibody were done at 4°C overnight. Antibodies were diluted in PBS containing 1% serum and biotin blocking reagent at ratios of 1:250 for β -catenin, 1:500 for COX-2, 1:150 for CD31, 1:150 for Ki-67, 1:200 for SMAD4, 1:500 for ER α , and 1:200 for MGMT. Slides were washed and then reacted with biotinylated antimouse secondary antibody for 30 min at room temperature. Staining was optimized with Vectastain Elite ABC reagents for 15 to 30 min and was detected with 3,3'-diaminobenzidine chromogen. Sections were counterstained with hematoxylin.

Images were obtained with an Olympus BX40 microscope. Each immunohistochemical marker was scored by a single study pathologist (M.R.), who was blinded to treatment and biopsy time point. Scoring criteria were standard for each marker. For COX-2, epithelium and stromal cells were scored separately to quantify both staining area and intensity. Staining area was scored from 0 to 3, where 0, no stain; 1, 1% to 30% stain; 2, 31% to 70% stain; and 3, 71% to 100% stain. A similar scoring system of 0 to 3 was assigned to intensity of staining, where 0, no staining; 1, weak staining; 2, moderate staining; and 3, strong staining. Sections of an adenoma were stained in parallel with ACF and served as a reference positive control to standardize scoring. Final scores equaled (stroma area \times stroma intensity) + (epithelium area \times epithelium intensity). Expression of β -catenin was evaluated by comparing the staining pattern in ACF crypt cells with that in normal mucosa cells, with particular attention paid to any difference in the nuclear expression of β -catenin between ACF and normal. Microvessel density was evaluated following CD31 immunostain of normal and ACF sections. Microvessel density was scored at $\times 20$ magnification count of all CD31-positive cells within five representative fields in areas with optimal crypt orientation (i.e., longitudinal rather than cross-sectional crypt views). Staining for nuclear Ki-67 was scored as the total number of cells positive in three distinct, well-oriented crypts per specimen. Proliferative index expressed the ratio of positively stained nuclei to the total number of cells present within the crypts. Immunostaining for SMAD4 and ER α was scored based on nuclear staining intensity on a scale from 0 to 3, for cells residing at the crypt or ACF base. Nuclear expression of MGMT was scored as either intact or absent in ACF epithelial cells

based on comparison with normal nuclear expression identified in the nonneoplastic colonic crypts.

Statistical analyses

Our various analyses used the following statistical methods: contingency table analysis with the Mantel-Haenszel χ^2 to compare categorical variables; McNemar's χ^2 to compare pre- and post-treatment paired differences in dichotomous variables; *t* test to compare continuous variables (number of adenomas and number of ACF); analysis of covariance with control for baseline ACF number to assess the pre- and post-treatment changes in the number of ACF by treatment group; and repeated measures ANOVA within the general linear model to assess differences in immunohistochemical markers by time period (pre- and post-treatment), biopsy type (ACF or normal), and treatment group (celecoxib or placebo) for repeated measures on the same patient for time period and biopsy type. The Mantel-Cox life-table extension of the Mantel-Haenszel statistic was used to compare the cumulative proportion of patients with adenomas over the 3-y period by treatment group and patient characteristics. A summary risk ratio was also obtained from the Mantel-Cox procedure (5). Breslow's test for homogeneity was used to determine the risk ratio for the relationship between tissue SMAD4 expression and adenoma recurrence. All analyses were done using SAS version 9.1.

Results

Patient baseline characteristics and comparison with overall APC trial participants

Forty-five patients fully participated in this substudy of the APC trial, receiving a repeat magnification chromoendoscopy (Fig. 2) within 8 to 12 months of beginning treatment on the APC trial. Seventeen substudy patients received placebo, 15 received celecoxib (200 mg twice daily), and 13 received celecoxib (400 mg twice daily). Thirty-five patients were nonusers of aspirin and so were eligible for study biopsies. The patients participating in this ACF substudy were predominantly male

(93%), a figure higher than the overall APC cohort (68% males; Table 1). In addition, a smaller proportion of the ACF cohort had advanced adenomas at baseline (40% ACF cohort, 52% APC overall). The baseline characteristics of the ACF study cohort were otherwise well matched to the overall APC trial cohort (Table 1). In keeping with the eligibility requirements of the APC trial, all of the patients undergoing magnification chromoendoscopy had either multiple adenomas or at least one large adenoma (Table 1). The year 1 results of ACF substudy patients were representative of the overall APC trial cohort in terms of on-study adenoma recurrence (Table 2). However, ACF substudy placebo patients had a relatively low rate of adenoma recurrence at year 3 compared with the overall APC cohort (37.5% versus 60.7%, respectively). This difference was likely due to variability introduced by the small number of substudy patients (versus the large overall number of APC patients; see Table 2).

ACF histology

A total of 655 ACF were counted in 45 patients (Figs. 1 and 2; Table 3). Of the 45 patients undergoing magnification chromoendoscopy, 35 (78%) had ACF identified at baseline and 38 (84%) had ACF identified at baseline and/or follow-up magnification chromoendoscopy (Fig. 2). A mean of 8.3 ± 1.0 ACF per patient were observed at baseline examination and 6.3 ± 1.0 ACF per patient after 8 to 12 months of treatment with drug or placebo.

Thirty-five patients were non-aspirin users and so were eligible for and received pre- and post-treatment biopsies for histology and immunohistochemistry: 13 of 17 patients on placebo, 12 of 15 patients on celecoxib (200 mg twice daily), and 10 of 13 patients on celecoxib (400 mg twice daily). A total of 70 ACF from these patients were examined by H&E; none

Table 1. Cohort description

Characteristic	ACF cohort			APC trial overall		
	Placebo twice daily (n = 17)	200 mg celecoxib twice daily (n = 15)	400 mg celecoxib twice daily (n = 13)	Placebo twice daily (n = 679)	200 mg celecoxib twice daily (n = 685)	400 mg celecoxib twice daily (n = 671)
Age (y), median (range)	61 (51-81)	59 (38-70)	63 (50-78)	59 (31-88)	59 (35-83)	59 (34-87)
Male sex, n (%)	17 (100.0)	13 (86.7)	12 (92.3)	473 (69.7)	460 (67.2)	454 (67.7)
Body mass index in males, mean \pm SE	28.5 \pm 1.1	30.0 \pm 1.7	31.6 \pm 1.9	28.8 \pm 0.2	28.9 \pm 0.2	28.6 \pm 0.2
Current cigarette smoker, n (%)	1 (5.9)	5 (33.3)	1 (7.7)	122 (18.0)	119 (17.4)	96 (14.3)
Colorectal cancer in a parent, n (%)	5 (29.4)	5 (33.3)	2 (15.4)	140 (20.6)	147 (21.5)	142 (21.2)
No. adenomas at baseline, median \pm SE	2.0 \pm 1.2	2.0 \pm 1.5	2.0 \pm 1.9	2.0 \pm 0.1	2.1 \pm 0.1	2.1 \pm 0.1
At least one adenoma \geq 1 cm, n (%)	8 (47.0)	5 (33.3)	4 (30.8)	288 (42.4)	303 (44.2)	291 (43.4)
Advanced adenoma* at baseline, n (%)	9 (52.9%)	5 (33.3)	4 (30.8)	341 (50.2)	354 (51.7)	333 (49.6)
Hyperplastic polyp detected during a study colonoscopy, n (%)	6 (35.3)	6 (40.0)	6 (46.2)	268 (39.5)	271 (39.6)	276 (41.1)

*Features of an advanced adenoma are size \geq 1.0 cm, villous or tubulovillous histology, high-grade dysplasia, and/or invasive cancer.

Table 2. Adenoma detection during study

Endpoint	ACF cohort year 1		ACF cohort year 1 and/or year 3		APC trial overall year 1		APC trial overall year 1 and/or year 3	
	Placebo twice daily (n = 17)	Celecoxib twice daily (n = 28)	Placebo twice daily (n = 16)	Celecoxib twice daily (n = 28)	Placebo twice daily (n = 679)	Celecoxib twice daily (n = 1356)	Placebo twice daily (n = 679)	Celecoxib twice daily (n = 1356)
Detection of any adenoma, n (%) [*]	6 (37.5)	5 (18.5)	6 (37.5)	12 (45.7)	271 (44.6)	323 (26.6)	354 (60.7)	465 (40.4)

NOTE: Values represent the number of patients within a treatment category who developed an adenoma during the period indicated.

^{*}The ACF subgroup is comparable to the overall APC trial cohort for the results obtained at year 1 for both celecoxib and placebo groups. Over the 3-yr surveillance interval, the cumulative adenoma detection rate for placebo treatment was lower for the ACF subgroup than the overall APC trial cohort. Because the number of patients in the ACF placebo subgroup was very small (16), these rates could still be considered comparable.

contained features indicating dysplasia. Of the 70 ACF, 64 (91%) were hyperplastic and 6 (9%) were nonhyperplastic (Fig. 1). For purposes of this analysis, these categories were combined and termed “nondysplastic.”

Relationship of nondysplastic ACF to synchronous, recurrent, or advanced colorectal adenomas

All patients had synchronous (baseline) adenomas removed at a prestudy colonoscopy. Of the 45 patients undergoing magnification chromoendoscopy, 35 had ACF at baseline. The mean number of baseline adenomas in the 35 patients with ACF at baseline magnification chromoendoscopy was 2.1, compared with 2.5 for the 10 patients without ACF at

baseline ($P = 0.48$). Of patients undergoing magnification chromoendoscopy, 18 (40%) had one or more advanced adenomas at baseline. For patients with advanced adenomas at baseline, 14 (78%) also had one or more ACF identified at baseline. This figure was the same for those without advanced adenomas at baseline, 21 of 27 (78%), indicating that the presence of nondysplastic ACF did not correlate with a higher risk of synchronous advanced adenomas ($P = 1.0$). The mean number of ACF at baseline was also not different between those with and without advanced adenomas (8.2 versus 8.3, respectively; $P = 0.98$).

The relationship between the presence and number of baseline ACF and the incidence and number of adenomas

Table 3. ACF detection by magnification chromoendoscopy

Endpoint	MCE placebo twice daily (n = 17)			MCE celecoxib twice daily (n = 28)			Baseline or posttreatment	
	Baseline	Posttreatment	Pretreatment-posttreatment difference	Baseline	Posttreatment	Pretreatment-posttreatment difference	Placebo twice daily (n = 17)	Celecoxib twice daily (n = 28)
Total ACF count per group	139	101	-38 [*]	233	182	-51 [*]	240	415
Average ACF count per patient \pm SE [†]	8.2 \pm 2.4	5.9 \pm 1.7	2.3 \pm 1.7	8.3 \pm 1.7	6.5 \pm 1.5	1.8 \pm 1.1	14.1 \pm 3.8	14.8 \pm 3.1
Total no. patients with ACF detected (%)	13 (76.5)	12 (70.6)		22 (78.6)	21 (75.0)		14 (82.4)	24 (85.7)

Abbreviation: MCE, magnification chromoendoscopy.

^{*}For the 35 patients who were not taking cardioprotective aspirin, five ACF per patient were removed at the baseline magnification chromoendoscopy. This could have contributed to the pretreatment-posttreatment difference for both the placebo and celecoxib treatment groups. However, analysis taking this into consideration reveals no significant pretreatment-posttreatment difference for either treatment category. The difference in ACF pretreatment-posttreatment between celecoxib and placebo patients with control for baseline ACF level was 0.5 (95% confidence interval, -2.8-3.7; $P = 0.77$). When taking into account removal of ACF in non-aspirin-using patients, the difference was -1.0 (95% confidence interval, -2.7-4.6; $P = 0.60$).

[†]One patient with 55 ACF at baseline was an extreme outlier and was assigned the ACF value of the patient with the next to highest value (38) by winsorizing.

Table 4. Relationship between ACF and hyperplastic polyps

Endpoint	Patients with hyperplastic polyps, <i>n</i> = 18		Patients without hyperplastic polyps, <i>n</i> = 27	
	Placebo twice daily (<i>n</i> = 6)	Celecoxib twice daily (<i>n</i> = 12)	Placebo twice daily (<i>n</i> = 11)	Celecoxib twice daily (<i>n</i> = 16)
Cases with no ACF identified, <i>n</i> (%)	1 (17)	2 (17)	2 (18)	2 (13)
Average ACF count per patient ± SE	11.0 ± 4.5	12.7 ± 4.3	14.7 ± 5.5	16.4 ± 4.5

NOTE: Neither the presence of ACF in a given patient or the average number of ACF per patient predicted the presence of hyperplastic polyps in the entire colorectum.

detected during the 3-year study follow-up interval was assessed. Recurrent adenomas were detected at year 1 and/or year 3 colonoscopies in 46% of patients with ACF and 30% of patients without ACF at baseline. For patients who developed recurrent adenomas during the APC trial, 15 (83%) had at least 1 ACF at baseline, with a mean number of ACF in these patients of 8.4 ± 2.2 . For those who did not develop recurrent adenomas during the trial, these figures were 18 (72%) and 8.7 ± 1.8 , respectively. These results indicated that baseline ACF determination failed to predict the occurrence of newly detected adenomas during the chemoprevention trial.

Relationship of nondysplastic ACF to formation of hyperplastic colorectal polyps

Our data indicated that nondysplastic ACF were not precursors of sporadic colorectal adenomas; however, it is possible that these primarily hyperplastic proliferations are early precursors of hyperplastic polyps. These lesions are clinically relevant if they are numerous or exhibit the distinct histologic features of serrated adenomas. We determined the relationship between nondysplastic ACF and hyperplastic polyps in the study participants. Of the 35 patients with characterized nondysplastic ACF, 18 also had hyperplastic polyps identified during the APC trial observation period (Table 4). The percent of patients with no ACF detected did not vary by treatment group or presence of hyperplastic polyps ($P = 0.76$). The mean number of ACF detected in the patients with hyperplastic polyps was 12.1 ± 3.1 , compared with 15.7 ± 3.4 in those without hyperplastic polyps ($P = 0.55$). Consequently, for this small cohort, nondysplastic ACF did not indicate an increased tendency to form hyperplastic polyps.

Effects of celecoxib on nondysplastic ACF and adenomas

ACF could be considered a valid surrogate endpoint biomarker for celecoxib chemoprevention if modulation of baseline characteristics, such as ACF number or histologic character, predicted successful adenoma chemoprevention over the 1-year and 3-year observation periods of the APC trial. We therefore examined the relationship between baseline ACF characteristics, study treatment, and adenoma detection during the 3-year APC trial treatment interval.

Celecoxib was effective in preventing adenomas in the subset of patients on this ACF substudy (Table 2). For the 28 patients undergoing magnification chromoendoscopy who received celecoxib, adenoma detection during the first year follow-up period was decreased by 51% (risk ratio, 0.49). This reduction was consistent with that found for the APC trial overall (5). However, no difference in the degree of change in ACF number during the treatment interval was noted among the celecoxib or placebo groups. For patients treated with placebo, change in average ACF count from baseline to 8 to 12 months was 2.3, compared with 1.8 for those receiving celecoxib, corresponding to an average difference of 0.5 (95% confidence interval, -2.8 - 3.7 ; $P = 0.77$). In placebo patients, 76.5% had ACF detected at baseline, and 70.6% had ACF at posttreatment magnification chromoendoscopy. These figures were 78.6% and 75.0%, respectively, for patients treated with celecoxib (Table 3). These results show that celecoxib chemoprevention of adenomas was effective in the subset of patients undergoing magnification chromoendoscopy, but this effect was not accompanied by a reduction in ACF incidence or number.

Immunohistochemical characterization of ACF and celecoxib response

We obtained 70 formalin-fixed ACF biopsies from the 35 patients who were eligible for biopsy and immunohistochemistry (described above in "ACF histology"). Immunohistochemistry was used to determine whether changes associated with adenoma formation were seen in ACF, and/or were associated with celecoxib effects. Because all of the ACF in study patients were nondysplastic, we also obtained archived tissue samples containing dysplastic ACF from patients with familial adenomatous polyposis to serve as a comparison for the immunohistochemistry studies. Of interest, we observed no significant difference in immunohistochemical staining when hyperplastic ACF were compared with normal mucosa biopsies for COX-2, CD31, β -catenin, SMAD4, MGMT, or ER α (Figs. 3 and 4; Table 5). The only immunohistochemical assay revealing a significant difference between normal tissue and ACF was the proliferation marker Ki-67. Compared with normal-appearing mucosa, ACF showed increased proliferative index as determined by Ki-67 staining ($P < 0.0001$). In keeping with this, microscopy showed that the proliferative compartments of hyperplastic

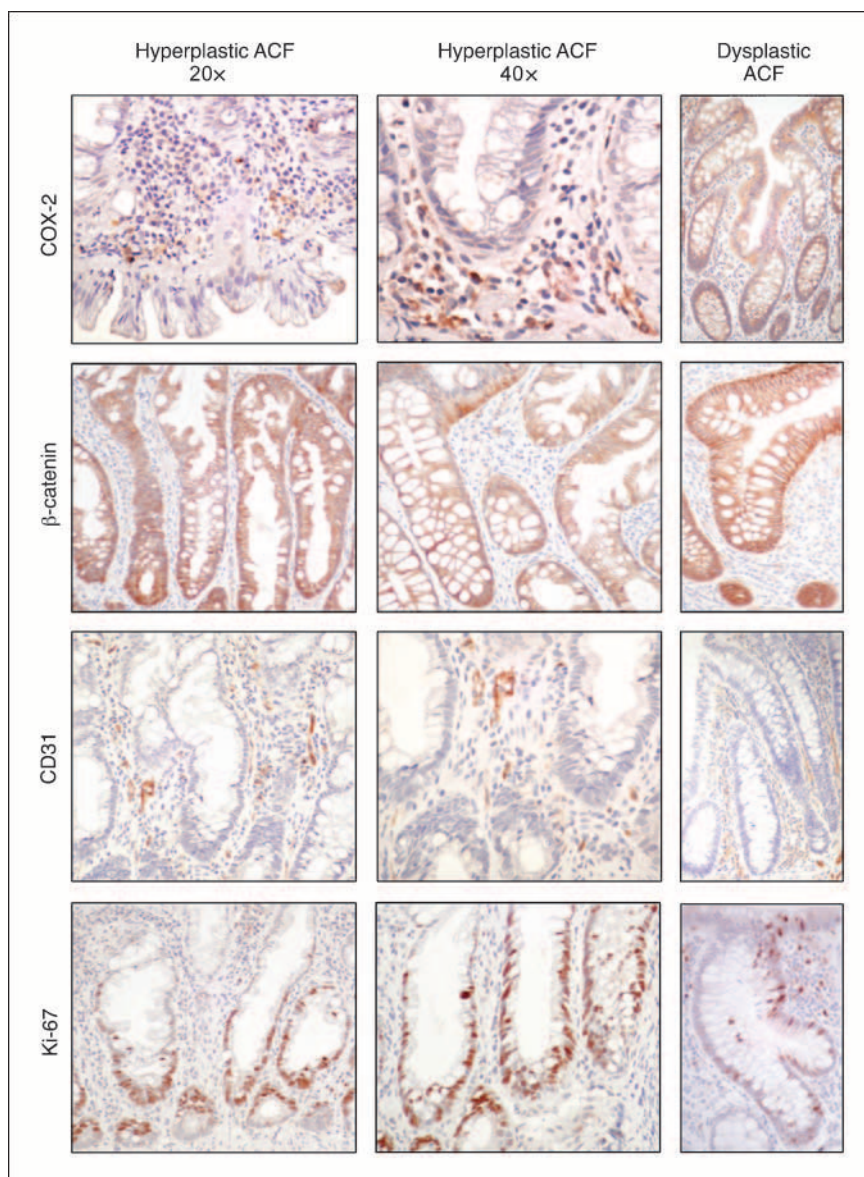
ACF crypts were expanded compared with those of normal mucosa (Fig. 3). Celecoxib treatment was associated with a 30% decrease in mean ACF proliferative index, from 30.73 to 21.65 ($P = 0.045$). In the normal mucosa, celecoxib treatment increased the proliferative index by 27%, from 11.08 to 14.06 ($P = 0.052$). There were no treatment-associated differences in the placebo arm.

The target of nonsteroidal anti-inflammatory drug chemoprevention is COX-2, an enzyme up-regulated in colorectal adenomas and cancers (13, 14). We assessed COX-2 expression in the nondysplastic ACF from study participants and also examined the effect of celecoxib treatment on COX-2 expression. Our scoring system took into account both epithelial and stromal COX-2 expression. Representative immunohistochemistry results appear in Fig. 3, and the corresponding scoring data are compiled in Table 5. We observed no difference in tissue COX-2 expression when pretreatment ACF were compared with those obtained post-

treatment, or when posttreatment ACF from placebo patients were compared with those from patients receiving celecoxib. However, variability in this measurement was suggested by posttreatment results in the placebo group. Here, we observed a decrease in mean COX-2 immunohistochemistry score from 4.44 to 2.33 ($P = 0.02$). This result, rather than modulation by celecoxib treatment, accounted for a significant pretreatment-posttreatment difference ($P = 0.01$).

In model systems, COX-2 promotes angiogenesis, an activity that is suppressed by celecoxib *in vivo* (15). Microvessel density, as measured by CD31 immunohistochemistry, indicates the degree of angiogenesis of a target lesion compared with adjacent normal tissue. We examined this effect in ACF by determining microvessel density pre- and post-treatment with celecoxib. We found no significant difference in microvessel density among ACF in treatment groups for baseline and posttreatment time points (Fig. 3; Table 5).

Fig. 3. Representative immunohistochemical stains of ACF from study patients. All ACF in study participants were nondysplastic. For comparison, each stain was also done using dysplastic ACF obtained from patients with familial adenomatous polyposis (*right*). Immunohistochemistry for β -catenin showed normal localization to the plasma membrane in all hyperplastic ACF examined. No significant difference in COX-2 staining intensity or CD31 microvessel density was observed on comparison of ACF and normal tissue specimens. Relative to normal mucosa, the Ki-67 proliferative compartment was expanded in ACF crypts.



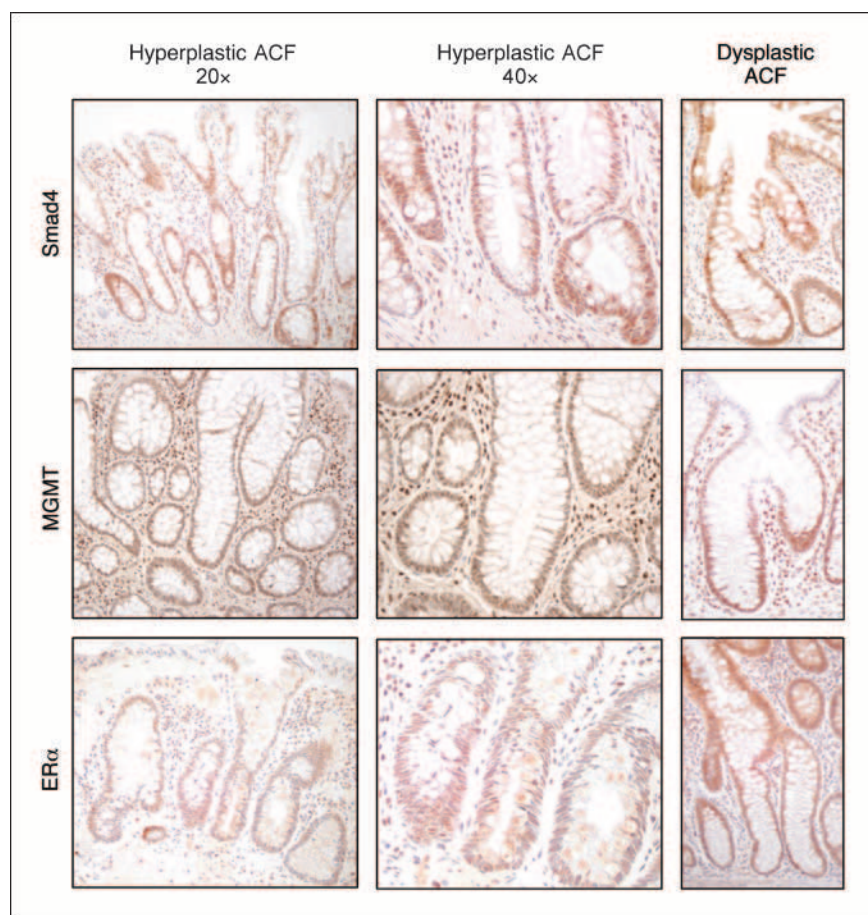


Fig. 4. ACF from study patients stained with antibodies to detect expression of SMAD4, MGMT, and ER α . For comparison, dysplastic ACF from patients with familial adenomatous polyposis were stained with the same antibodies (*right*). We observed intact expression of MGMT in all nondysplastic ACF examined, and no difference in ER α expression between normal mucosa and nondysplastic ACF. SMAD4 expression did not vary between normal rectal mucosa and ACF.

Expression and localization of the oncoprotein β -catenin were examined as indicators of functional loss of the APC tumor suppressor gene, and because studies in animal tumor models show that celecoxib normalizes β -catenin expression (16). Normal expression of β -catenin was observed in all nondysplastic ACF examined (Fig. 3). This was indicated by appropriate distribution of membrane-localized β -catenin in the differentiated cells. In contrast, dysplastic ACF from patients with familial adenomatous polyposis showed an increase in both cytoplasmic and nuclear β -catenin expression. When pre- and post-treatment ACF were compared, no treatment-associated differences in β -catenin expression were observed (data not shown).

Hyperplastic ACF of the distal colon and rectum may be the earliest lesion of a disease spectrum described by the serrated adenoma-carcinoma pathway (17, 18). This pathway is characterized by extensive CpG island methylation-associated silencing of tumor suppressors, including the DNA repair gene, *MGMT*, and *ER α* , which is the most common protein lost by methylation-associated promoter silencing in colorectal tumors (19, 20). Identification of elevated CpG island methylation in ACF may also indicate increased sensitivity to celecoxib chemoprevention, as work done in rodent colon tumor model found that celecoxib and difluoromethylornithine reduced CpG site hypermethylation of *ER α* (21). We assayed for promoter methylation-associated tumor suppressor gene silencing, using immunohistochemistry to detect MGMT and

ER α . For comparison tissues, we used normal rectal mucosa biopsies obtained from the ACF study participants, as well as archived dysplastic ACF from familial adenomatous polyposis patients. We found intact expression of MGMT in all nondysplastic ACF examined, and no difference in *ER α* expression between normal mucosa and nondysplastic ACF (Fig. 4; Table 5).

Loss of SMAD4, a tumor suppressor responsible for cell survival signaling via transforming growth factor β (TGF- β) pathway, may be a relatively late event in colorectal tumorigenesis (22); however, data from animal models also suggest that SMAD4 loss is a factor in the serrated/hyperplastic pathway of colorectal tumorigenesis (23). We examined SMAD4 expression in our study tissues and found no significant difference in expression between normal mucosa and nondysplastic ACF (Fig. 4; Table 5). Two of the patients in this APC trial substudy developed serrated adenomas during the 3-year colonoscopic surveillance period. One of these patients, treated with placebo, had 19 rectal ACF at baseline and 7 ACF at follow-up magnification chromoendoscopy. The second patient received celecoxib 200 mg twice daily and had 11 and 8 ACF at baseline and follow-up magnification chromoendoscopy, respectively. For both of these patients, ACF and normal tissue biopsies showed intact MGMT expression and normal expression of *ER α* and SMAD4 when ACF were compared with normal rectal mucosa samples.

Although SMAD4 expression did not vary between normal rectal mucosa and ACF, SMAD4 expression in baseline ACF was a predictor of the primary outcome measurement of the APC trial (i.e., adenoma recurrence at either the year 1 or the year 3 study colonoscopy). Patients who had reduced levels of SMAD4 in their ACF were less likely to have recurrent adenomas detected during the APC trial (Table 6). In patients with intact nuclear SMAD4 expression at baseline, 80% developed recurrent adenomas, compared with 18% of those with reduced SMAD4 levels (risk ratio, 0.23; $P = 0.01$). When the effect of treatment was considered, the prognostic value of SMAD4 expression remained. This relationship was not observed for any of the other immunohistochemical markers studied.

Discussion

The results of this substudy indicate that nondysplastic ACF were not an accurate surrogate endpoint biomarker of recur-

rent colorectal adenomas in the APC trial. We identified 655 pre- and post-treatment ACF, with no evidence of dysplastic ACF, in 45 patients, who were similar to APC trial patients in all important aspects. Celecoxib treatment did not significantly alter ACF number ($P = 0.77$). ACF had an increased proliferative index as determined by Ki-67 compared with adjacent normal tissue ($P < 0.0001$) but lacked other features of neoplasia reflected by COX-2 expression and microvessel density, nuclear localization of β -catenin, and expression of the tumor suppressors SMAD4, ER α , and MGMT. Only baseline SMAD4 expression in ACF correlated with posttreatment adenoma recurrence, and this result was independent of treatment arm ($P = 0.01$). The presence or number of nondysplastic ACF did not correlate with a higher risk of synchronous advanced or recurrent adenomas.

In this study, a large number of rectal ACF were removed for microscopic examination. This work confirmed the ability of magnification chromoendoscopy to detect histologically

Table 5. Immunohistochemistry results

Marker	Placebo (n = 13)			Celecoxib (n = 22)			P for treatment effects and interaction effect*		
	Baseline	Post treatment	P, pretreatment-posttreatment difference	Baseline	Post treatment	P, pretreatment-posttreatment difference	Celecoxib vs placebo	Pretreatment-posttreatment	Normal mucosa vs ACF [†]
COX-2 IHC score									
Normal mucosa	3.00	3.33	0.54	2.81	2.81	1.00	0.46	0.64	0.82
ACF	4.44	2.33	0.02	3.06	3.06	1.00	0.62	0.01	
CD31 IHC score									
Normal mucosa	17.67	22.42	0.09	20.81	21.05	0.93	0.77	0.21	0.31
ACF	22.89	23.78	0.72	21.56	24.38	0.34	0.91	0.39	
Ki-67 IHC score									
Normal mucosa	12.74	11.51	0.32	11.08	14.06	0.052	0.77	0.41	<0.0001
ACF	28.94	23.57	0.32	30.73	21.65	0.045	0.98	0.04	
SMAD4 (% intact stain)									
Normal mucosa	38	50	0.32	36	79	0.08	0.16	0.29	
ACF ^{‡,§}	38	75	0.18	54	62	0.65	0.62	0.08	
ER α (% intact stain)									
Normal mucosa	0	0	—	0	0	—	0.61	1.00	
ACF ^{‡,§}	17	33	0.56	0	23	—	0.71	0.91	

Abbreviation: IHC, immunohistochemistry.

*Using repeated ANOVA.

[†]ACF vs adjacent normal comparison is based on subjects with marker levels for pre- and post-magnification chromoendoscopy biopsies as well as for both normal and ACF tissue.

[‡]A total of 45 patients participated in this magnification chromoendoscopy substudy. Of these, 10 patients were taking cardioprotective doses of aspirin, and to avoid bleeding complications these individuals had rectal ACF counted but did not undergo biopsy of either ACF or normal mucosa. In addition, the numbers of cases studied by immunohistochemistry for SMAD4 and ER α were smaller still due to insufficient remaining tissue in some cases (numbers given in Table 6).

[§]SMAD4 and ER α are dichotomized as intact (SMAD4 = 3; ER α = 3) or deficient (SMAD4 <3; ER α <3). McNemar's test for paired proportions is used to assess whether there are significant baseline to 8-mo differences in the percent with SMAD4 intact or ER α intact.

distinct ACF in the rectum. What was striking, however, was the absence of dysplastic ACF in this cohort of patients at a high risk of colorectal cancer. Each of the patients in the substudy had either multiple or large adenomas, and 40% had advanced lesions removed at baseline, yet none of the 70 ACF biopsied in these patients contained dysplastic features. This result agreed with other studies reporting a prevalence of dysplastic ACF in sporadic patients of <10% (7, 8, 24).

The most likely explanation for the lack of ACF correlation with disease severity and modulation by celecoxib is that nondysplastic ACF are not precursors of sporadic adenomas. This is in contrast to dysplastic ACF, which are common in patients with familial adenomatous polyposis. Dysplastic ACF have morphologic and molecular similarities to adenomas, leading some authors to term these lesions "microadenomas" (25). In support of this, nondysplastic ACF rarely, if ever, show loss of APC protein function, which is characterized by increased β -catenin expression and nuclear localization (24, 26). These features, however, are common in dysplastic ACF from familial adenomatous polyposis patients (Fig. 3). Conversely, mutations in K-ras, particularly of codon 12, have a reported frequency of 69% to 100% in nondysplastic ACF, but are rare in small adenomas (27, 28).

Several conditions are necessary for an endpoint to be considered a validated surrogate endpoint biomarker of more advanced disease. One requirement is that the biomarker correlates with the target disease. Numerous studies measuring ACF by magnification chromoendoscopy found a high degree of association between the number of rectal ACF and the presence of synchronous adenomas and adenocarcinomas (29). Our study did not include patients without synchronous adenomas, and therefore we cannot address the sensitivity and specificity of magnification chromoendoscopy for detection of synchronous neoplasia. All patients in the present study had colorectal adenomas, and 40% had a high risk of colorectal cancer that was based on the removal of an advanced adenoma at baseline. Despite these characteristics, only 78% of patients had rectal ACF at baseline, and ACF frequency was the same in patients with and without advanced

adenomas. Overall, this result showed a relatively high false negative rate of ~20% for magnification chromoendoscopy when used to identify synchronous colorectal neoplasia. Increased endoscopic scrutiny (e.g., surveying 20 high-power fields instead of 10) may have lowered this number.

In secondary analyses of ACF immunohistology, we explored whether ACF exhibited characteristics expected of adenoma precursors. We also assessed the ability of celecoxib to modulate ACF immunophenotype. Of these analyses, SMAD4 nuclear expression was the only baseline ACF characteristic that correlated with adenoma recurrence. Although most of our data indicated that ACF are not adenoma precursors, these lesions could be a marker for global epigenetic changes that promote tumor formation. TGF- β signaling, which is defined by nuclear SMAD4 expression, serves a tumor suppressor function in advanced cancers (22). This role may be different in early neoplasia (23). TGF- β signaling plays a positive role in the resolution of inflammation and suppresses tumor formation. On the other hand, data from animal models demonstrate cross talk between the TGF- β and Wnt pathways, and show that activation of TGF- β signaling promotes intestinal tumor initiation in the setting of APC mutation (30). Our finding that reduced baseline SMAD4 nuclear expression in ACF was associated with a reduced risk of colorectal adenoma recurrence during the substudy is consistent with the hypothesis that TGF- β signaling is context specific and plays different roles in tumor initiation and promotion. This intriguing association deserves further mechanistic characterization in colorectal cancer initiation models and warrants prospective validation in clinical studies of patients both with and without colorectal adenomas.

The most important element of surrogate endpoint biomarker validation is a correlation between treatment modulation of the biomarker and clinical outcome of treatment. The only study variable significantly affected by celecoxib treatment was tissue proliferative index, as measured by nuclear Ki-67 expression. These results, however, are difficult to interpret because the modulation associated with celecoxib occurred in opposite directions in ACF and normal mucosa. At baseline, the proliferative index was elevated in ACF

Table 6. Relationship between ACF SMAD4 expression and adenoma recurrence

	Patients with intact SMAD by IHC, <i>n</i> = 10		Patients with deficient SMAD by IHC, <i>n</i> = 11	
Patients with recurrent adenomas at year 1 and/or year 3, <i>n</i> (%)	8 (80)		2 (18)	
Risk ratio (95% confidence interval)	1		0.23 (0.06-0.83)*	
<i>P</i>			0.01	
	Patients with intact SMAD by IHC, <i>n</i> = 10		Patients with deficient SMAD by IHC, <i>n</i> = 11	
	Placebo twice daily (<i>n</i> = 3)	Celecoxib twice daily (<i>n</i> = 7)	Placebo twice daily (<i>n</i> = 4)	Celecoxib twice daily (<i>n</i> = 7)
Patients with recurrent adenomas at year 1 and/or year 3, <i>n</i> (%)	3 (100)	5 (71)	1 (25)	1 (14)

*The risk ratio (95% confidence interval) for risk of recurrent adenomas by SMAD4 status controlling for treatment status was 0.22 (0.06-0.80) with Breslow's test for homogeneity of *P* = 0.49.

compared with normal mucosa ($P < 0.0001$), and celecoxib treatment lowered the ACF value by 30% ($P = 0.045$). However, the proliferative index of normal mucosa was increased by 27% following celecoxib treatment ($P = 0.052$). It is possible that celecoxib treatment produces different changes in cell proliferation depending on whether the cell is neoplastic (ACF) or normal. If this is the case, then it is possible that determination of proliferative index in either ACF or normal mucosa could be used as a surrogate endpoint biomarker of celecoxib chemoprevention. It is also possible that these results are an artifact of small sample size. Therefore, although these results are intriguing, they require confirmation in future clinical trials.

Colorectal adenomas are considered to be a validated surrogate endpoint biomarker for sporadic colorectal cancer because removing adenomas by endoscopic polypectomy correlates with a decrease in colorectal cancer incidence (31). An adenoma endpoint, however, requires chemoprevention trials of up to 3 years of duration and sample sizes of hundreds of patients, and so it is important to identify new surrogate end-point biomarkers that reduce the size, dura-

tion, and cost of colorectal cancer chemoprevention studies. Based on the APC trial data presented here, however, we conclude that nondysplastic ACF were not a surrogate endpoint biomarker for recurrent colorectal adenomas or, by extension, for colorectal cancer. We were able to draw this conclusion because the endpoints of this substudy were set within the context of a successful chemoprevention trial. The detailed immunohistochemical analyses of this substudy also raise the possibility that tissue SMAD4 expression may predict adenoma risk and that ACF or normal tissue proliferative index modulation may be a surrogate endpoint biomarker of celecoxib response. This ACF study and the resulting preliminary, hypothesis-generating molecular findings show the importance of integrating translational biology endpoints into clinical trials.

Disclosure of Potential Conflicts of Interest

C. Gostout: Commercial research grant, other commercial research support, and speakers bureau Olympus America. M.M Bertagnolli, Commercial research grant, Pfizer, Inc., Honorarium, Metamark, Inc. The other authors disclosed no potential conflicts of interest.

References

1. Cancer facts and figures, 2006 [article on the Internet]. American Cancer Society 2006. Available from: <http://www.cancer.org/downloads/STT/CAFF2006PWSecured.pdf>.
2. Baron JA, Cole BF, Sandler RS, et al. A randomized trial of aspirin to prevent colorectal adenomas. *N Engl J Med* 2003;348:891–9.
3. Arber N, Eagle CJ, Spicak J, et al. Celecoxib for the prevention of colorectal adenomatous polyps. *N Engl J Med* 2006;355:885–95.
4. Steinbach G, Lynch PM, Phillips RK, et al. The effect of celecoxib, a cyclooxygenase-2 inhibitor, in familial adenomatous polyposis. *N Engl J Med* 2000;342:1946–52.
5. Bertagnolli MM, Eagle CJ, Zauber AG, et al. Celecoxib for the prevention of sporadic colorectal adenomas. *N Engl J Med* 2006;355:873–84.
6. McLellan EA, Bird RP. Aberrant crypts: potential preneoplastic lesions in the murine colon. *Cancer Res* 1998;48:6187–92.
7. Adler DG, Gostout CJ, Sorbi D, Burgart LJ, Wang L, Harmsen WS. Endoscopic identification and quantification of aberrant crypt foci in the human colon. *Gastrointest Endosc* 2002;56:657–62.
8. Takayama T, Katsuki S, Takahashi Y, et al. Aberrant crypt foci of the colon as precursors of adenoma and cancer. *N Engl J Med* 1998;339:1277–84.
9. Wargovich MJ, Jimenez A, McKee K, et al. Efficacy of potential chemopreventive agents on rat colon aberrant crypt formation and progression. *Carcinogenesis* 2000;21:1149–55.
10. Mereto E, Fencica L, Ghia M. Effect of aspirin on incidence and growth of aberrant crypt foci induced in the rat colon by 1,2-dimethylhydrazine. *Cancer Letters* 1994;76:5–9.
11. Bird RP. Observation and quantification of aberrant crypts in the murine colon treated with a colon carcinogen: preliminary findings. *Cancer Letters* 1987;37:147–51.
12. Shpitz B, Klein E, Buklan G, et al. Suppressive effect of aspirin on aberrant crypt foci in patients with colorectal cancer. *Gut* 2003;52:1598–601.
13. Adegboyega PA, Ololade O, Saada J, Mifflin R, Di Mari JF, Powell DW. Subepithelial myofibroblasts express cyclooxygenase-2 in colorectal tubular adenomas. *Clin Cancer Res* 2004;10:5870–9.
14. Sheehan KM, O'Connell F, O'Grad A, et al. The relationship between cyclooxygenase-2 expression and characteristics of malignant transformation in human colorectal adenomas. *Eur J Gastroenterol Hepatol* 2004;16:619–25.
15. Masferrer J. Approach to angiogenesis inhibition based on cyclooxygenase-2. *Cancer J* 2001;13:S144–50.
16. Carothers AM, Moran AE, Cho NL, Redston M, Bertagnolli MM. Changes in antitumor response in C57BL/6J–Min/+ mice during long-term administration of a selective cyclooxygenase-2 inhibitor. *Cancer Res* 2006;66:6432–8.
17. Makinin MJ. Colorectal serrated adenocarcinoma. *Histopathology* 2007;50:131–50.
18. Jass JR, Baker K, Zlobec I, et al. Advanced colorectal polyps with the molecular and morphological features of serrated polyps and adenomas: concept of a “fusion” pathway to colorectal cancer. *Histopathology* 2006;49:121–31.
19. Campan M, Weisenberger DJ, Laird PW. DNA methylation profiles of female steroid hormone-driven human malignancies. *Curr Top Microbiol Immunol* 2006;310:414–78.
20. Jass JR. Classification of colorectal cancer based on correlation of clinical, morphological and molecular features. *Histopathology* 2007;50:113–30.
21. Pereira MA, Tao L, Wang W, et al. Modulation by celecoxib and difluoromethylornithine of the methylation of DNA and the estrogen receptor- α gene in rat colon tumors. *Carcinogenesis* 2004;25:1917–23.
22. Kouvidou C, Latoufis C, Lianou E, et al. Expression of Smad4 and TFG- β 2 in colorectal carcinoma. *Anticancer Res* 2006;26:2901–7.
23. Alberici P, Jagmohan-Chagur S, De Pater E, et al. Smad4 haploinsufficiency in mouse models for intestinal cancer. *Oncogene* 2006;25:1841–51.
24. Jen J, Powell SM, Papadopoulos N, et al. Molecular determinants of dysplasia in colorectal lesions. *Cancer Res* 1994;54:5523–6.
25. Hurlstone DP, Cross SS. Role of aberrant crypt foci detected using high-magnification chromoscopic colonoscopy in human colorectal carcinogenesis. *J Gastroenterol Hepatol* 2005;20:173–81.
26. Otori K, Konishi M, Sugiyama K, et al. Infrequent somatic mutation of the adenomatous polyposis coli gene in aberrant crypt foci of human colon tissue. *Cancer J* 1998;83:896–900.
27. Yamashita N, Minamoto T, Ochiai A, Onda M, Esumi H. Frequent and characteristic K-ras activation and absence of p53 protein in aberrant crypt foci of the colon. *Gastroenterology* 1995;108:600–3.
28. Losi L, Roncucci L, di Gregorio C, de Leon MP, Benhattar J. K-ras and p53 mutations in human colorectal aberrant crypt foci. *J Pathol* 1996;178:259–63.
29. Stevens RG, Swede H, Rosenberg DW. Epidemiology of colonic aberrant crypt foci: Review and analysis of existing studies. *Cancer Letters* 2007;252:171–83.
30. Labbe E, Lock L, Letamendia A, et al. Transcriptional cooperation between the transforming growth factor- β and Wnt pathways in mammary and intestinal tumorigenesis. *Cancer Res* 2007;67:75–84.
31. Winawer SJ, Zauber AG, Ho MN, et al. Prevention of colorectal cancer by colonoscopic polypectomy. The National Polyp Study Workgroup. *N Engl J Med* 1993;329:1977–81.