

To the editor:

CALR-mutated essential thrombocythemia evolving to chronic myeloid leukemia with coexistent CALR mutation and BCR-ABL translocation

The understanding of the genetic basis of the myeloproliferative neoplasms has increased tremendously in the last few years.¹ In essential thrombocythemia (ET), 50% to 65% of the patients carry the *JAK2* V617F mutation, whereas only ~5% of patients carry *MPL* exon 10 mutations. More recently, *CALR* exon 9 mutations were identified in ~20% to 25% of ET patients.^{2,3} *CALR* mutations have been found almost exclusively in ET and primary myelofibrosis, suggesting that *CALR* mutations primarily affect the biology of megakaryocytes. Interestingly, *CALR*-mutant ET seems to be a distinctive entity within myeloid neoplasms with distinguishing clinical features. It affects relatively young individuals and is characterized by markedly elevated platelet count but relatively low thrombotic risk and no progression to polycythemia vera.⁴ Here we report a case of *BCR-ABL*⁺ chronic myeloid leukemia (CML) presenting 3 years after the diagnosis of a *JAK2*⁻*MPL*⁻ ET, both lesions carrying the same *CALR* mutation. The case occurred in a 26-year-old man who was noted in 2011 to have new-onset thrombocytosis (platelets [PLTs], $1159 \times 10^9/L$) with normal hemoglobin and white blood cell (WBC) count. The bone marrow (BM) biopsy was normocellular with a normal myeloid:erythroid ratio but an increased amount of megakaryocytes without fibrosis. The megakaryocytes showed a predominance of hyperlobated “staghorn” forms often present in loose clusters (Figure 1A-C). Molecular studies at the time of diagnosis showed wild-type *JAK2* and *MPL* genes. A diagnosis of *JAK2*⁻*MPL*⁻ ET was rendered. The patient was treated with interferon 135 μg once per week and then with a 12-day interval with good response (Figure 1G).

In May 2014, the patient was noted to have new-onset leukocytosis (WBC, $14.8 \times 10^9/L$) with normal PLT count. Three months later, the patient’s WBC count increased to $25.7 \times 10^9/L$. Molecular studies revealed a *BCR-ABL* (e14a2) fusion transcript in peripheral blood (PB). A BM biopsy revealed hypercellularity with an elevated myeloid:erythroid ratio. Megakaryocytes were predominantly small and hypolobated (Figure 1D-E). Immunohistochemical analysis with CD61 highlighted the increased number of dwarf megakaryocytes (Figure 1F). Fluorescent in situ hybridization analysis using a *BCR-ABL* dual color, dual fusion translocation probe (Zytolight, Zytomed) confirmed a *BCR-ABL* fusion in 99 of 100 cells, indicative of the t(9;22)(q34;q11.2) translocation (Figure 1D, insert). Retrospectively, molecular studies and fluorescent in situ hybridization analysis for the *BCR-ABL* fusion transcript were performed in the 2011 BM biopsy, both of which rendered negative results. Fragment length analysis with subsequent Sanger sequencing of *CALR* exon 9 gene demonstrated an identical 5-bp insertion (mutation type 2; c.1154_1155insTTGTC, p.K385fs*47) in both biopsies (Figure 1H-I). Next-generation sequencing performed in purified PB granulocytes revealed a mutant *CALR* allele burden of 44%, which is in agreement with the heterozygous mutation found with fragment length analysis. To rule out the possibility of a *CALR* germ line mutation, a hair shaft probe was analyzed that revealed a *CALR* wild-type sequence confirming the presence of a somatic mutation in the hematopoietic cells.^{5,6} The interferon therapy was switched to the tyrosine kinase inhibitor nilotinib (150 mg). After 3 months, the patient has had a good hematologic response but has not achieved complete molecular response (*BCR-ABL* International Standard 3.23), whereas PLT

counts have steadily increased, and no change in the *CALR* allele burden has been observed (Figure 1G).

This is the first description of a *CALR* exon 9 mutated ET with characteristic clinical findings (young adult with very high PTL count at presentation) that acquired a t(9;22)(q34;q11.2) translocation and changed the morphology from ET to CML. The high allele burden of mutant *CALR* concurrent with *BCR-ABL* translocation in almost 100% of the BM cells is a strong argument in favor of a common clone that harbors both genetic alterations. Our findings suggest that a subclone of the preexisting *CALR*-mutated heterozygous clone acquired a *BCR-ABL* translocation, conferring an additional growth advantage to double-mutant progenitors and shifted the morphology from ET to CML. Treatment with nilotinib is causing disappearance of the double-mutant clone and favoring re-emergence of the *CALR*-mutant-only clone manifested by the constant allele burden of mutant *CALR* with increased PLTs in PB, returning to the original phenotype. Similar findings have been described in cases with simultaneous *BCR-ABL* translocation and *JAK2* V617F mutations.⁷⁻⁹ Our case highlights how the clinical and morphologic appearance of myeloproliferative neoplasms is governed by their mutational profile.

Irina Bonzheim

*Institute of Pathology and Comprehensive Cancer Center Tübingen,
University Hospital Tübingen,
Tübingen, Germany*

Barbara Mankel

*Institute of Pathology and Comprehensive Cancer Center Tübingen,
University Hospital Tübingen,
Tübingen, Germany*

Peter Klaphor

*Gemeinschaftspraxis Hämato-Onkologie,
Munich, Germany*

Janine Schmidt

*Institute of Pathology and Comprehensive Cancer Center Tübingen,
University Hospital Tübingen,
Tübingen, Germany*

Tanja Hinrichsen

*Zentrum für Humangenetik und Laboratoriumsdiagnostik,
Martinsried, Germany*

Oliver Wachter

*Zentrum für Humangenetik und Laboratoriumsdiagnostik,
Martinsried, Germany*

Falko Fend

*Institute of Pathology and Comprehensive Cancer Center Tübingen,
University Hospital Tübingen,
Tübingen, Germany*

Leticia Quintanilla-Martinez

*Institute of Pathology and Comprehensive Cancer Center Tübingen,
University Hospital Tübingen,
Tübingen, Germany*

Acknowledgments: The authors thank the technical staff of the molecular and immunohistochemical laboratories at the Institute of Pathology, University Hospital, Tübingen, Germany.

This work was supported in part by Sonderforschungsbereich 685 (L.Q.-M., F.F., and I.B.).

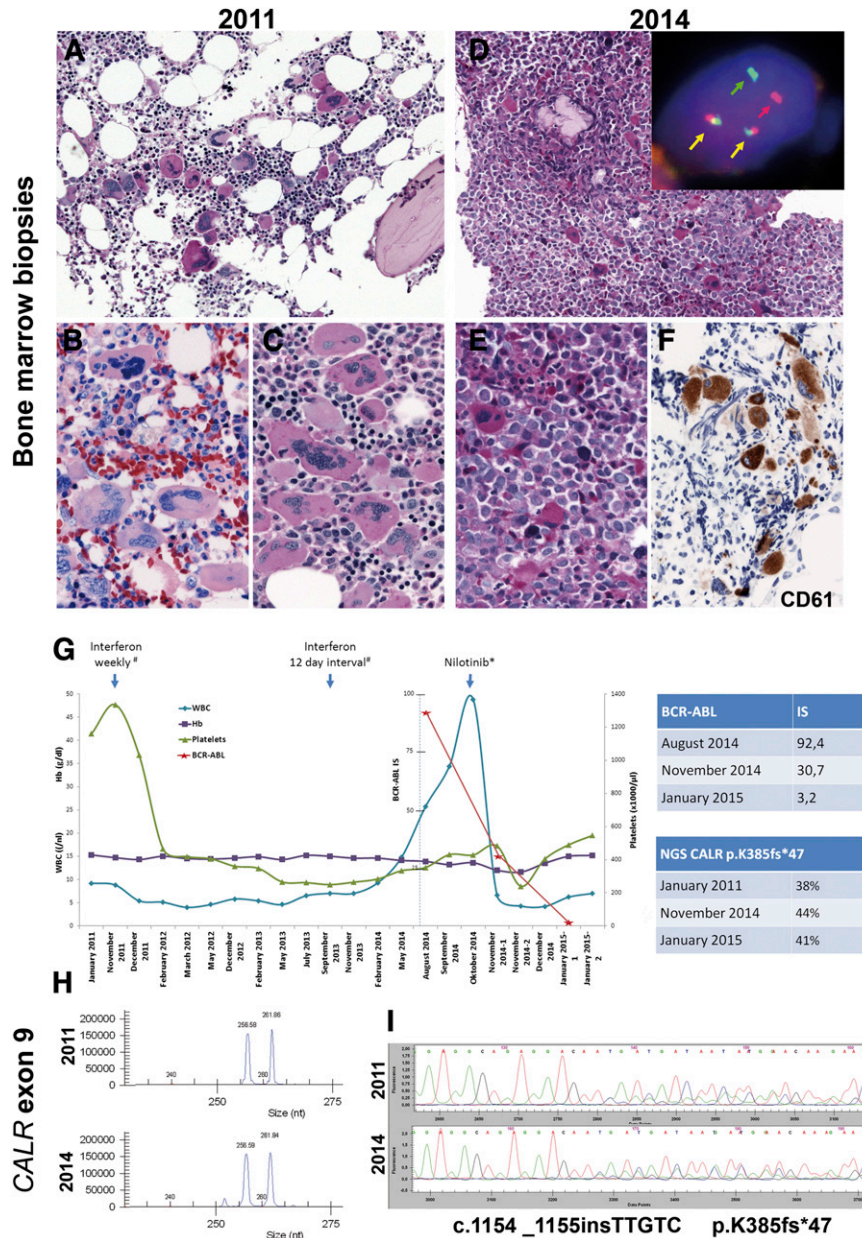


Figure 1. Morphologic and molecular findings in a case of *CALR*-mutated essential thrombocytemia that evolved into a *CALR*-mutated *BCR-ABL*⁺ chronic myeloid leukemia. (A-C) Bone marrow biopsy in 2011. (A) Normocellular BM with increased amount of large hyperlobated “staghorn” megakaryocytes (PAS stain). (B-C) Higher magnification showing the loose clusters of megakaryocytes with mainly staghorn forms (B: Giemsa stain; C: periodic acid Schiff stain). (D-F) BM biopsy in 2014. (D) Hypercellular BM with increased myeloid:erythroid ratio and increased amount of small hypolobated dwarf megakaryocytes (PAS stain). Insert: Interphase fluorescent in situ hybridization analysis using *BCR-ABL* dual color, dual fusion translocation probe (Zytotomed, Zytolight *BCR-ABL*) shows one red signal (red arrow), one green signal (green arrow), and two red/green fusion signals (yellow arrow) indicative of a t(9;22)(q34;q11). (E) Higher magnification showing the atypical small hypolobated megakaryocytes in a background of left-shifted granulopoiesis (periodic acid Schiff stain). (F) CD61 (Dako; Glostrup, Denmark) staining highlights the small hypolobated megakaryocytes. (G) Graphic depiction of the peripheral blood counts from January 2011 to January 2015. The patient was treated originally with interferon 135 μ g. In October 2014, he was switched to nilotinib 150 mg (2-0-2). The top table shows the quantitative reverse transcription polymerase chain reaction (qRT-PCR) results of the *BCR-ABL* fusion transcript in international standard (IS). The bottom table shows the next-generation sequencing results of the allele burden of *CALR* mutant. (H) Fragment length analysis of *CALR* exon 9 hotspot region shows concurrent amplification of the wild-type allele resulting in a 257-bp fragment and a mutated allele of 262 bp in both BM biopsies. (I) Sanger sequencing of the *CALR* exon 9 hotspot region confirmed an identical frameshift mutation in both biopsies (c.1154_1155insTTGTC, p.K385fs*47). Fluorescent in situ hybridization images were acquired with a $\times 100/1.40$ oil immersion objective in a Zeiss Axio fluorescence microscope (Zeiss) equipped with the appropriate filters sets and an Axio CAM MRm camera (Zeiss) and were documented and processed by using the Axio Vision Rel 4.8 software (Zeiss). Immunohistochemical analysis was performed on an automated immunostainer (Ventana Medical Systems, Tucson, AZ), following the manufacturer’s protocols. Fragment analysis of *CALR* exon 9 hotspot region was performed by using Phusion Hot Start DNA polymerase (Finnzymes) with adequate amplification conditions and D4-fluorescent dye primer modification (Sigma-Aldrich).² The products were separated by capillary electrophoresis on the GenomeLab GeXP Genetic Analysis System and analyzed with GenomeLab GeXP 10.2 software (Beckman Coulter, Krefeld, Germany). Sequencing of *CALR* exon 9 hotspot region was performed by using M13-tailed primers (forward: 5'-CTGGTCTGGTCTGATGTC-3'; reverse: 5'-GGGGACATCTTCTCTCAT-3') and Phusion Hot Start DNA polymerase with adequate amplification conditions, followed by dye terminator cycle sequencing (Quick Start Master Mix) using M13 primers and capillary electrophoresis on the GenomeLab GeXP Genetic Analysis System 10.2 software. Next-generation sequencing was applied for mutational screening of *CALR* (exon 9). By using a 2-step PCR, design amplicons were generated that included sequencing adaptors for Roche 454 sequencing and an individual multiplex identifier (MID tag) to allow multiplexing. After amplicon pooling, the library was purified (QIAquick PCR purification kit; Qiagen, Hilden, Germany) followed by agencourt AMPure XP (Beckman Coulter) and quantified by using the Quant-iT PicoGreen Kit (Invitrogen, Carlsbad, CA). Following the emulsion-based PCR amplification (GS Junior emPCR kit), clonally amplified beads were enriched according to the manufacturer’s recommendations and quantified on a CASY cell counter (Roche). The 454 sequencing data were generated on a GS Junior using the GS Junior Titanium Sequencing Kit (Roche). The expected coverage was $\times 1000$. Data analysis was performed by using JSI Sequence Pilot, SEQNext (JSI Medical Systems GmbH, Kippenheim, Germany). Hb, hemoglobin.

Contribution: I.B., B.M., and J.S. performed molecular analysis and analyzed data; P.K. contributed vital patient information; T.H. and O.W. performed genetic analysis; L.Q.-M. and F.F. designed the study, performed the histologic analysis, analyzed data, and wrote the paper.

F.F. and L.Q.-M. contributed equally to this work.

Conflict-of-interest disclosure: The authors declare no competing financial interests.

Correspondence: Leticia Quintanilla-Martinez, Institute of Pathology, University Hospital Tübingen, Liebermeisterstrasse 8, 72076 Tübingen, Germany; e-mail: leticia.quintanilla-fend@med.uni-tuebingen.de.

References

- Cazzola M, Kralovics R. From Janus kinase 2 to calreticulin: the clinically relevant genomic landscape of myeloproliferative neoplasms. *Blood*. 2014; 123(24):3714-3719.
- Klampfl T, Gisslinger H, Harutyunyan AS, et al. Somatic mutations of calreticulin in myeloproliferative neoplasms. *N Engl J Med*. 2013;369(25): 2379-2390.
- Nangalia J, Massie CE, Baxter EJ, et al. Somatic CALR mutations in myeloproliferative neoplasms with nonmutated JAK2. *N Engl J Med*. 2013; 369(25):2391-2405.
- Rumi E, Pietra D, Ferretti V, et al; Associazione Italiana per la Ricerca sul Cancro Gruppo Italiano Malattie Mieloproliferative Investigators. JAK2 or CALR mutation status defines subtypes of essential thrombocythemia with substantially different clinical course and outcomes. *Blood*. 2014;123(10): 1544-1551.
- Rumi E, Harutyunyan AS, Pietra D, et al; Associazione Italiana per la Ricerca sul Cancro Gruppo Italiano Malattie Mieloproliferative Investigators. CALR exon 9 mutations are somatically acquired events in familial cases of essential thrombocythemia or primary myelofibrosis. *Blood*. 2014;123(15): 2416-2419.
- Lundberg P, Nienhold R, Ambrosetti A, Cervantes F, Pérez-Encinas MM, Skoda RC. Somatic mutations in calreticulin can be found in pedigrees with familial predisposition to myeloproliferative neoplasms. *Blood*. 2014;123(17): 2744-2745.
- Hussein K, Bock O, Seegers A, et al. Myelofibrosis evolving during imatinib treatment of a chronic myeloproliferative disease with coexisting BCR-ABL translocation and JAK2V617F mutation. *Blood*. 2007;109(9): 4106-4107.
- Yamada O, Mahfoudhi E, Plo I, et al. Emergence of a BCR-ABL translocation in a patient with the JAK2V617F mutation: evidence for secondary acquisition of BCR-ABL in the JAK2V617F clone. *J Clin Oncol*. 2014;32(21): e76-e79.
- Bocchia M, Vannucchi AM, Gozzetti A, et al. Insights into JAK2-V617F mutation in CML. *Lancet Oncol*. 2007;8(10):864-866.

© 2015 by The American Society of Hematology

To the editor:

Bridging to transplant with azacitidine in juvenile myelomonocytic leukemia: a retrospective analysis of the EWOG-MDS study group

DNA methyltransferase-inhibiting azanucleosides have become a mainstay of treatment of myeloid neoplasms in adult patients,¹ with 5-azacitidine (azacitidine) being the agent in broadest clinical use. Although not curative, treatment with azacitidine achieves hematologic improvement and transfusion independency in many patients and prolongs survival.^{2,3} Even though most children with juvenile myelomonocytic leukemia (JMML) qualify for allogeneic hematopoietic stem cell transplantation (HSCT), the acceptable toxicity of low-dose azacitidine and its cytoreductive potential make it an attractive option as a bridging therapy before HSCT⁴ or as palliation after 1 or more transplants have failed. We previously published the first case report of a boy with JMML who achieved a complete clinical and genetic remission after 8 cycles of azacitidine.⁵ Here, we present a retrospective compilation of 12 children with JMML who received individual off-label treatment with azacitidine before HSCT (N = 9) or for relapsed disease (N = 3).

The children were treated at 11 centers November 2007-April 2012. Ten children were enrolled in the studies “98” or “2006” of the European Working Group of Myelodysplastic Syndromes in Childhood (EWOG-MDS; registered at www.clinicaltrials.gov as #NCT00047268 and #NCT00662090). Approval was obtained from the institutional review board of each institution, and parental informed consent was provided according to the Declaration of Helsinki. Two children were treated at centers not participating in EWOG-MDS studies. One case (D644) was published previously.⁵ The diagnosis of all children was centrally reviewed, and response was evaluated according to international consensus criteria.⁶

The median age of the 12 patients was 4.8 years (range 0.4-9.1) (Table 1). A total of 64 azacitidine cycles were administered (median 5.5 cycles, range 1-11). Seven of 12 treatments consisted of 100 mg/m² azacitidine per intravenous infusion on 5 consecutive days every 28 days. In the other 5 patients, the substance was administered over

5 to 7 days at a single dose of 50 to 100 mg/m² per intravenous or subcutaneous route every 28 to 42 days.

Severe neutropenia ($\leq 500/\mu\text{L}$) was observed in 4 children. Cytopenias led to dose reduction in 2 children, both treated for relapse after second HSCT. Other adverse events were gastrointestinal problems including nausea and vomiting in 2 children, skin rash in 2 children, and fatigue or slight creatinine elevation in 1 patient each. Seven episodes of infection were reported for a total of 64 azacitidine cycles (10.9%).

Of 9 children treated prior to HSCT, 3 normalized blood counts and spleen size (scored as clinical CR) (Table 1). In 2 of these patients, monosomy 7 was present in leukemic cells but disappeared after cycles 5 and 6, respectively. The leukemic karyotype was normal in the other child with clinical CR, precluding the assessment of cytogenetic response. Two of the 3 CR patients featured a somatic *PTPN11* gene mutation. The mutation became undetectable after cycle 6 in 1 child (NS002); material for mutational analysis under azacitidine was unavailable from the other child (D827). The third leukemia carried a somatic *KRAS* mutation, which was no longer detectable after 7 cycles of azacitidine (D644).⁵ One child (CH058) experienced considerable regression of spleen size and became transfusion independent (scored as clinical PR). All 4 children underwent HSCT after 7 to 11 cycles. A fifth child (NS001) responded unusually early, as indicated by reduction of splenomegaly after the first cycle and hematologic improvement after cycle 3 (scored as clinical PR). Azacitidine was then discontinued because of parental choice. Three children progressed rapidly under azacitidine and underwent expedited HSCT. One child (I255) was not evaluable for response because of concomitant treatment. Three children with JMML received azacitidine for leukemia recurrence after the second HSCT. They achieved clinical PR or could be maintained in stable disease for 4 cycles before progressing.