

Increased Numbers of Low-Oxygenated Pancreatic Islets After Intraportal Islet Transplantation

Richard Olsson,¹ Johan Olerud,¹ Ulrika Pettersson,¹ and Per-Ola Carlsson^{1,2}

OBJECTIVE—No previous study has measured the oxygenation of intraportally transplanted islets, although recent data suggest that insufficient engraftment may result in hypoxia and loss of islet cells.

RESEARCH DESIGN AND METHODS—After intraportal infusion into syngeneic mice, islet oxygenation was investigated in 1-day-old, 1-month-old, or 3-month-old grafts and compared with renal subcapsular grafts and native islets. Animals received an intravenous injection of pimonidazole for immunohistochemical detection of low-oxygenated islet cells ($pO_2 < 10$ mmHg), and caspase-3 immunostaining was performed to assess apoptosis rates in adjacent tissue sections.

RESULTS—In the native pancreas of nontransplanted animals, ~30% of the islets stained positive for pimonidazole. In 1-day-old and 1-month-old grafts, the percentage of pimonidazole-positive islets in the liver was twice that of native islets, whereas this increase was abolished in 3-month-old grafts. Beneath the renal capsule, pimonidazole accumulation was, however, similar to native islets at all time points. Apoptosis rates were markedly increased in 1-day-old intrahepatic grafts compared with corresponding renal islet grafts, which were slightly increased compared with native islets. One month posttransplantation renal subcapsular grafts had similar frequencies of apoptosis as native islets, whereas apoptosis in intraportally implanted islets was still high. In the liver, islet graft vascular density increased between 1 and 3 months posttransplantation, and apoptosis rates simultaneously dropped to values similar to those observed in native islets.

CONCLUSIONS—The vascular engraftment of intraportally transplanted islets is markedly delayed compared with renal islet grafts. The prolonged ischemia of intraportally transplanted islets may favor an alternative implantation site. *Diabetes* 60:2350–2353, 2011

Long-term outcome after clinical islet transplantation still remains poor, with few patients being insulin-independent 5 years posttransplantation (1). Several factors contribute to the deterioration of islet graft function, including instant death of infused islets (2), recurrence of disease (3), acute or chronic rejection (4), and insufficient revascularization (5,6).

The endogenous islets are richly vascularized, with no cell more than one cell away from arterial blood (7). The islet organ has a high blood flow, although the blood

perfusion of different islets varies (8). Moreover, the islet β -cells are highly dependent on their vasculature for nutrient metabolism and insulin release (9), and pretransplantation islet isolation and culture result in rapid degeneration of islet microvasculature (10).

At transplantation, islets completely depend on diffusion of nutrients and oxygen from the surrounding tissue. Thus, islet size, graft composition, and implantation organ oxygen levels may influence graft oxygenation. Posttransplantation new islet microvessels are formed, but the vascular density of native islets is not restored (5,6), which results in anaerobic metabolism in renal subcapsular grafts (11). In clinical islet transplantation, islets are, however, infused into the portal vein and dispersed into the liver. The oxygen diffusion properties are probably different between 200–250 islets implanted subcapsularly (12) and the intraportal route, where only one or a few islets engraft in the same area of liver tissue. Hitherto, vascular density has been reported to be decreased after intraportal islet transplantation (5,6), but the islet graft oxygen tension has only been recorded in liver subcapsular multi-islet grafts (12).

The current study aimed to investigate the oxygenation of intraportally transplanted islets. For this purpose, we used the oxygen-dependent bioreductive metabolism of pimonidazole to localize endogenous and transplanted islets with low oxygenation.

RESEARCH DESIGN AND METHODS

Male C57BL/6 mice were purchased from M&B Research and Breeding Center (Ry, Denmark). Animal housing and all experiments were approved by the animal ethics committee of Uppsala University. Blood glucose concentrations were determined with test reagent strips (Medisense; Baxter Travenol, Deerfield, IL) from samples obtained from the cut tip of the tail.

Islet isolation, culture, and transplantation. Islets were isolated by collagenase digestion, and 150 islets were cultured free floating in 5 mL RPMI-1640 medium (Sigma-Aldrich, Irvine, U.K.) in 95% air/5% CO₂ (5). After 3–4 days of culture, 200 islets were packed in a butterfly cannula (25 gauge) for injection into the portal vein or packed in a braking pipette for implantation beneath the renal capsule (5).

Measurements of oxygenation in cultured islets. Islets were incubated with 200 μ mol/L pimonidazole (Hypoxyprobe-1; Chemicon International, Temecula, CA) at standard culture conditions (95% air/5% CO₂) for 2 h, fixed in 4% paraformaldehyde, paraffin embedded, and immunostained for pimonidazole (described below).

Measurements of oxygenation in native and transplanted pancreatic islets. Islet oxygenation was investigated in the native pancreas of nontransplanted animals and in intraportally transplanted islets 1 day, 1 month, or 3 months posttransplantation. Furthermore, islet oxygenation was measured in renal subcapsular islet grafts 1 day or 1 month after implantation. For measurements of islet oxygenation, the 2-nitroimidazole pimonidazole (Chemicon), which had previously been reported to accumulate proportionally to the intracellular levels of oxygen (13), was used. We have previously evaluated this marker for use in pancreatic islets and observed that oxygen-sensitive intracellular pimonidazole accumulation also occurs in islet cells at $pO_2 < 10$ mmHg (14). Pimonidazole (60 mg/kg) was injected intravenously into the tail vein of awake animals. Two hours later, the animals were killed and their pancreas, liver, or graft-bearing kidney was immediately retrieved, fixed in 10% (vol/vol) formalin, and embedded in paraffin.

From the ¹Department of Medical Cell Biology, Uppsala University, Uppsala, Sweden; and the ²Department of Medical Sciences, Uppsala University, Uppsala, Sweden.

Corresponding author: Richard Olsson, richard.olsson@karolinska.se.

Received 2 April 2009 and accepted 19 June 2011.

DOI: 10.2337/db09-0490

This article contains Supplementary Data online at <http://diabetes.diabetesjournals.org/lookup/suppl/doi:10.2337/db09-0490/-/DC1>.

© 2011 by the American Diabetes Association. Readers may use this article as long as the work is properly cited, the use is educational and not for profit, and the work is not altered. See <http://creativecommons.org/licenses/by-nc-nd/3.0/> for details.

Immunohistochemical staining for insulin, pimonidazole, or caspase-3.

Every third slide with liver sections was stained for insulin to identify intraportally transplanted islets (5). Adjacent slides to located islet grafts were immunostained for pimonidazole (Chemicon) or caspase-3 (Cell Signaling Technology, Danvers, MA) according to the manufacturers' instructions. Moreover, tissue sections of cultured islets, native pancreas from control animals, and renal subcapsular grafts were stained for pimonidazole or caspase-3, and all tissues were counterstained with hematoxylin. The liver has an oxygen tension of ~10 mmHg, with even lower oxygenation in the proximity of central veins (12,15); thus, pimonidazole normally accumulates in liver tissue (preferentially around central veins). Therefore, liver tissue from pimonidazole-injected animals was used as positive control, whereas liver tissue from saline-injected animals was used as negative control. The fraction of islet cells positive for pimonidazole or caspase-3 was evaluated under a light microscope (magnification 100 \times and 400 \times , respectively). The percentage of pimonidazole-positive islet cells in renal subcapsular grafts was evaluated using a morphometric computerized system (ImageJ 1.3v; National Institutes of Health, Bethesda, MD).

Islet cell oxygen-dependent apoptosis. Islets were dispersed by trypsin digestion and placed on cover glasses precoated with poly-L-lysine (Sigma-Aldrich) to avoid islet oxygen diffusion gradients (14). Dispersed islet cells from each animal ($n = 3$) were incubated at 37°C for 4 h in airtight chambers containing gas mixtures with different oxygen tensions (0.5, 1.0, 1.5, or 2.0% O₂ in 5% CO₂, saturated with N₂; Air Liquid Gas, Stockholm, Sweden). After incubation at different oxygen tensions, the dispersed islet cells were retrieved and immediately stained for caspase-3 (CaspGLOW Fluorescein Active Caspase-3 Staining kit; Medical & Biological Laboratories, Woburn, MA).

Evaluation of vascular density. The vascular density of islets grafted into the liver was investigated 1 and 3 months posttransplantation. Endothelial cells were selectively stained using the lectin *Bandeiraea simplicifolia* (Sigma-Aldrich), and vascular densities were calculated as previously described (5,16). **Statistical analysis.** Values are expressed as means \pm SEM. For multiple comparisons between data, ANOVA and Fisher protected least significant difference post hoc test (SigmaStat 2.03; SPSS, Chicago, IL) was used. $P < 0.05$ was considered statistically significant.

RESULTS

Throughout the study, all mice were normoglycemic (non-fasting blood glucose ~ 7 mmol/L). All mice weighed ~ 30 g. **Islet oxygenation assessed by pimonidazole immunostainings in vitro and in vivo.** Cultured pimonidazole-positive islets often showed a stained center surrounded by unstained cells (Supplementary Data). This probably reflected low central oxygenation due to oxygen consumption gradients and diffusion limitations within islets. In large islets, an unstained central necrosis was sometimes observed because accumulation of pimonidazole only occurs in live cells (14). In contrast, endogenous islets were always homogeneously stained or unstained, whereas transplanted islets also sometimes displayed heterogeneous staining patterns reflecting oxygen consumption gradients caused by dysfunctional microvasculature.

Oxygenation of native and transplanted pancreatic islets. All animals subjected to an intravenous injection of pimonidazole ($n = 20$) accumulated pimonidazole in native and transplanted islets, respectively. After saline injection ($n = 2$), no positive immunostaining for pimonidazole in the pancreas was observed (data not shown). In the pancreas of nontransplanted animals, 118 ± 32 islets/pancreas ($n = 5$) were evaluated. In liver islet grafts, 17 ± 2 transplanted islets/recipient ($n = 4-7$) were analyzed, whereas in islets grafted to the renal site 10-12 tissue sections were investigated ($n = 4-5$). Approximately 30% of the native islets in nontransplanted animals stained positive for pimonidazole, whereas the exocrine tissue was negative or weakly stained (Fig. 1). After intraportal implantation, the pimonidazole-positive subpopulation of islets was doubled at both 1 day and 1 month posttransplantation compared with that in the pancreas of control animals, whereas at 3 months posttransplantation the increased islet cell

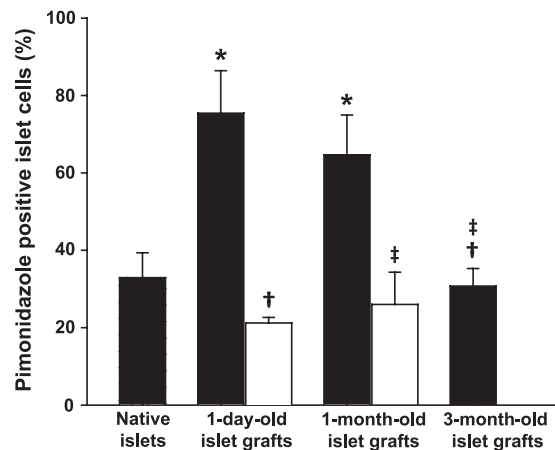


FIG. 1. Pimonidazole-positive islets in the native pancreas and in islet grafts after implantation into the portal vein (■) or into the renal subcapsular space (□). * $P < 0.05$ compared with native islets; † $P < 0.05$ compared with islets implanted into the liver 1 day posttransplantation; ‡ $P < 0.05$ compared with the liver site 1 month posttransplantation.

pimonidazole accumulation had disappeared. The fraction of endocrine tissue positive for pimonidazole in renal subcapsular grafts was comparable to native islets both 1 day and 1 month posttransplantation.

Apoptosis in native and transplanted islets. Apoptosis was increased 100-fold the day after intraportal implantation, whereas beneath the renal capsule the increase was only 20-fold compared with native islets (Fig. 2). At 1 month posttransplantation, the frequencies of apoptosis had decreased in all grafts and only islets infused into the liver retained an increased rate of apoptosis. At 3 months posttransplantation, the rates of apoptosis in intrahepatic grafts had also decreased to values similar to those in native islets. **Vascular density of intrahepatic islet grafts and islet cell oxygen-dependent apoptosis.** There was a marked increase in vascular density in 3-month-old compared with 1-month-old intrahepatic grafts (709 ± 135 vs. 203 ± 49 blood vessels/mm²; $n = 5$; $P < 0.05$) (Fig. 3). Incubation of dispersed islet cells at oxygen tensions $< 1.5\%$ O₂ (~ 11 mmHg) approximately doubled the frequency of

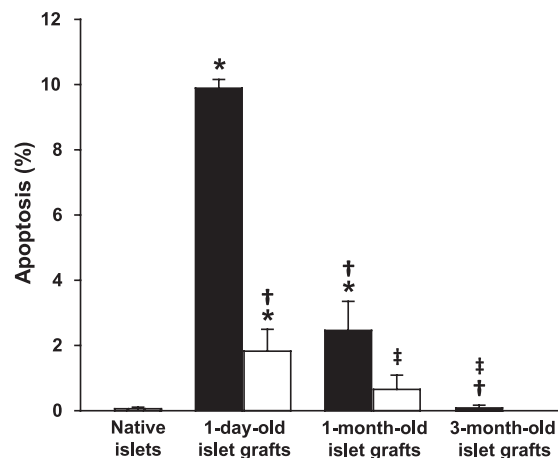


FIG. 2. Apoptosis in native islets and grafts implanted into the portal vein (■) or into the renal subcapsular space (□). * $P < 0.05$ compared with the native islets; † $P < 0.05$ compared with intraportally transplanted islets 1 day posttransplantation; ‡ $P < 0.05$ compared with the liver site 1 month posttransplantation.

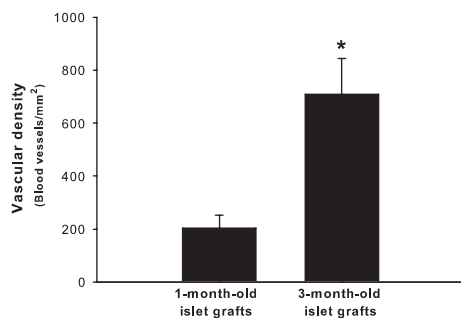


FIG. 3. Vascular density in 1-month-old and 3-month-old islet grafts implanted into the portal vein. * $P < 0.05$ compared with 1-month-old islet grafts.

caspase-3-positive cells compared with higher oxygen levels ($n = 3$; $P < 0.05$) (Fig. 4).

DISCUSSION

In the current study, we used the bioreductive metabolism of pimonidazole for immunohistochemical detection of low-oxygenated islets after intraportal transplantation. Pimonidazole accumulates in tissues with oxygen tensions <10 mmHg, and it has been widely used in cancer research, including islet tumors (17), as well as in studies of normal physiology (15). Hyperglycemia may, however, increase pimonidazole accumulation through oxygen-independent mechanisms (18), and because the revascularization and oxygenation of islet grafts are similar in normoglycemic and cured diabetic recipients (12,16), only normoglycemic recipients were allocated to this study.

In 1-day-old grafts, when islets completely depended on oxygen diffusion for their survival, the fraction of intrahepatic islets with low oxygenation was doubled compared with that recorded in the pancreas of control animals. Notably, the percentage of low-oxygenated intrahepatic islets remained similarly increased 1 month posttransplantation, i.e., $\sim 70\%$ of the transplanted islets had an oxygen tension <10 mmHg. In contrast, renal islet grafts had a similar number of pimonidazole-positive islet cells as control tissue in both 1-day-old and 1-month-old grafts. Interestingly, these findings were supported by markedly increased apoptosis in intraportally implanted islets both 1 day and 1 month posttransplantation, whereas in renal subcapsular grafts only a modest increase in apoptosis was observed.

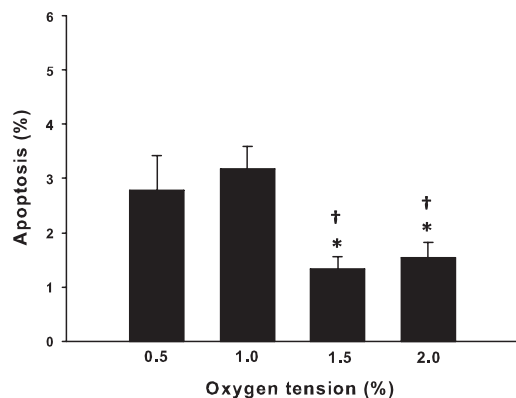


FIG. 4. Apoptosis in dispersed islet cells incubated at different oxygen tensions (0.5, 1.0, 1.5, or 2.0%) for 4 hours. * $P < 0.05$ compared with 0.5% O_2 ; † $P < 0.05$ compared with 1.0% O_2 .

These data strongly suggest that intraportally transplanted islets suffer from aggravated ischemia compared with what previously has been reported for the renal subcapsular site (12). When comparing the present data with previous studies, it is, however, important to note that pimonidazole positivity only discriminates oxygen tension <10 mmHg, without reflecting differences in absolute values, which may be assessed by oxygen-sensitive microelectrodes. Thus, there may be significant differences in absolute tissue oxygen tension among pimonidazole-positive islet cells.

Consistent with our previous observations in rats (14), there was a subpopulation of native islets ($\sim 30\%$) that stained positive for pimonidazole. In rats, these pimonidazole-positive native islets were previously characterized by decreased protein biosynthesis, suggesting decreased oxygen requirements due to low metabolic activity. Although pimonidazole-positive native islets have low oxygenation (<10 mmHg), it is unlikely that they are exposed to true hypoxia, given that in the case of hypoxia accumulation of substances such as adenosine would immediately increase islet blood flow (19), thereby improving oxygen levels. These rescue mechanisms are, however, impaired in avascular or poorly revascularized islet grafts, which may result in increased vulnerability to hypoxic stress. That hypoxia, due to loss of the normal microvasculature, results in islet cell death is further supported by the increased rates of apoptosis in dispersed islet cells at oxygen tensions <10 mmHg and by the reported improvement in graft oxygenation with concomitant decreased apoptosis rates during the first months posttransplantation (revascularization period).

At 1 and 6 months posttransplantation, the islet graft vascular densities have been reported to be similarly low in the renal site (16). Interestingly, the present data suggest delayed revascularization in the liver with improved vascular density in 3-month-old compared with 1-month-old islet grafts. Moreover, the initial high numbers of pimonidazole-positive and apoptotic islets after intraportal transplantation also imply that implantation into the liver increases hypoxic stress during the engraftment period. The mechanisms of the delayed revascularization and the functional consequences of differently oxygenated intraportally transplanted islets are yet to be determined, but intraportally engrafted islets have been reported to demonstrate impaired glucose oxidation rates as well as decreased insulin release (20). This opens the possibility that treatments to improve oxygenation of intraportally transplanted islets may be beneficial similarly to the benefit reported for renal subcapsular grafts, where improvements of the blood perfusion by either vasodilation (21) or increased vascular density (22,23) may improve graft function.

We conclude that intraportally transplanted islets are poorly oxygenated during the early posttransplantation period and that their vascular engraftment is delayed compared with the renal site. Novel strategies to improve vascular engraftment are warranted because low oxygenation may restrict islet graft function (24,25), and the prolonged ischemia of intraportally transplanted islets may favor an alternative implantation site.

ACKNOWLEDGMENTS

This work was supported by grants from the Swedish Research Council (72XD-15043), the Juvenile Diabetes Research Foundation, AFA Insurance, the Swedish Diabetes

Association, the Family Ernfors Fund, the Swedish Society for Medical Research, and the David and Astrid Hageléns Foundation.

This work also received support from the European Foundation for the Study of Diabetes/Novo Nordisk and the Novo Nordisk Foundation. No other potential conflicts of interest relevant to this article were reported.

R.O. researched data and wrote the manuscript. J.O., U.P., and P.-O.C. researched data, contributed to discussion, and reviewed the manuscript.

The skilled technical assistance of Astrid Nordin, Eva Törnélius, and Guangxiang Zang (Department of Medical Cell Biology, Uppsala University, Sweden) is gratefully acknowledged.

REFERENCES

- Koh A, Senior P, Salam A, et al. Insulin-heparin infusions peritransplant substantially improve single-donor clinical islet transplant success. *Transplantation* 2010;89:465–471
- Eich T, Eriksson O, Sundin A, et al. Positron emission tomography: a real-time tool to quantify early islet engraftment in a preclinical large animal model. *Transplantation* 2007;84:893–898
- Young HY, Zucker P, Flavell RA, Jevnikar AM, Singh B. Characterization of the role of major histocompatibility complex in type 1 diabetes recurrence after islet transplantation. *Transplantation* 2004;78:509–515
- Shapiro AM, Geng Hao E, Lakey JR, Finegood DT, Rajotte RV, Kneteman NM. Defining optimal immunosuppression for islet transplantation based on reduced diabetogenicity in canine islet autografts. *Transplantation* 2002;74:1522–1528
- Mattsson G, Jansson L, Carlsson PO. Decreased vascular density in mouse pancreatic islets after transplantation. *Diabetes* 2002;51:1362–1366
- Lau J, Carlsson PO. Low revascularization of human islets when experimentally transplanted into the liver. *Transplantation* 2009;87:322–325
- Bonner-Weir S. Morphological evidence for pancreatic polarity of beta-cell within islets of Langerhans. *Diabetes* 1988;37:616–621
- Jansson L. Microsphere distribution in the pancreas of anesthetized rats. Alloxan stimulates the blood flow to all islets whereas glucose only affects the blood perfusion of a subgroup of islets. *Int J Pancreatol* 1996;20:69–74
- Hellerström C. Effects of carbohydrates on the oxygen consumption of isolated pancreatic islets of mice. *Endocrinology* 1967;81:105–112
- Nyqvist D, Köhler M, Wahlstedt H, Berggren PO. Donor islet endothelial cells participate in formation of functional vessels within pancreatic islet grafts. *Diabetes* 2005;54:2287–2293
- Carlsson PO, Kiuru A, Nordin A, et al. Microdialysis measurements demonstrate a shift to nonoxidative glucose metabolism in rat pancreatic islets transplanted beneath the renal capsule. *Surgery* 2002;132:487–494
- Carlsson PO, Palm F, Andersson A, Liss P. Markedly decreased oxygen tension in transplanted rat pancreatic islets irrespective of the implantation site. *Diabetes* 2001;50:489–495
- Hodgkiss RJ. Use of 2-nitroimidazoles as bioreductive markers for tumour hypoxia. *Anticancer Drug Des* 1998;13:687–702
- Olsson R, Carlsson PO. A low oxygenated subpopulation of pancreatic islets constitutes a functional reserve of endocrine cells. *Diabetes* 2011;60:2068–2075
- Arteel GE, Thurman RG, Yates JM, Raleigh JA. Evidence that hypoxia markers detect oxygen gradients in liver: pimonidazole and retrograde perfusion of rat liver. *Br J Cancer* 1995;72:889–895
- Mattsson G, Jansson L, Nordin A, Carlsson PO. Impaired revascularization of transplanted mouse pancreatic islets is chronic and glucose-independent. *Transplantation* 2003;75:736–739
- Casanovas O, Hicklin DJ, Bergers G, Hanahan D. Drug resistance by evasion of antiangiogenic targeting of VEGF signaling in late-stage pancreatic islet tumors. *Cancer Cell* 2005;8:299–309
- Ling LL, Sutherland RM. Modulation of the hypoxic toxicity and binding of misonidazole by glucose. *Br J Cancer* 1986;54:911–917
- Carlsson PO, Olsson R, Källskog O, Bodin B, Andersson A, Jansson L. Glucose-induced islet blood flow increase in rats: interaction between nervous and metabolic mediators. *Am J Physiol Endocrinol Metab* 2002;283:E457–E464
- Mattsson G, Jansson L, Nordin A, Andersson A, Carlsson PO. Evidence of functional impairment of syngeneically transplanted mouse pancreatic islets retrieved from the liver. *Diabetes* 2004;53:948–954
- Kampf C, Lau T, Olsson R, Leung PS, Carlsson PO. Angiotensin II type 1 receptor inhibition markedly improves the blood perfusion, oxygen tension and first phase of glucose-stimulated insulin secretion in revascularised syngeneic mouse islet grafts. *Diabetologia* 2005;48:1159–1167
- Zhang N, Richter A, Suriawinata J, et al. Elevated vascular endothelial growth factor production in islets improves islet graft vascularization. *Diabetes* 2004;53:963–970
- Olerud J, Johansson M, Lawler J, Welsh N, Carlsson PO. Improved vascular engraftment and graft function after inhibition of the angiostatic factor thrombospondin-1 in mouse pancreatic islets. *Diabetes* 2008;57:1870–1877
- Dionne KE, Colton CK, Yarmush ML. Effect of oxygen on isolated pancreatic tissue. *ASAIO Trans* 1989;35:739–741
- Papas KK, Long RC Jr, Constantinidis I, Sambanis A. Effects of oxygen on metabolic and secretory activities of beta TC3 cells. *Biochim Biophys Acta* 1996;1291:163–166