

## Pathologic Complete Response to Neoadjuvant Chemotherapy of Breast Carcinoma Is Associated with the Disappearance of Tumor-Infiltrating Foxp3<sup>+</sup> Regulatory T Cells

Sylvain Ladoire,<sup>1,2</sup> Laurent Arnould,<sup>1</sup> Lionel Apetoh,<sup>3</sup> Bruno Coudert,<sup>1</sup> Francois Martin,<sup>2</sup> Bruno Chauffert,<sup>1,2</sup> Pierre Fumoleau,<sup>1</sup> and François Ghiringhelli<sup>1,2,3</sup>

**Abstract Purpose:** T-cell infiltration is associated with good tumor prognosis in many cancers. To assess the capacity of neoadjuvant chemotherapy to affect T-cell infiltration in breast cancer, we evaluated CD3 and CD8 infiltrates, and the Foxp3 immunosuppressive T cells.

**Experimental Design:** CD3<sup>+</sup>, CD8<sup>+</sup>, and Foxp3<sup>+</sup> cell infiltrates were detected by immunohistochemistry in a series of 56 breast cancer patients before and after the end of neoadjuvant chemotherapy.

**Results:** Poor prognostic factors (negative hormonal receptors, high tumor grade, and nodal involvement) were associated with a significantly higher number of CD3, CD8, and Foxp3 infiltrates before the beginning of chemotherapy. Chemotherapy resulted in a decrease in Foxp3 infiltrates, whereas the level of CD8 and CD3 infiltrates remained unchanged. Pathologic complete responses (pCR) had a drastic decrease of Foxp3<sup>+</sup> cells, whereas these cells remained elevated in nonresponders. A cutoff criterion that combined high CD8 infiltration and no Foxp3 cell infiltration on surgical specimens is associated with pCR with a sensitivity of 75% and a specificity of 93%. The infiltrate of cytotoxic TiA1 and granzyme B – positive cells was dramatically enhanced after chemotherapy only in patients with pCR. By multivariate analysis, association of a high CD8 infiltration and no Foxp3 infiltration on final histologic specimens were independently associated with pCR.

**Conclusion:** These findings indicate that pCR to neoadjuvant chemotherapy is associated with an immunologic profile combining the absence of immunosuppressive Foxp3 cells and the presence of a high number of CD8 T cells and cytotoxic cells. These results argue for the induction of an antitumor immune response by chemotherapy.

Many patients with local breast cancer are suitable candidates for neoadjuvant chemotherapy, with the aim of facilitating conservative surgery of the tumor and initiating early systemic treatment of micrometastases. Moreover, this approach provides an opportunity to assess tumor chemosensitivity to the preoperative regimen by measuring the residual disease obtained on surgical specimen. Pathologic complete response (pCR) after neoadjuvant chemotherapy has been described as a strong indicator of survival, justifying its use as a surrogate marker of chemosensitivity (1). Although chemotherapy mainly

acts directly by cytotoxic effect on tumor cells, the chemotherapy-induced tumor cell death also has the ability to harness the host's immune system to fight against its tumor. A recent study showed the involvement of Th1 antitumor responses in anticancer chemotherapy in mice (2), and also in breast cancer patients treated with anthracycline-based chemotherapy (3, 4). Interestingly, in these breast cancer patients, a polymorphism in the immune gene *Toll-like receptor 4* was an independent factor of poor prognosis in response to chemotherapy (5). Thus, clinically used anticancer agents seem to also mediate their cytotoxic effects through the immune system (6).

Spontaneous tumor immunity also influences tumor prognosis. High T-cell infiltration and CD8 infiltrate have been linked to a better prognosis in colon carcinoma and in ovarian cancer (7, 8). These data strongly suggest that tumor infiltration by CD8 cytotoxic effectors could control tumor growth and account for a better prognosis. By contrast, human tumors also promote accumulation of CD4<sup>+</sup>CD25<sup>+</sup> immunosuppressive regulatory T cells (Treg) in the tumor bed or in the blood. These cells are known as the key contributor to maintenance of immune tolerance, preventing emergence of organ-specific autoimmune diseases (9). These cells constitute ~2% to 3% of CD4<sup>+</sup> human blood T cells and could be characterized by the specific expression of the transcription factor Foxp3 (10). Patients with various types of cancer have higher numbers of

**Authors' Affiliations:** <sup>1</sup>Centre Régional de Lutte Contre le Cancer and <sup>2</sup>Institut National de la Santé et de la Recherche Médicale CRI-866, Faculty of Medicine, Dijon, France; and <sup>3</sup>Institut Gustave Roussy, Villejuif, France  
Received 9/28/07; revised 11/26/07; accepted 12/15/07.

**Grant support:** Ligue contre le Cancer comité de Côte d'Or and comité de la Nièvre.

The costs of publication of this article were defrayed in part by the payment of page charges. This article must therefore be hereby marked *advertisement* in accordance with 18 U.S.C. Section 1734 solely to indicate this fact.

**Requests for reprints:** François Ghiringhelli, Centre Georges François Leclerc, Centre de Recherche INSERM 866, Faculté de Médecine, 7 boulevard Jeanne D'Arc, 21000 Dijon, France. Phone: 33-3-80-39-33-53; Fax: 33-3-80-39-34-34; E-mail: francois.ghiringhelli@wanadoo.fr.

© 2008 American Association for Cancer Research.

doi:10.1158/1078-0432.CCR-07-4491

Tregs in peripheral blood than healthy donors (11), and high levels of Treg tumor infiltration have been reported in hepatocellular (12), lung (13), ovarian (14), gastric, esophageal (15), and recently in breast cancer (16). Emerging evidence suggests that Treg cells have an important immunopathologic role in human tumor growth by suppressing endogenous tumor-associated antigen-specific T-cell immunity (14). Furthermore, three recent studies show that Treg infiltrates influence tumor prognosis in ovarian, gastrointestinal stromal tumor, and breast cancer (14, 17, 16).

Although histologic changes after neoadjuvant chemotherapy of breast cancer have been previously reported, *in situ* effects of chemotherapy on tumor/host immune system interactions remains unclear. A direct action of chemotherapy on Treg blood number has been suggested in HER2+ breast tumor treated by trastuzumab-based chemotherapy (18). Nevertheless, to our knowledge, the effect of breast cancer chemotherapy on tumor-infiltrated cytotoxic CD8 and suppressor Foxp3 T cells remains unknown.

The aim of the present study was therefore to examine the evolution of tumor-infiltrating CD8<sup>+</sup> T cell and Foxp3<sup>+</sup> cells through neoadjuvant chemotherapy in breast cancer patients. Importantly, this study reveals a strong relationship between T-cell infiltrate and complete histologic response.

## Materials and Methods

**Patients, treatment, and histology.** Our series included 56 consecutive patients treated in our institution (Centre Regional de Lutte Contre

le Cancer Dijon, Dijon, France) between January 2004 and May 2005 for operable breast carcinoma with preoperative chemotherapy followed by surgery and radiotherapy. After obtaining informed consent and approval by the Regional Ethical Committee for Medical Research (Comité Consultatif pour la Protection des Patients dans la Recherche Biomédicale de Côte d'Or), the diagnosis was established by a core needle biopsy. Histologic type was defined according to the WHO classification. Histoprognostic grade was defined according to the modified Bloom and Richardson method. The steroid hormone receptor estrogen receptor and progesterone receptor status was determined using enzyme-immunoassays (Abbott Diagnostics). The Herceptest scoring method was used for determination of c-erbB-2 status, considering only 3-grade score as determining HER-2-positive tumors.

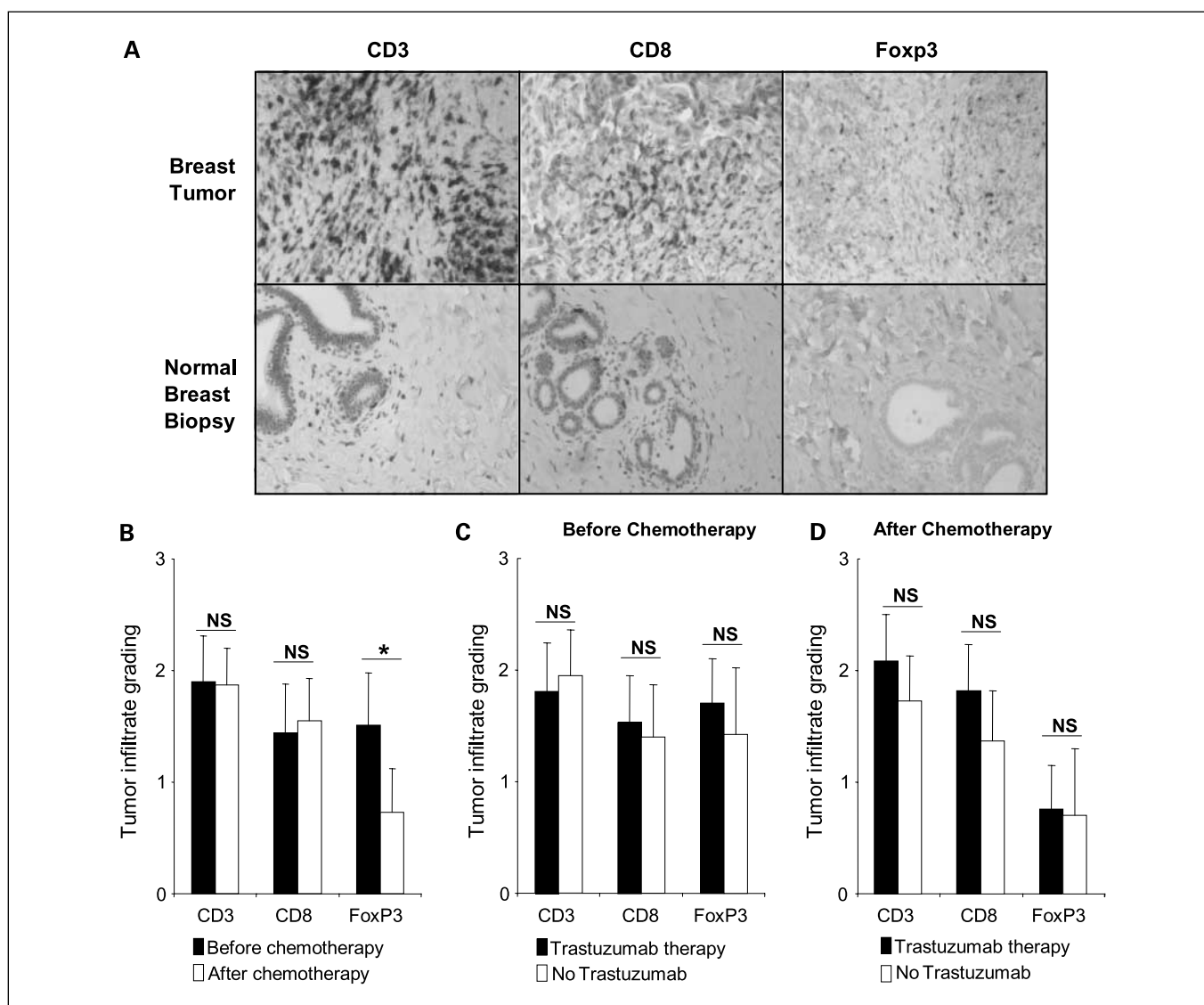
Chemotherapy was done using an anthracycline-based regimen: FEC 100 (epirubicin 100 mg/m<sup>2</sup>, cyclophosphamide 500 mg/m<sup>2</sup>, and 5-fluorouracil 500 mg/m<sup>2</sup>) or CEX (epirubicin 100 mg/m<sup>2</sup>, cyclophosphamide 500 mg/m<sup>2</sup>, and capecitabine 900 mg/m<sup>2</sup>, day 1-14); taxane regimens were used sequentially (with docetaxel 100 mg/m<sup>2</sup>) with anthracyclines-based chemotherapy. Patients with HER-2-positive tumors were treated with trastuzumab (2 mg/kg) associated with chemotherapy by docetaxel 100 mg/m<sup>2</sup> or by docetaxel 75 mg/m<sup>2</sup> + carboplatin AUC 6.

Surgery was done 2 to 3 wk after the last cycle of chemotherapy. Histologic response was determined on surgical specimens according to the Chevallier (19) and Sataloff classification (20). Breast tissue without residual malignant epithelial cell and associated with no microscopic evidence of invasive cancer in axillary specimens (Sataloff TA/NA or TA/NB, or Chevallier 1) was considered as pCR.

**Immunohistochemical labeling.** Immunohistochemistry used monoclonal antibodies against the pan T-cell marker CD3 (Ventana), the cytolytic T-cell marker CD8 (Dako), and Foxp3 (Abcam). Labeling was

**Table 1.** Patient and tumor characteristics

	Total cases	pCR group	NR group
Total cases	56	12	44
Age			
Mean ± SD	49.9 ± 8	47.6 ± 9.6	50.3 ± 8
Median (range)	51.5 (30-67)	49 (30-60)	49 (35-67)
Tumor size			
Mean ± SD	4.4 ± 1.7	4.6 ± 1.4	4.7 ± 2
Median (range)	4 (1-8)	3.9 (2-5)	4.5 (1-8)
Initial clinical tumor status			
T <sub>1</sub>	1	0	1
T <sub>2</sub>	33	7	26
T <sub>3</sub>	17	4	13
T <sub>4</sub>	5	1	4
Initial clinical node status			
N <sub>0</sub>	17	4	13
N <sub>1</sub>	31	5	26
N <sub>2</sub>	6	2	4
N <sub>3</sub>	2	1	1
Tumor grade			
1	4	0	4
2	33	5	28
3	19	7	12
HER overexpression (immunohistologic analysis)	20	8	12
Estrogen receptor			
Positive	37	4	33
Negative	19	8	11
Progesterone receptor			
Positive	27	2	25
Negative	29	10	19
Chemotherapy			
Anthracycline-based regimen	25	3	22
Anthracycline and taxane regimen	11	2	9
Trastuzumab and taxane regimen	20	7	13



**Fig. 1.** Evolution of the immune infiltrate. *A*, immunohistochemical staining with CD3, CD8, and Foxp3 antibody in breast cancer tumor (*top*) and normal breast (*bottom*). *B*, evolution of CD3<sup>+</sup>, CD8<sup>+</sup>, and Foxp3<sup>+</sup> tumor cell infiltration into breast tumor before and after neoadjuvant chemotherapy. *C*, CD3<sup>+</sup>, CD8<sup>+</sup>, and Foxp3<sup>+</sup> tumor cell infiltration into breast tumor before and after neoadjuvant chemotherapy according to the chemotherapeutic regimen (trastuzumab or no trastuzumab). Statistical analysis was done with the Mann-Whitney *U* test. NS, nonsignificant. \*,  $P \leq 0.05$ .

detected using the Dako Envision system (Dako). The stained arrays were counterstained with hematoxylin and mounted in Aquamount (Dako).

Positive and negative staining controls were carried out with paraffin tonsil sections using Foxp3 monoclonal antibody and an isotype-matched negative control antibody.

Potential cytolytic cells were stained with Granzyme B (Dako) and TiA1 (Immunotech).

**Quantification of T cells.** To evaluate the extent of lymphocytic infiltration, a grading system for semiquantitative scoring of lymphocytic infiltration based on the system established by Black et al. (21) was used. In our system, grade 0 corresponds to absence of lymphocytes and grades 1 to 3 correspond to increasing degrees of lymphocytic infiltration from a few scattered cells (grade 1) to marked infiltrate that mimics a lymphoid organ (grade 3). A modified scoring system was used for Foxp3<sup>+</sup> cells. We assessed at least 10 fields at high-power magnification ( $\times 200$ ): grade 0 corresponds to absence of Foxp3 cells; grade 1 corresponds to the presence of 1 to 3 Foxp3 cells in less than three fields; grade 2 corresponds to the presence of 1 to

3 Foxp3 cells in more than three fields; and grade 3 corresponds to the presence of more than 3 Foxp3 cells in more than three fields. For all these labels, the levels of lymphocytic infiltration were evaluated by two independent pathologists. For each location, all cases in which scores differed by more than one grade on the semiquantitative scoring were reexamined and a consensus score was reached.

**Statistical analyses.** The association of variables was evaluated with the  $\chi^2$  test or with the Fisher's exact test if required. The Mann-Whitney *U* test was used to compare noncontinuous variables as appropriate. Initial clinical size; nodal status; histologic grade; initial estrogen receptor and progesterone receptor status; HER2 status; chemotherapy regimen; and level of CD3<sup>+</sup>, CD8<sup>+</sup> T cells and Foxp3<sup>+</sup> lymphocytic infiltration at each biopsy were tested in univariate analysis. A *P* value  $< 0.05$  was considered significant.

A multivariate logistic regression model was also done to analyze the independent factors associated with these markers. Forward stepwise model selection was used to build the logistic regression model. Statistical analysis was done using XLSTAT software (Addinsoft) and Medcalc (Medcalc Software).

**Table 2.** Correlation analyses between the number of tumor-infiltrating T cells and clinicopathologic data before and after neoadjuvant chemotherapy (Mann-Whitney *U* test)

Categories	CD3 immune profile (mean ± SD)	P	CD8 immune profile (mean ± SD)	P	Foxp3 immune profile (mean ± SD)	P
<b>A. Before neoadjuvant chemotherapy</b>						
Age						
<50	1.9 ± 0.9	0.9	1.5 ± 0.8	0.6	1.6 ± 1	0.5
>50	1.9 ± 1		1.4 ± 1		1.4 ± 1.1	
T						
<40 mm	1.8 ± 1	0.3	1.5 ± 1	0.9	1.4 ± 1.1	0.5
>40 mm	2 ± 0.9		1.5 ± 0.9		1.6 ± 1.1	
N						
0	1.7 ± 1.1	0.05	1.1 ± 0.8	0.05	1.1 ± 1	0.05
+	2.1 ± 0.9		1.9 ± 1		1.9 ± 1	
Tumor grade						
1 + 2	1.7 ± 0.9	0.01	1.3 ± 0.9	0.03	1.2 ± 0.9	0.01
3	2.3 ± 1		1.8 ± 0.8		2 ± 1.1	
Estrogen receptor						
0	2.1 ± 1	0.4	1.8 ± 0.9	0.05	2 ± 1	0.02
+	1.8 ± 0.9		1.4 ± 1		1.3 ± 0.9	
Progesterone receptor						
0	2 ± 1	0.5	1.8 ± 1.1	0.04	1.7 ± 1.2	0.04
+	1.8 ± 0.8		1.1 ± 0.8		1 ± 0.9	
HER						
0	1.9 ± 0.9	0.7	1.4 ± 0.9	0.2	1.7 ± 1	0.3
+	1.9 ± 0.9		1.6 ± 0.9		1.4 ± 1.2	
<b>B. After neoadjuvant chemotherapy</b>						
Age						
<50	1.8 ± 0.8	0.6	1.6 ± 1	0.5	0.6 ± 0.9	0.6
>50	1.9 ± 0.8		1.5 ± 0.8		0.5 ± 0.8	
T						
<40 mm	1.8 ± 0.8	0.7	1.4 ± 1	0.2	0.6 ± 0.8	0.2
>40 mm	1.9 ± 0.9		1.7 ± 0.8		0.9 ± 1	
N						
0	1.7 ± 1	0.1	1.5 ± 1.1	0.98	0.5 ± 0.7	0.5
+	2 ± 0.7		1.5 ± 0.8		0.8 ± 1	
Tumor grade						
1 + 2	1.7 ± 0.8	0.04	1.2 ± 0.7	0.004	0.7 ± 0.9	0.9
3	2.2 ± 0.8		2 ± 0.9		0.7 ± 0.9	
Estrogen receptor						
0	2.2 ± 0.7	0.04	2.1 ± 0.8	0.001	0.9 ± 0.9	0.2
+	1.7 ± 0.8		1.2 ± 0.8		0.7 ± 0.9	
Progesterone receptor						
0	2.2 ± 0.7	0.01	1.8 ± 0.9	0.05	0.7 ± 0.9	0.7
+	1.6 ± 0.8		1.2 ± 0.8		0.8 ± 1	
HER						
0	1.7 ± 0.8	0.05	1.3 ± 0.0	0.05	0.7 ± 0.9	0.9
+	2.1 ± 0.9		1.9 ± 0.9		0.7 ± 0.8	
Chemotherapy						
Trastuzumab + taxane	2.2 ± 0.8	0.04	2 ± 0.7	0.04	0.7 ± 0.8	0.9
Other treatment	1.7 ± 0.8		1.3 ± 0.6		0.8 ± 0.7	

## Results

**Patient characteristics.** Patient and tumor characteristics are reported in Table 1. Most patients presented with T<sub>2</sub> or T<sub>3</sub> tumors and had clinically detectable axillary lymph node involvement at diagnosis. One third of patients presented with a high tumor grade or an overexpression of Her2/Neu protein.

Preoperative chemotherapy was given every 3 weeks for a total of six cycles, and consisted of an anthracycline-based regimen in 25 cases (46%), taxane regimens used sequentially with anthracyclines-based chemotherapy in 11 cases (20%), and trastuzumab with taxane in 20 patients (34%).

Classic histologic analysis of surgical specimens revealed a pCR in 12 cases (21.4%). This pCR was achieved in 40%

(8 of 20) of tumors overexpressing HER2, but in only 4 of the 36 patients (11%) with HER2-negative tumor ( $P = 0.01$ ).

**Analysis of T-cell infiltrates during treatment.** In normal breast tissue, there were few CD3 and CD8 cells. Foxp3 cells were almost absent from normal tissue. By contrast CD3, CD8, and Foxp3 cells were found in higher density in breast invasive carcinoma (Fig. 1A).

After neoadjuvant chemotherapy, CD3 and CD8 infiltrates remained stable, whereas Foxp3<sup>+</sup> cell numbers significantly decreased on surgical specimens ( $P = 0.01$ ; Fig. 1B).

These results argue for a differential reaction of intratumoral conventional T cells compared with intratumoral Foxp3 cells in response to chemotherapy. Interestingly, this observation was independent of chemotherapeutic regimen,

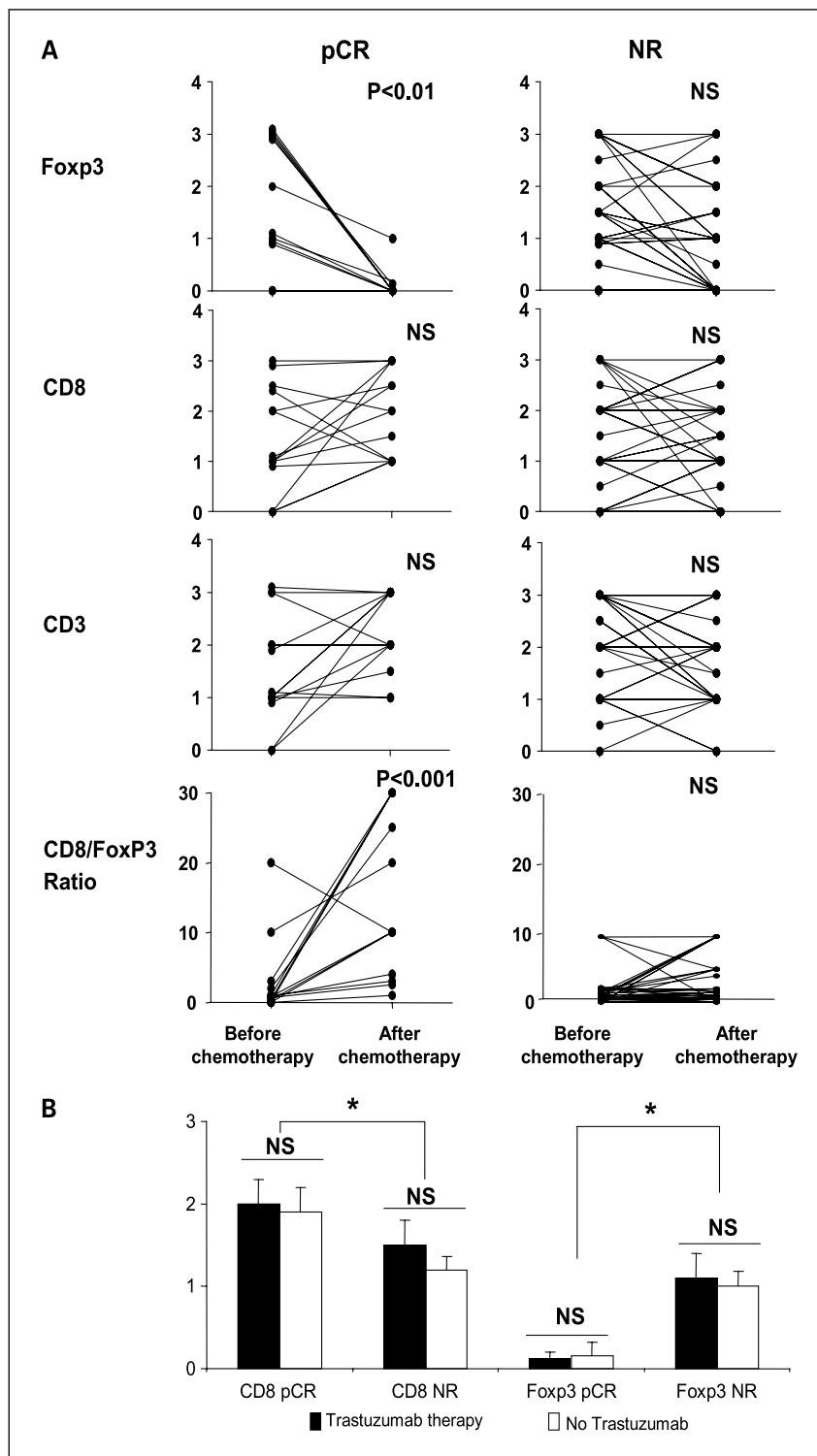
namely trastuzumab therapy or anthracycline-based therapy (Fig. 1C).

We assessed the association between T-cell infiltrates and classic prognostic factors. At the initial histologic examination, higher tumor grade, positive nodal status, and negative hormonal receptor expression were significantly associated with higher CD8 and Foxp3 infiltrates (Table 2A). At the final histo-

logic analysis, only high CD8 and CD3 infiltration remained associated with poor prognostic factors (Table 2B).

Altogether, these data suggest that high initial T-cell infiltrate, whatever the type (CD3, CD8, or Foxp3), was correlated with classic poor prognosis factor. Chemotherapy, whatever the regimen, has a specific effect on Foxp3 infiltrate and decrease the number of Foxp3 tumor-infiltrated cells.

**Fig. 2.** Evolution of the immune infiltrate according to histologic response. **A**, evolution of CD3<sup>+</sup>, CD8<sup>+</sup>, and Foxp3<sup>+</sup> tumor cell infiltration into breast tumor and evolution of CD8/Foxp3 ratio before and after neoadjuvant chemotherapy, according to the pathologic response (pCR  $n = 12$  or NR  $n = 44$ ). Whereas CD3 and CD8 infiltration levels remain stable in both pCR and NR patients, Foxp3 infiltration is decreased in pCR patients only. **B**, CD8<sup>+</sup> and Foxp3<sup>+</sup> tumor cell infiltration after neoadjuvant chemotherapy according to the pathologic response (pCR or NR), and according to the chemotherapeutic regimen (trastuzumab or no trastuzumab). Statistical analysis was done with the Mann-Whitney  $U$  test. \*,  $P \leq 0.05$ .



**Comparative analysis of pathologic complete responders and nonresponders.** Chemotherapy decreases Foxp3 immunosuppressive infiltrate but maintains CD8 effectors, arguing for a positive role of chemotherapy on local antitumor immunity. We hypothesized that if these immunologic modifications were involved in increased antitumor effects and better tumor prognosis, they would be associated with complete pathologic response on final surgical specimens.

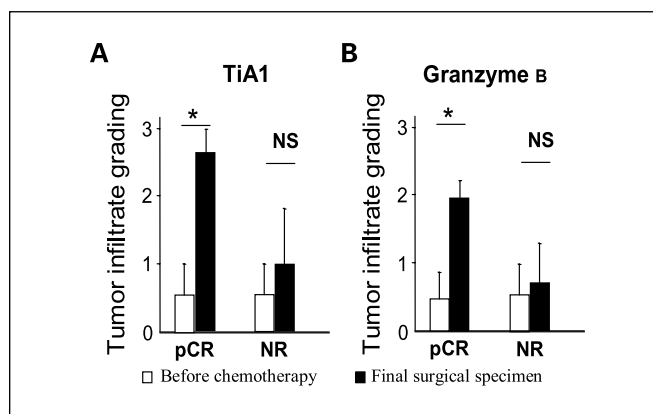
By univariate analysis, classic prognostic factors (high tumor grade and preoperative chemotherapy with trastuzumab) were found predictive of pCR (not shown).

Higher CD8 infiltrate before and after chemotherapy was associated with pCR ( $P = 0.037$  and  $P = 0.026$ , respectively). Foxp3 initial infiltrate was not predictive of pCR, but at the final histologic analysis, pCR patients had a significantly lower number of Foxp3 cells (and often none) than nonresponders (NR;  $P = 0.003$ ). Interestingly, trastuzumab therapy did not modify this observation, suggesting that final Foxp3 and CD8 infiltrate were associated with pCR regardless of the type of chemotherapy (Fig. 2B). Evolution of immune infiltrate dramatically differed between pCR and NR patients: pCR patients were characterized by disappearance of Foxp3 infiltrate and an increase of CD8/Foxp3 ratio, whereas NR patients had a stable level of Foxp3 cells and of the CD8/Foxp3 ratio (Fig. 2A). Indeed, in 11 of 12 patients with pCR, no Foxp3 cells were found in the final histologic sample, whereas only 19 of 44 poor responders were free of Foxp3<sup>+</sup> cell infiltrate at the same time point ( $P = 0.01$ ).

Finally, a combined immunologic criterion that associated grade 2 or more CD8 infiltrate and the absence of Foxp3 infiltrate on surgical specimens was found to be strongly associated with pCR and predicted pCR with a sensitivity of 75% and a specificity of 93%. None of the 13 patients considered as very poor responders (defined by a TD/ND or TD/NC or TC/ND Sataloff's score or Chevallier 4 on surgical specimen) featured this immunologic profile. Multivariate analysis confirmed that only histologic high grade, trastuzumab therapy, and the combined immunologic criterion were independent predictors of pCR (Table 3).

**Chemotherapy induces cytotoxic response in pCR patients.** Synthesis of cytolytic granules, which contain some toxic protein such as granzyme B, is critical for CD8<sup>+</sup> T-cell cytotoxic functions. TiA1 is also a 17 kDa cytoplasmic granule-associated protein expressed in cells possessing potential cytolytic activity (22). Therefore, to further characterize the effect of chemotherapy onto cytotoxic function of immune cells, we analyzed the T-cytotoxic response, assessed by expression of cytolytic granule-associated protein by infiltrating CD8<sup>+</sup> T in matched pCR and NR patient.

Whereas tumor infiltrates weakly expressed these proteins before chemotherapy, we observed a strong accumulation of



**Fig. 3.** Evolution of the cytotoxic immune infiltrate. Cytotoxic immune response characterized by accumulation of TiA1 and granzyme B – positive cells into breast tumor before and after chemotherapy in pCR ( $n = 5$ ) and NR patients ( $n = 5$ ). Statistical analysis was done with the Mann-Whitney  $U$  test. \*,  $P \leq 0.05$ .

granzyme B and TiA1-expressing cells after chemotherapy but only in pCR patient (Fig. 3). This observation supports the hypothesis that chemotherapy could induce cytotoxic immune response in pCR patients.

### Discussion

This study highlights the importance of the immune system in the prognosis of localized breast cancer and the interaction between chemotherapy and the immune system in this setting.

The presence of tumor-infiltrating T lymphocytes is considered as a marker of host immune response to tumor antigens, and has been shown to correlate with outcome in melanoma (23), prostate (24), renal cell (25), esophageal (26), colorectal (27), and ovarian carcinomas (8, 28). In ovarian cancer, Zhang et al. (8) reported that the presence of CD3<sup>+</sup> tumor-infiltrating T lymphocytes correlates with improved outcome, whereas Curiel et al. (14) underline the negative role of Treg cells among tumor-infiltrating T lymphocytes by demonstrating an inverse correlation between Treg cell infiltration in ovarian carcinoma and overall survival. In a recent study done on epithelial ovarian cancer, Sato et al. (28) showed that neither intra-epithelial CD3<sup>+</sup> nor Treg cell tumor-infiltrating T lymphocytes alone were associated with survival, but that a high intra-epithelial CD8<sup>+</sup>/Treg ratio, as in our study, was associated with improved outcome. Nevertheless, none of these studies focused on immune response induced by chemotherapy, and our study is the first to show that Foxp3 regulatory T-cell infiltration and Foxp3/CD8 ratio after neoadjuvant chemotherapy is strongly associated with pCR.

**Table 3.** Multivariate analyses (logistic regression) for patient pCR

Categories	HR (95% CI)	P	
Tumor grade	1 + 2 vs 3	19.9 (1.3-315.1)	0.03
Trastuzumab therapy	0 vs +	18.9 (1.2-308.7)	0.04
Combined immune variable	Foxp3 0 and CD8 $\geq 2$ vs Foxp3 >0 or CD8 <2	99.9 (5.8-1727.9)	0.0015

Abbreviations: HR, hazard ratio; 95% CI, 95% confidence interval.

As previously reported, we observed that breast tumors were highly infiltrated with CD8 and Foxp3 T cells compared with normal breast tissue (16, 29). Moreover, there was an association between aggressive phenotype and T-cell infiltration. These results are in line with those obtained by Bates (16) in a population of breast cancer patients treated by surgery followed by adjuvant treatment. In this study, only a high Treg infiltrate was associated with shorter survival, making it possible to identify patients at risk of relapse after 5 years. In our study, we showed that Treg infiltrate, and also CD8 infiltration, is associated with classic markers of poor prognosis in breast cancer.

In our patients, although CD3 and CD8 infiltrates remained stable during the treatment, the Foxp3 infiltrate strongly decreased, suggesting a higher sensitivity of Treg cells to the chemotherapeutic regimen than conventional T cells. These data are in line with our previous report demonstrating an elective cytotoxic effect of a cyclophosphamide metronomic regimen on Treg subset (30). Some other authors have shown the ability of paclitaxel and anthracycline to enhance antitumor immune response in mouse breast carcinoma model through Treg depletion (31).

Furthermore, we observed in our study a dichotomy between complete responders and other patients. Although the Foxp3 infiltrate remained stable in the NR patient, it was almost abolished in the pCR group. As trastuzumab could modify antitumor immune response (32), our results could be biased by the higher incidence of trastuzumab-treated patients in the pCR group. Nonetheless, we did not observe any difference in lymphocyte infiltrate between HER2-overexpressing tumors and other tumors. Moreover, the immunologic profiles of HER2-negative and HER2-overexpressing patients who achieved a pCR were similar, suggesting that immune reaction was not dependent on HER2 expression and trastuzumab treatment, but

depends more generally on the administration of chemotherapy. Perez et al. (18) showed that trastuzumab, but not other therapies, induced a decrease in Treg blood number in metastatic breast cancer patients with objective response. The discrepancy with our study may result from the difference in tumor stage and also from the anatomic compartment studied. In fact, Treg biology may change between blood Treg and tumor infiltration Treg.

The use of a combined criterion associating the absence of Foxp3 infiltrate with high CD8 infiltration reinforced our data. This combined criterion discriminates with a good sensitivity and specificity the pCR group from the NR group, suggesting that when chemotherapy is effective and eliminates the tumor, an associated immune response is present, mediated by CD8 T cells relieved from the control of immunosuppressive Foxp3 cells. These results suggest that chemotherapy induces an immune response in pCR patients that may enhance efficacy of the treatment. To confirm this hypothesis, we examined markers of T-cell cytotoxicity before and after the treatment. In this manner, we could determine that cytotoxic capacity of T cells is only enhanced in complete responders, when Treg cells have disappeared.

It is noteworthy that in this model of neoadjuvant chemotherapy in breast carcinoma, we confirm our previous data obtained in an adjuvant setting (5), which showed that the antitumor effect of chemotherapy is partially mediated by an immunologic effect.

In conclusion, we show here for the first time that an immunologic signature consisting of the absence of Foxp3 cells and the presence of a high number of CD8 T cells on final surgical biopsy of breast tumor treated by neoadjuvant chemotherapy is associated with pCR. Our data suggest that immunologic effects triggered by chemotherapy may participate in the complete remissions induced by the antitumor treatments.

## References

- Kuerer HM, Newman LA, Smith TL, et al. Clinical course of breast cancer patients with complete pathologic primary tumor and axillary lymph node response to doxorubicin-based neoadjuvant chemotherapy. *J Clin Oncol* 1999;17:460–9.
- Lake RA, van der Most RG. A better way for a cancer cell to die. *N Engl J Med* 2006;354:2503–4.
- Casares N, Pequignot MO, Tesniere A, et al. Caspase-dependent immunogenicity of doxorubicin-induced tumor cell death. *J Exp Med* 2005;202:1691–701.
- Obeid M, Tesniere A, Ghiringhelli F, et al. Calreticulin exposure dictates the immunogenicity of cancer cell death. *Nat Med* 2007;13:54–61.
- Apetoh L, Ghiringhelli F, Tesniere A, et al. Toll-like receptor 4-dependent contribution of the immune system to anticancer chemotherapy and radiotherapy. *Nat Med* 2007;13:1050–9.
- Lake RA, Robinson BW. Immunotherapy and chemotherapy—a practical partnership. *Nat Rev Cancer* 2005;5:397–405.
- Pages F, Berger A, Camus M, et al. Effector memory T cells, early metastasis, and survival in colorectal cancer. *N Engl J Med* 2005;353:2654–66.
- Zhang L, Conejo-Garcia JR, Katsaros D, et al. Intratumoral T cells, recurrence, and survival in epithelial ovarian cancer. *N Engl J Med* 2003;348:203–13.
- Sakaguchi S, Ono M, Setoguchi R, et al. Foxp3<sup>+</sup> CD25<sup>+</sup> CD4<sup>+</sup> natural regulatory T cells in dominant self-tolerance and autoimmune disease. *Immunol Rev* 2006;212:8–27.
- Fontenot JD, Gavin MA, Rudensky AY. Foxp3 programs the development and function of CD4<sup>+</sup>CD25<sup>+</sup> regulatory T cells. *Nat Immunol* 2003;4:330–6.
- Wolf AM, Wolf D, Steurer M, Gastl G, Gunsilius E, Grubeck-Loebenstien B. Increase of regulatory T cells in the peripheral blood of cancer patients. *Clin Cancer Res* 2003;9:606–12.
- Ormandy LA, Hillebrand T, Wedemeyer H, Manns MP, Gretten TF, Korangy F. Increased populations of regulatory T cells in peripheral blood of patients with hepatocellular carcinoma. *Cancer Res* 2005;65:2457–64.
- Woo EY, Chu CS, Goletz TJ, et al. Regulatory CD4(+)CD25(+) T cells in tumors from patients with early-stage non-small cell lung cancer and late-stage ovarian cancer. *Cancer Res* 2001;61:4766–72.
- Curjel TJ, Coukos G, Zou L, et al. Specific recruitment of regulatory T cells in ovarian carcinoma fosters immune privilege and predicts reduced survival. *Nat Med* 2004;10:942–9.
- Ichihara F, Kono K, Takahashi A, Kawaida H, Sugai H, Fujii H. Increased populations of regulatory T cells in peripheral blood and tumor-infiltrating lymphocytes in patients with gastric and esophageal cancers. *Clin Cancer Res* 2003;9:4404–8.
- Bates GJ, Fox SB, Han C, et al. Quantification of regulatory T cells enables the identification of high-risk breast cancer patients and those at risk of late relapse. *J Clin Oncol* 2006;24:5373–80.
- Ghiringhelli F, Menard C, Terme M, et al. CD4<sup>+</sup>CD25<sup>+</sup> regulatory T cells inhibit natural killer cell functions in a transforming growth factor- $\beta$ -dependent manner. *J Exp Med* 2005;202:1075–85.
- Perez SA, Karamouzis MV, Skarlos DV, et al. CD4<sup>+</sup>CD25<sup>+</sup> regulatory T-cell frequency in HER-2/neu (HER)-positive and HER-negative advanced-stage breast cancer patients. *Clin Cancer Res* 2007;13:2714–21.
- Chevallier B, Roche H, Olivier JP, Chollet P, Hurlteloup P. Inflammatory breast cancer. Pilot study of intensive induction chemotherapy (FEC-HD) results in a high histologic response rate. *Am J Clin Oncol* 1993;16:223–8.
- Sataloff DM, Mason BA, Prestipino AJ, Seinige UL, Lieber CP, Baloch Z. Pathologic response to induction chemotherapy in locally advanced carcinoma of the breast: a determinant of outcome. *J Am Coll Surg* 1995;180:297–306.
- Black MM, Speer FD, Opler SR. Structural representations of tumor-host relationships in mammary carcinoma; biologic and prognostic significance. *Am J Clin Pathol* 1956;26:250–65.
- Anderson P. TIA-1: structural and functional studies on a new class of cytolytic effector molecule. *Curr Top Microbiol Immunol* 1995;198:131–43.
- Ladanyi A, Somlai B, Gilde K, Fejos Z, Gaudi I, Timar J.

- T-cell activation marker expression on tumor-infiltrating lymphocytes as prognostic factor in cutaneous malignant melanoma. *Clin Cancer Res* 2004;10:521–30.
24. Vesalainen S, Lipponen P, Talja M, Syrjanen K. Histological grade, perineural infiltration, tumour-infiltrating lymphocytes and apoptosis as determinants of long-term prognosis in prostatic adenocarcinoma. *Eur J Cancer* 1994;30A:1797–803.
25. Nakano O, Sato M, Naito Y, et al. Proliferative activity of intratumoral CD8(+) T-lymphocytes as a prognostic factor in human renal cell carcinoma: clinicopathologic demonstration of antitumor immunity. *Cancer Res* 2001;61:5132–6.
26. Schumacher K, Haensch W, Roefzaad C, Schlag PM. Prognostic significance of activated CD8(+) T cell infiltrations within esophageal carcinomas. *Cancer Res* 2001;61:3932–6.
27. Naito Y, Saito K, Shiiba K, et al. CD8<sup>+</sup> T cells infiltrated within cancer cell nests as a prognostic factor in human colorectal cancer. *Cancer Res* 1998;58:3491–4.
28. Sato E, Olson SH, Ahn J, et al. Intraepithelial CD8<sup>+</sup> tumor-infiltrating lymphocytes and a high CD8<sup>+</sup>/regulatory T cell ratio are associated with favorable prognosis in ovarian cancer. *Proc Natl Acad Sci U S A* 2005;102:18538–43.
29. Liyanage UK, Moore TT, Joo HG, et al. Prevalence of regulatory T cells is increased in peripheral blood and tumor microenvironment of patients with pancreas or breast adenocarcinoma. *J Immunol* 2002;169:2756–61.
30. Ghiringhelli F, Menard C, Puig PE, et al. Metronomic cyclophosphamide regimen selectively depletes CD4<sup>+</sup>CD25<sup>+</sup> regulatory T cells and restores T and NK effector functions in end stage cancer patients. *Cancer Immunol Immunother* 2007;56:641–8.
31. Machiels JP, Reilly RT, Emens LA, et al. Cyclophosphamide, doxorubicin, and paclitaxel enhance the antitumor immune response of granulocyte/macrophage-colony stimulating factor-secreting whole-cell vaccines in HER-2/neu tolerized mice. *Cancer Res* 2001;61:3689–97.
32. Arnould L, Gelly M, Penault-Llorca F, et al. Trastuzumab-based treatment of HER2-positive breast cancer: an antibody-dependent cellular cytotoxicity mechanism? *Br J Cancer* 2006;94:259–67.