

Efficacy of Vemurafenib in a Trametinib-Resistant Stage IV Melanoma Patient – Letter

Mathias Bernhardt^{1,2}, Elias Orouji^{1,2}, Lionel Larr이버^{1,2}, Christoffer Gebhardt^{1,2}, and Jochen Utikal^{1,2}

Targeted treatment of *BRAF* gene-mutated melanoma with *BRAF* and *MEK* inhibitors has prolonged progression-free and overall survival (1, 2). Several mechanisms of

resistance to *BRAF* and *MEK* inhibition treatment have been described, most of which involve reactivation of downstream *MAP-ERK* kinase/extracellular signal-regulated

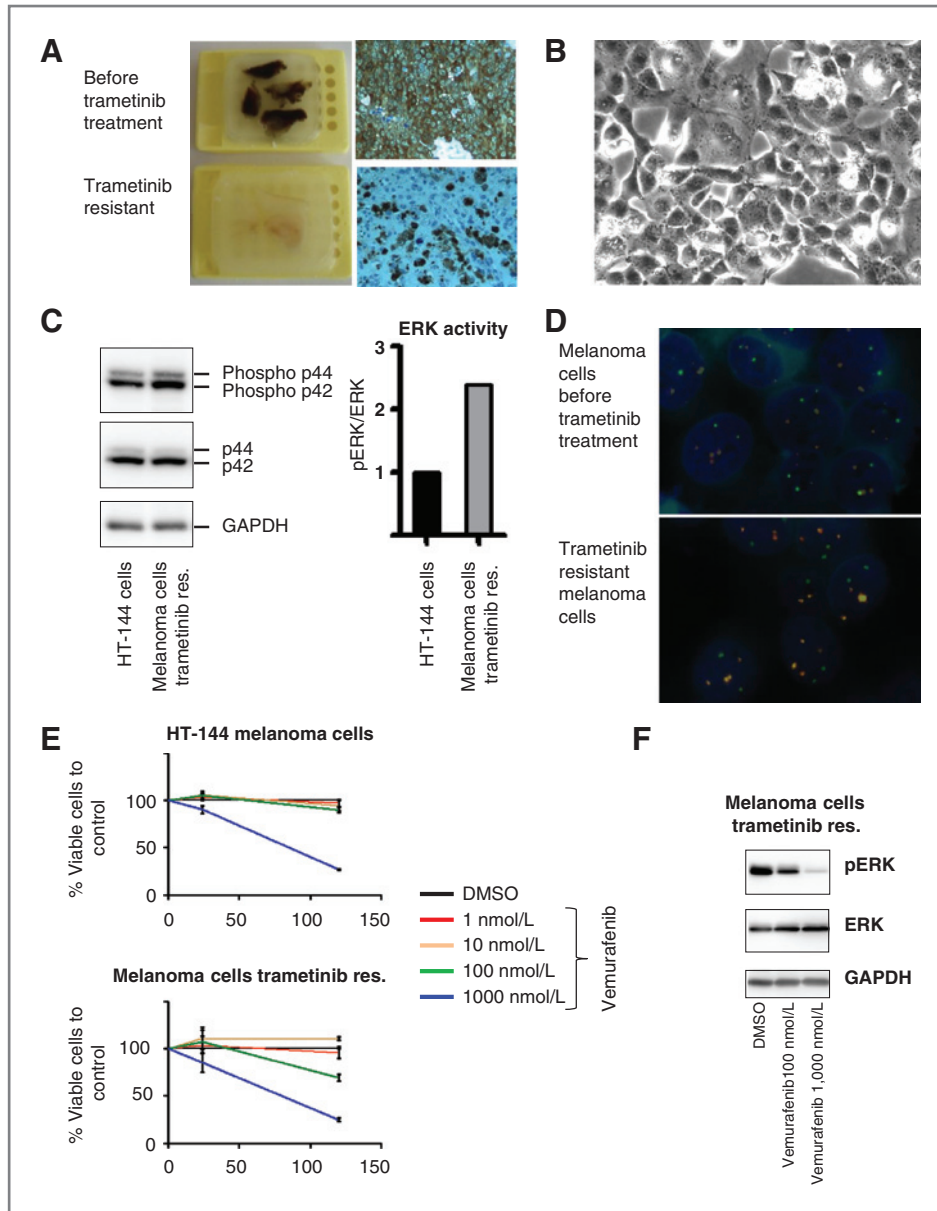


Figure 1. A, paraffin-embedded biopsies of melanoma metastases taken before (top) and after treatment with trametinib (bottom). S100B expression is low in dedifferentiated trametinib-resistant tumor cells. B, melanoma cell line established from a trametinib-resistant subcutaneous metastasis. C, strong pERK activity measured by Western blot analysis in trametinib-resistant tumor cells (in comparison with treatment-naïve *BRAF* V600E-mutated HT144 melanoma cells). D, FISH shows no gain of *BRAF* gene copy numbers after trametinib treatment (green signals, *BRAF* gene locus (7q34); orange signals, centromeric 7 reference probe). E, efficacy of vemurafenib in trametinib-resistant melanoma cells similar to naïve V600E-mutated HT144 melanoma cells in the AlamarBlue cell proliferation assay. F, Western blot analysis showing a decrease of phosphoERK expression after vemurafenib administration in trametinib-resistant melanoma cells. DMSO, dimethyl sulfoxide; GAPDH, glyceraldehyde-3-phosphate dehydrogenase.

Authors' Affiliations: ¹Skin Cancer Unit, German Cancer Research Center (DKFZ), Heidelberg and ²Department of Dermatology, Venereology and Allergology, University Medical Center Mannheim, Ruprecht-Karl University of Heidelberg, Mannheim, Germany

Note: Supplementary data for this article are available at Clinical Cancer Research Online (<http://clincancerres.aacrjournals.org/>).

Corresponding Author: Jochen Utikal, Skin Cancer Unit, German Cancer Research Center (DKFZ) Theodor-Kutzer-Ufer 1-3 Mannheim 68135, Germany. Phone: 49-621-383-4461; Fax: 49-621-383-3815; E-mail: jochen.utikal@umm.de

doi: 10.1158/1078-0432.CCR-13-2349

©2014 American Association for Cancer Research.

kinase (MEK/ERK) signaling (3). Thus, BRAF-inhibitor resistance mechanisms would be expected to confer resistance to downstream MEK inhibitor (4). The outcome of an upstream inhibition of the signaling pathway is elusive in which an MEK inhibitor is followed by a BRAF inhibitor (5).

Here, we report on a 43-year-old male Caucasian patient with BRAF V600E-mutated stage IV melanoma who was treated successfully for 10 months with the MEK inhibitor trametinib. Under this treatment, metastases in lung, lymph nodes, and subcutaneous tissue were regressive. However, tumor cells became resistant indicated by fast progressive disease with new brain and dedifferentiated subcutaneous metastases (Fig. 1A). A cell line established from trametinib-resistant melanoma cells (Fig. 1B) showed high levels of ERK and pERK, suggesting still a strong activity of the BRAF/MEK/ERK signaling pathway (Fig. 1C). We could not detect mutations in the coding sequence of MEK1 (MEK2 was not transcriptionally expressed) that may inhibit the binding-site of trametinib and thus might explain the activation of the pathway. To exclude amplification of gene copy numbers of genes involved in the BRAF/MEK/ERK signaling pathway resulting in a higher transcriptional activity, we performed FISH experiments with gene locus-specific probes (Fig. 1D and Supplementary Table S1). However, no amplification of these gene loci in trametinib-resistant

cells could be seen, suggesting other transcriptional mechanisms explaining the trametinib resistance.

In search for a potential treatment option for our patient, we tested viable melanoma cells (Fig. 1B) *in vitro* for potential targeted therapies. We could detect still a strong inhibition of cell growth and pERK levels with the BRAF inhibitor vemurafenib (Fig. 1E and F). This prompted us to treat our patient with vemurafenib 480 mg twice per day. One week after induction of vemurafenib treatment, the symptoms of the patient ameliorated (ECOG2 improved to ECOG0) and tumor masses regressed (Supplementary Fig. S1). Unfortunately, treatment with vemurafenib had to be interrupted after 1 month due to grade 3 tachycardia and heart toxicity and the patient died 2 months later.

This case shows that upstream sequential treatment with a BRAF-inhibitor might be still efficient in MEK inhibitor-resistant patients with melanoma. Besides the sequential administration shown here, intermittent administration also should be studied further.

Disclosure of Potential Conflicts of Interest

J. Utikal is consultant/advisory board member for and has received speakers bureau honoraria from Roche and MSD. No potential conflicts of interest were disclosed by the other authors.

Received August 28, 2013; revised October 23, 2013; accepted November 18, 2013; published online May 1, 2014.

References

1. Flaherty KT, Robert C, Hersey P, Nathan P, Garbe C, Milhem M, et al. Improved survival with MEK inhibition in BRAF-mutated melanoma. *N Engl J Med* 2012;367:107–14.
2. Flaherty KT, Infante JR, Daud A, Gonzalez R, Kefford RF, Sosman J, et al. Combined BRAF and MEK inhibition in melanoma with BRAF V600 mutations. *N Engl J Med* 2012;367:1694–703.
3. Romano E, Pradervand S, Paillusson A, Weber J, Harshman K, Muehlethaler K, et al. Identification of multiple mechanisms of resistance to vemurafenib in a patient with BRAFV600E-mutated cutaneous melanoma successfully rechallenged after progression. *Clin Cancer Res* 2013;19:5749–57.
4. Kim KB, Kefford R, Pavlick AC, Infante JR, Ribas A, Sosman JA, et al. Phase II study of the MEK1/MEK2 inhibitor Trametinib in patients with metastatic BRAF-mutant cutaneous melanoma previously treated with or without a BRAF inhibitor. *J Clin Oncol* 2013;31:482–9.
5. Goldinger SM, Murer C, Stieger P, Dummer R. Upstream MAPK pathway inhibition: MEK inhibitor followed by a BRAF inhibitor in advanced melanoma patients. *Eur J Cancer* 2014;50:406–10.