

New Intra-arterial Drug Delivery System for the Treatment of Liver Cancer: Preclinical Assessment in a Rabbit Model of Liver Cancer

Kelvin Hong, Afsheen Khwaja, Eleni Liapi, Michael S. Torbenson, Cristos S. Georgiades and Jean-Francois H. Geschwind

Abstract **Background:** In the fight against cancer, new drug delivery systems are attractive to improve drug targeting of tumors, maximize drug potency, and minimize systemic toxicity. We studied a new drug delivery system comprising microspheres, with unique properties allowing delivery of large amounts of drugs to tumors for a prolonged time, thereby decreasing plasma levels. Liver tumors, unlike nontumorous liver, draw most of their blood supply from the hepatic artery. Exploiting this property, we delivered drug-eluting microspheres/beads (DEB) loaded with doxorubicin, intra-arterially, in an animal model of liver cancer (Vx-2).

Purpose: The purpose of our study was to determine the pharmacokinetics and tumor-killing efficacy of DEB.

Results: Our results show that plasma concentration of doxorubicin was minimal in the animals treated with DEB at all time points (0.009-0.05 $\mu\text{mol/L}$), suggesting high tumor retention of doxorubicin. This was significantly lower (70-85% decrease in plasma concentration) than control animals treated with doxorubicin intra-arterially. Within the tumor, doxorubicin concentration peaked at 3 days (413.5 nmol/g), remaining high to 7 days (116.7 nmol/g) before declining at 14 days (41.76 nmol/g), indicating continuous doxorubicin elution from beads. In control animals, peak tumor concentration of doxorubicin was 0.09 nmol/g. Tumor necrosis (approaching 100%) was greatest at 7 days, with minimal adverse local side effects reflected in liver function tests results. The plasma concentration of doxorubicinol (doxorubicin main metabolite) was minimal.

Conclusions: Our results support the concept of DEBs as an effective way to deliver drugs to tumor. This new technology may prove to be a useful weapon against liver cancer.

Regional intra-arterial infusion therapy is often used clinically in patients with primary and secondary tumors of the liver (1-3), because liver tumors, unlike healthy liver tissue, are supplied almost exclusively by hepatic arterial flow (2-4). The basic assumption is that higher tumor drug levels can be achieved by hepatic artery infusion, thus reducing systemic circulation exposure and in turn decreasing toxicity (5-7). Tumor extraction of doxorubicin or 5-fluorouracil by cancer cells has been reported to be higher after hepatic artery infusion than with systemic or portal vein infusion (5, 6, 8-12). The concept of exploiting the hepatic arterial

route to liver tumors is extremely attractive and is commonly used to treat patients with unresectable liver cancer (2, 13, 14). Transcatheter arterial chemoembolization (TACE) involves the emulsification of chemotherapeutic agent in an oily medium, used in this case as a drug carrier, and delivered intra-arterially to liver tumors for maximum effect. The purpose of the embolization is to reduce arterial inflow, diminish washout of the chemotherapeutic agents, and prolong contact time between cancer cells and the chemotherapeutic agents (7). These factors combine to significantly reduce systemic toxicity. Yet, despite evidence of some clinical success with TACE, the search for more effective drug delivery systems persists. A new type of microsphere with drug-eluting capabilities may offer the possibility of a precise controlled release of the chemotherapeutic agent into the tumor bed. These microspheres or beads alleviate the need for an oil/chemotherapy suspension as well as an additional embolization step and can be administered intra-arterially in the same exact manner as with TACE. The potential benefits of such beads are considerable because a sustainable release of chemotherapy over time could have a greater effect on tumor kill. In addition, because the amount of chemotherapy loaded into the beads can be controlled, a more precise dose of chemotherapy can be delivered to the tumor. Our study was designed to evaluate the improved pharmacokinetic profile and efficacy (tumor kill) of such a new type of drug delivery

Authors' Affiliation: Division of Vascular and Interventional Radiology, Johns Hopkins Medical Institutions, Baltimore, Maryland
Received 10/11/05; revised 12/27/05; accepted 2/3/06.

Grant support: Biocompatibles, Inc.

The costs of publication of this article were defrayed in part by the payment of page charges. This article must therefore be hereby marked *advertisement* in accordance with 18 U.S.C. Section 1734 solely to indicate this fact.

Note: Presented at the 91st Scientific Assembly and Annual Meeting Radiological Society of North America and at the 2005 Annual Meeting, American Society of Clinical Oncology, Gastrointestinal Symposium.

The authors have no potential conflicts of interest.

Requests for reprints: Jean-Francois H. Geschwind, Interventional Radiology, The Johns Hopkins Hospital, 600 North Wolfe Street, Blalock 545, Baltimore, MD 21287. Phone: 410-614-6597; Fax: 410-955-0233; E-mail: jfg@jhmi.edu.

© 2006 American Association for Cancer Research.

doi:10.1158/1078-0432.CCR-05-2225

system consisting of drug-eluting beads (DEB) loaded with doxorubicin compared with other conventional treatments when delivered intra-arterially in a rabbit model of liver cancer (Vx-2).

Materials and Methods

Animal model and tumor implantation. Our institution's Animal Care Committee approved the study, and experiments were done in accordance with institutional guidelines. For our purpose, which was to study a new drug delivery system in liver tumors, the rabbit Vx-2 tumor model, a known model of hypervascular tumor (15), was selected for implantation in the liver because of the similarities of its blood supply to that of human liver tumors. Other attributes of this tumor model include rapid growth and development of a sizable tumor (typically within 10-14 days) that can be readily identifiable as a hypervascular tumor during diagnostic angiography. The rabbit is also large enough that selective catheter manipulation in the hepatic artery from access through the common femoral artery is feasible (15).

Adult New Zealand White rabbits weighing 3.5 to 4.2 kg ($n = 50$; Myrtle's Rabbitry, Thompson Station, TN) were used. For successful implantation of the Vx-2 tumor into the liver, the tumor was first grown for 2 weeks on the hind leg of a carrier rabbit. Each carrier rabbit was used to supply tumor cells for implantation into the left lobe of the liver of two separate rabbits. All the rabbits, carriers and recipients, were anesthetized with a mixture of acepromazine (2.5 mg/kg; Phoenix, St. Joseph, MO) and ketamine hydrochloride (44 mg/kg; Phoenix) administered i.m.; i.v. access was gained via a marginal ear vein and sodium pentobarbital (Abbott Laboratories, Abbott Park, IL) was given i.v. to maintain anesthesia. The abdomen of each rabbit was shaved and prepped with povidine iodine. The liver was exposed with a midline subxiphoid incision, and clumps of tumor cells (0.1-0.2 mL) from the harvested minced tumors were implanted directly into the left lobe of the exposed liver of recipient rabbits using a 21-gauge angiocatheter. This method allows the growth of a single, solitary, well-demarcated tumor in the liver of each recipient rabbit. The abdomen was closed in two layers, and proper aseptic technique was rigorously observed during each implantation. After surgery, the animals were placed in cages and monitored in the animal laboratory under direct supervision of a physician or a technician until they recovered from anesthesia. Analgesic buprenorphine (0.02-0.05 mg/kg) was administered i.m. for pain or distress. The tumors were allowed to grow for another 10 to 14 days, at which time they reached an ellipsoidal shape with dimensions ranging between 2.5 and 3.5 cm (15).

Preparation of DEBs. The embolization beads used in this study were composed of a sulfonate-modified poly(vinyl alcohol) hydrogel that has the capability of interacting with therapeutic agents (16). More specifically, these beads were prepared by the reverse suspension

polymerization of a methacryloyl-modified polyvinyl alcohol macromer, synthesized by the reaction of polyvinyl alcohol with *N*-acrylamido-aminoacetaldehyde followed by copolymerization with 2-acrylamido-2-methylpropane sulfonate by free radical polymerization. The beads were sorted into size ranges using calibrated sieves. Bland beads (100-300 μm) used in one of the control arms were supplied hydrated in PBS (denoted GS in our study). Doxorubicin-loaded beads (100-300 μm) contained 45 mg drug/g wet beads and were supplied lyophilized and hydrated in saline before use.

Experimental protocol. Table 1 details the various arms of the study. New Zealand White rabbits ($n = 42$) were divided into six groups of seven animals each (five study animals and two controls). Study animals were treated with an intra-arterial injection of the DEB, whereas control animals received an intra-arterial injection of doxorubicin (IA) alone (without the microspheres) at the same concentration as the test animals (11.25 mg). The animals were sacrificed at six different time points corresponding to the six treatment groups at 1, 12, and 24 hours and 3, 7, and 14 days, respectively. Another eight animals were divided into two groups of four animals each and were treated with either an intra-arterial injection of doxorubicin followed by bland beads (IA + GS group), or with the classic TACE protocol used in our clinical practice (lipiodol, doxorubicin, and bland beads: TACE group; ref. 7). Animals in these two groups were sacrificed 3 and 7 days after treatment and were used as controls for the study animals sacrificed at the same time points (3 and 7 days after treatment with DEB). Note that blood samples (plasma) were collected at 20, 40, 60, 120, and 180 minutes after treatments in all animal groups to determine pharmacokinetics and liver function.

Intra-arterial administration of DEB and TACE procedure. Preanesthetics were administered, and anesthesia was carried out as described above. Transcatheter hepatic artery administration of the DEB was done under fluoroscopy. The animals were brought to the angiography suite and intubated using a size 3.0-mm endotracheal tube (Mallinkrodt Medical, St. Louis, MO) but not ventilated. Surgical cut down was done to gain access into the common femoral artery, after which a 4-French sheath (Cook, Inc., Bloomington, IN) was placed. A specially manufactured 2-French catheter with a tip in the shape of a hockey stick (JB1 catheter; Cook) was manipulated into the celiac axis, after which a celiac arteriogram was done to delineate the blood supply to the liver and confirm the location of the tumor. The tumor could readily be visualized as a region of hypervascular blush located on the left side of the liver near the gastric fundus. The left hepatic artery, which nearly exclusively provided flow to the tumor, was then selectively catheterized off the common hepatic artery with the aid of a steerable guide wire (0.010-0.014 in. Transsend wire; Boston Scientific Oncology, Natick, MA). After having ensured adequate positioning of the catheter, the DEB or various treatments used for the control animals were carefully infused directly into the artery. After completion of the infusion, the catheter was removed, and the common femoral artery

Table 1. Study group design and time points of animal sacrifice

Time of sacrifice	Groups 1-6 (each $n = 7$)		TACE ($n = 4$)	IA + bland beads ($n = 4$)
	IA ($n = 5$)	Control ($n = 2$)		
1 h	X	X	—	—
12 h	X	X	—	—
24 h	X	X	—	—
3 d	X	X	X	X
7 d	X	X	X	X
14 d	X	X	—	—

Abbreviations: IA, intra-arterial doxorubicin; TACE, transcatheter arterial chemoembolization; IA+ bland beads, intra-arterial doxorubicin and bland beads (microspheres).

was ligated using resorbable suture material to obtain hemostasis. The animals were returned to cages and followed-up daily until their respective times of sacrifice.

Test and control infusions. Vials of lyophilized DEB (sizes range, 100-300 μm) were hydrated in 1 mL of sterile water, to which 2 mL of Omnipaque contrast media (Amersham, Piscataway, NJ) and 1 mL of saline were added. In each test rabbit, 1 mL of the total solution (containing ~ 11.25 mg doxorubicin in DEB) was injected intra-arterially. Control arm animals received either infusion of doxorubicin alone (IA; same concentration, ~ 11.25 mg doxorubicin), or doxorubicin followed by 1 mL (300-500 μm bland spheres; IA + GS), or with doxorubicin emulsified in lipiodol oil (ethiodol; Savage Laboratories, Melville, NY) followed by plain spheres (TACE).

Pharmacokinetics for doxorubicin and doxorubicinol. Doxorubicinol is the main metabolite during the breakdown of doxorubicin. Whole blood (3 mL) was collected at 20, 40, 60, 120, and 180 minutes after treatments via a catheter inserted in an ear vein in all animal groups. Analysis was done via liquid chromatography-tandem mass spectrometry. Blood samples were also collected to determine liver function (liver function test).

Euthanasia and necropsy. Animals were sacrificed under deep anesthesia by i.v. injections of 100 mg/kg of thiopental i.v. at 1, 12, and 24 hours, 3, 7, and 14 days. Necropsy was done on all animals. Rabbit livers were dissected, carefully removed, and placed in a container containing 5% formaldehyde. Five-millimeter slices were taken for gross examination. Each section was embedded completely in paraffin, after which 4- μm slices were treated with H&E stain. Tumor viability was estimated by visual inspection and expressed as a percentage of viable tumor area for each slice. The tumors were removed from the liver and where possible dissected into two equal halves. One half was then submitted for doxorubicin analysis by mass spectroscopy, and the other half was submitted for histologic evaluation. Nontumor liver tissue (~ 100 mg) was also excised and analyzed in a manner similar to that described above.

Statistical analysis. The pharmacokinetics and mean fractions of necrosis \pm SD were compared using Student's *t* test for between-group comparisons and paired Student's *t* test for within-group comparisons. Differences were considered statistically significant for $P < 0.05$.

Results and Discussion

Pharmacokinetics doxorubicin and doxorubicinol. The peak in plasma doxorubicin concentration occurred at ~ 20 minutes for all groups, with near return to baseline after 3 hours (Fig. 1A). The level of doxorubicin when administered through the DEB was low at all time points (0.009-0.05 $\mu\text{mol/L}$). More importantly, peak plasma concentration of doxorubicin was significantly lower when administered with the DEB than intra-arterially without the DEB (82% reduction). The difference in plasma doxorubicin concentration between the DEB and the IA groups was statistically significant at 20, 40, and 60 minutes ($P = 0.015, 0.037,$ and $0.035,$ respectively). Note that the peak plasma concentration of doxorubicin with the DEB was also lower than that of conventional TACE but did not reach statistical significance. The pharmacokinetic profile of doxorubicinol in all the control groups (IA alone, IA + GS, and TACE) mirrored that of doxorubicin (Fig. 1B), with an initial sharp increase followed by a decline over time. This indicates rapid degradation of doxorubicin and doxorubicinol because both compounds are actively metabolized in the systemic circulation. In contrast, the pharmacokinetic profile in the DEB group was vastly different with a steady increase in doxorubicinol concentration over the time studied. This steady increase in doxorubicinol combined with a decrease in plasma doxorubi-

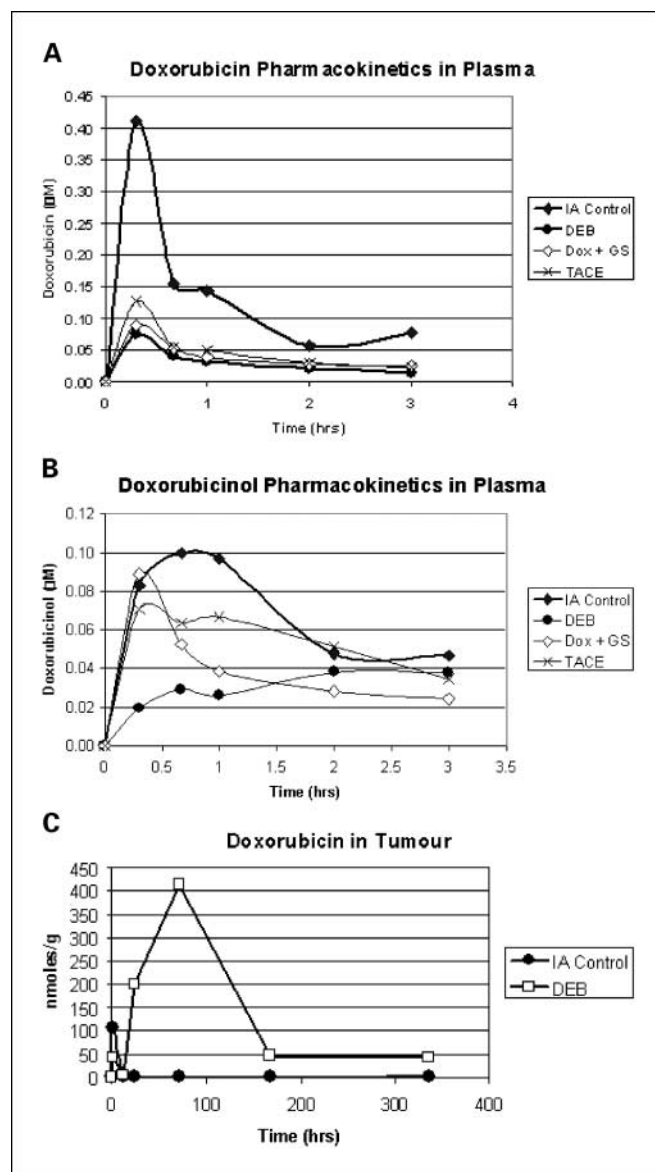


Fig. 1. A, pharmacokinetics of doxorubicin concentrations in plasma. B, pharmacokinetics doxorubicinol concentrations in plasma. C, doxorubicin levels in explanted liver tumor.

cin levels as uniquely shown in the DEB group supports the theory of continuous drug elution over time from the microspheres delivered to the tumor. As doxorubicin is released from the microspheres within the tumor, it is slowly degraded into doxorubicinol, which is then released systemically. This, therefore, explains the steady increase in plasma doxorubicinol levels over time (Fig. 1A and B). These results, therefore, support the slow drug release properties of the DEB within the tumor and confirm the theoretical benefit of a reduced systemic exposure to chemotherapy.

Doxorubicin in tumor and normal tissue. The presence of doxorubicin in the tumor and nontumorous liver tissue was measured to assess the deliverability of doxorubicin from the DEB to a target site (Fig. 1C). In the DEB group, the greatest concentration of doxorubicin within the tumor was obtained at 3 days posttreatment (413.5 nmol/g) and remained high at

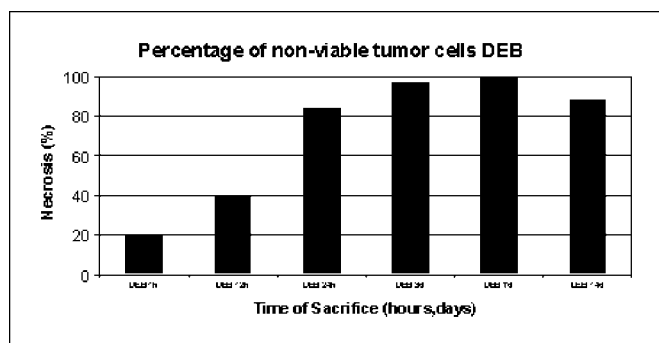


Fig. 2. Tumor necrosis and damage for DEB and controls IA and TACE groups.

7 days (116.7 nmol/g) and even 14 days (41.76 nmol/g), suggesting continuous elution of doxorubicin from the beads (Fig. 2). In contrast, the concentration of doxorubicin in the tumor was nearly undetectable at all time points when administered IA (ranged from a peak of 100 nmol/g immediately after injection to 0 nmol/g within 1 hour of injection). Tumor doxorubicin concentration was also low in the IA + GS (5-25 nmol/g) and TACE (12-36 nmol/g) groups, although not as low as the IA group. In nontumorous liver tissue, doxorubicin levels did not surpass 31 nmol/g and were lower in the DEB (range, 2-17 nmol/g) than the IA (range, 0-31 nmol/g) or other control groups over the 14-day period. These results clearly show that doxorubicin slowly eluted out of the microspheres into the tumor to reach a maximal peak concentration 3 days after treatment. By eluting out of the microspheres in a loco-regional fashion, chemotherapeutic agents can become concentrated within the tumor bed, maximizing their potency and minimizing their systemic toxicities.

Tumor necrosis. In the DEB group, tumor necrosis was minimal 1 hour after treatment and greatest at 7 days after therapy. Note that complete tumor destruction was shown only in the DEB group, and it occurred in those animals sacrificed 7 days after treatment (Fig. 2). The relationship between the degree of tumor destruction and the “dwell” time of the DEBs in the tumor was nearly linear. It took time for the doxorubicin to elute out of the microspheres and concentrate in sufficient amounts within the tumor bed to kill most of the tumor cells. Here, we should note that animals in all groups were treated with the same amount of DEBs (i.e., same amount of embolization beads). Therefore, the difference in tumor necrosis could only be explained by the amount of doxorubicin that had eluted out of the beads and not by the mechanical effects of the beads on blood flow (i.e., disturbance of tumor blood supply). Histology sections taken at various time points illustrate this phenomenon (Figs. 3 and 4). This drug delivery system is unique because it allowed slow elution of doxorubicin into the tumor over at least 14 days (we did not obtain measurements beyond that time point), in turn increasing the concentration of doxorubicin within the tumor. In the end, the concentration of doxorubicin was such that cancer cells could no longer survive in this environment. Our results again support the concept of DEB as it proved to have a potent cytotoxic effect on the tumor. This effect could not be explained by the embolization alone because stasis within the tumor feeding vessel was never achieved during any

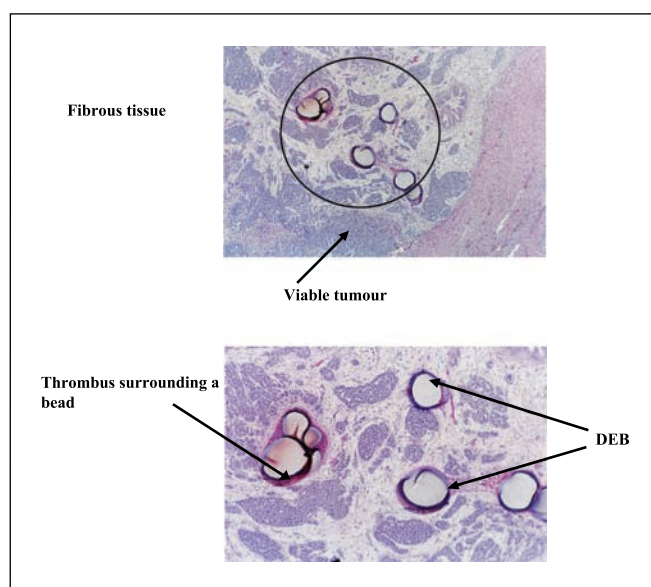


Fig. 3. Tumor tissue from an animal treated with DEB, sacrificed at 1 hour. Several DEBs are seen surrounded by viable tumor tissue. The drug is still contained within the microspheres, resulting in viable cancer cells.

of the experiments. In contrast, tumor necrosis in the various control groups did not exceed 35% except in the TACE group where it reached 90% in the animals sacrificed 3 days posttreatment. Here, we should note that because of its rapid growth, the Vx-2 tumor exceeds its blood supply within 7 to 10 days of implantation in the liver, resulting in a 30% to 40% baseline level of tumor necrosis. Although concentration of doxorubicin within the tumor was significantly less in the TACE than in the DEB group, the fraction of tumor necrosis was nearly identical at day 3 but less at day 7. This potent effect of TACE has been described in an earlier report and is

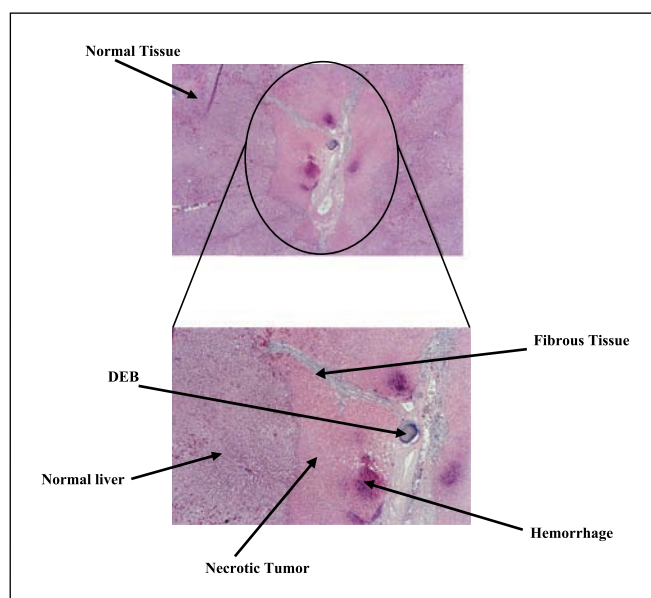


Fig. 4. Tumor tissue from an animal treated with DEB, sacrificed at 3 days. A DEB is seen surrounded by necrotic tumor tissue and viable cells located beyond the tumor capsule in the healthy liver tissue. The drug has mostly left the microspheres to concentrate within the tumor resulting in total destruction of the tumor.

likely the result of cytotoxic effects of both the lipiodol, in which the chemotherapeutic agent is suspended, as well as the embolic material on cancer cells (7). Although such tumor destruction following TACE seems to be beneficial, in reality, it may be detrimental clinically because the embolization effects on tumor blood flow prevents retreatment secondarily to occlusion or stasis of the main tumor-feeding vessel. This very issue is another advantage of the DEBs because impairment of flow of the main tumor feeding vessels was not encountered in our study.

Liver function tests. Measuring liver enzymes after loco-regional liver therapy provides key information about the general state of liver function. It is common clinically for liver enzymes to increase transiently following TACE, peaking at 24 to 36 hours before returning to baseline after 5 to 7 days. As expected, in the DEB group, we found all three liver enzymes (aspartate aminotransferase, alkaline phosphatase, and alanine aminotransferase) to increase transiently reaching a peak between 10 and 70 hours posttreatment before returning to baseline within 7 days of therapy (data not shown). The IA group had a similar profile but was generally less pronounced (lower peak values than that of the DEB group) and exhibited a more rapid return to baseline than the DEB group. Interestingly, albumin levels (marker of liver synthetic function) remained within reference range throughout in the DEB group. Finally, total bilirubin levels (marker for liver metabolic function) were slightly higher in the DEB (0.1-0.15 mg/dL) than the IA group

(0.1-0.12 mg/dL). Taken together, these results show that DEB therapy caused minimal transient elevation of liver enzymes (not significantly different than those encountered clinically after TACE), without significant compromise of liver function. None of the animals treated with the DEB showed any clinical side effects as a result of therapy, such as lack of appetite or loss of urination.

In summary, the results of our study provide clear supportive evidence for the concept of loco-regional drug delivery. This new drug delivery system proved to be extremely potent by allowing large amounts of chemotherapy to concentrate within the tumor over time, thereby maximizing the cytotoxic effect of the agent without causing more systemic toxicities. Rather, the pharmacokinetic profile provided by this new drug delivery system was more favorable than that of a more classic direct IA injection. Furthermore, combination of IA and embolization with bland beads resulted in minimal effect on tumor destruction (similar in fact to IA treatment alone), indicating that physical occlusion of the feeding vessels without the sustained delivery of the drug was not as effective in this model. Comparison of the effects of DEB versus conventional TACE showed that the DEB produced higher levels of drug in the tumor and maintained a greater degree of necrosis out to day 7. Taken together, the increased antitumor effect and the reduced systemic toxicity of this new drug delivery system may provide a tremendous clinical benefit in patients suffering from liver cancer.

References

1. Komorizono Y, Oketani M, Sako K, et al. Risk factors for local recurrence of small hepatocellular carcinoma tumors after a single session, single application of percutaneous radiofrequency ablation. *Cancer* 2003;97:1253-62.
2. Lo CM, Ngan H, Tso WK, et al. Randomized controlled trial of transarterial lipiodol chemoembolization for unresectable hepatocellular carcinoma. *Hepatology* 2002;35:1164-71.
3. Chamberlain MN, Gray BN, Heggie JC, et al. Hepatic metastases: a physiological approach to treatment. *Br J Surg* 1983;70:596-8.
4. Stribley KV, Gray BN, Chmiel RL, et al. Internal radiotherapy for hepatic metastases II: the blood supply to hepatic metastases. *J Surg Res* 1983;34:25-32.
5. Ridge JA, Collin C, Bading JR, et al. Increased Adriamycin levels in hepatic implants of rabbit Vx-2 carcinoma from regional infusion. *Cancer Res* 1988;48:4584-7.
6. Raoul JL, Heresbach MD, Bretagne JF, et al. Chemoembolization of hepatocellular carcinomas, a study of biodistribution and pharmacokinetics of doxorubicin. *Cancer* 1992;70:585-90.
7. Geschwind JF, Ramsey DE, van der Wal BC, et al. A. Transcatheter arterial chemoembolization of liver tumors: effects of embolization protocol on injectable volume of chemotherapy and subsequent arterial patency. *Cardiovasc Intervent Radiol* 2003;26:111-7.
8. Teder H, Johansson CJ. The effect of different dosages of degradable starch microspheres (Spherex) on the distribution of doxorubicin regionally administered to the rat. *Anticancer Res* 1993;13:2161-4.
9. Sadahiro S, Suzuki T, Ishikawa K, et al. Pharmacokinetics of 5-fluorouracil following hepatic intra-arterial infusion in a VX2 hepatic metastasis model. *Jpn J Clin Oncol* 2003;33:377-81.
10. Goh YM, Kong HL, Wang CH. Simulation of the delivery of doxorubicin to hepatoma. *Pharm Res* 2001;18:761-70.
11. Favoulet P, Cercueil JP, Faure P, et al. Increased cytotoxicity and stability of lipiodol-pirarubicin emulsion compared to classical doxorubicin-lipiodol: potential advantage for chemoembolization of unresectable hepatocellular carcinoma. *Anticancer Drugs* 2001;12:801-6.
12. Johansson CJ, Teder H, Gronquist L, et al. Hepatic intra-arterial administration of doxorubicin and degradable starch microspheres. A pharmacokinetic study in the rat. *Acta Oncol* 1994;33:39-42.
13. Llovet JM, Real MI, Montana X, et al. Arterial embolisation or chemoembolisation versus symptomatic treatment in patients with unresectable hepatocellular carcinoma: a randomised controlled trial. *Lancet* 2002;359:1734-9.
14. Camma C, Schepis F, Orlando A, et al. Transarterial chemoembolization for unresectable hepatocellular carcinoma: meta-analysis of randomized controlled trials. *Radiology* 2002;224:47-54.
15. Geschwind JF, Artemov D, Abraham S, et al. Chemoembolization of liver tumor in a rabbit model: assessment of tumor cell death with diffusion-weighted MR imaging and histologic analysis. *J Vasc Interv Radiol* 2000;11:1245-55.
16. Lewis AL, Gonzalez MV, Lloyd AW, et al. DC Bead: *in-vitro* characterization of a drug delivery device for transarterial chemoembolization. *J Vasc Interv Radiol* 2006;17:335-42.