

## EGFR Exon 20 Insertion A763-Y764insFQEA and Response to Erlotinib—Letter

Pei Jye Voon<sup>1</sup>, Dana Wai Yi Tsui<sup>3</sup>, Nitzan Rosenfeld<sup>3</sup>, and Tan Min Chin<sup>1,2</sup>

We read with great interest the recent article by Arcila and colleagues (1). We present a case of exon 20 insertion mutation (A763\_Y764insFQEA), with documented clinical and radiologic response to EGF receptor (EGFR) tyrosine kinase inhibitor (TKI). To our knowledge, this is the first

of his right supraclavicular lymph node showed adenocarcinoma TTF 1+, CK 7+ consistent with a lung primary. EGFR exon 20 insertion A763\_Y764insFQEA was detected on sequencing of the primary tumor (3). In view of potential *de novo* resistance, palliative first-line treatment chemother-

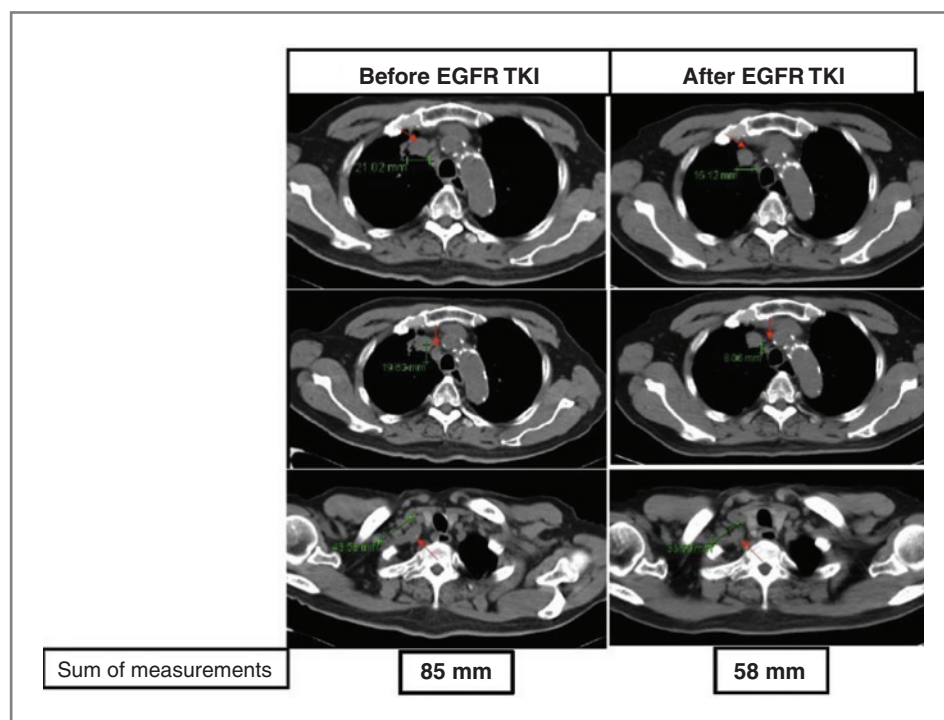


Figure 1. Computer tomography scans of the patient before and after treatment with erlotinib. The sum of measurements of the lung and lymph node lesions (indicated by arrows) before and after treatment is also shown.

report of response to erlotinib monotherapy with this particular solitary mutation (1, 2).

The patient, a 75-year-old Chinese male ex-smoker (40 pack-years), was diagnosed with metastatic non-small cell lung carcinoma in November 2010. Fine needle aspiration

apy with single-agent gemcitabine, followed by single-agent docetaxel and vinorelbine at progression were used (platinums were not used because of creatinine clearance of 40 mL/min, a borderline performance status ECOG1, multiple comorbidities of hypertension and cerebrovascular accident). Stable disease [Response Evaluation Criteria in Solid Tumors (RECIST) criteria] was achieved with relatively short progression-free survival. At progression of disease in August 2012, 100 mg of erlotinib daily was initiated, at reduced dose due to his multiple comorbidities. Nonetheless, he reported grade 3 skin toxicity that required further dose reduction of erlotinib to 100 mg every other day. Despite the reduced dose of erlotinib, he achieved partial response (RECIST) at the 2-month computer tomography (CT) imaging assessment (see Fig. 1), with a prompt clinical response in his supraclavicular lymph node (no longer palpable after 2 weeks of erlotinib). Currently, at 5 months of erlotinib treatment, CT shows stable disease. His disease response despite the lower erlotinib dose shows

**Authors' Affiliations:** <sup>1</sup>Department of Hematology-Oncology, National University Cancer Institute, National University Health System; <sup>2</sup>Cancer Science Institute, Centre for Translational Medicine, National University of Singapore, Singapore, and <sup>3</sup>Cancer Research UK Cambridge Institute, University of Cambridge, Li Ka Shing Centre, Cambridge, United Kingdom

**Note:** The authors of the original article declined to submit a response.

**Corresponding Author:** Tan Min Chin, Department of Hematology-Oncology, National University Cancer Institute, National University Health System, 5 Lower Kent Ridge Road, Tower Block Level 7, Singapore 119074. Phone: 65-67724140; Fax: 65-67795545; E-mail: Tan\_Min\_CHIN@nuhs.edu.sg

doi: 10.1158/1535-7163.MCT-13-0192

©2013 American Association for Cancer Research.

that this particular mutation is likely a sensitizing mutation to EGFR TKI, despite its location in exon 20, consistent with the predicted function by the *in silico* molecular modeling reported by Arcila and colleagues (ref. 1; of c-helix mutations not affecting the drug binding site). We note a previous report (4) of documented response to 25 mg daily of erlotinib in EGFR mutants. Other known sensitizing mutations were not found in either the tumor or the circulating DNA (in plasma) of this patient (5), making it highly likely that the positive response was due to the EGFR exon 20 insertion mutation A763\_Y764insFQEA.

Our findings highlight the heterogeneity of clinical response for exon 20 insertion mutations to EGFR TKI. Future research on this intriguing mutation is needed to delineate its position as a predictive marker for non-small cell lung carcinoma.

#### Disclosure of Potential Conflicts of Interest

No potential conflicts of interest were disclosed.

Received March 20, 2013; revised June 17, 2013; accepted June 26, 2013; published OnlineFirst August 22, 2013.

#### References

1. Arcila ME, Nafa K, Chaft JE, Rekhtman N, Lau C, Reva BA, et al. EGFR exon 20 insertion mutations in lung adenocarcinomas: prevalence, molecular heterogeneity, and clinicopathologic characteristics. *Mol Cancer Ther* 2013;12:220–9.
2. Yasuda H, Kobayashi S, Costa DB. EGFR exon 20 insertion mutations in non-small-cell lung cancer: preclinical data and clinical implications. *Lancet Oncol* 2012;13:e23–31.
3. Chin TM, Anuar D, Soo R, Salto-Tellez M, Li WQ, Ahmad B, et al. Detection of epidermal growth factor receptor variations by partially denaturing HPLC. *Clin Chem* 2007;53:62–70.
4. Yeo WL, Riely GJ, Yeap BY, Lau MW, Warner JL, Bodio K, et al. Erlotinib at a dose of 25 mg daily for non-small cell lung cancers with EGFR mutations. *J Thorac Oncol* 2010;5:1048–53.
5. Forshew T, Murtaza M, Parkinson C, Gale D, Tsui DW, Kaper F, et al. Noninvasive identification and monitoring of cancer mutations by targeted deep sequencing of plasma DNA. *Sci Transl Med* 2012;4:136ra68.