

Gonadal Tumor in Frasier Syndrome: A Review and Classification

Jiro Ezaki^{1,2}, Kazunori Hashimoto³, Tatsuo Asano⁴, Shoichiro Kanda⁴, Yuko Akioka⁴, Motoshi Hattori⁴, Tomoko Yamamoto^{2,5}, and Noriyuki Shibata^{2,5}

Abstract

Frasier syndrome is a rare inherited disease characterized by steroid-resistant nephrotic syndrome, gonadal tumor, and male pseudohermaphroditism (female external genitalia with sex chromosomes XY), which is based on a splice site mutation of Wilms tumor-suppressor gene 1 (*WT1*). Several unusual Frasier syndrome cases have been reported in which male pseudohermaphroditism was absent. We reviewed 88 Frasier syndrome cases in the literature and classified them into three types (type 1–3) according to external genitalia and sex chromosomes, and described their clinical phenotypes. Type 1 Frasier syndrome is characterized by female external genitalia with 46,XY ($n = 72$); type 2 by male

external genitalia with 46,XY ($n = 8$); and type 3 by female external genitalia with 46,XX ($n = 8$). Clinical course differs markedly among the types. Although type 1 is noticed at the mean age of 16 due to mainly primary amenorrhea, type 2 and 3 do not present delayed secondary sex characteristics, making diagnosis difficult. The prevalence of gonadal tumor is high in type 1 (67%) and also found in 3 of the 8 type 2 cases, but not in any type 3 cases, which emphasize that preventive gonadectomy is unnecessary in type 3. On the basis of our findings, we propose a new diagnostic algorithm for Frasier syndrome. *Cancer Prev Res*; 8 (4): 271–6. ©2015 AACR.

Introduction

Frasier syndrome and Denys–Drash syndrome (DDS) are both rare inherited diseases characterized by steroid-resistant nephrotic syndrome, which leads to renal failure, gonadal tumor (most commonly gonadoblastoma or dysgerminoma), and male pseudohermaphroditism (female external genitalia with sex chromosomes XY; ref. 1). In comparison with other conditions in which male pseudohermaphroditism is present, the risk of gonadal tumor is particularly high in Frasier syndrome (60% compared with 40% for DDS and 15% for partial androgen insensitivity syndrome; ref. 2). Early diagnosis and early elective bilateral gonadectomy have, therefore, been recommended for patients with Frasier syndrome and DDS (3, 4).

Frasier syndrome and DDS are both caused by specific mutations in the Wilms tumor-suppressor gene (*WT1*), which is located in autosome 11p13 (3). In DDS, a dominant negative

mutation in exons 8 or 9 of *WT1* leads to the production of abnormal *WT1* protein, which results in renal failure before 1 year of age and the development of Wilms tumor of the kidney (1). In contrast, in Frasier syndrome, a point mutation on the donor splice site on intron 9 [intervening sequence (IVS 9)] of *WT1* leads to a slow progression of glomerulopathy, leading to proteinuria and nephrotic syndrome in childhood, followed by renal failure in adolescence or early adulthood. Only one case of Frasier syndrome associated with Wilms tumor has been reported (5). The presence of focal segmental glomerulosclerosis or diffuse mesangial sclerosis limits the utility of renal histopathology in distinguishing between these two syndromes (6).

WT1 is a regulator of early gonadal and renal development (7). Two major *WT1* isoforms are produced by alternative splicing of the lysine–threonine–serine (KTS) domain, including an insertion (+KTS) or deletion (–KTS; ref. 3). The +KTS isoform of *WT1* participates in RNA processing, and has been shown to play a crucial role in the regulation of sex-determining region Y (*SRY*) *in vivo* in mice (3, 7). Thus, it can be surmised that *WT1* or *SRY* mutations can induce early errors in the processes of sex determination mediated by preventing proper formation of the testis. Furthermore, sex reversal is observed in male mice deficient in the +KTS isoform of *WT1* (7). In human patients with Frasier syndrome, a point mutation on IVS9 brings about downregulation of the +KTS isoform of *WT1*, which in turn diminishes *SRY* expression levels (8), and thereby impairs testicular development (7). Thus, male to female sex reversal will occur in pediatric Frasier syndrome patients with 46,XY (9).

Because most patients with Frasier syndrome have external female genitalia and are raised as girls, Frasier syndrome is often suspected when these children with steroid-resistant nephrotic syndrome are evaluated for delayed puberty or primary amenorrhea. The diagnosis is confirmed by detecting *WT1* mutations (3). Because of the high risk of gonadal tumor, early diagnosis of Frasier syndrome and early gonadectomy are very important for

¹The Medical Training Center for Graduates, Tokyo Women's Medical University, Tokyo, Japan. ²Department of Surgical Pathology, Tokyo Women's Medical University, Tokyo, Japan. ³Department of Obstetrics and Gynecology, Tokyo Women's Medical University, Tokyo, Japan. ⁴Department of Pediatric Nephrology, Tokyo Women's Medical University, Tokyo, Japan. ⁵Department of Pathology, Tokyo Women's Medical University, Tokyo, Japan.

Note: Supplementary data for this article are available at Cancer Prevention Research Online (<http://cancerprevres.aacrjournals.org/>).

Current address for Jiro Ezaki: Department of Legal Medicine, School of medicine, Tokyo Women's Medical University, Japan.

Corresponding Author: Noriyuki Shibata, Department of Pathology, Tokyo Women's Medical University, 8-1 Kawada-cho, Shinjuku-ku, Tokyo 162-8666, Japan. Phone: 81-3-3353-8111, ext. 22231; Fax: 81-3-5269-7408; E-mail: shibatana@research.twmu.ac.jp

doi: 10.1158/1940-6207.CAPR-14-0415

©2015 American Association for Cancer Research.

preventing tumorigenesis (3, 4). However, because most Frasier syndrome patients only present with slowly progressing renal failure, it is very difficult to distinguish it from primary amenorrhea associated with other disorders. A possible option for early diagnosis of Frasier syndrome might be the genetic screening of children with steroid-resistant nephrotic syndrome.

Over the past two decades, several cases of Frasier syndrome of unusual phenotype have been reported. These cases carry a Frasier syndrome-specific IVS 9 mutation in *WT1* without the presence of male pseudohermaphroditism. These cases can be classified into two types: patients with male chromosomes (XY) and male external genitalia, and patients with female chromosomes (XX) and female external genitalia. Mother and daughter cases of Frasier syndrome with transmission of *WT1* splice-site mutation have been reported (10). The clinical features of these "unusual" cases differ from classical Frasier syndrome.

Previous review articles concerning Frasier syndrome have not provided detailed descriptions of the clinical features and treatment of classical and unusual cases (7, 11). Here, we review the literature, focusing on clinical course, mutation patterns, and prevalence rates of gonadal tumor in classical and unusual cases of Frasier syndrome. We also propose a new classification system for Frasier syndrome, which may be applied to genetic diagnosis and therapeutic strategies.

Literature Review and Classification of Frasier Syndrome

Search strategy and selection criteria

A systematic search of the MEDLINE database up to February 2014 was performed to identify literature with the search term, "Frasier syndrome." In addition, an extensive manual search was conducted using references from all retrieved reports and review articles. Initially, we found 99 cases that were classified as Frasier syndrome. However, for the purpose of the current analysis, 8 cases were excluded because they lacked descriptions about external genitalia and/or karyotype. Two cases with *WT1* mutations (1168C→T and 1174T→C) in exon 9 but not IVS 9 mutation have been reported as unusual Frasier syndrome (12). Although these mutations are also consistent with DDS, both slow progression of steroid-resistant nephrotic syndrome and the absence of Wilms tumor indicate Frasier syndrome (12). However, the fact that these cases were not associated with abnormal KTS splice isoforms suggests an etiology similar to DDS rather than Frasier syndrome. We therefore excluded these two cases from our study. Another unusual Frasier syndrome case showed external genitalia of female phenotype, chronic renal failure, and primary hypogonadism as well as defects of the uterine cervix, body and tubes, and gonads on pelvic MRI (13, 14). However, the case was excluded from our study because genetic analysis of *WT1* was not performed. The inclusion criteria for our review of the Frasier syndrome literature were as follows: (i) the presence of steroid-resistant nephrotic syndrome; and (ii) the presence of male pseudohermaphroditism or IVS 9 mutation. In total, 88 Frasier syndrome cases were selected for our review (Supplementary Table S1).

Classification of Frasier syndrome

Because Frasier syndrome is caused by a point mutation in the IVS9 of *WT1* located on chromosome 11 (autosome), by which abnormal WT1 + KTS protein are produced (7), both males and

females can suffer from Frasier syndrome. However, the interaction between SRY and abnormal WT1 + KTS protein means that the presence of SRY (male) affects phenotype in Frasier syndrome. Moreover, it is hypothesized that there is a gene on the Y chromosome that is involved in the development of gonadoblastoma (15). This is called the gene for testis-specific protein Y (*TSPY*), which has been referred to as the gonadoblastoma locus on the Y chromosome (GBY; ref. 16). However, the complete mechanism by which the *TSPY* product causes tumorigenesis remains to be elucidated (2). Therefore, we classified Frasier syndrome from viewpoints such as sex chromosome and external genitalia.

All of the selected cases were categorized into three types: type 1 cases with female external genitalia and 46,XY ($n = 72$); type 2 with male external genitalia and 46,XY ($n = 8$); and type 3 cases with female external genitalia and 46,XX ($n = 8$; Table 1). To our knowledge, there have been no cases of Frasier syndrome with male external genitalia and 46,XX.

Clinical course of Frasier syndrome

We extracted information on the "first complaint" and the "complaint that lead to diagnosis of Frasier syndrome" from each of the 88 cases, and compared their clinical course. Proteinuria, nephrotic syndrome, and hypertension, or edema due to renal failure were abbreviated as "renal disorder," and primary amenorrhea and/or delayed puberty were abbreviated as "delayed secondary sex characteristics." The number of cases, age of complaints, types of *WT1* mutation and histopathologic type of gonadal tumor were described for each type of Frasier syndrome (Table 1). We diagnosed a case with coexisting gonadoblastoma and dysgerminoma as having dysgerminoma, which is more malignant than gonadoblastoma.

To elucidate the characteristics of gonadal tumor in type 1, we compared the age at gonadectomy and between three groups: cases without gonadal tumor, cases with gonadoblastoma and cases with dysgerminoma (Table 2). To explore the relationship between the types of *WT1* mutation and the occurrence of gonadal tumor, we also compared the difference in the number of cases corresponding to each type of *WT1* mutation (Table 2).

Statistical analysis

Age was expressed as mean \pm SD. One-way ANOVA was used for continuous variables, and the χ^2 test was used for categorical variables. Statistical analyses were performed using the SPSS statistics software, version 20 (IBM). A *P* value of <0.05 was considered to be statistically significant.

Type 1 Frasier syndrome (female external genitals with sex chromosome XY)

The majority of cases reported in the literature ($n = 72$, 82%) were of type 1 Frasier syndrome (Table 1). In type 1, the most common "first complaint" (that which prompted parents of Frasier syndrome patients to first visit a clinic), was renal disorder in the infant period ($n = 49$, mean age at first visit: 5.4 ± 4.3 years). Only seven type 1 cases were diagnosed with Frasier syndrome at this point. Most other type 1 patients were diagnosed in adolescence due to delayed secondary sexual characteristics ($n = 36$, mean age at diagnosis: 16.3 ± 2.3 years). In the cases with descriptions of *WT1* mutation, 90% of genetic mutations were restricted to IVS9 +4 and IVS9 +5 of *WT1*.

Table 1. Classification of Frasier syndrome ($n = 88$)

External genitalia Sex chromosome	Type 1 ($n = 72$)		Type 2 ($n = 8$)		Type 3 ($n = 8$)	
	Female XY		Male XY		Female XX	
	<i>n</i>	Age, y (mean \pm SD)	<i>n</i>	Age, y (mean \pm SD)	<i>n</i>	Age, y (mean \pm SD)
First complaint						
Renal disorder ^a	49	5.4 \pm 4.3	3	5.3 \pm 0.6	6	7.8 \pm 5.2
Delayed secondary sex characteristics ^b	4	17.0 \pm 3.4	0		0	
Hypospadias or aplasia of testis	0		5	1.0 \pm 2.2	0	
Abdominal pain or mass	3	10.0 \pm 3.6	0		0	
Other	4	4.5 \pm 3.9	0		1	13.0
No description	12		0		1	
Complaint leading to Frasier syndrome diagnosis						
Renal disorder	7	6.1 \pm 1.3	3	13.0 \pm 13.9	2	4.5 \pm 2.1
Delayed secondary sex characteristics	36	16.3 \pm 2.3	0		0	
Hypospadias or aplasia of testis	0		1	5.0	0	
Abdominal pain or mass	6	11.3 \pm 3.4	0		0	
Others	4	3.0 \pm 4.2	4	14.5 \pm 5.0	2	15.0 ^c
No description	19		0		4	
	<i>n</i> (%)		<i>n</i> (%)		<i>n</i> (%)	
<i>WT1</i> mutation						
IVS9 -1A→G	0		1 (10)		0	
IVS9 +1G→A	2 (4)		0		0	
IVS9 +2T→C	2 (4)		0		0	
IVS9 +4 C→T	17 (34)		5 (50)		1 (12.5)	
IVS9 +5 G→A	27 (55)		2 (20)		7 (87.5)	
IVS9 +6 T→A	1 (2)		0		0	
No description	23 ^d		0		0	
Gonadal tumor	See Table 2 for details		Sertoli cell tumor and seminoma ($n = 1$); ITGCN ($n = 1$); Gonadoblastoma ($n = 1$)		No gonadal tumor reported	

^aFeatures including proteinuria, nephrotic syndrome, hypertension, and edema.

^bFeatures including primary amenorrhea and delayed puberty.

^cAge was available in one case.

^dNo description was excluded in the percentage.

The characteristics of gonadal tumor ($n = 45$) in type 1 Frasier syndrome are summarized in Table 2. A previous study indicated that early diagnosis of Frasier syndrome and early gonadectomy prevented the occurrence of gonadal tumor (4). To verify this association, we compared the mean age at gonadectomy in cases without gonadal tumor, cases with gonadoblastoma, and cases with dysgerminoma. The tendency for cases with clinically aggressive gonadal tumor phenotypes to undergo early gonadectomy creates a reverse causal problem. We therefore conducted analyses separately: cases noticed because of renal disorder or delayed secondary sexual characteristics and cases noticed because of abdominal pain or mass. There was no statistically significant difference of age at gonadectomy and position of *WT1* mutation among the three groups: cases without gonadal tumor, cases with gonadoblastoma and cases with dysgerminoma ($P = 0.519$ for age at gonadectomy and $P = 0.779$ for position of *WT1* mutation, Table 2). Neoplastic transformations seem to occur in the period of adolescence. However, our study's cross-sectional design meant that we could not ascertain the rate of gonadal tumor occurrence.

Six Frasier syndrome cases were diagnosed by the presence of abdominal pain or mass, all of which had gonadal tumor [gonadoblastoma (refs. 17–19), or dysgerminoma (refs. 20–22)]. In some cases, metastasis (17), or recurrence (20) was observed. These cases underwent gonadectomy around the age of 11, which was earlier than in cases diagnosed by the presence of renal disorder and/or delayed secondary sexual characteristics. Among the 46,XY Frasier syndrome cases, 32 (67%) had gonadal tumor,

suggesting that the risk of gonadal tumor is higher than that reported in previous studies [60%; (ref. 11) and 48% (ref. 7)].

Type 2 Frasier syndrome (male external genitals with sex chromosome XY)

Eight cases of type 2 Frasier syndrome have been reported (8, 12, 23–29). Although 5 of the cases initially visited clinics due to hypospadias or aplasia of testis (mean age at first visit: 1.0 ± 2.2 years), in most cases, these features did not lead to the diagnosis of Frasier syndrome. Three cases were diagnosed during investigation of renal disorder, and four cases were diagnosed because of other features (Table 1). Features that lead to the diagnosis of Frasier syndrome in these four cases include testicular nodule (gonadoblastoma; ref. 27), genetic investigation due to familial history of Frasier syndrome (28, 29), and severe hypertension due to renal failure (24).

Interestingly, both the distribution and pattern of *WT1* mutation in type 2 Frasier syndrome were different from those in type 1 Frasier syndrome. The number of patients with IVS9 +5G→A ($n = 27$) was larger than patients with IVS9 +4C→T ($n = 17$) in type 1 Frasier syndrome, whereas the number of patients with IVS9 +5G→A ($n = 2$) was smaller than patients with IVS9 +4C→T ($n = 5$) in type 2 Frasier syndrome ($P = 0.11$ for the χ^2 test of IVS9 +4C→T and IVS9 +5G→A; Table 1). The position of the altered base could influence the ratio of +KTS and -KTS isoforms of *WT1* protein, by which external genitals were determined. However, it is also conceivable that other mutations may affect

Table 2. Characteristics of gonadal tumor in type 1 Frasier syndrome ($n = 45$)^a

Cases diagnosed Frasier syndrome by renal disorder or/and delay of secondary sexual character^b ($n = 39$)				
Age at gonadectomy	No gonadal tumor ($n = 15$)	Gonadoblastoma ($n = 13$)	Dysgerminoma ($n = 11$)	<i>P</i>
	Year (mean \pm SD) 15.8 \pm 4.8	Year (mean \pm SD) 13.6 \pm 6.5	Year (mean \pm SD) 15.6 \pm 3.8	0.519 ^c
<i>WT1</i> mutation	<i>n</i>	<i>n</i>	<i>n</i>	<i>P</i>
IVS9 -1A→G	0	0	0	0.775 ^d
IVS9 +1G→A	0	0	1	
IVS9 +2T→C	0	0	0	
IVS9 +4 C→T	3	2	2	
IVS9 +5 G→A	6	4	3	
IVS9 +6 T→A	0	0	0	
No information	6	7	5	

Cases diagnosed Frasier syndrome by abdominal pain or mass ($n = 6$)

Age at gonadectomy	No gonadal tumor ($n = 0$)	Gonadoblastoma ($n = 3$)	Dysgerminoma ($n = 3$)	<i>P</i>
	Year (mean \pm SD) NA	Year (mean \pm SD) 11.7 \pm 4.9	Year (mean \pm SD) 11.0 \pm 2.0	0.839 ^c
<i>WT1</i> mutation	<i>n</i>	<i>n</i>	<i>n</i>	<i>P</i>
IVS9 -1A→G	0	0	0	1.000 ^d
IVS9 +1G→A	0	0	0	
IVS9 +2T→C	0	0	0	
IVS9 +4C→T	0	1	1	
IVS9 +5G→A	0	2	2	
IVS9 +6T→A	0	0	0	
No information	0	0	0	

^aCases with no information on age at gonadectomy and/or histologic features and/or diagnostic symptom ($n = 26$) were excluded from the total (73 cases) of type 1 Frasier syndrome in this table.

^bOne case of type 1 Frasier syndrome with seminoma without information about *WT1* gene mutation was excluded also excluded from this table.

^cA *P* value was calculated by one-way ANOVA.

^dA *P* value was calculated by the χ^2 test.

the phenotype of external genitalia. Whole-genome sequencing in types 1 and 2 Frasier syndrome patients may clarify the mechanism by which external genital phenotypes are determined.

Among the 8 cases of type 2 Frasier syndrome, three cases first presented because of gonadal tumors: Sertoli cell tumor and seminoma (23), intratubular germ cell neoplasia unclassified (ITGCN; ref. 8), and gonadoblastoma (27). There is no description concerning gonadectomy in cases without gonadal tumor (24, 26, 28–30). The rate of gonadal tumor in type 2 Frasier syndrome cases remains unclear. Because type 2 Frasier syndrome cases do not present primary amenorrhea, the presence of steroid-resistant nephrotic syndrome in children with male external genitalia may provide a chance to examine mutations in *WT1*. Clinicians should pay attention to the history of infantile hypopadias or aplasia of testis.

Type 3 Frasier syndrome (female external genitalia with sex chromosome XX)

Eight cases of type 3 Frasier syndrome have been reported (10, 13, 14, 31–36). Few type 3 Frasier syndrome cases are diagnosed because patients exhibit normal secondary sexual characteristics by the XX chromosome and suffer from renal failure without gonadal impairment. In a previous case report on mother-to-child transmitted *WT1* splice-site mutation (10), the mother (46,XX) had an IVS9+5G→A mutation of *WT1* and renal failure without gonadal impairment, and her 46,XY daughter had the same mutation and renal failure. It is of interest that the mother and daughter seem to be of types 3 and 1, respectively. These cases point to the possibility that a 46,XY child who is born to a type 3 Frasier syndrome parent could have type 1 Frasier syndrome. In this regard, *WT1* sequencing is useful not only in

instances of sporadic steroid-resistant nephrotic syndrome, but also in familial cases. Thus, it should be considered with caveat that patients with type 3 Frasier syndrome, as well as those with types 1 and 2, might require careful genetic counseling.

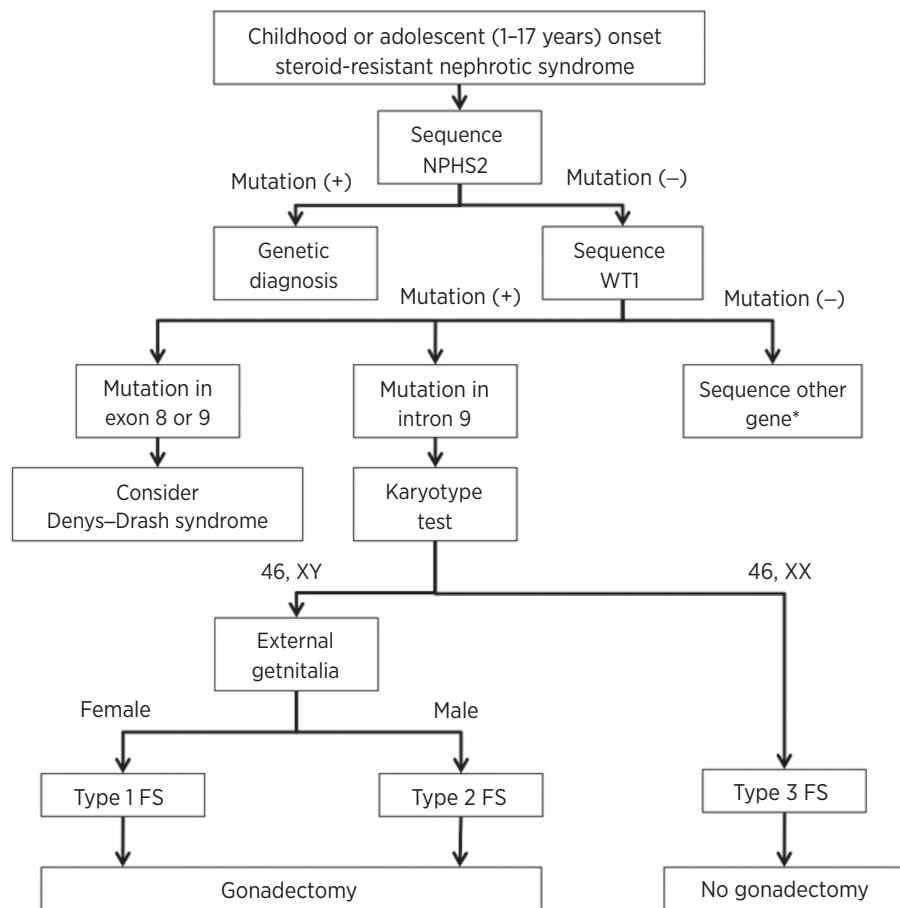
It is noteworthy that there were no cases of type 3 Frasier syndrome with gonadal tumor (Table 1). The absence of gonadal tumor in type 3 Frasier syndrome, in contrast with the other types, suggests the possibility that a gonadoblastoma-related gene locus exists on the Y chromosome (15). On the basis of this finding, it would seem that gonadectomy should not be recommended in cases of type 3 Frasier syndrome. However, the existence of 8 non-Frasier syndrome cases with gonadoblastoma in pure 46,XX females suggests that there is a level of risk of gonadal tumor in type 3 Frasier syndrome that cannot be ignored (37, 38). The prudent recommendation in type 3 Frasier syndrome cases might, therefore, be that medical practitioners carry out careful follow-up examinations of gonadal (ovarian) tissues.

Discussion

On the basis of the results of our review of 88 Frasier syndrome cases, we classified Frasier syndrome into three types (types 1–3 Frasier syndrome). All genetic mutations were detected at the IVS9 region of *WT1*. However, the rates of occurrence of gonadal tumor and clinical features differed among the three types. Although gonadal tumor was frequently present in types 1 and 2, it was not present in any type 3 Frasier syndrome cases. In comparison with other studies, our study showed a higher risk of gonadal tumor (67%) in type 1 Frasier syndrome (7, 11). Six cases were diagnosed in response to abdominal pain or mass reflecting gonadal tumor (17–22), of which two showed metastasis or recurrence (17, 20). These six cases underwent gonadectomy at around 11 years of

Figure 1.

Algorithm for diagnosis of Frasier syndrome. Diagnostic processes require the following criteria/data: clinical features, presence of steroid-resistant nephrotic syndrome, and gene analysis. FS, Frasier syndrome; *NPHS2*, nephrosis 2, idiopathic, steroid-resistant (podocin); *WT1*, Wilms tumor gene 1. *, in infantile- or child-onset steroid-resistant nephrotic syndrome cases, *NPHS1* should be sequenced. *PLCE1* should be sequenced in cases of AR familial history in the event that a patient is negative for *NPHS1* mutation. In cases of adolescent-onset steroid-resistant nephrotic syndrome, *TRPC6/INF2* and *ACTN4* should be sequenced if the patient has AD familial history (see ref. 39 for details).



age—which was younger than in cases diagnosed in response to renal disorder, delayed secondary sexual characteristics, or both. These data suggest that diagnosis of Frasier syndrome before puberty requires sequencing analysis of *WT1*. Gonadal tumor is also a risk in type 2 Frasier syndrome cases. Thus, early diagnosis and early gonadectomy should be considered in cases of types 1 and 2. However, given that no cases of gonadal tumor have been reported from type 3 Frasier syndrome, gonadectomy should not be recommended in type 3—even if that necessitates the further follow-up examination of gonadal tissues.

A large number of genetic mutations have been identified in subjects with steroid-resistant nephrotic syndrome and focal segmental glomerulosclerosis. A genetic testing algorithm for steroid-resistant nephrotic syndrome based on age at onset and familial/sporadic status was recently reported (39). According to the algorithm for infantile and child onset steroid-resistant nephrotic syndrome, *WT1* gene analysis should be performed only in patients with "sporadic steroid-resistant nephrotic syndrome" and "female external genitalia" who are negative for mutation in the gene for nephrosis 2, idiopathic, and steroid-resistant (podocin; *NPHS2*). *NPHS2* mutation is the most common cause of infantile and child onset steroid-resistant nephrotic syndrome (39).

Cases of Frasier syndrome types 2 and 3 show steroid-resistant nephrotic syndrome but not primary amenorrhea. Although there is a lack detailed data concerning age of onset, the age at onset of

renal disorder represented by proteinuria ranges from 1 to 18 years. In other words, these data point to the possibility that cases of steroid-resistant nephrotic syndrome in patients of 1 to 18 years of age could include cases of type 2 and 3 Frasier syndrome. The fact that there are Frasier syndrome cases displaying male external genitalia (type 2 Frasier syndrome according to our classification) or suspected familial steroid-resistant nephrotic syndrome (10), indicates that it is noteworthy to consider sequencing analysis of *WT1* not only in patients with female external genitalia and sporadic steroid-resistant nephrotic syndrome, but also in those with male external genitalia or familial steroid-resistant nephrotic syndrome. Regarding these characteristics, we have proposed a new diagnostic algorithm for Frasier syndrome (Fig. 1).

Taken together, we summarized and reviewed the clinical, genetic, and pathologic features of 88 Frasier syndrome cases. It is very important to perform early diagnosis and type classification on Frasier syndrome cases. Further investigations using epidemiologic, genetic, and molecular biologic approaches will be addressed to verify the ultimate significance of our new classification system, which is linked to clarifying the etiology of Frasier syndrome and therapeutic strategies.

Disclosure of Potential Conflicts of Interest

No potential conflicts of interest were disclosed.

Received November 19, 2014; revised January 12, 2015; accepted January 16, 2015; published OnlineFirst January 26, 2015.

References

- Saylam K, Simon P. WT1 gene mutation responsible for male sex reversal and renal failure: the Frasier syndrome. *Eur J Obstet Gynecol Reprod Biol* 2003;110:111–3.
- Pleskacova J, Hersmus R, Oosterhuis JW, Setyawati BA, Faradz SM, Cools M, et al. Tumor risk in disorders of sex development. *Sex Dev* 2010;4:259–69.
- Guaragna MS, Lutaif AC, Bittencourt VB, Piveta CS, Soardi FC, Castro LC, et al. Frasier syndrome: four new cases with unusual presentations. *Arq Bras Endocrinol Metabol* 2012;56:525–32.
- Hughes IA, Houk C, Ahmed SF, Lee PA. Consensus statement on management of intersex disorders. *J Pediatr Urol* 2006;2:148–62.
- Jaubert F, Vasiliu V, Patey-Mariaud de Serre N, Auber F, Jeanpierre C, Gubler MC, et al. Gonad development in Drash and Frasier syndromes depends on WT1 mutations. *Arkh Patol* 2003;65:40–4.
- Hausladen J, Granahan E, Bockenbauer D. Case report: teenage girl with proteinuria and amenorrhea. *Curr Opin Pediatr* 2001;13:150–3.
- Hersmus R, van der Zwan YG, Stoop H, Bernard P, Sreenivasan R, Oosterhuis JW, et al. A 46,XY female DSD patient with bilateral gonadoblastoma, a novel SRY missense mutation combined with a WT1 KTS splice-site mutation. *PLoS ONE* 2012;7:e40858.
- Schumacher V, Gueler B, Looijenga LH, Becker JU, Amann K, Engers R, et al. Characteristics of testicular dysgenesis syndrome and decreased expression of SRY and SOX9 in Frasier syndrome. *Mol Reprod Dev* 2008;75:1484–94.
- Love JD, DeMartini SD, Coppola CP. Prophylactic bilateral salpingo-oophorectomy in a 17-year-old with Frasier syndrome reveals gonadoblastoma and seminoma: a case report. *J Pediatr Surg* 2006;41:e1–4.
- Denamur E, Bocquet N, Mougnot B, Da Silva F, Martinat L, Loirat C, et al. Mother-to-child transmitted WT1 splice-site mutation is responsible for distinct glomerular diseases. *J Am Soc Nephrol* 1999;10:2219–23.
- Joki-Erkkila MM, Karikoski R, Rantala I, Lenko HL, Visakorpi T, Heinonen PK. Gonadoblastoma and dysgerminoma associated with XY gonadal dysgenesis in an adolescent with chronic renal failure: a case of Frasier syndrome. *J Pediatr Adolesc Gynecol* 2002;15:145–9.
- Kohsaka T, Tagawa M, Takekoshi Y, Yanagisawa H, Tadokoro K, Yamada M. Exon 9 mutations in the WT1 gene, without influencing KTS splice isoforms, are also responsible for Frasier syndrome. *Hum Mutat* 1999;14:466–70.
- Reznik VM, Mendoza SA, Freidenberg GR. Evaluation of delayed puberty in the female adolescent with chronic renal failure. *Pediatr Nephrol* 1993;7:551–3.
- Bailey WA, Zwingman TA, Reznik VM, Griswold WR, Mendoza SA, Jones KL, et al. End-stage renal disease and primary hypogonadism associated with a 46,XX karyotype. *Am J Dis Child* 1992;146:1218–23.
- Page DC. Hypothesis: a Y-chromosomal gene causes gonadoblastoma in dysgenetic gonads. *Development* 1987;101 Suppl:151–5.
- Tsuchiya K, Reijo R, Page DC, Distche CM. Gonadoblastoma: molecular definition of the susceptibility region on the Y chromosome. *Am J Hum Genet* 1995;57:1400–7.
- Koziell A, Charmandari E, Hindmarsh PC, Rees L, Scambler P, Brook CG. Frasier syndrome, part of the Denys Drash continuum or simply a WT1 gene associated disorder of intersex and nephropathy? *Clin Endocrinol* 2000;52:519–24.
- Okuhara K, Tajima S, Nakae J, Sasaki S, Tochimaru H, Abe S, et al. A Japanese case with Frasier syndrome caused by the splice junction mutation of WT1 gene. *Endocr J* 1999;46:639–42.
- Frasier SD, Bashore RA, Mosier HD. Gonadoblastoma associated with pure gonadal dysgenesis in monozygous twins. *J Pediatr* 1964;64:740–5.
- Mestrallet G, Bertholet-Thomas A, Ranchin B, Bouvier R, Frappaz D, Cochat P. Recurrence of a dysgerminoma in Frasier syndrome. *Pediatr Transplant* 2011;15:e53–5.
- Subbiah V, Huff V, Wolff JE, Ketonen L, Lang FF Jr, Stewart J, et al. Bilateral gonadoblastoma with dysgerminoma and pilocytic astrocytoma with WT1 GT-IVS9 mutation: a 46 XY phenotypic female with Frasier syndrome. *Pediatr Blood Cancer* 2009;53:1349–51.
- Shimoyama H, Nakajima M, Naka H, Park YD, Hori K, Morikawa H, et al. A girl with bilateral ovarian tumours: Frasier syndrome. *Eur J Pediatr* 2002;161:81–3.
- Kitsiou-Tzeli S, Deligiorgi M, Malaktari-Skarantavou S, Vlachopoulos C, Megremis S, Fylaktou I, et al. Sertoli cell tumor and gonadoblastoma in an untreated 29-year-old 46,XY phenotypic male with Frasier syndrome carrying a WT1 IVS9+4C>T mutation. *Hormones* 2012;11:361–7.
- Yang Y, Feng D, Huang J, Nie X, Yu Z. A child with isolated nephrotic syndrome and WT1 mutation presenting as a 46, XY phenotypic male. *Eur J Pediatr* 2013;172:127–9.
- Chan WK, To KF, But WM, Lee KW. Frasier syndrome: a rare cause of delayed puberty. *Hong Kong Med J* 2006;12:225–7.
- Tajima T, Sasaki S, Tanaka Y, Kusunoki H, Nagashima T, Nonomura K, et al. 46,XY phenotypic male with focal segmental glomerulosclerosis caused by the WT1 splice site mutation. *Horm Res* 2003;60:302–5.
- Melo KF, Martin RM, Costa EM, Carvalho FM, Jorge AA, Arnhold JJ, et al. An unusual phenotype of Frasier syndrome due to IVS9 +4C>T mutation in the WT1 gene: predominantly male ambiguous genitalia and absence of gonadal dysgenesis. *J Clin Endocrinol Metab* 2002;87:2500–5.
- Denamur E, Bocquet N, Baudouin V, Da Silva F, Veitia R, Peuchmaur M, et al. WT1 splice-site mutations are rarely associated with primary steroid-resistant focal and segmental glomerulosclerosis. *Kidney Int* 2000;57:1868–72.
- Demmer L, Primack W, Loik V, Brown R, Therville N, McElreavey K. Frasier syndrome: a cause of focal segmental glomerulosclerosis in a 46,XX female. *J Am Soc Nephrol* 1999;10:2215–8.
- Kanemoto K, Ishikura K, Ariyasu D, Hamasaki Y, Hataya H, Hasegawa Y, et al. WT1 intron 9 splice acceptor site mutation in a 46,XY male with focal segmental glomerulosclerosis. *Pediatr Nephrol* 2007;22:454–8.
- Yang YH, Zhao F, Feng DN, Wang JJ, Wang CF, Huang J, et al. Wilms' tumor suppressor gene mutations in girls with sporadic isolated steroid-resistant nephrotic syndrome. *Genet Mol Res* 2013;12:6184–91.
- Fujita S, Sugimoto K, Miyazawa T, Yanagida H, Tabata N, Okada M, et al. A female infant with Frasier syndrome showing splice site mutation in Wilms' tumor gene (WT1) intron 9. *Clin Nephrol* 2010;73:487–91.
- Ismaili K, Verdure V, Vandenhoute K, Janssen F, Hall M. WT1 gene mutations in three girls with nephrotic syndrome. *Eur J Pediatr* 2008;167:579–81.
- Aucella F, Biscaglia L, De Bonis P, Gigante M, Caridi G, Barbano G, et al. WT1 mutations in nephrotic syndrome revisited. High prevalence in young girls, associations and renal phenotypes. *Pediatr Nephrol* 2006;21:1393–8.
- Chak WL, To KF, Cheng YL, Tsui KM, Lo KL, Tong HM, et al. Gonadal mosaicism of Frasier syndrome in 3 Chinese siblings with donor splice site mutation of Wilms' tumour gene. *Nephron* 2002;91:526–9.
- Jeanpierre C, Denamur E, Henry I, Cabanis MO, Luce S, Cecille A, et al. Identification of constitutional WT1 mutations, in patients with isolated diffuse mesangial sclerosis, and analysis of genotype/phenotype correlations by use of a computerized mutation database. *Am J Hum Genet* 1998;62:824–33.
- Esin S, Baser E, Kucukozkan T, Magden HA. Ovarian gonadoblastoma with dysgerminoma in a 15-year-old girl with 46, XX karyotype: case report and review of the literature. *Arch Gynecol Obstet* 2012;285:447–51.
- Kanagal DV, Prasad K, Rajesh A, Kumar RC, Cherian S, Shetty H, et al. Ovarian Gonadoblastoma with Dysgerminoma in a Young Girl with 46, XX Karyotype: a Case Report. *J Clin Diagn Res* 2013;7:2021–2.
- Santin S, Bullich G, Tazon-Vega B, Garcia-Maset R, Gimenez I, Silva I, et al. Clinical utility of genetic testing in children and adults with steroid-resistant nephrotic syndrome. *Clin J Am Soc Nephrol* 2011;6:1139–48.