

# An Elevated Hematogenous Photosensitizer in the Preterm Neonate

Leon A. Bynoe,\* John D. Gottsch,\* Srinivas R. Sadda,\* Robert W. Panton,\*  
Emily M. S. Haller,† and Christine A. Gleason‡

**Purpose.** Human blood contains low levels of protoporphyrin IX (PP IX), a photoactive compound that produces reactive oxygen species when exposed to light. It has been proposed that photoactivation of PP IX and subsequent generation of potentially tissue-damaging reactive oxygen may be a mechanism of retinal injury in retinopathy of prematurity (ROP). The purpose of this study is to determine an association between blood PP IX level and infant birth-weight and gestational age.

**Methods.** Erythrocyte PP IX levels were measured from the umbilical cord blood of 31 neonates, both full term and preterm. Birthweights and gestational ages were recorded.

**Results.** PP IX levels in infants weighing < 1000 grams (n = 7) average 200 µg/dl, which is significantly higher than PP IX levels in infants weighing > 1000 grams (125 µg/dl, n = 24; P < 0.02).

**Conclusion.** Elevated PP IX levels may place preterm neonates at increased risk for photosensitizing retinal injury. *Invest Ophthalmol Vis Sci* 1993;34:2878–2880.

Oxygen administration has long been correlated with the development of retinopathy of prematurity (ROP).<sup>1</sup> Recently, light exposure has been added as a possible risk factor for this disease.<sup>2</sup> We have postulated that a third factor, a hematogenous photosensitizer, is necessary to photogenerate reactive oxygen species (such as superoxide anion and singlet oxygen), which initiate injury to nascent capillaries leading to ROP.<sup>3</sup>

Protoporphyrin IX (PP IX) is a potent photosensitizer that is naturally occurring in circulating erythrocytes and represents at least 95% of “free” porphyrin in blood.<sup>4</sup> We have previously demonstrated the light-dependent generation of superoxide anion<sup>5</sup> and hydroxyl radical<sup>6</sup> from human erythrocytes containing normal levels of PP IX. Furthermore, we have also demonstrated light-mediated retinal injury in protoporphyrin mice.<sup>7</sup> In this study, the levels of PP IX in

three groups of neonates at different levels of risk for the development of ROP were measured: full term (>2000 g); preterm (≤2000 g, ≥1000 g); and preterm (<1000 g)

## METHODS

The experimental protocol followed the tenets of the Declaration of Helsinki and was reviewed and approved by the Joint Committee on Clinical Investigation of the Johns Hopkins Medical Institutions. Blood was collected into EDTA-containing vacutainer tubes (Becton-Dickinson, Rutherford, NJ) from the umbilical cord of 31 preterm and full-term neonates at the time of delivery. Birth weight and gestational ages were recorded. Erythrocyte PP IX levels were measured from blood specimens by fluorophotometry.<sup>4</sup> Erythrocyte superoxide dismutase activity was also measured.<sup>8,9</sup> Groups were compared for statistical significance using independent Student's *t*-test.

## RESULTS

The PP IX levels of full-term and preterm neonates were plotted as a function of birth weight (Fig. 1). The blood of neonates weighing <1000 g had an average

From the \*Wilmer Ophthalmological Institute, the †Department of Obstetrics and Gynecology, and the ‡Department of Pediatrics, Johns Hopkins Hospital, Baltimore, Maryland.

Supported in part by a Focused Giving Award from Johnson and Johnson (JJC).  
Submitted for publication October 11, 1992; accepted March 1, 1993.

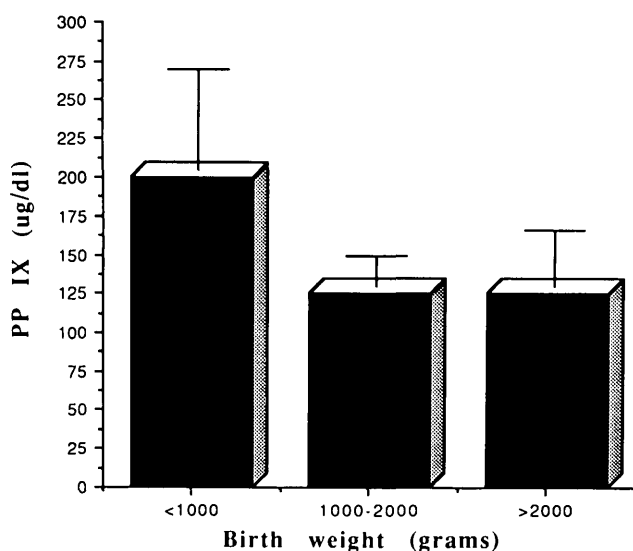
Proprietary interest category: N.

Reprint requests: John D. Gottsch, M.D., the Wilmer Ophthalmological Institute, Johns Hopkins Hospital, Maumenee Building 313, 600 N. Wolfe Street, Baltimore, MD 21205.

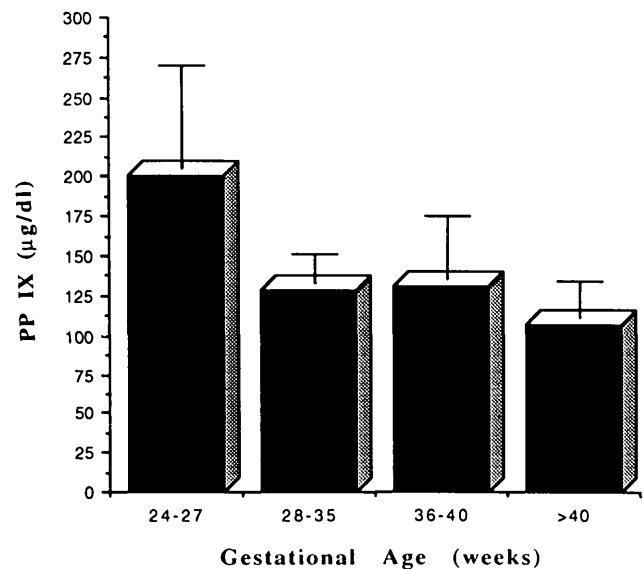
PP IX of  $200 \pm 65 \mu\text{g}/\text{dl}$ , which was significantly higher than neonates weighing  $\geq 1000 \text{ g}$  ( $125 \pm 32 \mu\text{g}/\text{dl}$ ;  $P < 0.02$ ). The PP IX levels were also analyzed with respect to gestational age (Fig. 2). From this figure, it is shown that neonates from 24 to 27 weeks' gestational age had an average PP IX level that was at least 50% higher than other gestational age groups (i.e., for age group 36 to 40 weeks, the PP IX level was  $131 \pm 40 \mu\text{g}/\text{dl}$ ; for  $>40$  weeks, the value was  $107 \pm 23 \mu\text{g}/\text{dl}$ ). Of note is that all infants in the 24 to 27 weeks' gestational age group weighed  $<1000 \text{ g}$ . No significant differences were found in erythrocyte superoxide dismutase activity levels ( $722 \pm 173 \text{ U}/\text{ml}$ ).

## DISCUSSION

This study demonstrates that a potent photosensitizer, PP IX, is significantly elevated in the preterm neonate weighing  $<1000 \text{ g}$  when compared to full-term infants or preterm infants weighing  $\geq 1000 \text{ g}$ . An inverse relationship between birth weight and ROP has been well documented. With light exposure and high oxygen tension, PP IX in erythrocytes could produce singlet oxygen, superoxide anion, and hydroxyl radical,<sup>5,6</sup> which could potentially damage nascent capillaries. A hematogenous photosensitization model of ROP could explain how the factors of increased oxygen tension and light interact to produce the disease. If elevated PP IX is implicated as a factor in ROP, then exposure to blue light should be avoided, because blue light (the Soret band centered at 410 nm) is the excitation wavelength that causes the greatest production of free radicals from PP IX.<sup>3</sup> Although light exposure has



**FIGURE 1.** Erythrocyte PP IX levels of neonates weighing  $<1000 \text{ g}$  ( $n = 7$ ), between 1000 and 2000 g ( $n = 6$ ), and  $>2000 \text{ g}$  ( $n = 18$ ). The PP IX levels were significantly higher in infants weighing  $<1000 \text{ g}$  ( $P < 0.02$ ).



**FIGURE 2.** Erythrocyte PP IX levels plotted against gestational age. The 24- to 27-week age group ( $n = 7$ ) revealed significantly elevated PP IX levels when compared with each of the other age groups ( $P < 0.02$ ). For the age groups 28 to 35, 36 to 40, and  $>40$  weeks,  $n = 7, 12,$  and 5, respectively.

been proposed as a risk factor for ROP,<sup>2</sup> evidence that light exposure does not play a role in the development of ROP was suggested in a study comparing usual lighting and reduced lighting levels in the intensive care nursery.<sup>10</sup> Considering the findings presented herein, perhaps further studies specifically investigating the effect of blue light exposure on preterm infants should be performed.

Physiologic findings in preterm neonates may predispose them to photosensitizing retinal injury. These include the absence of a pupillary light reflex with fixed dilated pupils<sup>11</sup> and a decrease in eyelid closure when the gestational age is less than 28 weeks.<sup>12</sup> All these factors increase the amount of light reaching the retina. Also, ROP has a predilection to develop in the temporal and nasal regions, areas where retinal light dose is highest.<sup>13</sup>

Levels of PP IX in full-term and preterm neonatal cord blood has been reported to be elevated when compared to PP IX levels in adults.<sup>14</sup> We have confirmed this observation and have demonstrated that low birth weight is an important factor in infant PP IX levels (i.e., there was no significant difference in PP IX levels between preterm and full-term neonates weighing  $\geq 1000 \text{ g}$ ). Further study is warranted to determine if infants who develop ROP have higher levels of PP IX at birth or develop higher levels during the high-risk period after birth.

### Key Words

ROP, protoporphyrin IX, hematogenous photosensitization, light exposure, preterm neonate

**References**

1. Patz A, Hoeck LE, De La Cruze E. Studies on the effects of high oxygen administration in retrolental fibroplasia: Nursery observation. *Am J Ophthalmol.* 1952;35:1248-1252.
2. Glass P, Avery GB, Subramanian KS, et al. Effect of bright light in the hospital nursery on the incidence of retinopathy of prematurity. *N Engl J Med.* 1985;313:401-404.
3. Gottsch JD, Pou S, Bynoe LA, Rosen GM. Hematogenous photosensitization: A mechanism for the development of age-related macular degeneration. *Invest Ophthalmol Vis Sci.* 1990;31:1674-1682.
4. Chisolm JJ Jr, Brown DH. Micro-scale photofluorometric determination of 'free erythrocyte porphyrin' (protoporphyrin IX). *Clin Chem.* 1975;21:1669-1689.
5. Bynoe LA, Gottsch JD, Pou S, Rosen, GM. Light-dependent generation of superoxide from human erythrocytes. *Photochem Photobiol.* 1992;56:353-356.
6. Bynoe LA, Pou S, Gottsch JD, Rosen GM. Light-dependent spin trapping of hydroxyl radical from human erythrocytes. *Biochem Biophys Res Comm.* 1991;179:1305-1310.
7. Gottsch JD, Bynoe LA, Harlan JB, Rencs EV, Green WR. Light-induced deposits in Bruch's membrane of protoporphyrin mice. *Arch Ophthalmol.* 1993;111:126-129.
8. McCord JM, Fridovich I. Superoxide dismutase: An enzymatic function for erythrocyte (hemocuprein). *J Biol Chem.* 1969;244:6049-6055.
9. Winterbourn CC, Hawkins RE, Brian M, Carrell RW. The estimation of red cell superoxide dismutase activity. *J Lab Clin Med.* 1975;85:337-341.
10. Ackerman B, Sherwonit E, Williams J. Reduced incidental light exposure: Effect on the development of retinopathy of prematurity in low birthweight infants. *Pediatrics.* 1989;83:958-962.
11. Isenberg SJ, Molarte A, Vasquez M. The fixed and dilated pupils of premature infants. *Am J Ophthalmol.* 1990;110:168-171.
12. Robinson J, Moseley MJ, Thompson JR, Fielder AR. Eyelid opening in preterm neonates. *Arch Dis Childhood.* 1989;64:943-948.
13. Fielder AR, Robinson J, Shaw DE. ROP: Location: A clue to pathogenesis. ARVO Abstracts. *Invest Ophthalmol Vis Sci.* 1990;31:119.
14. Paes B, Andrew M, Milner R, Ali MAM. Developmental changes in red cell creatine and free erythrocyte protoporphyrin in healthy premature infants during the first six months of life. *J Pediatr.* 1987;111:745-747.