

How I treat hemophagocytic lymphohistiocytosis in the adult patient

Alison M. Schram¹ and Nancy Berliner^{1,2}

¹Department of Medicine and ²Division of Hematology, Department of Medicine, Brigham and Women's Hospital, Harvard Medical School, Boston, MA

Hemophagocytic lymphohistiocytosis (HLH) is a devastating disorder of uncontrolled immune activation characterized by clinical and laboratory evidence of extreme inflammation. This syndrome can be caused by genetic mutations affecting cytotoxic function (familial HLH) or be secondary to infectious, rheumatologic, malignant, or metabolic conditions (acquired HLH). Prompt recognition is paramount and, without early treatment, this disorder is frequently fatal. Although HLH is well described in the pediatric population, less is known about the appropriate work-up and treatment in adults. Here, we review the clinical characteristics, diagnosis, and treatment of HLH in adults. (*Blood*. 2015; 125(19):2908-2914)

Introduction

Hemophagocytic lymphohistiocytosis (HLH) is a rare and devastating disorder of uncontrolled immune activation that has gained increasing recognition over the past decade. Patients with HLH present with clinical and laboratory evidence of extreme inflammation.¹ This syndrome was first described in 1939 by Scott and Robb-Smith and again in 1952 when Farquhar and Claireaux reported a case of 2 infant siblings with progressive and fatal cytopenias, hepatosplenomegaly, and fevers with autopsy showing hemophagocytosis.^{2,3} This same constellation of symptoms has been subsequently described in both the pediatric and adult populations. In recent years, HLH has attracted growing attention due to an apparent inexplicable rise in the incidence of the disorder. The incidence of HLH in pediatrics is estimated as 1 to 225 per 300 000 live births and varies by geographic region.⁴⁻⁶ Although the incidence in the adult population is unknown, the number of cases reported in the literature has dramatically increased over the past 10 years. HLH is categorized as primary (familial) or secondary (acquired). Primary HLH is caused by genetic mutations affecting the cytotoxic function of T lymphocytes and natural killer (NK) cells and typically presents in young children. Secondary (acquired) HLH occurs in the setting of infectious, malignant, rheumatologic, or metabolic conditions. Occasionally, an inciting event is not identified and HLH is considered idiopathic. Although these entities are classically felt to be distinct, there is support for the idea that many patients with HLH have an underlying genetic predisposition. Although the causes, clinical presentation, and appropriate treatment of HLH may be different in the older age group, our understanding of HLH in the adult setting derives primarily from research in pediatrics. This review highlights 3 cases of adult HLH and discusses a clinical approach to this illness in adults.

Case 1

A previously healthy 30-year-old man presented with 2 weeks of fatigue, cough, and fevers to 102.9°F. He was noted to have splenomegaly, pancytopenia with an absolute neutrophil count (ANC) of 726, elevated ferritin of 924 µg/L, elevated transaminases, and diffuse pulmonary infiltrates on chest computed tomography (CT) scan. He was begun on

empiric broad-spectrum antibiotics. Bone marrow biopsy revealed a hypercellular marrow with maturing trilineage hematopoiesis, virtually absent iron stores, and very rare hemophagocytosis. Bone marrow flow cytometry showed no clonal populations. Extensive infectious work-up including Epstein-Barr virus (EBV) viral load, cytomegalovirus (CMV) viral load, and a bronchoscopy with biopsies revealed no source of infection. He was diagnosed with HLH and was started on the HLH-94 protocol with etoposide and dexamethasone.¹ He tolerated the chemotherapy well. Ferritin levels peaked at 1600 µg/L and subsequently declined. Positron emission tomography (PET)-CT scanning was negative and repeat bone marrow biopsy was hypocellular with no evidence of hemophagocytosis. He was discharged on dexamethasone 10 mg daily without etoposide but returned 12 days later with a fever of 102°F and epistaxis. He was restarted on etoposide. Molecular genetic analysis demonstrated a homozygous T272C (A91V) mutation in the gene encoding perforin 1 (PRF1), a gene commonly implicated in primary HLH. He was given alemtuzumab followed by matched related donor reduced-intensity conditioning (RIC) hematopoietic stem cell transplantation (HSCT). He engrafted successfully and has had no recurrent HLH >1 year after transplant.

Case 2

A 66-year-old woman with a history of hypertension, hyperlipidemia, and Hashimoto thyroiditis presented with 3 months of severe fatigue, fevers, oral ulcers, and dyspnea. She initially sought care from her primary care physician and was given steroids for presumed asthma. After several months with no improvement, she was hospitalized for further evaluation. While an inpatient, she was noted to have daily fevers to 102°F, mild-moderate pancytopenia, elevated transaminases, and bilateral chronic pulmonary emboli on imaging. Extensive cardiac, rheumatologic, and infectious work-up was unrevealing. A bone marrow biopsy was performed and was suggestive of evolving myelodysplastic syndrome. She was discharged and followed as an outpatient by hematology, where she had fevers to 102.7°F in clinic, a 30-lb weight loss, and profound fatigue. PET-CT scanning was essentially unremarkable. She was readmitted for

Submitted January 6, 2015; accepted March 2, 2015. Prepublished online as *Blood* First Edition paper, March 10, 2015; DOI 10.1182/blood-2015-01-551622.

© 2015 by The American Society of Hematology

neutropenic fever and worsening pancytopenia, transaminitis, hyperbilirubinemia, hypofibrinogenemia, and rising ferritin (peak 2949 $\mu\text{g/L}$). She underwent percutaneous liver biopsy, which showed extensive inflammation and an intense histiocytic infiltrate without frank hemophagocytosis. Unfortunately, liver biopsy was complicated by damage to the right hepatic artery necessitating embolization and subsequent transfer to the medical intensive care unit. Despite no further bleeding, she became rapidly hypotensive requiring vasopressor support and had persistent fevers to 104°F. Repeat bone marrow biopsy showed clear hemophagocytosis and she was diagnosed with HLH. Notably, she had no splenomegaly or hypertriglyceridemia, soluble CD25 was only mildly elevated at 1159 U/mL, and NK cell function was not sent. She was started on prednisone 1 mg/kg followed by the HLH-94 treatment protocol and was rapidly weaned off vasopressors, extubated, and laboratory derangements improved. She was discharged and did well for 2 months on etoposide/dexamethasone with return to her prior functional status. One week after completing therapy, her symptoms recurred with worsening laboratory abnormalities. She was started on the maintenance phase of HLH-94 with cyclosporine in addition to etoposide/dexamethasone. This was complicated by cyclosporine-induced renal failure and posterior reversible encephalopathy syndrome. The decision was made to pursue stem cell transplant. She underwent a matched unrelated donor RIC HSCT. She did well, with no further evidence of HLH. Unfortunately, she developed graft-versus-host disease of the liver and recurrent pulmonary emboli 9 months after transplant resulting in multiorgan failure and death.

Case 3

A 38-year-old man was referred to our institution with a new diagnosis of primary cutaneous $\gamma\delta$ T-cell lymphoma. He had been in excellent health until 3 months prior when he presented to his primary care physician with persistent symptoms of sinusitis. Despite treatment with a course of antibiotics, his symptoms progressed and he developed drenching night sweats, anorexia with 40-lb weight loss, fatigue, and multiple subcutaneous nodules on his trunk and legs. An extensive work-up revealed primary cutaneous $\gamma\delta$ T-cell lymphoma and he was referred to our institution for treatment. On initial evaluation, he was found to also have HLH with splenomegaly in addition to thrombocytopenia, borderline neutropenia, hypofibrinogenemia, hypertriglyceridemia, elevated transaminases, hyperferritinemia, and elevated soluble interleukin-2 receptor (sIL2R). He was started on an etoposide-containing chemotherapy regimen with 2 cycles of cyclophosphamide, doxorubicin, etoposide, vincristine, and prednisone (CHOEP). Follow-up PET scan showed a mixed response, so this was stopped and he received 3 cycles of gemcitabine-oxaliplatin (GEM-OX)X followed by 2 cycles of romidepsin. This course was complicated by multiple admissions for fever and an episode of *Clostridium difficile*. His lymphoma initially responded well to this therapy but he was admitted 5 months after initial presentation with progressive disease. He was started on dexamethasone and ifosfamide, carboplatin, and etoposide (ICE) but unfortunately shortly after initiation developed worsening mental status, and treatment goals were changed to comfort measures. Autopsy revealed widespread lymphoma in addition to fungal bronchopneumonia and evidence of candidemia.

Pathophysiology and classification of HLH

The clinical and laboratory manifestations of HLH are produced by an overactive but ineffective immune system. The reasons for this immune

dysregulation vary and the syndrome is categorized as either primary (familial) or secondary (acquired). Primary HLH typically presents in the first year of life with or without a positive family history. It is a recessive condition caused by mutations in genes important for NK and T-cell granule-mediated cytotoxic function.^{7,8}

When a cytotoxic T lymphocyte or NK cell encounters an infected cell or tumor cell, a series of coordinated steps are required for an effective cytotoxic response. This includes the trafficking, docking, priming, membrane fusion, and entry of cytotoxic granules into the target cell leading to apoptosis. Perforin, a protein found in the granules, inserts into the target cell's membrane forming a pore that leads to osmotic lysis and assists in the penetration of granzymes.^{9,10} Effective cell lysis dampens the immune response by decreasing antigen stimulation and triggering activation-induced cell death.

Homozygous null mutations in several genes important for these functions have been implicated in primary HLH and cause familial hemophagocytic lymphohistiocytosis (FHL) subtypes FHL2-FHL5. These include *PRF1*, *UNC13D* (MUNC13-4), *STX11*, and *STXBP2* (MUNC18-2), respectively.^{9,11-15} The gene responsible for FHL1 has not been identified but has been localized to a region on 9q21.¹⁶ These mutations cause impaired cytotoxic function and lead to an uncontrolled inflammatory response with the activation and expansion of interferon γ (IFN γ)-producing T cells. High levels of IFN γ lead to macrophage activation and overproduction of proinflammatory cytokines, which can cause severe tissue damage and organ failure. In patients with known genetic defects or a family history of HLH, the syndrome may present sporadically, but usually presents in association with an identifiable trigger (most often EBV). Patients with congenital immune-deficiency syndromes can also develop HLH due to mutations in genes that regulate immune function, including *LYST* (Chédiak-Higashi syndrome), *AP3B1* (Hermansky-Pudlak syndrome type 2), *RAB27A* (Griscelli syndrome type 2), *SH2D1A* (X-linked lymphoproliferative disease [XLP] type 1), *BIRC4/XIAP* (XLP type 2), *IL2RG* (X-linked severe combined immunodeficiency [X-SCID]), and IL-2-inducible T cell kinase [ITK].¹⁷⁻²³

The term secondary (acquired) HLH describes patients with the HLH phenotype in the absence of a known genetic cause. It can occur in children or adults, typically in the setting of immunodeficiency or an underlying malignant, infectious, or autoimmune disorder.²⁴⁻³² When HLH arises in association with rheumatologic disease, it is termed macrophage activation syndrome (MAS). MAS is most commonly seen in association with adult-onset Still disease, systemic juvenile idiopathic arthritis, and systemic lupus erythematosus but has also been described in other rheumatologic conditions.³³⁻³⁵ The common malignancies associated with HLH include non-Hodgkin lymphoma and acute leukemia. Various infections have been described as triggers, including viral, bacterial, fungal, and parasitic infections. HLH can occur as the initial presentation of the underlying disorder or later in the course, occasionally in the setting of disease progression or the addition of an additional trigger. A retrospective study at Mayo Clinic identified 62 adults with HLH. The majority had a malignancy (52%), followed by infection (34%), autoimmune disorder (8%), and an idiopathic cause of HLH (6%). The most common malignancy observed was T-cell lymphoma (59%) and the most frequent infection was EBV (26%).²⁵ Recently, a large study in France identified 162 adult patients with HLH.²⁴ Again, the most common associated conditions were malignancy (60%), infection (25%), and autoimmune disorders (3%). The most common malignancy in this cohort was B-cell lymphoma (22%) and the most prevalent infection was *Mycobacterium* (8%). Notably, nearly half of these patients were immunosuppressed at presentation due to either HIV infection or immunosuppressive therapy. Case series

Table 1. Diagnostic guidelines for HLH

Guidelines
The diagnosis of HLH requires a molecular diagnosis consistent with HLH or 5 of 8 of the below criteria
1. Fever
2. Splenomegaly
3. Cytopenias affecting ≥ 2 lineages
a. Hemoglobin < 9 g/dL
b. Platelets $< 100 \times 10^9/L$
c. Neutrophils $< 1.0 \times 10^9/L$
4. Hypertriglyceridemia and/or hypofibrinogenemia
a. Triglycerides ≥ 265 mg/dL
b. Fibrinogen ≤ 150 mg/dL
5. Hemophagocytosis in bone marrow, spleen, or lymph nodes
6. Low or absent NK cell activity
7. Ferritin ≥ 500 $\mu\text{g/L}$
8. sCD25 (ie, sIL2R) ≥ 2400 U/mL

from Japan and China show similar results, with malignancy and infection as leading causes of secondary HLH.^{26,27}

Although primary HLH is almost uniformly inherited in an autosomal-recessive manner, Zhang et al and others have identified heterozygous mutations in *PRF1*, *UNC13D*, and *STXBP2* in adults with HLH.^{36,37} Many of these mutations occurred with increased frequency compared with controls and the expected rates from single nucleotide polymorphism databases. Functional prediction models led the authors to postulate that these changes represented hypomorphic alleles. A recent paper from the same group reported a cohort of patients with heterozygous mutations in 2 known HLH genes, suggesting a possible digenic mode of inheritance.³⁸ In patients with systemic juvenile idiopathic arthritis, a specific haplotype within the *UNC13D* gene encoding MUNC13-4 is associated with the development of MAS.³⁹ Patients with MAS have also been found to harbor mutations in other HLH genes, including *STXBP2* and *PRF1*.⁴⁰ Additional studies are needed to better elucidate the functional significance of these genetic alterations. The *PRF1* variant 272C>T (p.Ala91Val) reported in Case 1 has been extensively studied and remains somewhat controversial. It is found at a relatively high allele frequency in population databases and control groups (0% to 9%), which has led some to term it a neutral polymorphism.⁴¹⁻⁴⁴ However, several studies have reported functional consequences of this variant including decreased *PRF1* expression, reduced lytic activity, and impaired NK cell-mediated cytotoxicity.⁴⁵⁻⁴⁸ Additionally, functional prediction models including Polyphen-2 and the sorting intolerant from tolerant (SIFT) algorithm imply that this change is damaging. Primary HLH and secondary HLH have historically been considered separate entities; however, these new genetic insights and the observation that primary HLH is often set off by a trigger suggest that there may be more overlap than previously recognized.⁴⁹

Diagnosis and evaluation

Hemophagocytic lymphohistiocytosis is diagnosed by a constellation of signs, symptoms, and laboratory abnormalities. The presenting symptoms are often nonspecific and a high index of suspicion is necessary for prompt identification and treatment. Early diagnosis is essential because without treatment HLH is frequently fatal. In 2004, The Histiocyte Society proposed an updated set of criteria to aid in identification of patients with HLH for clinical trials (Table 1).⁵⁰ These include molecular testing consistent with HLH or 5 of 8 of the

following criteria: fever, splenomegaly, cytopenias affecting ≥ 2 lineages, hypertriglyceridemia and/or hypofibrinogenemia, hemophagocytosis (in bone marrow, spleen, or lymph node), hyperferritinemia, impaired NK cell function, and elevated soluble CD25 (sCD25) (ie, sIL2R). Additional findings that are common are transaminitis, coagulopathy, hyponatremia, edema, rash, hypoalbuminemia, elevated lactate dehydrogenase (LDH), C-reactive protein, and D-dimer, increased very low-density lipoprotein, decreased high-density lipoprotein, elevated cerebrospinal fluid protein and cells, and neurologic symptoms ranging from focal deficits to altered mental status.^{24,25,27,32,50} Patients may not have all of these features on initial presentation, making diagnosis challenging. It is important to note that these criteria were developed for the diagnosis of pediatric HLH, but have been widely applied to patients with secondary HLH, including adults. There is currently no universally accepted set of criteria for diagnosing HLH in the adult population.

The diagnosis of HLH is particularly challenging because the symptoms are nonspecific and many features overlap with other causes of severe illness including sepsis and hematologic malignancy. Importantly, these same disorders can trigger HLH, further complicating the diagnosis. The largest obstacle is often considering HLH in the differential diagnosis. For example, patient 2 above was referred to our hospital for tertiary care evaluation after 3 months of unexplained fever and constitutional symptoms, and nearly died early in the course of her evaluation. This is not atypical for the presentation of HLH.

Once the diagnosis is entertained, relevant studies should be sent promptly, including a complete blood count, triglycerides, fibrinogen, ferritin, and sCD25. sCD25 is not readily available at all institutions and can take time to return, but it is helpful for diagnosis and correlates with disease severity more reliably than other markers.⁵¹ Additionally, a high CD25 to ferritin ratio is seen more often in lymphoma-associated HLH and may be a useful marker to distinguish this entity from other causes of HLH (ratio, 8.56 vs 0.66 with $P = .0004$).⁵² We suggest sending this test in every patient but not delaying treatment while waiting for the result if the diagnosis of HLH is otherwise clear. The macrophage-specific scavenger receptor CD163 has also been shown to significantly increase in states of macrophage activation.⁵³ It is a useful marker for HLH but can also be increased in other inflammatory disorders that cause macrophage activation.⁵⁴ Fibrinogen is an acute-phase reactant that is elevated in most inflammatory disorders but is low in HLH. Similarly, erythrocyte sedimentation rate (ESR) is low in HLH secondary to decreased fibrinogen levels.

Elevated ferritin occurs in the vast majority of patients with HLH but is nonspecific. The published criteria use a ferritin cutoff value of ≥ 500 $\mu\text{g/L}$ when diagnosing HLH. This is based on the HLH-94 study that showed a sensitivity of 84% at this level. Subsequent studies have demonstrated that a higher threshold of $\geq 10\,000$ $\mu\text{g/L}$ has a 90% sensitivity and 96% specificity for HLH.⁵⁵ Like most of the literature on HLH, these studies were carried out in the pediatric population. At our institution, using a population of only adults, we found that there was no level above which ferritin was specific for HLH.⁵⁶ Of 113 patients identified with ferritin levels $> 50\,000$ $\mu\text{g/L}$, only 19 had HLH. This suggests that although significantly elevated ferritin might be specific for HLH in the pediatric setting, this does not hold true in adults. Of 50 adult patients identified at our institution with HLH, the median ferritin level on presentation was 5823 $\mu\text{g/L}$ (minimum 461 $\mu\text{g/L}$ and maximum 98 110) and the median maximum ferritin level was 19 687 $\mu\text{g/L}$ (minimum 1618 $\mu\text{g/L}$ and maximum 202 911 $\mu\text{g/L}$).

Although hemophagocytosis is the pathologic hallmark of HLH, it is important to note that it is neither sensitive nor specific. The prevalence of hemophagocytosis in the bone marrow of HLH patients ranges from 25% to 100% and reads often vary between pathologists.^{24,25,51,57}

Table 2. Scoring systems for the diagnosis of secondary HLH

HScore	Delphi study
Known underlying immunodepression	Predisposing underlying disease
High temperature	Fever
Organomegaly	Organomegaly
Hyperferritinemia	Hyperferritinemia
Cytopenia	Cytopenia
Hemophagocytosis	Hemophagocytosis
Hypertriglyceridemia	Elevated LDH
Hypofibrinogenemia	
Elevated SGOT/ALT	

ALT, alanine aminotransferase; SGOT, serum glutamic oxaloacetic transaminase.

Additionally, it can be commonly found in critically ill patients in the absence of HLH.^{58,59} Nevertheless, the evaluation of suspected HLH should include a bone marrow biopsy. In the first 2 cases above, hemophagocytosis was eventually described in the bone marrow, but was not definitively diagnosed on the initial marrow examination in either patient. The sensitivity of finding hemophagocytosis in the marrow is increased by staining for CD163, which specifically highlights macrophages. However, as in these patients, finding hemophagocytosis in the marrow usually requires anticipation of the diagnosis, as well as the request for special stains.

NK cell activity is part of the diagnostic criteria for pediatric HLH but this test is rarely helpful in the adult population, and we do not send it. This test was not performed in any of the described patients.

Recently, multiple groups have suggested more standardized criteria for the diagnosis of secondary HLH. Fardet et al created and validated the HScore, which includes 9 weighted variables.⁶⁰ This scoring system is available online (<http://saintantoine.aphp.fr/score/>). A web-based Delphi study by a panel of experts compiled a similar list of criteria (Table 2).⁶¹ These newly proposed criteria are a step toward improving the diagnosis of HLH in adults.

Our approach to the evaluation and treatment of HLH is outlined in Figure 1. As previously noted, many patients with HLH are referred to a tertiary care center after prolonged evaluation at an outside hospital and we aim to assess them as quickly as possible and start HLH-specific therapy if appropriate. Patients should be questioned about recent infections, malignancy, underlying immune disorders, pharmacologic immunosuppression, rheumatologic conditions, and family history of similar symptoms. A cardiopulmonary examination is necessary and every patient should also be evaluated for hepatosplenomegaly, lymphadenopathy, rashes, neurologic abnormalities, and evidence of bleeding or bruising. For better assessment of splenomegaly, consider an abdominal ultrasound. In addition, all patients should have a basic metabolic panel, coagulation studies (prothrombin time, activated partial thromboplastin time), liver function tests, LDH, and albumin. If no trigger is readily identified, a work-up for infectious causes is warranted including blood cultures, urinalysis, urine cultures, thin and thick blood smear, chest x-ray, purified protein derivative (or T-spot), viral titers, and serology (EBV, CMV, influenza, hepatitis C virus, hepatitis B virus, herpes simplex virus, Varicella zoster virus, parvovirus, adenovirus, measles virus, human herpesvirus 8, HIV). Elevated EBV viral load can be a consequence of immune suppression or in EBV-driven lymphoma and does not necessarily suggest that EBV triggered HLH. EBV usually triggers HLH in the setting of a newly acquired lytic EBV infection, which is more common in children. Initial evaluation for malignancy should include peripheral flow cytometry, PET-CT scanning, and bone marrow biopsy. Rheumatologic work-up typically includes testing for antinuclear antibody, in addition to more specific studies based on

clinical suspicion. We have found that PET-CT scanning often reveals marked activity in the spleen in the absence of active adenopathy in patients with idiopathic HLH. We support sending genetic testing for the known HLH mutations, including *PRF1*, *UNC13D*, *STX11*, *STXBP2*, and *RAB27A*, although treatment should not be delayed for the results and negative results are common in adults. We do not routinely send flow for surface expression of perforin or granzyme B in adults. In anticipation of treatment, it is often useful to send HLA typing and perform a cardiac echocardiogram.

Treatment and prognosis

The treatment of HLH is designed to halt any underlying trigger and control the overactive immune system. If a malignancy or infection is identified, disease-specific treatment should be initiated immediately. In cases of lymphoma-associated HLH, treatment with an etoposide-containing chemotherapy regimen should be strongly considered (as in Case 3). These measures are occasionally sufficient to break the immune dysregulation. Additional immunosuppressive therapy should be initiated immediately in severe cases and in those that fail to respond to disease-specific therapy after 2 to 3 days. In circumstances with no clear precipitant, a known genetic predisposition, or EBV infection, an etoposide-based regimen should be started without delay.

In 1980, etoposide was reported to successfully treat 2 patients with HLH.⁶² It has subsequently been tested in large studies and is considered standard of care.^{1,63,64} Etoposide works by inhibiting topoisomerase II, leading to double-stranded DNA breaks.⁶⁵ In a murine model of HLH, only etoposide, methotrexate, and cyclophosphamide improved objective signs of disease, laboratory abnormalities, and survival. Notably, dexamethasone had minimal benefit. Etoposide selectively depleted activated T cells leading to suppression of inflammatory cytokines and improved survival, suggesting that T-cell deletion, rather than suppression of activation, was most effective.⁶⁶ Nonetheless, standard treatment of HLH includes the addition of a steroid to etoposide for further suppression of hypercytokinemia and inflammation.⁶⁷ Patients with a known predisposition to HLH, recurrent disease, or no clear precipitating cause should ultimately be taken to allogeneic bone marrow transplant. Before the use of stem cell transplant in primary HLH, nearly all patients relapsed and died.⁶⁸ In 1986, Fischer et al described the first cure for primary HLH through allogeneic HSCT.⁶⁹ Since that time, HSCT has become a mainstay of treatment in pediatric HLH and is increasingly used in adults with recurrent HLH or HLH with a known genetic predisposition. Bone marrow transplant should be avoided in individuals with active disease because of cytokine storm and increased risk of graft-versus-host disease. Alemtuzumab, a monoclonal antibody to CD52, destroys mature lymphocytes and can be used in patients with active disease who need a bridge to transplant (as in Case 1) or in those who are transplant ineligible.^{70,71}

There are no prospective trials guiding treatment of HLH in adults. Treatment in adults has been based on the HLH-94 study, a large prospective pediatric study conducted by The Histiocyte Society in patients <16 years old with no history of immunosuppression or malignancy. This study investigated a treatment regimen that included an 8-week induction with dexamethasone and etoposide. If neurologic symptoms were present, they also received intrathecal methotrexate. If familial disease or relapsing disease was present, the patient received maintenance therapy with dexamethasone pulses, cyclosporine daily, and etoposide until he or she was able to undergo stem cell transplant.¹ This regimen resulted in improved outcomes but there were a significant number of early relapses.^{1,63} This prompted

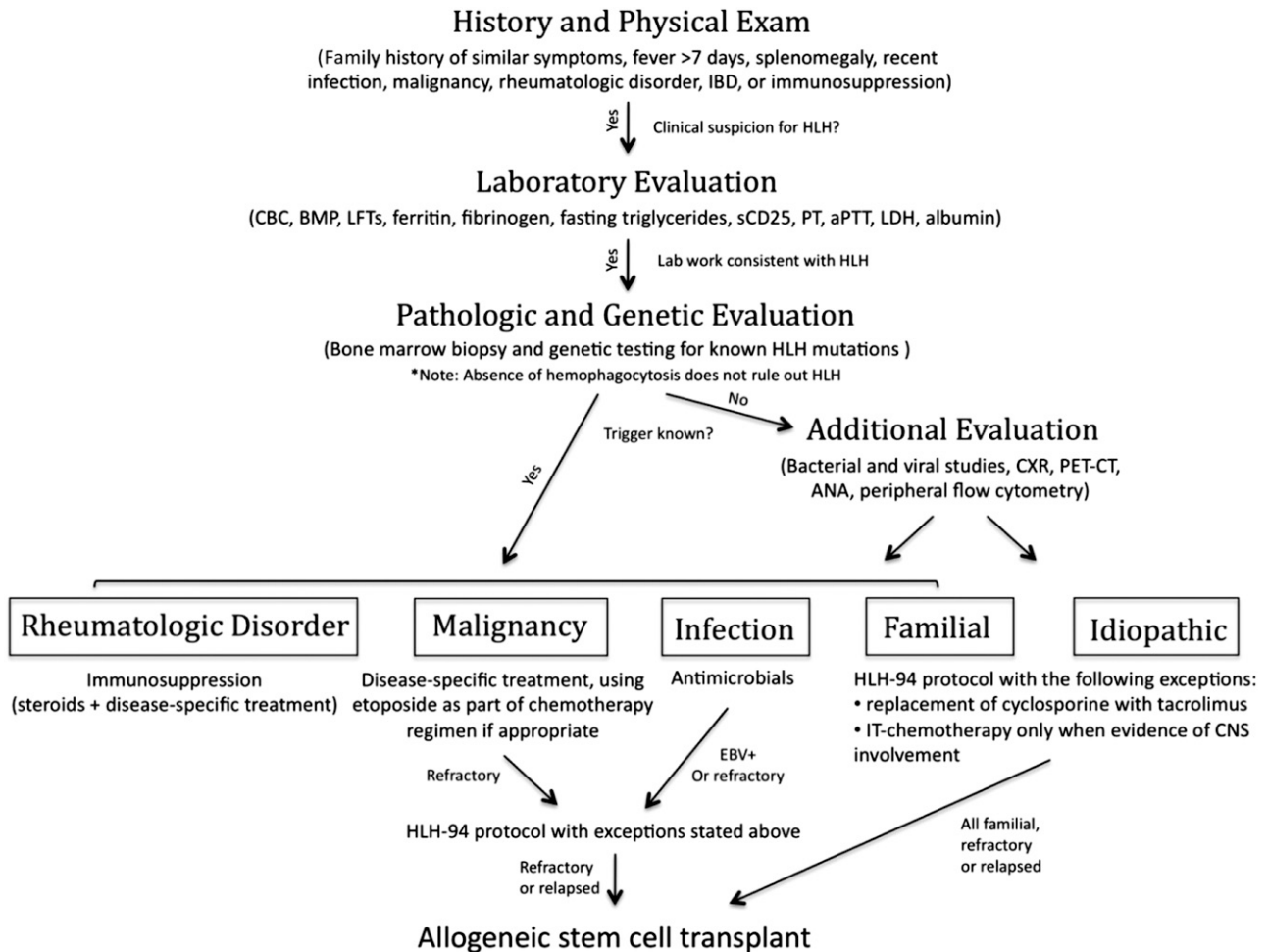


Figure 1. Schematic algorithm of our approach to the diagnosis and treatment of adult HLH.

HLH-2004, an ongoing prospective study that includes the addition of cyclosporine during induction (target trough 200 mg/L).

In adults, we recommend an 8-week induction with etoposide (150 mg/m²) in patients with HLH but not MAS. This is based on the HLH-94 protocol, consisting of twice-weekly dosing for the first 2 weeks and weekly dosing thereafter. Patients with liver dysfunction are dose reduced by 50% to 75%, with an increase in dose as liver function improves. Those with renal failure should also have dosing adjustments (reduce by 25% in CrCl 10-50 mL per minute, 50% in <10 mL per minute). Because etoposide is albumin-bound, profound depression of albumin, as occurs in some patients, may increase the effective dosing of etoposide. Although this may result in increased cytopenias, we do not usually adjust the dose for albumin. We typically administer etoposide regardless of blood counts. Dexamethasone is administered as outlined in the HLH-94 protocol; in acutely ill patients, it is begun intravenously, but is then dosed orally for 8 weeks as outlined in the HLH-94 protocol. In general, we delay the introduction of calcineurin inhibitors until after the initial 8 to 12 weeks of therapy. Although the original protocol called for cyclosporine, we often use tacrolimus as it appears slightly less nephrotoxic. In Case 2, cyclosporine was not tolerated and the patient suffered renal failure and posterior reversible encephalopathy syndrome. Central nervous system involvement with HLH is much less common in adults than in children; consequently, we do not routinely administer intrathecal methotrexate to adults.

We believe that adults who are candidates for transplant should undergo allogeneic stem cell transplant if they have refractory or relapsed disease. In pediatrics, an RIC regimen improves survival compared with the classic myeloablative approach.^{72,73} Based on these data, we favor RIC transplants with a preparative regimen including alemtuzumab followed by fludarabine and busulfan. In patients who initially respond to HLH treatment but later recur, etoposide and dexamethasone are initially restarted with the goal of eventual stem cell transplant. If they do not respond rapidly, we treat patients with alemtuzumab. Similarly, if symptoms and signs of HLH recur while etoposide and dexamethasone are being tapered, the doses are increased with transition to alemtuzumab if the HLH is not controlled. Patients on HLH treatment are at high risk for infection and should receive *Pneumocystis carinii* and fungal prophylaxis. Supportive care with appropriate blood products should be given as needed.

Patients with MAS should be treated initially with steroids alone and typically do not require etoposide. When response is inadequate, additional immunosuppressive agents that address the underlying rheumatologic disorder are recommended rather than HLH-specific therapy.

Response to treatment is determined by clinical and laboratory evidence of resolution, including improved splenomegaly, lymphadenopathy, fever curve, ferritin, sIL2R, liver function tests, and fibrinogen. We monitor the ferritin level during and after treatment, as this seems to correlate with disease activity. Using leukopenia,

anemia, and thrombocytopenia as disease markers is problematic given etoposide's bone marrow suppressive effects.

Primary HLH is almost universally fatal without treatment.⁶⁸ The mortality of secondary HLH and HLH in adults without treatment is high, but the statistics are limited by the small number of cases. Case series of adults treated with a variety of regimens report a 30-day mortality of 20% to 44% and overall mortality of 50% to 75%.^{25-27,31,74,75} Patients with HLH associated with malignancy suffer a worse prognosis.^{25,26,74,76} HLH therapy, including stem cell transplant, has revolutionized the treatment and can result in long-term survival and cure.

Summary

HLH is a syndrome of uncontrolled immune activation that has become increasingly recognized over the past decade. It can be due to an underlying defect in cytotoxic function or secondary to a trigger, frequently in the setting of immunosuppression or a genetic predisposition. In adults, HLH is often associated with a malignant,

infectious, or autoimmune disorder. Early recognition is crucial and without prompt treatment HLH is often fatal. Treatment includes targeting the underlying disorder and controlling the immune dysregulation. Etoposide, dexamethasone, and ultimately HSCT are the mainstay for the majority of patients with HLH. Further studies are required to improve our understanding of the optimal treatment of HLH in adults.

Authorship

Contribution: A.M.S. wrote the first draft of the manuscript in consultation with N.B.; and A.M.S. and N.B. jointly edited and completed the manuscript.

Conflict-of-interest disclosure: The authors declare no competing financial interests.

Correspondence: Nancy Berliner, Division of Hematology, Brigham and Women's Hospital, 75 Francis St, Mid-Campus 3, Boston, MA 02115; e-mail: nberliner@partners.org.

References

- Henter J-I, Samuelsson-Horne A, Aricò M, et al; Histocyte Society. Treatment of hemophagocytic lymphohistiocytosis with HLH-94 immunochemotherapy and bone marrow transplantation. *Blood*. 2002;100(7):2367-2373.
- Scott RB, Robb-Smith AHT. Histiocytic medullary reticulosis. *Lancet*. 1939;234(6047):194-198.
- Farquhar JW, Claireaux AE. Familial haemophagocytic reticulosis. *Arch Dis Child*. 1952;27(136):519-525.
- Henter JI, Elinder G, Söder O, Ost A. Incidence in Sweden and clinical features of familial hemophagocytic lymphohistiocytosis. *Acta Paediatr Scand*. 1991;80(4):428-435.
- Gürgey A, Göğüş S, Ozyürek E, et al. Primary hemophagocytic lymphohistiocytosis in Turkish children. *Pediatr Hematol Oncol*. 2003;20(5):367-371.
- Ishii E, Ohga S, Tanimura M, et al; Japan LCH Study Group. Clinical and epidemiologic studies of familial hemophagocytic lymphohistiocytosis in Japan. *Med Pediatr Oncol*. 1998;30(5):276-283.
- Chandrakasan S, Filipovich AH. Hemophagocytic lymphohistiocytosis: advances in pathophysiology, diagnosis, and treatment. *J Pediatr*. 2013;163(5):1253-1259.
- Filipovich AH. The expanding spectrum of hemophagocytic lymphohistiocytosis. *Curr Opin Allergy Clin Immunol*. 2011;11(6):512-516.
- Voskoboinik I, Smyth MJ, Trapani JA. Perforin-mediated target-cell death and immune homeostasis. *Nat Rev Immunol*. 2006;6(12):940-952.
- de Saint Basile G, Ménasché G, Fischer A. Molecular mechanisms of biogenesis and exocytosis of cytotoxic granules. *Nat Rev Immunol*. 2010;10(8):568-579.
- Stepp SE, Dufourcq-Lagelouse R, Le Deist F, et al. Perforin gene defects in familial hemophagocytic lymphohistiocytosis. *Science*. 1999;286(5446):1957-1959.
- Feldmann J, Callebaut I, Raposo G, et al. Munc13-4 is essential for cytolytic granules fusion and is mutated in a form of familial hemophagocytic lymphohistiocytosis (FHL3). *Cell*. 2003;115(4):461-473.
- zur Stadt U, Rohr J, Seifert W, et al. Familial hemophagocytic lymphohistiocytosis type 5 (FHL-5) is caused by mutations in Munc18-2 and impaired binding to syntaxin 11. *Am J Hum Genet*. 2009;85(4):482-492.
- zur Stadt U, Schmidt S, Kasper B, et al. Linkage of familial hemophagocytic lymphohistiocytosis (FHL) type-4 to chromosome 6q24 and identification of mutations in syntaxin 11. *Hum Mol Genet*. 2005;14(6):827-834.
- Côte M, Ménager MM, Burgess A, et al. Munc18-2 deficiency causes familial hemophagocytic lymphohistiocytosis type 5 and impairs cytotoxic granule exocytosis in patient NK cells. *J Clin Invest*. 2009;119(12):3765-3773.
- Ohadi M, Lalloz MR, Sham P, et al. Localization of a gene for familial hemophagocytic lymphohistiocytosis at chromosome 9q21.3-22 by homozygosity mapping. *Am J Hum Genet*. 1999;64(1):165-171.
- Rubin CM, Burke BA, McKenna RW, et al. The accelerated phase of Chediak-Higashi syndrome. An expression of the virus-associated hemophagocytic syndrome? *Cancer*. 1985;56(3):524-530.
- Enders A, Zieger B, Schwarz K, et al. Lethal hemophagocytic lymphohistiocytosis in Hermansky-Pudlak syndrome type II. *Blood*. 2006;108(1):81-87.
- Ménasché G, Pastural E, Feldmann J, et al. Mutations in RAB27A cause Griscelli syndrome associated with haemophagocytic syndrome. *Nat Genet*. 2000;25(2):173-176.
- Arico M, Imashuku S, Clementi R, et al. Hemophagocytic lymphohistiocytosis due to germline mutations in SH2D1A, the X-linked lymphoproliferative disease gene. *Blood*. 2001;97(4):1131-1133.
- Rigaud S, Fondanèche M-C, Lambert N, et al. XIAP deficiency in humans causes an X-linked lymphoproliferative syndrome. *Nature*. 2006;444(7115):110-114.
- Grunebaum E, Zhang J, Dadi H, Roifman CM. Haemophagocytic lymphohistiocytosis in X-linked severe combined immunodeficiency. *Br J Haematol*. 2000;108(4):834-837.
- Huck K, Feyen O, Niehues T, et al. Girls homozygous for an IL-2-inducible T cell kinase mutation that leads to protein deficiency develop fatal EBV-associated lymphoproliferation. *J Clin Invest*. 2009;119(5):1350-1358.
- Rivière S, Galicier L, Coppo P, et al. Reactive hemophagocytic syndrome in adults: a retrospective analysis of 162 patients. *Am J Med*. 2014;127(11):1118-1125.
- Parikh SA, Kapoor P, Letendre L, Kumar S, Wolanskyj AP. Prognostic factors and outcomes of adults with hemophagocytic lymphohistiocytosis. *Mayo Clin Proc*. 2014;89(4):484-492.
- Takahashi N, Chubachi A, Kume M, et al. A clinical analysis of 52 adult patients with hemophagocytic syndrome: the prognostic significance of the underlying diseases. *Int J Hematol*. 2001;74(2):209-213.
- Li J, Wang Q, Zheng W, et al. Hemophagocytic lymphohistiocytosis: clinical analysis of 103 adult patients. *Medicine (Baltimore)*. 2014;93(2):100-105.
- Fardet L, Lambotte O, Meynard J-L, et al. Reactive haemophagocytic syndrome in 58 HIV-1-infected patients: clinical features, underlying diseases and prognosis. *AIDS*. 2010;24(9):1299-1306.
- Rouphael NG, Talati NJ, Vaughan C, Cunningham K, Moreira R, Gould C. Infections associated with haemophagocytic syndrome. *Lancet Infect Dis*. 2007;7(12):814-822.
- Dhote R, Simon J, Papo T, et al. Reactive hemophagocytic syndrome in adult systemic disease: report of twenty-six cases and literature review. *Arthritis Rheum*. 2003;49(5):633-639.
- Shabbir M, Lucas J, Lazarchick J, Shirai K. Secondary hemophagocytic syndrome in adults: a case series of 18 patients in a single institution and a review of literature. *Hematol Oncol*. 2011;29(2):100-106.
- Ramos-Casals M, Brito-Zerón P, López-Guillermo A, Khamashta MA, Bosch X. Adult haemophagocytic syndrome. *Lancet*. 2014;383(9927):1503-1516.
- Sawhney S, Woo P, Murray KJ. Macrophage activation syndrome: a potentially fatal complication of rheumatic disorders. *Arch Dis Child*. 2001;85(5):421-426.
- Lambotte O, Khellaf M, Harmouche H, et al. Characteristics and long-term outcome of 15 episodes of systemic lupus erythematosus-associated hemophagocytic syndrome. *Medicine (Baltimore)*. 2006;85(3):169-182.

35. Schulert GS, Grom AA. Macrophage activation syndrome and cytokine-directed therapies. *Best Pract Res Clin Rheumatol*. 2014;28(2):277-292.
36. Zhang K, Jordan MB, Marsh RA, et al. Hypomorphic mutations in PRF1, MUNC13-4, and STXBP2 are associated with adult-onset familial HLH. *Blood*. 2011;118(22):5794-5798.
37. Clementi R, Emmi L, Maccario R, et al. Adult onset and atypical presentation of hemophagocytic lymphohistiocytosis in siblings carrying PRF1 mutations. *Blood*. 2002;100(6):2266-2267.
38. Zhang K, Chandrakasan S, Chapman H, et al. Synergistic defects of different molecules in the cytotoxic pathway lead to clinical familial hemophagocytic lymphohistiocytosis. *Blood*. 2014;124(8):1331-1334.
39. Zhang K, Biroscak J, Glass DN, et al. Macrophage activation syndrome in patients with systemic juvenile idiopathic arthritis is associated with MUNC13-4 polymorphisms. *Arthritis Rheum*. 2008;50(9):2892-2896.
40. Zhang M, Behrens EM, Atkinson TP, Shakoory B, Grom AA, Cron RQ. Genetic defects in cytotoxicity in macrophage activation syndrome. *Curr Rheumatol Rep*. 2014;16(9):439.
41. Molleran Lee S, Villanueva J, Sumegi J, et al. Characterisation of diverse PRF1 mutations leading to decreased natural killer cell activity in North American families with haemophagocytic lymphohistiocytosis. *J Med Genet*. 2004;41(2):137-144.
42. Zur Stadt U, Beutel K, Weber B, Kabisch H, Schneppenheimer R, Janka G. A91V is a polymorphism in the perforin gene not causative of an FHLH phenotype. *Blood*. 2004;104(6):1909-1910.
43. Abecasis GR, Auton A, Brooks LD, et al; 1000 Genomes Project Consortium. An integrated map of genetic variation from 1,092 human genomes. *Nature*. 2012;491(7422):56-65.
44. Exome Variant Server. NHLBI GO Exome Sequencing Project (ESP). Seattle, WA. <http://evs.gs.washington.edu/EVS/>. Accessed September 2014.
45. Voskoboinik I, Thia M-C, Trapani JA. A functional analysis of the putative polymorphisms A91V and N252S and 22 missense perforin mutations associated with familial hemophagocytic lymphohistiocytosis. *Blood*. 2005;105(12):4700-4706.
46. Voskoboinik I, Sutton VR, Ciccone A, et al. Perforin activity and immune homeostasis: the common A91V polymorphism in perforin results in both presynaptic and postsynaptic defects in function. *Blood*. 2007;110(4):1184-1190.
47. Martínez-Pomar N, Lanio N, Romo N, Lopez-Botet M, Matamoros N. Functional impact of A91V mutation of the PRF1 perforin gene. *Hum Immunol*. 2013;74(1):14-17.
48. Trambas C, Gallo F, Pende D, et al. A single amino acid change, A91V, leads to conformational changes that can impair processing to the active form of perforin. *Blood*. 2005;106(3):932-937.
49. Voskoboinik I, Trapani JA. Perforinopathy: a spectrum of human immune disease caused by defective perforin delivery or function. *Front Immunol*. 2013;4:441.
50. Henter J-I, Horne A, Aricò M, et al. HLH-2004: diagnostic and therapeutic guidelines for hemophagocytic lymphohistiocytosis. *Pediatr Blood Cancer*. 2007;48(2):124-131.
51. Jordan MB, Allen CE, Weitzman S, Filipovich AH, McClain KL. How I treat hemophagocytic lymphohistiocytosis. *Blood*. 2011;118(15):4041-4052.
52. Tsuji T, Hirano T, Yamasaki H, Tsuji M, Tsuda H. A high sIL-2R/ferritin ratio is a useful marker for the diagnosis of lymphoma-associated hemophagocytic syndrome. *Ann Hematol*. 2014;93(5):821-826.
53. Schaefer DJ, Schleiffenbaum B, Kurrer M, et al. Soluble hemoglobin-haptoglobin scavenger receptor CD163 as a lineage-specific marker in the reactive hemophagocytic syndrome. *Eur J Haematol*. 2005;74(1):6-10.
54. Møller HJ. Soluble CD163. *Scand J Clin Lab Invest*. 2012;72(1):1-13.
55. Allen CE, Yu X, Kozinetz CA, McClain KL. Highly elevated ferritin levels and the diagnosis of hemophagocytic lymphohistiocytosis. *Pediatr Blood Cancer*. 2008;50(6):1227-1235.
56. Schram AM, Campigotto F, Mullally A, et al. Marked hyperferritinemia does not predict for HLH in the adult population. *Blood*. 2015;125(10):1548-1552.
57. Gupta A, Tyrrell P, Valani R, Benseler S, Weitzman S, Abdelhaleem M. The role of the initial bone marrow aspirate in the diagnosis of hemophagocytic lymphohistiocytosis. *Pediatr Blood Cancer*. 2008;51(3):402-404.
58. François B, Trimoreau F, Vignon P, Fixe P, Praloran V, Gastinne H. Thrombocytopenia in the sepsis syndrome: role of hemophagocytosis and macrophage colony-stimulating factor. *Am J Med*. 1997;103(2):114-120.
59. Strauss R, Neureiter D, Westenburger B, Wehler M, Kirchner T, Hahn EG. Multifactorial risk analysis of bone marrow histiocytic hyperplasia with hemophagocytosis in critically ill medical patients—a postmortem clinicopathologic analysis. *Crit Care Med*. 2004;32(6):1316-1321.
60. Fardet L, Galicier L, Lambotte O, et al. Development and validation of the HScore, a score for the diagnosis of reactive hemophagocytic syndrome. *Arthritis Rheum (Munch)*. 2014;66(9):2613-2620.
61. Hejblum G, Lambotte O, Galicier L, et al. A web-based delphi study for eliciting helpful criteria in the positive diagnosis of hemophagocytic syndrome in adult patients. *PLoS ONE*. 2014;9(4):e94024.
62. Ambruso DR, Hays T, Zwartjes WJ, Tubergen DG, Favara BE. Successful treatment of lymphohistiocytic reticulosis with phagocytosis with epipodophyllotoxin VP 16-213. *Cancer*. 1980;45(10):2516-2520.
63. Trottestam H, Horne A, Aricò M, et al; Histiocyte Society. Chemoimmunotherapy for hemophagocytic lymphohistiocytosis: long-term results of the HLH-94 treatment protocol. *Blood*. 2011;118(17):4577-4584.
64. Imashuku S, Kuriyama K, Sakai R, et al. Treatment of Epstein-Barr virus-associated hemophagocytic lymphohistiocytosis (EBV-HLH) in young adults: a report from the HLH study center. *Med Pediatr Oncol*. 2003;41(2):103-109.
65. Hande KR. Etoposide: four decades of development of a topoisomerase II inhibitor. *Eur J Cancer*. 1998;34(10):1514-1521.
66. Johnson TS, Terrell CE, Millen SH, Katz JD, Hildeman DA, Jordan MB. Etoposide selectively ablates activated T cells to control the immunoregulatory disorder hemophagocytic lymphohistiocytosis. *J Immunol*. 2014;192(1):84-91.
67. Tothova Z, Berliner N. Hemophagocytic syndrome and critical illness: new insights into diagnosis and management [published online ahead of print January 8, 2014]. *J Intensive Care Med*. doi: 10.1177/0885066613517076.
68. Janka GE. Familial hemophagocytic lymphohistiocytosis. *Eur J Pediatr*. 1983;140(3):221-230.
69. Fischer A, Cerf-Bensussan N, Blanche S, et al. Allogeneic bone marrow transplantation for erythrophagocytic lymphohistiocytosis. *J Pediatr*. 1986;108(2):267-270.
70. Strout MP, Seropian S, Berliner N. Alemtuzumab as a bridge to allogeneic SCT in atypical hemophagocytic lymphohistiocytosis. *Nat Rev Clin Oncol*. 2010;7(7):415-420.
71. Marsh RA, Allen CE, McClain KL, et al. Salvage therapy of refractory hemophagocytic lymphohistiocytosis with alemtuzumab. *Pediatr Blood Cancer*. 2013;60(1):101-109.
72. Marsh RA, Vaughn G, Kim M-O, et al. Reduced-intensity conditioning significantly improves survival of patients with hemophagocytic lymphohistiocytosis undergoing allogeneic hematopoietic cell transplantation. *Blood*. 2010;116(26):5824-5831.
73. Cooper N, Rao K, Gilmour K, et al. Stem cell transplantation with reduced-intensity conditioning for hemophagocytic lymphohistiocytosis. *Blood*. 2006;107(3):1233-1236.
74. Arca M, Fardet L, Galicier L, et al. Prognostic factors of early death in a cohort of 162 adult haemophagocytic syndrome: impact of triggering disease and early treatment with etoposide. *Br J Haematol*. 2015;168(1):63-68.
75. Park H-S, Kim D-Y, Lee J-H, et al. Clinical features of adult patients with secondary hemophagocytic lymphohistiocytosis from causes other than lymphoma: an analysis of treatment outcome and prognostic factors. *Ann Hematol*. 2012;91(6):897-904.
76. Shirono K, Tsuda H. Virus-associated haemophagocytic syndrome in previously healthy adults. *Eur J Haematol*. 1995;55(4):240-244.