

## THE SUBENDOTHELIAL SPACE IN CERTAIN ENDOCRINE TISSUES

By J. D. LEVER, M.D.

(From the Department of Anatomy, University of Cambridge, Cambridge, England)

PLATE 93

A subendothelial space between the parenchymal cell plasma membrane and the plasma membrane of the endothelial lining of the regional blood sinusoids has been reported in both adrenal cortex and medulla and in the corpus luteum (1, 2, 3). To date, such a space or interval has been seen to best advantage in the parathyroid (Fig. 1). As described in other endocrine tissues (*vide supra*) the subendothelial interval communicates with intercellular spaces between adjacent parenchymal cells. With regard only to the membranous boundaries of both subendothelial and intercellular intervals (and not to the outlines of any contained material), it can be said that these freely communicate in the rat parathyroid (Fig. 1). For the most part in this tissue adjacent endothelial and parenchymal plasma membranes follow gentle curves and the interval between them is correspondingly regular (Fig. 1). In contrast the interparenchymal cell spaces are tortuous and vary greatly in width along their extent. It follows that in some of their course adjacent parenchymal plasma membranes are convoluted and interdigitating (Fig. 2).

The use of the term "subendothelial *space*" probably dates back to Disse's (4) description of the interval between the Kupffer-endothelial lining of the sinusoids and the parenchymal cells of the liver. In the same connection it was more recently used by Fawcett (5).

Collagen has been noted in small amount in the subendothelial space of the anterior pituitary (6); the thyroid (7); the adrenal medulla (2); the adrenal cortex (1), particularly in the zona reticularis and in increased amount following hypophysectomy (8).

The fact that endocrine secretory material must cross the subendothelial space in order to gain the blood stream might have a bearing on the interpretation of relevant electron micrographs. In Fig. 1 there is a grey amorphous material applied to, but distinct from, the plasma membrane of both parenchymal and endothelial cells of the rat parathyroid. The same appearance, described by Farquhar and Rinehart in the anterior pituitary (6), is also found in the thyroid (Fig. 4), in which gland Dempsey and Peterson (7) interpreted the amorphous lining material as basement membrane. Again it is observed in both adrenal cortex and medulla, though in the former it is presented as a single concentra-

tion of material, often interrupted and indefinite, in the middle of the subendothelial space. Whether or not all of this subendothelial amorphous material is in fact basement membrane in any or all of these endocrine tissues is at present unresolved. Recently Green and van Breemen (9) have reported the presence of secretory granules in the subendothelial and intercellular spaces of the anterior pituitary. Furthermore, when in hyperactive states of the adrenal medulla (2) and adrenal cortex (1) the subendothelial and interparenchymal spaces are filled with semiopaque material, it is tempting to regard the presence of this material (Fig. 3) as indicative of a secretory transfer from the parenchymal cells.

## REFERENCES

1. Lever, J. D., *Am. J. Anat.*, 1955, **97**, 409.
2. Lever, J. D., *Endocrinology*, 1955, **57**, 621.
3. Lever, J. D., *Anat. Rec.*, 1956, **124**, 111.
4. Disse, J., *Arch. mikr. Anat.*, 1890, **36**, 203.
5. Fawcett, D. W., *J. Appl. Phys.*, 1953, **24**, 1424.
6. Farquhar, M. G., and Rinehart, J. F., *J. Appl. Phys.*, 1954, **25**, 1466.
7. Dempsey, E. W., and Peterson, R. R., *Endocrinology*, 1955, **56**, 46.
8. Lever, J. D., *Endocrinology*, 1956, **58**, 163.
9. Green, J. D., and van Breemen, V. L., *Am. J. Anat.*, 1955, **97**, 177.

PLATE

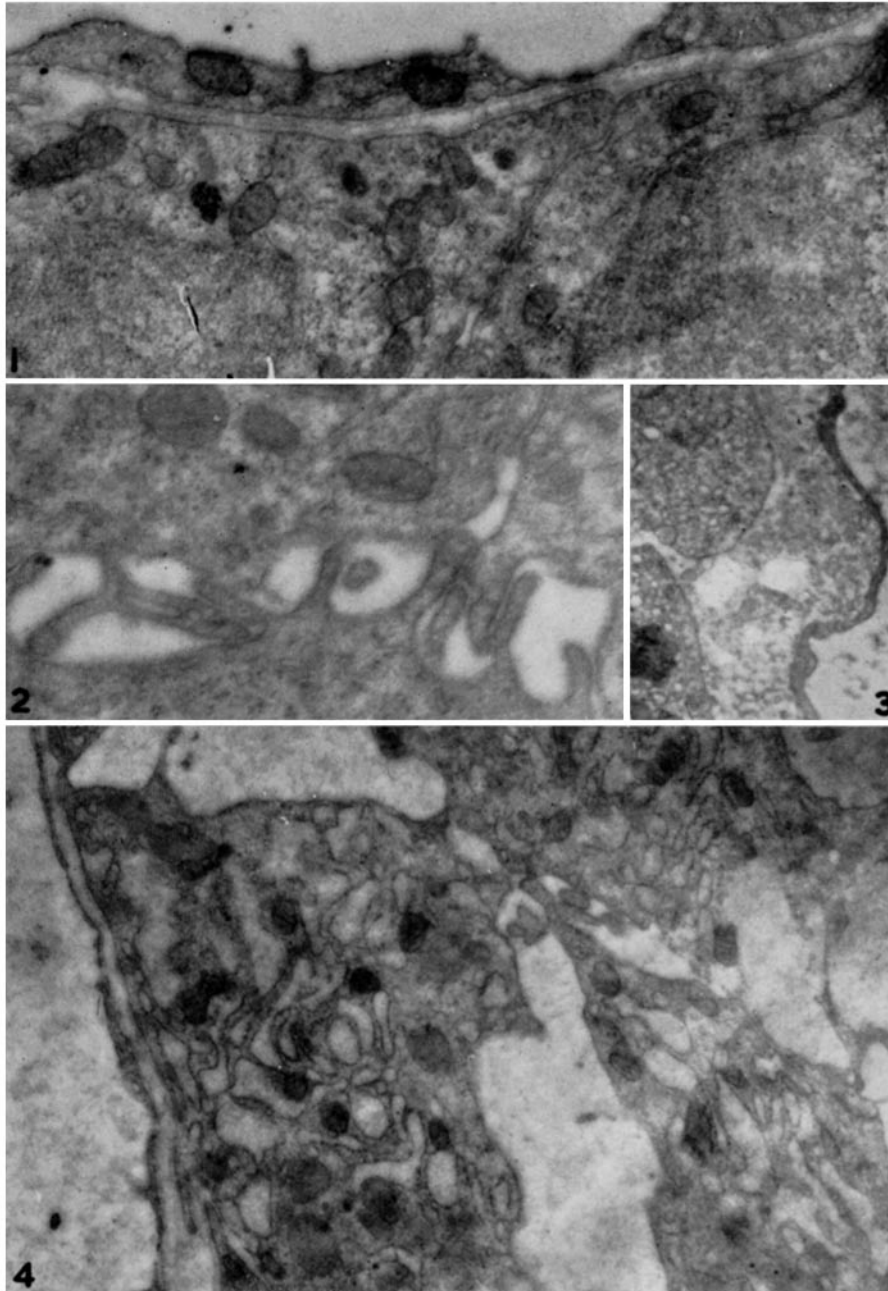
## EXPLANATION OF PLATE 93

FIG. 1. Rat parathyroid. Above is a capillary lumen with endothelial lining. The subendothelial space is bounded by adjacent plasma membranes of parenchymal and endothelial cells. Applied to, but distinct from, both these plasma membranes is a layer of semiopaque amorphous material. To right of center an intercellular interval is continuous with the subendothelial space.  $\times 27,000$ .

FIG. 2. Rat parathyroid. The interdigitating plasma membranes of adjacent parenchymal cells enclose a highly irregular intercellular space.  $\times 31,500$ .

FIG. 3. From the zona reticularis of an acutely stressed human adrenal. From right to left a capillary lumen; its endothelial lining, the subendothelial space containing semiopaque material and saccular bodies; the outlines of two parenchymal cells.  $\times 12,000$ .

FIG. 4. Rat thyroid. From left to right, a capillary lumen and its endothelial lining; the subendothelial space similar to that in Fig. 1; parenchymal cells containing granular-walled spaces, and other organelles. The large intervals between neighbouring parenchymal spaces are somewhat accentuated intercellular spaces containing a semiopaque formless material.  $\times 19,000$ .



(Lever: Subendothelial space in endocrine tissues)