

Temozolomide as Monotherapy Is Effective in Treatment of Advanced Malignant Neuroendocrine Tumors

Sara Ekeblad,¹ Anders Sundin,² Eva Tiensuu Janson,¹ Staffan Welin,¹ Dan Granberg,¹ Henrik Kindmark,¹ Kristina Dunder,¹ Gordana Kozlovacki,¹ Håkan Örlfors,¹ Mattias Sigurd,¹ Kjell Öberg,¹ Barbro Eriksson,¹ and Britt Skogseid¹

Abstract Purpose: A retrospective analysis of the toxicity and efficacy of temozolomide in advanced neuroendocrine tumors.

Experimental Design: Thirty-six patients with advanced stages of neuroendocrine tumor (1 gastric, 7 thymic and 13 bronchial carcinoids, 12 pancreatic endocrine tumors, 1 paraganglioma, 1 neuroendocrine foregut, and 1 neuroendocrine cecal cancer) were treated with temozolomide (200 mg/m²) for 5 days every 4 weeks. Patients had previously received a mean of 2.4 anti-tumoral medical regimens. Tumor response was evaluated radiologically according to the Response Evaluation Criteria in Solid Tumors every 3 months on an intent-to-treat basis. The circulating tumor marker plasma chromogranin A was also assessed. The expression of O⁶-methylguanine DNA methyltransferase, an enzyme implicated in chemotherapy resistance, was studied by immunohistochemistry (*n* = 23) and compared with response to temozolomide.

Results: Median overall time to progression was 7 months (95% confidence interval, 3-10). Radiologic response was seen in 14% of patients and stable disease in 53%. Side effects were mainly hematologic; 14% experienced grade 3 or 4 thrombocytopenia (National Cancer Institute toxicity criteria). Ten patients had tumors with O⁶-methylguanine DNA methyltransferase immunoreactivity in <10% of nuclei, whereas four patients showed radiologic responses.

Conclusions: Temozolomide as monotherapy had acceptable toxicity and antitumoral effects in a small series of patients with advanced malignant neuroendocrine tumors and four of these showed radiologic responses.

There are currently no effective systemic antitumoral treatments for patients with bronchial or thymic carcinoids (1, 2), and limited, mostly uncontrolled data on pancreatic endocrine tumor management. Significant toxicity is seen in long-term treatment, and on extended follow-up, essentially all patients with advanced neuroendocrine tumor disease will have succumbed to their disease. Thus, finding new antitumoral regimens is of great importance for patients with these rare tumors.

Temozolomide is an alkylating agent with activity in metastatic melanoma (1) and glioma (2). It shares its active metabolite with dacarbazine (3), which is used in neuroendocrine tumors (4, 5). Unlike dacarbazine, temozolomide penetrates the blood-brain barrier, making it possible to treat brain metastases. Furthermore, temozolomide can be taken

orally, and is better tolerated and thus possibly associated with a higher quality of life (3, 6).

A few studies of temozolomide in combination with other antitumoral agents have been presented. An overall radiologic response rate of 25%, with a median duration of 13.5 months, was recently reported in a phase II study of the combination of temozolomide and thalidomide in the treatment of metastatic neuroendocrine tumors (7). In a retrospective study of a combination of temozolomide and capecitabine in neuroendocrine tumors of the pancreas, presented as an abstract at the 2006 American Society of Clinical Oncology meeting, 6% of patients had a complete response and 53% had a partial response, with a median duration of 9.5 months (8). Presented at the same meeting, a phase II study of temozolomide, together with bevacizumab, showed an overall response rate of 14% (9). However, there are no published data on the effect of temozolomide as monotherapy in neuroendocrine tumors.

O⁶-methylguanine DNA methyltransferase (MGMT) is a DNA repair enzyme believed to induce cancer cell resistance to O⁶-alkylating agents, e.g., temozolomide. Inactivation of the MGMT gene by promoter methylation is associated with longer survival in patients with glioblastoma treated with temozolomide (10, 11). Low MGMT expression, detected by immunohistochemistry, correlates with response to temozolomide treatment in low-grade oligodendroglioma, and MGMT immunostaining has been suggested as a marker for predicting tumor chemosensitivity (2). MGMT promoter hypermethylation has been

Authors' Affiliations: Departments of ¹Medical Sciences and ²Radiology, Uppsala University, Uppsala, Sweden

Received 8/16/06; revised 3/13/07; accepted 3/21/07.

Grant support: Swedish Cancer Society, Swedish Research Council, and the Lion's Fund for Cancer Research (B. Skogseid).

The costs of publication of this article were defrayed in part by the payment of page charges. This article must therefore be hereby marked *advertisement* in accordance with 18 U.S.C. Section 1734 solely to indicate this fact.

Requests for reprints: Britt Skogseid, Department of Medical Sciences, University Hospital, 75185 Uppsala, Sweden. Phone: 46-1861-10000; Fax: 46-1855-3601; E-mail: Britt.Skogseid@medsci.uu.se.

©2007 American Association for Cancer Research.
doi:10.1158/1078-0432.CCR-06-2053

described in small groups of neuroendocrine tumors [pancreatic endocrine tumor (EPT) and carcinoid; refs. 12, 13]. There are no published data on MGMT protein expression in neuroendocrine tumors.

We report our experience regarding toxicity and therapeutic effects in 36 patients with advanced malignant neuroendocrine tumors, treated with temozolomide at our clinic. We also semiquantitatively investigated tumor MGMT status with immunohistochemistry to assess a possible association with response to treatment.

Patients and Methods

Patients. We retrospectively evaluated all patients ($n = 36$) with histologically confirmed metastatic or inoperable malignant neuroendocrine tumors treated with temozolomide at our clinic between October 1999 and January 2006. Temozolomide was, in most cases, given when all other treatment options had failed. Patient characteristics are summarized in Table 1.

Treatment and evaluation. Temozolomide was administered orally for 5 consecutive days every 28 days. In the first cycle, patients received an induction dose of 100 or 150 mg/m²/d. In subsequent cycles, the dose was escalated to 200 mg/m²/d in 20 patients, but remained at lower doses in 16 patients, the majority due to bone marrow suppression from previous chemotherapy. In two cases, the dose was elevated to 200 mg/m²/d after 9 and 10 months, respectively. Hemoglobin, leukocytes, and thrombocytes were measured on day 21 of each cycle. Cycles were repeated on an outpatient basis in the absence of disease progression and unacceptable toxicity. Temozolo-

Table 1. Patient and tumor characteristics

Age	Median, 60 ± 10 y (range, 35-80)
Time from diagnosis	Median, 3.5 ± 5.8 y (range, 0-29)
Sex	
Male	22 (61)
Female	14 (39)
Tumors	
Thymic carcinoid	7 (19)
Bronchial carcinoid	13 (36)
Typical	10 (28)
Atypical	3 (8)
Gastric carcinoid	1 (3)
Pancreatic endocrine tumor	12 (33)
Neuroendocrine foregut tumor	1 (3)
Paraganglioma	1 (3)
Neuroendocrine cecal cancer	1 (3)
Total	36 (100)
No. of prior systemic antitumoral treatments	
0	2 (6)
1	7 (19)
2	10 (28)
3	12 (33)
4	4 (11)
6	1 (3)
Surgery of primary tumor	15 (42)
Staging	
Inoperable primary and/or metastases in only one location	18 (50)
Metastases in more than one location	18 (50)
Brain metastases	6 (17)

NOTE: Values in table expressed as n (%) values otherwise noted.

Table 2. Toxicity

Toxicity	Maximum toxicity grade			
	1	2	3	4
Anemia	9 (26%)	1 (3%)	1 (3%)	0 (0%)
Thrombocytopenia	8 (23%)	0 (0%)	5 (14%)	0 (0%)
Leukopenia	3 (9%)	1 (3%)	1 (3%)	0 (0%)
Neutropenia	0 (0%)	1 (3%)	0 (0%)	1 (3%)
Fatigue	8 (23%)	3 (9%)	2 (6%)	1 (3%)
Nausea	10 (29%)	0 (0%)	0 (0%)	0 (0%)

NOTE: Grading according to National Cancer Institute criteria. Number of patients, percentages within parentheses.

mid administration was postponed for 1 week if hematologic recovery after the previous cycle had not occurred. Toxicity grading was based on National Cancer Institute Common Toxicity Criteria. Patients routinely received tropisetron as an antiemetic.

Response was evaluated after every third cycle with computed tomography examination or magnetic resonance imaging, using clinical standard imaging protocols. Radiological tumor response was classified according to the Response Evaluation Criteria in Solid Tumors (14). Two patients were followed by ultrasonography. Complete response was defined as the disappearance of all lesions, and partial response as a decrease of 30% or more in the sum of the longest diameters. Progressive disease was defined as either the appearance of new lesions or an increase of 20% or more compared with the minimum sum of longest diameters recorded since the start of treatment. A sum increasing by <20% or decreasing by <30% and without the appearance of new lesions was considered stable disease. Any response was confirmed by a repeat measurement no less than 4 weeks after the criteria for response was first met. Time to progression was defined as the time between first administration of temozolomide and documentation of progressive disease.

Biochemical response was evaluated by analysis of the general neuroendocrine tumor marker chromogranin A (CgA) in plasma (≤ 4 nmol/mL; ref. 15). Mean CgA at baseline was 132 nmol/mL (median, 23; range, 3-1860). Response was defined as a decrease in CgA by $\geq 50\%$ from baseline (assessed in patients with an elevated baseline CgA). Biochemical progression was defined as an increase in CgA by $\geq 25\%$ from the baseline. An increase by <25% or decrease by <50% comprised biochemically stable disease.

Immunohistochemistry. MGMT protein expression was investigated in 23 tumor specimens (eight EPT, nine bronchial carcinoids, four thymic carcinoids, one paraganglioma, and one neuroendocrine foregut tumor). Paraffin-embedded sections of 4 μ m were used for

Table 3. Adverse events

Adverse events	No. of observations
Stomach ache, grade 1-2	6
Headache, grade 1	3
Lumbago, pulmonary embolism, seizures, respiratory tract infection	2
Others*	1

NOTE: Adverse events are based on descriptions in medical records. Grading according to National Cancer Institute criteria.

*Arthralgia, pleural effusion, grade 1 weight loss, grade 1 diarrhea, ascites, *Mycoplasma pneumoniae*, hypocalcemia, grade 2 depression, grade 3 gastrointestinal bleeding (tumor growth into the gastrointestinal tract, no thrombocytopenia), and hormonal crisis.

Table 4. Radiologic response

	All patients (N = 36)	EPT (n = 12)	Bronchial carcinoids (n = 13)	Thymic carcinoids (n = 7)	Other (n = 4)
Complete response	0 (0%)	0 (0%)	0 (0%)	0 (0%)	0 (0%)
Partial response	5 (14%)	1 (8%)	4 (31%)	0 (0%)	0 (0%)
Stable disease	19 (53%)	8 (67%)	4 (31%)	5 (71%)	2 (50%)
Progressive disease	12 (33%)	3 (25%)	5 (38%)	2 (29%)	2 (50%)

immunohistochemistry. For antigen retrieval, sections were subjected to pretreatment with 45-min pressure boiling in citrate buffer (pH 6.0). Immunohistochemistry was done using an autostainer (Dako Cytomation). Sections were incubated with a mouse monoclonal MGMT antibody (MAB16200; Chemicon, 1:500), diluted in Antibody Diluent (Dako Cytomation), at room temperature for 60 min. The reaction product was revealed using Dako kit 50087 (Dako Cytomation). Sections were counterstained with Mayer's hematoxylin. Initial experiments were done with omission of the primary antibody. All sections were scored by two individuals blinded for outcome, according to the fraction of nuclear staining, as high ($\geq 50\%$), intermediate (10-49%), or low ($< 10\%$).

Statistics. Analyses were done with the statistical package SPSS, version 14.0 (SPSS, Inc.). Overall survival and time to progression estimates were calculated with Kaplan-Meier methodology. Any treatment comparisons are presented on an intent-to-treat basis. The log-rank test (three-group comparison) was used to test the null hypothesis that time to progression was equal in patients with bronchial carcinoid, thymic carcinoid, or pancreatic endocrine tumor. The χ^2 test was used to test differences in response rates between tumors with a high or low expression of MGMT. $P < 0.05$ was considered significant.

Ethical approval. This study was approved by the local ethics committee. Informed consent regarding usage of tumor material for research purposes had been obtained from all patients at the time of initial treatment at our clinic.

Results

Toxicity. Medical records were available for evaluation of toxicity in 35 patients. Patients received a median of 4.5 cycles (range, 0-17). Median follow-up was 9 months (range, 0.2-25). Toxicities and adverse events are summarized in Tables 2 and 3. There were no fatal side effects; toxicities were mainly hematologic. Dose reduction due to hematologic toxicity was

necessary in four patients. Three patients required blood transfusions, and one patient required platelet transfusion. No patient had febrile neutropenia, opportunistic infections, or bleeding due to low platelets. Fatigue and nausea were mild in a majority of patients. Twenty-three patients (66%) reported no nausea, and the rest had grade 1 nausea. Twenty patients (57%) reported no fatigue and only two patients had grades 3 to 4 fatigue. One patient with a vasoactive intestinal peptide-producing pancreatic tumor experienced severe diarrhea and dehydration requiring treatment in an intensive care unit, due to excessive secretion of vasoactive intestinal peptide from the tumor after only one tablet of temozolomide. Therefore, temozolomide treatment was terminated.

Efficacy. All 36 patients were assessed for radiologic response, in an intent-to-treat analysis (Table 4). Three patients died before the first radiologic evaluation and one did not complete the first cycle of treatment. No patient had a complete response. Five patients (14%) showed partial responses (one atypical, three typical bronchial carcinoids, and one EPT; Fig. 1). These patients had received one ($n = 1$), two ($n = 1$), or three ($n = 3$) previous lines of systemic anti-tumoral treatment, respectively. Nineteen patients (53%) had stable disease. Of these 19, 13 were still stable at the end of the clinical follow-up reviewed in this study. Twelve patients (33%) had progressive disease as their best response to therapy. Median time to progression in the patient group as a whole was 7 months (95% confidence interval, 3-10; Fig. 2). There was no significant difference in the time to progression between patients with bronchial carcinoid, thymic carcinoid, and EPT. Median follow-up for patients who had not had progressive disease was 7 months (range, 2-17). Only one of the five patients with radiologic response progressed during

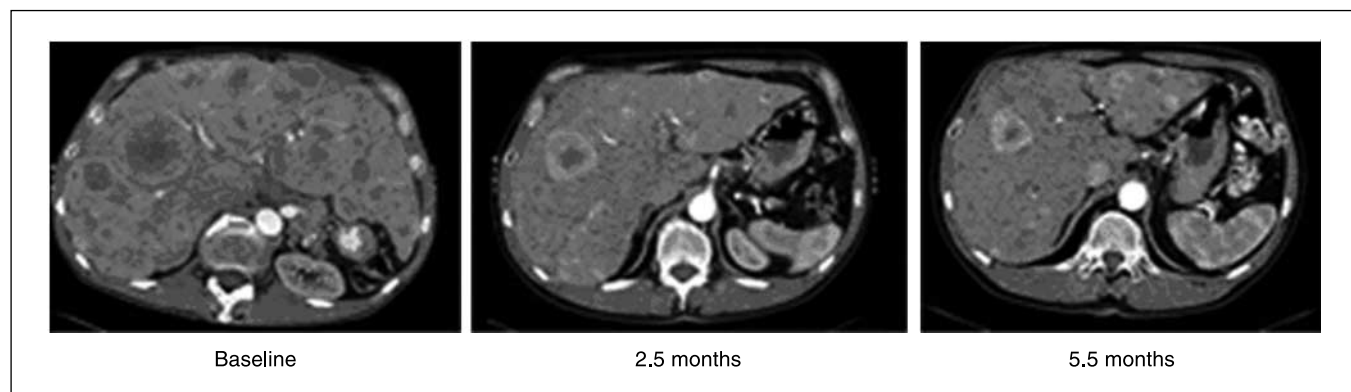


Fig. 1. Computed tomography images of a male patient (born 1950) with EPT: 2.5 mo after start of temozolomide treatment, there was a 59% tumor reduction (Response Evaluation Criteria in Solid Tumors criteria), and at 5.5 mo (2.5 mo after the end of follow-up for this study) there was an 89% reduction compared with baseline.

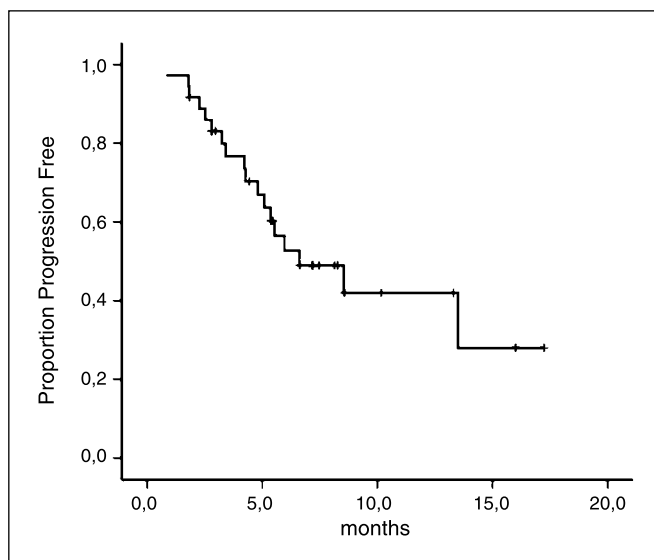


Fig. 2. Overall time to progression. Vertical lines, censored observations.

follow-up, after 8.5 months. The remaining four responders did not have tumor progression during follow-up, and were still stable after a median of 7.3 months (range, 2.5-13.0).

Results from repeated measurements of plasma CgA were available in 27 patients with elevated baseline CgA. Five (19%) showed a decrease of CgA of >50%, 10 (37%) had stable levels, and 12 (44%) showed biochemical progression as their best response to treatment. Of the five patients with radiologic response, two also had biochemical responses (68% and 95% reduction of plasma levels, respectively), one had biochemically stable disease as the best biochemical response, and two did not have elevated CgA at baseline.

At the end of clinical follow-up for this study, 13 of 36 patients had died from their disease. Median overall survival from start of temozolomide treatment, using Kaplan-Meier estimates, was 16 months (95% confidence interval, 11-22). Considering the limited follow-up of the 23 patients who were still alive at the end of clinical follow-up for this study (median, 8.6 months; 2.8-17.2), this Kaplan-Meier estimate might be uncertain.

MGMT expression. Nine out of 23 analyzed tumors had a high percentage of MGMT-immunoreactive nuclei (Fig. 3A). Of these, one patient showed a radiologic response, five had stable disease as their best response, and three had progressive disease at first evaluation. Four of 23 tumors had medium MGMT immunoreactivity. The patients harboring these tumors had stable disease as best response. The tumors of 10 patients expressed a low percentage of MGMT-immunoreactive nuclei (Fig. 3B). Four of these patients had radiologic responses, five showed stable disease and one showed progressive disease as best response. There was no significant difference in the response rate between tumors with a low of percentage of MGMT-immunoreactive tumor cell nuclei and tumors with a medium or high MGMT expression.

Discussion

Temozolomide as monotherapy has antitumoral activity in neuroendocrine tumors, with acceptable toxicity. In this intent-to-treat analysis, treatment with temozolomide rendered an

overall objective radiologic response rate of 14%, and a biochemical response rate of 19%. Bearing in mind the limitations of a retrospective design, these results are still promising, considering that patients had received a mean of 2.4 previous palliative antitumoral medical regimens.

Patients with bronchial and thymic carcinoids had clinical benefit (response or stabilization) in 62% and 71% of cases, respectively. Temozolomide could have an important role in the management of these tumors, in which there have previously been few effective medical treatment strategies (16, 17).

In general, treatment with temozolomide was well tolerated. Mainly, mild hematologic toxicity was seen. Fatigue and nausea were acceptable in a majority of patients. It is our experience that for a large majority of patients, treatment with temozolomide led to an improved well-being. This was attributed to a combination of tumor regression, fewer side effects compared with their individual experiences of previous chemotherapy, and not being subjected to repeated hospitalization.

Although the present study suggests temozolomide to be safe and well tolerated, others have shown a high frequency of opportunistic infections (18). In addition, we have recently experienced severely impaired hearing in two patients treated with temozolomide after the end of the defined observation period of this study.

In three recently published reports, combinations of temozolomide and thalidomide or bevacizumab or capecitabine rendered response rates of 14% to 59% (7-9). Due to differences in the chosen temozolomide schedules and variable patient materials, the actual effect of the addition of a second compound is not readily assessed in comparison with our study. In both studies, Kulke et al. used a more dose-intense temozolomide schedule (150 mg/m² 7 days every other week), whereas we used the standard schedule of 200 mg/m² 5 days every 4 weeks. In the temozolomide plus thalidomide study, patients had received a mean of 0.8 previous chemotherapy regimens, whereas in our study, the corresponding figure was 2.4. It is encouraging that so many of our patients, who in most cases received temozolomide when all other treatment options had failed, responded to treatment. In the temozolomide plus thalidomide study, only one carcinoid patient (7%) had a response, whereas we found patients with bronchial carcinoid to be frequent responders, with 31% showing an objective response. These differences could be due to different patient material; the previous study does not give information on what types of carcinoids were included.

Studies have indicated that tumors with a low expression of MGMT, measured either with methylation-specific PCR or with immunohistochemistry, respond better to temozolomide than tumors with abundant expression (2, 10, 11). Although methylation-specific PCR for MGMT has been more extensively evaluated, immunohistochemistry is more relevant for use in a clinical setting due to the availability of formalin-fixed tissue. We therefore chose the latter method. We found a low percentage of MGMT-positive tumor cell nuclei in 43% of tumors. Four out of five patients with a radiologic response had tumors with low MGMT expressions. A possible predictive value of MGMT immunohistochemistry in neuroendocrine tumors needs to be further investigated in a more comprehensive study design.

With limited toxicity, and the possibility for patients to receive treatment on an outpatient basis, temozolomide is an attractive option for palliative treatment in patients with

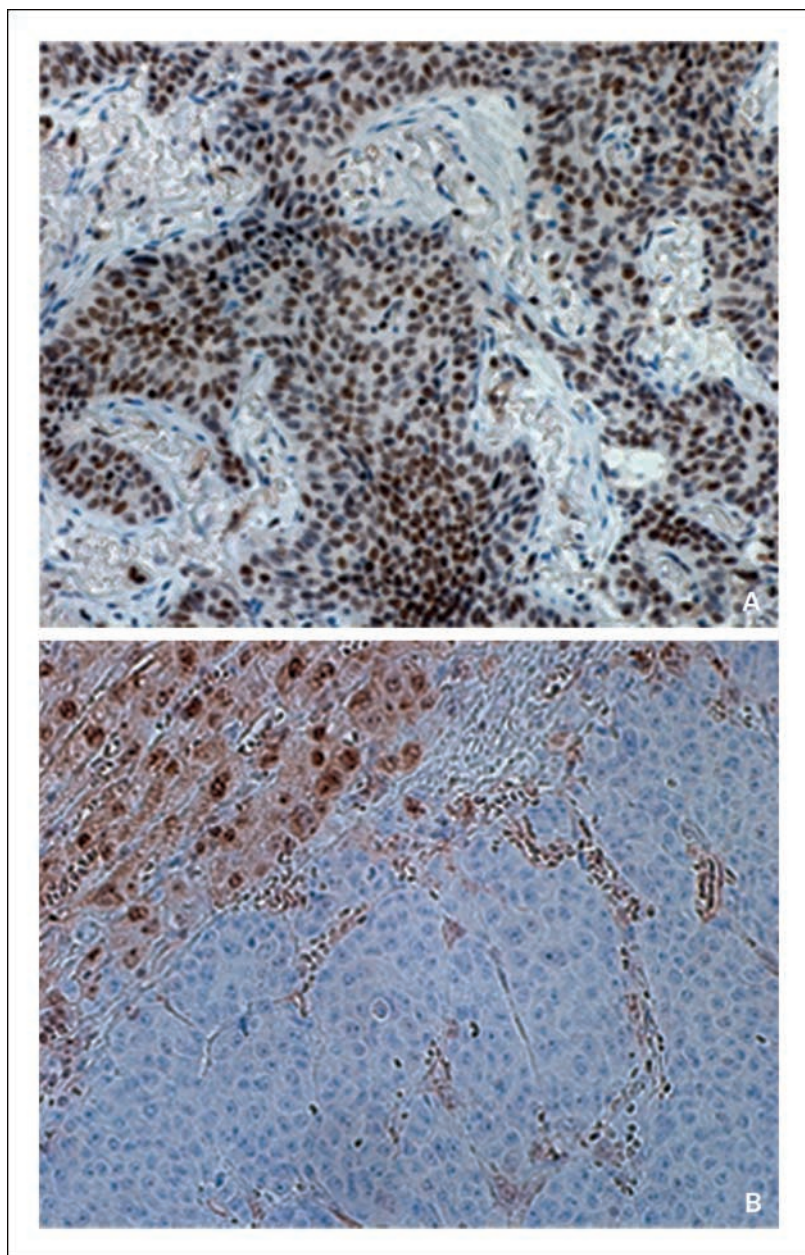


Fig. 3. Light microscopy of (A) bronchial carcinoid showing a high frequency of nuclear MGMT staining (magnification, $\times 50$) and (B) bronchial carcinoid with low frequency of nuclear MGMT staining (top left, normal liver tissue revealing strong MGMT reactivity; magnification, $\times 100$).

neuroendocrine tumors. It is a promising new agent for the treatment of bronchial and thymic carcinoids, for which few effective medical treatments, if any, have previously been available. Temozolomide is also an option for patients with EPT who progress on standard treatment.

References

- Middleton MR, Grob JJ, Aaronson N, et al. Randomized phase III study of temozolomide versus dacarbazine in the treatment of patients with advanced metastatic malignant melanoma. *J Clin Oncol* 2000;18:158–66.
- Levin N, Lavon I, Zelikovitch B, et al. Progressive low-grade oligodendrogliomas: response to temozolomide and correlation between genetic profile and O6-methylguanine DNA methyltransferase protein expression. *Cancer* 2006;106:175–65.
- Payne MJ, Pratap SE, Middleton MR. Temozolomide in the treatment of solid tumours: current results and rationale for dosing/scheduling. *Crit Rev Oncol Hematol* 2005;53:241–52.
- Bajetta E, Rimassa L, Carnaghi C, et al. 5-Fluorouracil, dacarbazine, and epirubicin in the treatment of patients with neuroendocrine tumors. *Cancer* 1998; 83:372–8.
- Bajetta E, Ferrari L, Procopio G, et al. Efficacy of a chemotherapy combination for the treatment of metastatic neuroendocrine tumours. *Ann Oncol* 2002;13:614–21.
- Yung WK, Albright RE, Olson J, et al. A phase II study of temozolomide vs. procarbazine in patients with glioblastoma multiforme at first relapse. *Br J Cancer* 2000;83:588–93.
- Kulke MH, Stuart K, Enzinger PC, et al. Phase II study of temozolomide and thalidomide in patients with metastatic neuroendocrine tumors. *J Clin Oncol* 2006;24:401–6.
- Isaccoff WH, Moss RA, Pecora AL, Fine RL. Temozolomide/capecitabine therapy for metastatic neuroendocrine tumors of the pancreas. A retrospective review. *J Clin Oncol*, 2006 ASCO Annual Meeting Proceedings, part I vol. 24, No. 18S (June 20 Supplement).

Acknowledgments

The authors thank Monica Hurtig and Margareta H. Lejonklou for excellent technical support and discussion. Anonymous reviewers provided comments that greatly improved this manuscript.

9. Kulke MHSK, Earle CC. A phase II study of temozolomide and bevacizumab in patients with advanced neuroendocrine tumors. *J Clin Oncol*, 2006 ASCO Annual Meeting Proceedings, part 1, vol. 24, No. 18S (June 20 Supplement).
10. Hegi ME, Diserens AC, Godard S, et al. Clinical trial substantiates the predictive value of O-6-methylguanine-DNA methyltransferase promoter methylation in glioblastoma patients treated with temozolomide. *Clin Cancer Res* 2004;10:1871–4.
11. Hegi ME, Diserens AC, Gorlia T, et al. MGMT gene silencing and benefit from temozolomide in glioblastoma. *N Engl J Med* 2005;352:997–1003.
12. House MG, Herman JG, Guo MZ, et al. Aberrant hypermethylation of tumor suppressor genes in pancreatic endocrine neoplasms. *Ann Surg* 2003;238:423–31; discussion 31–2.
13. Chan AO, Kim SG, Bedeir A, Issa JP, Hamilton SR, Rashid A. CpG island methylation in carcinoid and pancreatic endocrine tumors. *Oncogene* 2003;22:924–34.
14. Tsuchida Y, Therasse P. Response Evaluation Criteria in Solid Tumors (RECIST): new guidelines. *Med Pediatr Oncol* 2001;37:1–3.
15. Stridsberg M, Hellman U, Wilander E, Lundqvist G, Hellsing K, Oberg K. Fragments of chromogranin A are present in the urine of patients with carcinoid tumours: development of a specific radioimmunoassay for chromogranin A and its fragments. *J Endocrinol* 1993;139:329–37.
16. Granberg D, Eriksson B, Wilander E, et al. Experience in treatment of metastatic pulmonary carcinoid tumors. *Ann Oncol* 2001;12:1383–91.
17. Gal AA, Kornstein MJ, Cohen C, Duarte IG, Miller JI, Mansour KA. Neuroendocrine tumors of the thymus: a clinicopathological and prognostic study. *Ann Thorac Surg* 2001;72:1179–82.
18. Su YB, Sohn S, Krown SE, et al. Selective CD4+ lymphopenia in melanoma patients treated with temozolomide: a toxicity with therapeutic implications. *J Clin Oncol* 2004;22:610–6.