

Upper dorsal endoscopic thoracic sympathectomy: a comparison of one- and two-port ablation techniques

Michael O. Murphy, Jonathan Ghosh, Nadeem Khwaja, David Murray, Anastassi T. Halka, Andrew Carter, Neill J. Turner, Michael G. Walker*

Department of Vascular Surgery, Manchester Royal Infirmary, Oxford Road, Manchester M13 9WL, UK

Received 17 January 2006; received in revised form 29 March 2006; accepted 5 April 2006

Abstract

Objective: Facial blushing and hyperhidrosis, particularly in the facial, axillary or palmar distribution, are socially, professionally, and psychologically debilitating conditions. Endoscopic thoracic sympathectomy can be carried out through multiple ports or by using a single port and a modified thoracoscope with integrated electrocautery. We reviewed our own experience to compare outcomes between these methods. **Methods:** One hundred and nine consecutive endoscopic thoracic sympathectomies performed on 96 patients (M:F, 30:66) were examined with respect to operative method, symptom control, and patient satisfaction. Complete follow-up was available on 144 treated sides in 77 patients (80.2%), 38 treated with two ports, 39 performed by a one-port procedure. Mean age was 32.6 years (range 18–63) with a median follow-up of 25 months (range 5–85). Pooled data showed that the mean duration hospital stay was 1.6 nights with no deaths, conversions, or neurological injuries. **Results:** The one-port group showed superior outcomes in terms of hospital stay, rate of postoperative pneumothorax, and the need for chest drain insertion; however, there was no correlation between number of ports and patient satisfaction. The mean overall satisfaction rating out of 5 was 3.3 with 76.6% of patients rating the outcome as 3 or more. 90.9% had an initial improvement in symptoms, although 21 patients (27.3%) described a late return of symptoms. **Conclusion:** Endoscopic thoracic sympathectomy can be safely and effectively carried out using a single port with similar results to the traditional two-port procedure. The one-port procedure may allow for a shorter duration of stay and lower complication rate.

© 2006 Elsevier B.V. All rights reserved.

Keywords: Adult; Sympathectomy; Thoracoscopy; Minimally invasive surgery; Outcomes (includes mortality and morbidity)

1. Introduction

The first reports of sympathetic chain resection were published as early as 1920 [1], while the first report of endoscopic thoracic sympathectomy (ETS) was published in 1942 by Hughes [2]. Minimally invasive ETS has evolved to become a safe, effective, and reproducible treatment for facial blushing and hyperhidrosis (HH) of the hands, axilla, or face. Large published series have shown success rates of 71–100% following ETS with improved quality of life and treatment satisfaction of 93–95% [3,4]. However, no randomized trials have yet been performed to demonstrate the superiority of ETS over non-surgical treatments.

Primary or essential HH is a pathological condition of overperspiration characterized by excessive secretion of the eccrine glands disproportionate to the requirements of thermoregulation and dissipation of body heat. This is a functionally, professionally, and socially disabling condition

with an estimated incidence of 1% in developed countries [5]. The impact of HH on patients' quality of life is probably underestimated in clinical practice. No systemic or topical therapy has been found to reliably alleviate symptoms of HH. Among treatments used are antiperspirants, aluminium chloride, tap water iontophoresis, and oral anticholinergics. Botulinum Toxin A (Botox™) injection is the sole non-surgical treatment to show promise; however, limited long-term follow-up obligate further investigation [6], particularly when paralleled with the need for repeated treatments in other clinical indications.

Thoracic nerve resection (sympathectomy) or ablation (sympathicotomy) of the upper dorsal sympathetic chain has become the gold standard treatment for HH and facial blushing [7]. With the introduction of the endoscopic era, improved equipment has allowed a minimally invasive procedure to be carried out using video-assisted fiber optic thoracoscopy yielding excellent views of the sympathetic chain. More recently, the integration of electrocautery/diathermy to the thoracoscope permits a single-port procedure [8–10]. This approach has been shown to be faster [11], provides excellent cosmetic and functional outcomes [10] and

* Corresponding author. Tel.: +44 161 2764525; fax: +44 161 2768014.
E-mail address: stephanie.dalton@cmmc.nhs.uk (M.G. Walker).

does not require repositioning of the patient to do on both sides [12]. Despite this there is evidence that this method is underutilized with a recent regional survey showing only 1 of 78 surgeons used a single-port method [13].

Our aim was to analyze and compare the outcomes in patients treated using a one and more standard, multiple-port method.

2. Materials and methods

Between January 1998 and December 2003, 179 ETS were carried out on 96 patients by a single surgeon and anesthetist in an inner city University Teaching Hospital. There were 66 women and 30 men with a mean age of 32.6 years (range 18–63). One hundred and sixty-six procedures were bilateral; while of the 13 unilateral ETS, 10 were on the right. Four of the 96 patients (4.2%) went on to have a second operation, which was unilateral in all cases.

All 'redo' procedures and those patients treated for other indications, predominantly upper limb Raynaud's syndrome or ischemia, were excluded. Fifty-four ETS were performed for facial blushing/HH, 48 for axillary HH, and 54 for palmar HH, either solely or as a combination of symptoms (Fig. 1).

In bilateral procedures, the left side was operated on first and double lumen tracheal intubation was employed in all cases to allow isolation and active deflation of the operated side. Patients were placed in a semi-Fowler's

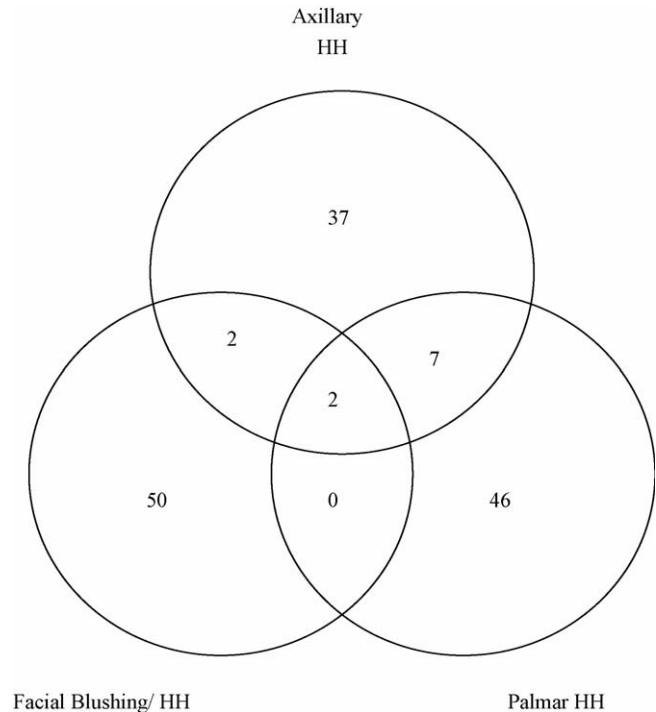


Fig. 1. Anatomical distribution of hyperhidrosis/blushing in 77 patients and 144 treated sides.

Tick each box as you see fit but feel free to add any additional comments at the end of the questionnaire.

- (a) Reason for the surgery: Blushing
 Excessive sweating in →
 Hands
 Armpit
 Face
- (b) Family history of this condition: No
 Parent
 Brother or sister
- (c) Improvement noticed: No improvement noticed
 Immediate
 Days afterwards
 Initial improvement but returned to →
 Same area
 Other area (specify below)
 Worsened symptoms in other areas
 Wound problem
- (d) Other Problems at the time: Eye problems
 Other (specify below)
- (e) Overall outcome: Perfect (5/5)
 Good (4/5)
 Satisfactory (3/5)
 Poor (2/5)
 Regret having procedure (1/5)
- (f) Treatments before surgery: None
 Creams/lotions
 Injections
 Medication
- (g) Information before surgery: GP
 Dermatologists/skin specialist
 Internet
 Friend
- (h) Additional comments:

Fig. 2. Postal questionnaire filled out by each patient.

position thus exposing both axillae to allow a sequential bilateral procedure without the need for turning. Peripheral arterial hemoglobin oxygen saturation was monitored routinely with pulse oximetry. On either side, the incision was made in the third intercostal space in the anterior axillary line. Thereafter a flexible port was introduced into the pleural cavity with an obtuse head trocar. In the small number of patients where pleural adhesions were encountered, these were divided without the need for an extra port. Monitoring of hand temperature to assess adequacy of resection was not routinely employed.

All cases used video assistance. The first 42 procedures were carried out using a 10 mm thoracoscope necessitating a second port for hook electrocautery in the second intercostal space in the mid-clavicular line. The remaining 54 operations were performed via a single port using an 8 mm 0° thoracoscope with integrated diathermy (Karl Storz Co, Tuttlingen, Germany). Following electrocautery of the sympathetic chain – T2 for facial blushing/HH, T2,3 for Palmar HH and T2,3,4 for axillary HH – the lungs were re-inflated under direct vision. Bleeding from small venules crossing the sympathetic trunk following ablation was controlled with diathermy. The intercostal muscle layer was closed with 2.0 PDS on a 'J-shaped' needle under a strip cutaneous apposition. All patients had a postoperative chest X-ray and a chest drain inserted where there was a significant pneumothorax. The majority of patients were discharged the next day with appropriate analgesia.

Follow-up was made by standard 6-week outpatient visit, medical note review, and by a specifically written postal questionnaire (Fig. 2), with a telephone interview for those who were non-responders. Patients were asked to rate their operative outcome of the procedure using a five-point scale.

Returned questionnaires were pooled with personal details, operative notes, preoperative and outpatient visits and were analyzed using SPSS V11.5. Statistical analysis is expressed as a mean for parametric data and median with ranges for non-parametric data. Comparisons between non-parametric data of the individual subgroups were done using a Pearson's correlation coefficient.

3. Results

Of the 180 procedures carried out on 96 patients, complete follow-up was available on 144 treated sides in 77 patients (80.2% return rate).

Pooled data represent 134 bilateral and 10 unilateral primary procedures, 38 treated with two ports, and 39 performed by a one-port procedure. There were no deaths, conversions, or neurological injuries (including postoperative Horner's syndrome). Blood loss was not routinely recorded but there was no incidence of postoperative hemothorax in the cohort. The demographics and operative outcomes of the two groups are outlined in Table 1. The two groups were similar in terms of age, sex distribution, and history of an affected family member. The difference in the rate of postoperative reflex sweating (RS) in the two groups was not statistically significant.

Nine patients (11.7%) had a unilateral pneumothorax on chest X-ray, two of whom (1.3%) required intercostal drain

Table 1
Patient details in the one-port and multiple-port groups

	Multiple-port group	Single-port group
M:F	15:23	9:30
Mean age (years)	34.33	32.44
Mean duration of stay (nights)	1.79	1.51
Family history of condition	13/38 (34.2%)	16/39 (41.0%)
Postoperative reflex sweating	11/38 (28.9%)	12/39 (30.8%)
Mean patient satisfaction out of 5	3.18	3.42
Went to a 'Redo' (%)	10.3	0
Prior to referral		
Consulted family doctor	36/38 (94.7%)	34/39 (97.2%)
Consulted Internet	6/38 (15.8%)	4/39 (10.3%)
Consulted dermatologist	6/38 (15.8%)	8/39 (20.6%)

insertion on symptomatic grounds. The rates of postoperative pneumothorax were 7.7% and 15.8% in the one- and multiple-port groups, respectively ($P < 0.05$), and it was noteworthy that both cases where intercostal drains were required were in the multiple-port group. There was a positive correlation between duration of hospital stay and presence of pneumothorax ($P < 0.05$).

The mean patient satisfaction was higher in the one-port group, 3.42 compared to the multiple-port group, 3.18 ($P = 0.13$). None of the patients in the single-port group went on to have 'redo' surgery while 4 patients (10.3%) went for a second procedure in the multiple-port group. All four additional surgeries were carried out because of a favorable outcome on one side only following bilateral ETS.

Patient stay was shorter in the single-port group with a mean stay of 1.51 nights compared to 1.79 in the multiple-port group ($P = 0.07$). The earlier discharge in the former group was not due to the higher rate of pneumothoraces and chest drains in the multiple-port group. The mean hospital stays for the cohort excluding postoperative pneumothoraces were 1.38 and 1.67, respectively.

While over 75% of the cohort rated their symptoms after the procedure as satisfactory or better, 17 patients rated symptoms as poor or worse. The overall satisfaction in patients with isolated axillary symptoms (3.38) compared favorably with those done for facial, palmar, or a combination of symptoms (3.24). However, the axillary group made up a greater percentage of those who complained of RS (43.9%) compared to those who were unaffected (23.0%).

Sixteen patients (20.7%) reported a family history of the condition. Seven had parents affected (9.1%), 5 had a sibling with the condition (6.5%), while in 4 individuals (5.1%) there was a history spanning two generations.

Almost 91% described a significant improvement in their symptoms following the procedure, 59 describing this as immediate (76.6%), with a further 11 describing a delayed improvement (14.3%). Seven patients described no improvement in their symptoms (9.1%). Twenty-one patients (27.3%) described a late return of symptoms with 72.7% symptom free at a median follow-up of 25 months (range 6–85).

Twenty-seven patients (35.1%) experienced RS, but it is noteworthy that only 6 patients (7.8%) reported this as severe. The mean score of patients without RS was 3.70 while in the RS group it was 2.56 and there was a positive correlation between poor patient satisfaction and the presence of postoperative RS ($P < 0.05$).

Thirty-one patients had some form of preoperative treatment consisting of topical creams (20), oral medication (9), and BotoxTM (2). The main source of information about the procedure prior to referral was the family physician (90.9%). In addition, 14 (18.2%) and 10 (12.9%) patients had consulted a dermatologists and the Internet, respectively. The absence of treatment or information prior to referral was a positive predictor of poor patient satisfaction ($P < 0.05$).

4. Discussion

This cohort study provides a comparison of a standard multiple-port technique and a single-port procedure, the former group acting as a control. The 80.2% return rate compares favorably with those in similar studies conducted elsewhere [14]. The anonymity of a postal survey provides data that is free from medical influence and provided a genuine patient viewpoint on satisfaction with the handling of their condition, the procedure, and perioperative information.

The results show that a one-port procedure is feasible, effective, and safe with similar outcomes, rates of RS, and patient satisfaction when compared with a standard procedure. These results are consistent with recently published data in terms of success, RS, patient satisfaction, pneumothorax, hospital stay [5], and family history [6]. HH and facial blushing are extremely debilitating conditions with several of the patients in our study describing the postoperative results as 'life changing'. The delayed improvement in symptoms observed in 14.3%, in the first few days postoperatively in most cases, is an odd finding and this subgroup of responders has not been reported before and did not have preponderance for any particular anatomical indication.

Although it is traditionally believed that the degree of postoperative RS was related to the extent of dissection, this has recently been questioned [15] and some authors would regard the high rates of RS seen in ETS, more than 90% in some series, as a consequence of the procedure rather than a true complication. It is widely accepted that RS is more common among patients treated for axillary HH than for other indications. Subgroup analysis in our patients showed those operated on for axillary symptoms made up a greater percentage of those who complained of RS (43.9%) compared to those who were unaffected (23.0%), similar to the poor outcomes reported in axillary patients by others [16]. The incidence of RS in this study is comparable with rates in large series and did not translate into a significant difference in patient satisfaction (3.38 vs 3.24). In our patient group, RS was well tolerated in most cases with only a small number of patients complaining of severe RS. Published case series with extensive follow-up would indicate that in up to 90% of cases, RS is well tolerated [17].

A family history was present in 34% of our patients, while rates as high as 65% have been reported in a Californian patient group, of comparable ethnic make up [6]. Although the influence of genetics has yet to be defined, the percentage of patients reporting a family history is higher than would be suggested by the 1% overall incidence and may represent either a true familial disposition or an under-estimation of the overall prevalence of the condition. There

is no evidence that the presence of a family history should alter investigation or treatment of HH or blushing.

In this study, there were no reported episodes of postoperative Horner's syndrome. This reflects the fact that the stellate ganglion is not visualized using the thoracoscopic approach. Interestingly, in the early reports of ETS, the incidence of Horner's syndrome was as high as 12% [18] but improved familiarity with the procedure and the anatomy, in particular the avoidance of the superior third of the stellate ganglion has resulted in rates of less than 1% in more modern series [19].

Postoperative pneumothorax rates have been reported as high as 75%, with 0.4–2.3% of these patients requiring chest drain insertion [20]. The incidence of pneumothorax in both groups compares favorably with these figures but it is noteworthy that both patients who required drains were treated by the traditional multiple port procedure, perhaps because a multiple port procedure is more likely to cause parenchymal injury and so require intercostal drainage.

Variability exists in the reported series in methods of inhaled anesthesia. In our series we employed double lumen intubation for sequential isolation and deflation of the operated side because it permits instantaneous visualization of the chain without the need for retraction. This is in accordance with groups who practice a minimally invasive or 'needlescopic' technique [9,21] but differs with the larger published series from Korea [22], Sweden [23], and Taiwan [24] where a trend towards single lumen intubation using a second port for retraction and apnoeic anesthesia is favored. It is notable, however, that in a paper concentrating on complications of ETS that three of the nine deaths described occurred with the use of double lumen anesthesia, the other deaths from bleeding (5) and an unknown cause (1) [20].

It is our practice to have a standardized preoperative discussion of the operative procedure, intended outcomes, and complications at the outpatient clinic and just before surgery. Despite this uniform approach, it was interesting to find that those who had been exposed to little information prior to referral to our service had poorer overall satisfaction that was not explained by any difference in indication, symptom distribution, or incidence of complications. It is difficult to explain this difference, and is likely to reflect a confounding variable such as those who seek information out are likely to gain most from the consent process and so have more realistic expectations from ETS.

Despite the non-randomized nature of this cohort study, we conclude that bilateral ETS can be successful when carried out through one port using double lumen intubation as short stay procedure with low complication rates. We have shown that the operation is particularly effective for facial and palmar symptoms. The high rates of RS seen in patients treated for axillary HH necessitates careful preoperative discussion but in this group did not translate into poor patient satisfaction. In this group, BotoxTM has a potential as an adjunct or alternative to ETS.

References

- [1] Kotzareff B. Resection partielle de tronc sympathique cervical droit pour hyperhidrose unilatérale. *Rev Med Suisse Romande* 1920;40:111–3.
- [2] Hughes J. Endothoracic sympathectomy. *Proc R Soc Med* 1942;35:585–6.

- [3] Ahn SS, Wieslander CK, Ro KM. Current developments in thoracoscopic sympathectomy. *Ann Vasc Surg* 2000;14(4):415–20.
- [4] de Campos JR, Kauffman P, Werebe Ede C, Andrade Filho LO, Kusniek S, Wolosker N, Jatene FB. Quality of life, before and after thoracic sympathectomy: report on 378 operated patients. *Ann Thorac Surg* 2003;76(3):886–91.
- [5] Loscertales J, Arroyo Tristan A, Congregado Loscertales M, Jimenez Merchan R, Giron Arjona JC, Arenas Linares C, Ayarra Jarne J. Thoracoscopic sympathectomy for palmar hyperhidrosis. Immediate results and postoperative quality of life. *Arch Bronconeumol* 2004;40(2):67–71.
- [6] Ro KM, Cantor RM, Lange KL, Ahn SS. Palmar hyperhidrosis: evidence of genetic transmission. *J Vasc Surg* 2002;35(2):382–6.
- [7] Whatling PJ, Collin J. Botulinum toxin injection is an effective treatment for axillary hyperhidrosis. *Br J Surg* 2001;88(6):814–5.
- [8] Drott C, Claes G, Olsson-Rex L, Dalman P, Fahlen T, Gothberg G. Successful treatment of facial blushing by endoscopic transthoracic sympathectomy. *Br J Dermatol* 1998;138(4):639–43.
- [9] Lardinois D, Ris HB. Minimally invasive video-endoscopic sympathectomy by use of a transaxillary single port approach. *Eur J Cardiothorac Surg* 2002;21(1):67–70.
- [10] Weight CS, Raitt D, Barrie WW. Thoracoscopic sympathectomy: a one-port technique. *Aust N Z J Surg* 2000;70(11):800.
- [11] Cohen Z, Shinhar D, Mordechai J, Mares AJ. Thoracoscopic upper thoracic sympathectomy for primary palmar hyperhidrosis. *Harefuah* 1996;131(9):303–5, 374.
- [12] Vallieres E. Endoscopic upper thoracic sympathectomy. *Neurosurg Clin N Am* 2001;12(2):321–7.
- [13] Khan AZ, Morgan SC, Currie IC, Lewis P, Lewis DR. Current practice of transthoracic endoscopic sympathectomy in the south west of England: an e-mail survey. *Eur J Vasc Endovasc Surg* 2001;22(4):373–5.
- [14] Dumont P, Denoyer A, Robin P. Long-term results of thoracoscopic sympathectomy for hyperhidrosis. *Ann Thorac Surg* 2004;78(5):1801–7.
- [15] Leseche G, Castier Y, Thabut G, Petit MD, Combes M, Cerceau O, Besnard M. Endoscopic transthoracic sympathectomy for upper limb hyperhidrosis: limited sympathectomy does not reduce postoperative compensatory sweating. *J Vasc Surg* 2003;37(1):124–8.
- [16] Ueyama T, Matsumoto Y, Abe Y, Yuge O, Iwai T. Endoscopic thoracic sympathectomy in Japan. *Ann Chir Gynaecol* 2001;90(3):200–2.
- [17] Chen HJ, Shih DY, Fung ST. Transthoracic endoscopic sympathectomy in the treatment of palmar hyperhidrosis. *Arch Surg* 1994;129(6):630–3.
- [18] Adar R. Surgical treatment of palmar hyperhidrosis before thoracoscopy: experience with 475 patients. *Eur J Surg Suppl* 1994;572:9–11.
- [19] Doolabh N, Horswell S, Williams M, Huber L, Prince S, Meyer DM, Mack MJ. Thoracoscopic sympathectomy for hyperhidrosis: indications and results. *Ann Thorac Surg* 2004;77(2):410–4 [discussion 4].
- [20] Ojimba TA, Cameron AE. Drawbacks of endoscopic thoracic sympathectomy. *Br J Surg* 2004;91(3):264–9.
- [21] Goh PM, Cheah WK, De Costa M, Sim EK. Needlescopic thoracic sympathectomy: treatment for palmar hyperhidrosis. *Ann Thorac Surg* 2000;70(1):240–2.
- [22] Lee DY, Hong YJ, Shin HK. Thoracoscopic sympathetic surgery for hyperhidrosis. *Yonsei Med J* 1999;40(6):589–95.
- [23] Rex LO, Drott C, Claes G, Gothberg G, Dalman P. The Boras experience of endoscopic thoracic sympathectomy for palmar, axillary, facial hyperhidrosis and facial blushing. *Eur J Surg Suppl* 1998;580:23–6.
- [24] Lin TS, Fang HY. Transthoracic endoscopic sympathectomy in the treatment of palmar hyperhidrosis—with emphasis on perioperative management (1,360 case analyses). *Surg Neurol* 1999;52(5):453–7.