

Quantitative Morphology of B, A, D, and PP Cells in Infants of Diabetic Mothers

R. D. G. MILNER, P. K. WIRDNAM, AND J. TSANAKAS

SUMMARY

Pancreatic specimens from 34 infants of diabetic mothers (IDM) and 32 control infants of gestational ages 26–44 wk were examined histologically using immunocytochemical stains for insulin, glucagon, somatostatin, and pancreatic polypeptide (PP). Each section was divided into PP-rich and PP-poor regions that are thought to be derived from the ventral and dorsal lobes of the gland, respectively. In some of these, the fractional area (%) occupied by positively stained B, A, and PP cells was determined by automatic image analysis, and the area occupied by D cells was determined by conventional point counting. The B cell fractional area was significantly higher in the IDM in both PP-poor and PP-rich areas ($P < 0.02$). The fractional area of A cells in PP-poor areas and of PP cells in PP-rich areas was also significantly greater in IDM ($P < 0.02$). The total endocrine cell fractional area was significantly greater in IDM in PP-poor but not in PP-rich regions of the pancreas. These results are not compatible with the hypothesis that maternal hyperglycemia results in specific fetal B cell hyperplasia and raise the possibility that hyperplasia of B, A, and PP cells in IDM may result from a variety of stimuli or that one stimulus acts on a pluripotential stem cell.

DIABETES 30:271–274, April 1981.

Pancreatic endocrine cell abnormalities in infants of diabetic mothers (IDM) are well documented, the most commonly described being hypertrophy and hyperplasia of the islets of Langerhans.^{1–7} The pathophysiology of diabetic pregnancy has led most authors to assume that the islet changes in IDM are due solely to B cell hypertrophy and hyperplasia, but the evidence for normality of the non-B endocrine cells has been largely subjective.⁶ The introduction of immunocytochemical staining^{8,9}

has made it possible to selectively identify insulin-, glucagon-, somatostatin-, and pancreatic polypeptide- (PP) containing cells. The purpose of this study was to establish the fractional areas of the four cell types in the pancreas of IDMs and to compare these with appropriate control pancreas. The analyses were subdivided by whether the tissue was rich or poor in pancreatic polypeptide, to take into account the fact that pancreas originating from the ventral or dorsal lobe has a different endocrine makeup.^{10–18}

MATERIALS AND METHODS

Formalin-fixed paraffin-embedded pancreatic blocks from 34 infants of diabetic mothers (IDM), with gestational ages ranging from 26 to 44 wk, were obtained from the Histopathology Departments of Sheffield Children's Hospital; King's College Hospital, London; University of Uppsala, Sweden; and University of Liege, Belgium. Pancreatic blocks from 32 age-matched controls were obtained from Sheffield. Infants used as controls had died from a variety of diseases, but cases with conditions known to affect the endocrine pancreas were excluded. Serial sections (6 μ m) were cut and adjacent sections were stained for insulin, glucagon, pancreatic polypeptide, and somatostatin by the immunoperoxidase (PAP) method of Sternberger.¹⁹ Endogenous peroxidase and erythrocyte pseudoperoxidase activity was inhibited by the method of Streefkerk²⁰ using a methanol/hydrogen peroxide (11:6 v/v) mixture. The following primary antisera were used: 1:1000 guinea pig anti-porcine insulin (Miles Laboratories Ltd., Slough, England), 1:1000 rabbit anti-porcine glucagon (a gift from Dr. C. M. D. Ross, Weston Park Hospital, Sheffield), 1:10,000 rabbit anti-bovine pancreatic polypeptide (a gift from Dr. R. E. Chance, Eli Lilly Laboratories, Indianapolis, Indiana), and 1:1000 rabbit anti-synthetic somatostatin (a gift from Professor W. Gepts, Brussels, Belgium). The reaction period for the above antisera was 24 h at 4°C. The secondary and tertiary antisera were 1:20 swine anti-rabbit IgG (Dako Immunoglobulins, Copenhagen, Denmark) and 1:100 horseradish peroxidase/rabbit anti-horseradish peroxidase complex (Dako Immunoglobulins, Copenhagen, Denmark). The reaction period for both

From the Department of Paediatrics, University of Sheffield, Children's Hospital, Sheffield S10 2TH, England.

Address reprint requests to Professor R. D. G. Milner, Department of Paediatrics, Children's Hospital, Sheffield S10 2TH, England.

Received for publication 14 August 1980.

was 40 min at room temperature. Sections were washed between different antisera with Tris saline buffer (pH 7.6, 0.05 M) and nonspecific background staining was reduced by pretreating the sections with 1% normal swine serum in Tris saline buffer. Visualization of the peroxidase was carried out according to the method of Graham and Karnovsky,²¹ using 125 mg of 3,4,3',4' tetra-amino biphenyl hydrochloride (BDH Chemicals Ltd., Poole, England) in 340 ml of citrate-acetate buffer (pH 5.0, 0.05M) containing 200 μ l of 100 vol hydrogen peroxide.

Control staining was performed by preabsorbing the primary antisera with their respective antigens or by omission of the primary antisera. Both procedures resulted in negative staining. Preabsorption of the primary antisera with antigens other than those against which they were raised did not prevent or diminish positive staining.

One section from each case was also stained with Masson's trichrome.

Morphometric analysis. Using a Wild binocular microscope at a magnification of 25 \times , the PP-rich region of the pancreatic-polypeptide-stained section from each case was outlined with a mapping pen. By placing the insulin, glucagon, or somatostatin section on top of the pancreatic polypeptide section, the PP-rich areas on these sections were also outlined. Measurements were performed separately in PP-rich and PP-poor regions of all pancreas.

The fractional surface area of a pancreatic section occupied by the immunostained cytoplasm of insulin (B), glucagon (A), or pancreatic polypeptide (PP) cells was measured using an automatic image analyzer (Quantimet 720) attached to a Nikon SKE series microscope and interfaced with a Hewlett Packard 9810A desk top calculator. The Quantimet 720 requires an adequate contrast difference between positive and negative tissue. In the case of somatostatin staining this was lacking, and therefore the fractional surface area occupied by immunostained cytoplasm of somatostatin (D) cells was measured by point counting as described by Chalkley.²² Large areas of interlobular connective tissue, blood vessels, or processing artifacts were not included in the measurement area.

RESULTS

All the 32 control pancreatic sections had PP-poor regions while 16 had PP-rich regions. Similarly, all 34 IDM pancreatic sections had PP-poor regions while 21 had PP-rich regions. However, not all the pancreatic sections were suitable for morphometric analysis, due to occasional high levels of nonspecific background staining. In IDM, B, A, D, and PP cell area estimates were performed in 34, 25, 17, and 28 cases, respectively, whereas in control infants, the numbers were 25, 26, 14, and 28. The individual results of the fractional area for each of the four cell types in PP-poor regions of control and IDM pancreas are shown diagrammatically in Figure 1. The mean fractional areas of B and A cells are significantly higher in IDM than in control pancreas ($P < 0.02$). Figure 2 shows the same results for PP-rich regions where it can be seen that the mean fractional areas of B and PP cells are significantly greater in IDM than in controls ($P < 0.02$). The mean fractional area of each cell type in those pancreatic sections with both PP-poor and PP-rich regions is shown in Table 1. In both control and IDM pancreas, each cell type was nonrandomly distributed between

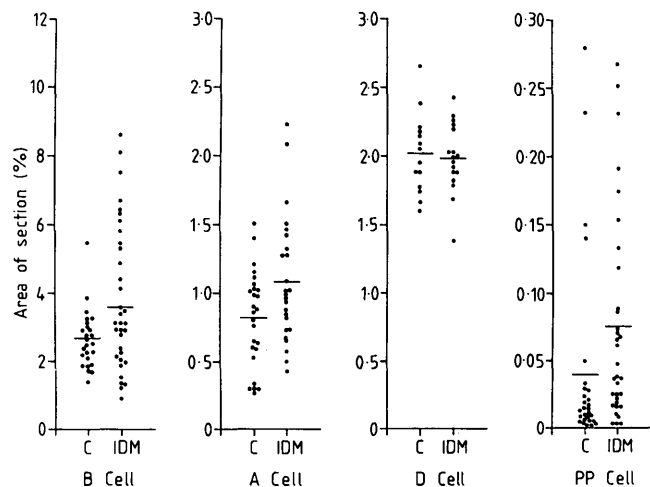


FIGURE 1. The fractional area (%) of B, A, D, and PP cells in the PP-poor region of individual IDM and control pancreas. The horizontal bar represents the mean of each group.

PP-rich and PP-poor regions, B, A, and D cells all being more common in PP-poor regions.

Although the fractional area occupied by PP cells in the PP-poor region was not significantly greater in IDM, the distribution of the cells was unusual. In the control pancreas, PP cells occurred in groups of two or three scattered throughout the exocrine tissue and were rarely seen in islets. In IDM, PP cells were located at the periphery of islets as well as being scattered in small clumps throughout the exocrine tissue. The fractional area of PP cells in PP-poor regions of IDMs correlated positively with the B cell fractional area in the same regions ($P < 0.01$), but there was no association between the two in PP-rich regions.

In some pancreatic sections morphometric analysis of all four cell types was possible, and, therefore, the total endocrine fractional area in these cases could be calculated as the sum of the four cell types (Table 2). No significant difference in total endocrine area was observed between control and IDM pancreas in PP-rich regions, but the mean endocrine fractional area in PP-poor regions of IDM was significantly greater than that in the control pancreas ($P < 0.02$).

FIGURE 2. The fractional area (%) of B, A, D, and PP cells in the PP-rich region of individual IDM and control pancreas. The horizontal bar represents the mean of each group.

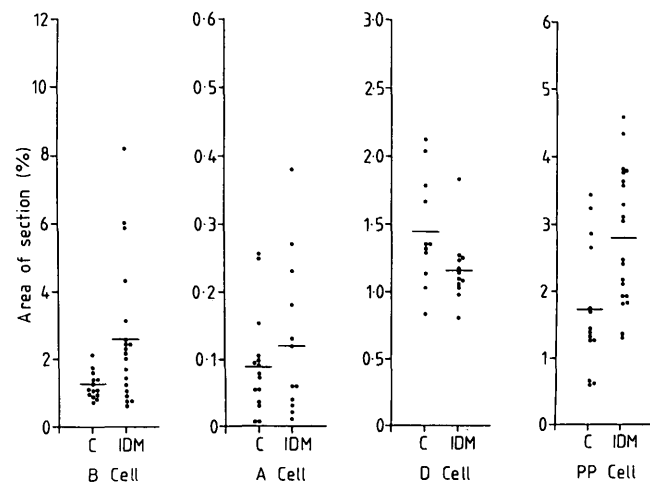


TABLE 1

The fractional area (% \pm SEM) of B, A, D, and PP cells in the PP-rich and PP-poor regions of pancreas from IDMs and control infants

Cell type	IDM			Control		
	PP-rich		PP-poor	PP-rich		PP-poor
B	2.29 \pm 0.38	(18)	3.42 \pm 0.47	1.24 \pm 0.09	(14)	2.50 \pm 0.18
A	0.11 \pm 0.03	(11)	1.02 \pm 0.14	0.09 \pm 0.01	(15)	0.75 \pm 0.08
D	1.15 \pm 0.07	(12)	1.95 \pm 0.08	1.44 \pm 0.12	(11)	2.00 \pm 0.09
PP	2.76 \pm 0.24	(18)	0.05 \pm 0.01	1.72 \pm 0.25	(14)	0.01 \pm 0.001

Only sections containing both PP-rich and PP-poor regions are included in the table. In each case the mean area in PP-rich regions differed significantly from that in PP-poor regions ($P < 0.005$). The number of observations is shown in parentheses.

The fractional area of pancreas occupied by endocrine tissue did not differ significantly between PP-rich and PP-poor regions in either IDM or control pancreas.

DISCUSSION

Pancreatic polypeptide-rich regions of the pancreas have been described in the rat,^{10,12} dog,¹³ and the human.^{11,14-17} The PP-rich region is confined to the posterior part of the head of the gland and is thought to be of ventral lobe origin, while the anterior part of the head, body, and tail are of dorsal lobe origin. Glucagon-containing cells are found more commonly in the PP-poor regions,^{10,12,14,16} and somatostatin-containing cells have been shown to be more numerous in the PP-poor regions of human neonatal pancreas.¹⁷ For these reasons, we decided to define pancreatic sections as PP-rich or PP-poor before attempting to compare the endocrine cell fractions of IDM and control infants.

An increased B cell fractional area was found in both PP-rich and PP-poor regions of IDM pancreas, confirming the conclusions in an earlier report.⁶ It is difficult to make a more direct comparison of our results and those of other workers since immunohistochemical staining reveals large numbers of single endocrine cells scattered throughout the exocrine tissue, which would not have been included in previous estimates of endocrine tissue fractions. However, 17 of the sections from IDM reported here were also studied by Cardell.⁴ Good agreement was observed between the origi-

nal estimates of islet fractional area and the present measurements of B cell fractional area (correlation coefficient 0.86, $P < 0.001$), despite the fact that in the original study no distinction was made between PP-rich and PP-poor regions.

The present experiments have shown for the first time that the IDM has an increased A and PP cell fraction as well as a greater B cell mass. The difference between control and test tissue is only demonstrable when appropriate precautions are taken to compare areas of the gland that are of the same embryological origin, and the importance of doing this must be emphasized.

Abnormal endocrine pancreatic development in IDM has been explained on the basis of maternal hyperglycemia causing fetal hyperglycemia, resulting in fetal B cell hyperplasia and hyperinsulinism.²³ Recently, emphasis has been placed on the complexity of the maternal metabolic changes in diabetic pregnancy,²⁴ and the present results show that the fetal endocrine response is more complex than pure B cell hyperplasia. When embryonic rat pancreas is grown in organ culture, amino acids have been shown to be more important than glucose in determining B cell development,^{25,26} and it is possible that the altered fetal environment in early diabetic pregnancy has a trophic effect on a common stem cell capable of developing into insulin, glucagon, or pancreatic polypeptide-containing cells of the mature fetus. The failure to observe a significant difference between somatostatin cells in the two groups could imply that this cell was of different embryological origin or was insensitive to the trophic stimuli.

TABLE 2

The total endocrine fractional area (% \pm SEM) in PP-rich and PP-poor regions of pancreas from IDM and control infants

Cell type	PP-rich	PP-poor
IDM		
B	2.13 \pm 0.51	4.12 \pm 0.44
A	0.09 \pm 0.03	1.25 \pm 0.12
D	1.15 \pm 0.14	2.05 \pm 0.06
PP	2.86 \pm 0.37	0.18 \pm 0.09
Total	6.25 \pm 0.63 (6)	7.62 \pm 0.59 (12)
Control		
B	1.41 \pm 0.10	2.78 \pm 0.17
A	0.11 \pm 0.02	0.98 \pm 0.08
D	1.46 \pm 0.15	2.06 \pm 0.08
PP	2.46 \pm 0.39	0.01 \pm 0.003
Total	5.45 \pm 0.53 (9)	5.48 \pm 0.25 (12)

Results are included from those sections in which morphometric analysis of all four cell types was possible. There was a significant difference ($P < 0.02$) in the total endocrine fractional area between IDM and controls in the PP-poor region but not in the PP-rich region. The number of observations is shown in parentheses.

ACKNOWLEDGMENTS

We are indebted to Prof. B. S. Cardell, Prof. J. L. Emery, Prof. G. Hultquist, and Dr. F. Sodoyez Goffaux for the supply of pancreatic material. The financial support of the British Diabetic Association and the Hawley Trust is gratefully acknowledged. We are grateful to Prof. J. L. Emery for helpful discussion.

REFERENCES

- Gray, S. H., and Feemster, L. C.: Compensatory hypertrophy and hyperplasia of the Islands of Langerhans in the pancreas of a child born of a diabetic mother. *Arch. Pathol. Lab. Med.* 7:348-55, 1926.
- Smyth, F. S., and Olney, M. B.: Diabetes and pregnancy. *J. Pediatr.* 13:772-86, 1938.
- Poursines, Y., and Cerati, P.: Hyperplasie du pancreas endocrine de la surrenale et de l'hypophyse, chez un foetus de mere diabetique. *Ann. Anat. Pathol.* 16:673-80, 1939.
- Cardell, B. S.: Hypertrophy and hyperplasia of the pancreatic islets in newborn infants. *J. Pathol. Bacteriol.* 66:335-46, 1953.

- ⁵ Woolf, N., and Jackson, W. P. U.: Maternal prediabetes and the fetal pancreas. *J. Pathol. Bacteriol.* 74:223-26, 1957.
- ⁶ Driscoll, S. G., Benirschke, K., and Curtis, G. W.: Neonatal deaths among infants of diabetic mothers. *Am. J. Dis. Child.* 100:818-35, 1960.
- ⁷ D'Agostino, A. N., and Bahn, R. C.: A histopathologic study of the pancreas of infants of diabetic mothers. *Diabetes* 12:327-31, 1963.
- ⁸ Coons, A. H., Greech, H. J., and Jones, R. N.: Immunological properties of an antibody containing a fluorescent group. *Proc. Soc. Exp. Biol. Med.* 47:200-202, 1941.
- ⁹ Coons, A. H., and Kaplan, M. H.: Localizations of antigens in tissue cells. II. Improvements in a method for the detection of antigens by means of fluorescent antibody. *J. Exp. Med.* 97:1-13, 1950.
- ¹⁰ Orci, L., Baetens, D., Ravazzola, M., Stefan, Y., and Malaisse-Lagae, F.: Pancreatic polypeptide and glucagon: non-random distribution in pancreatic islets. *Life Sci.* 19:1811-16, 1976.
- ¹¹ Orci, L., Malaisse-Lagae, F., Baetens, D., and Perrelet, A.: Pancreatic polypeptide-rich regions in the human pancreas. *Lancet* 2:1200-1201, 1978.
- ¹² Baetens, D., Malaisse-Lagae, F., Perrelet, A., and Orci, L.: Endocrine pancreas: three dimensional reconstruction shows two types of islets of Langerhans. *Science* 206:1323-25, 1979.
- ¹³ Gersell, D. J., Gingerich, R. L., and Greider, M. H.: Regional distribution and concentration of pancreatic polypeptide in the human and canine pancreas. *Diabetes* 28:11-15, 1979.
- ¹⁴ Malaisse-Lagae, F., Orci, L., and Perrelet, A.: Anatomic and hormonal markers for the ventral primordium in the human pancreas? *N. Engl. J. Med.* 300:436, 1979.
- ¹⁵ Malaisse-Lagae, F., Stefan, Y., Cox, J., Perrelet, A., and Orci, L.: Identification of a lobe in the adult human pancreas rich in pancreatic polypeptide. *Diabetologia* 17:361-65, 1979.
- ¹⁶ Orci, L., Stefan, Y., Malaisse-Lagae, F., and Perrelet, A.: Instability of pancreatic endocrine cell populations throughout life. *Lancet* 1:615-16, 1979.
- ¹⁷ Rahier, J., Wallon, J., Gepts, W., and Haot, J.: Localization of pancreatic polypeptide cells in a limited lobe of the human neonate pancreas: remnant of the ventral primordium? *Cell Tissue Res.* 200:359-66, 1979.
- ¹⁸ Rahier, J., Wallon, J., and Henquin, J. C.: Abundance of somatostatin cells in the human neonatal pancreas. *Diabetologia* 18:251-54, 1980.
- ¹⁹ Sternberger, L. A., Hardy, P. H., Cuculis, J. J., and Meyer, H. G.: The unlabelled antibody enzyme method of immunohistochemistry. *J. Histochem. Cytochem.* 18:315-33, 1970.
- ²⁰ Streefkerk, J. G.: Inhibition of erythrocyte pseudoperoxidase activity by treatment with hydrogen peroxidase following methanol. *J. Histochem. Cytochem.* 20:829-31, 1972.
- ²¹ Graham, R. C., and Karnovsky, M. J.: The early stages of absorption of injected horseradish peroxidase in the proximal tubules of the mouse kidney: ultrastructural cytochemistry by a new technique. *J. Histochem. Cytochem.* 14:291-302, 1966.
- ²² Chalkley, H. W.: Method for the quantitative morphologic analysis of tissues. *J. Natl. Cancer Inst.* 4:47-53, 1943.
- ²³ Pedersen, J.: Weight and length at birth of infants of diabetic mothers. *Acta Endocrinol.* 16:330-41, 1954.
- ²⁴ Freinkel, N., and Metzger, B. E.: Pregnancy as a tissue culture experience, the critical implications of maternal metabolism for fetal development. *In* *Pregnancy Metabolism, Diabetes and the Fetus*. Ciba Foundation Symposium 63 (new series). Excerpta Medica, Amsterdam, 1979.
- ²⁵ de Gasparo, M., Milner, G. R., Norris, P. D., and Milner, R. D. G.: Effect of glucose and amino acids on foetal rat pancreatic growth and insulin secretion in vitro. *J. Endocrinol.* 77:241-48, 1978.
- ²⁶ Milner, G. R., de Gasparo, M., Kay, R., and Milner, R. D. G.: Effect of glucose and amino acids on insulin, glucagon and zymogen granule size of foetal rat pancreas grown in organ culture. *J. Endocrinol.* 82:179-89, 1979.