

Oral Contraceptives Decrease the Prevalence of Ovarian Cancer in the Hen

Lindsey S. Treviño¹, Elizabeth L. Buckles², and Patricia A. Johnson¹

Abstract

Ovarian cancer is the leading cause of reproductive cancer death in U.S. women. This high mortality rate is due to the lack of early detection methods and ineffectiveness of therapy for advanced disease. Until more effective screening methods and therapies are developed, chemoprevention strategies are warranted. The hen has a high spontaneous prevalence of ovarian cancer and has been used as a model for studying ovarian cancer chemoprevention. In this study, we used the hen to determine the effect of progestin alone, estrogen alone, or progestin and estrogen in combination (as found in oral contraceptives) on ovarian cancer prevalence. We found that treatment with progestin alone and in combination with estrogen decreased the prevalence of ovarian cancer. A significant risk reduction of 91% was observed in the group treated with progestin alone (risk ratio = 0.0909; 95% CI: 0.0117–0.704) and an 81% reduction was observed in the group treated with progestin plus estrogen (risk ratio = 0.1916; 95% CI = 0.043–0.864). Egg production was also significantly reduced in these treatment groups compared with control. We found no effect of progestin, either alone or in combination with estrogen, on apoptosis or proliferation in the ovary, indicating that this is not the likely mechanism responsible for the protective effect of progestin in the hen. Our results support the use of oral contraceptives to prevent ovarian cancer and suggest that ovulation is related to the risk of ovarian cancer in hens and that other factors, such as hormones, more than likely modify this risk. *Cancer Prev Res*; 5(2); 343–9. ©2011 AACR.

Introduction

Ovarian cancer is the leading cause of reproductive cancer death in U.S. women. This high mortality rate can be attributed to the fact that more than 80% of women with the disease are diagnosed at late stages when tumors have metastasized. The 5-year survival rate is less than 30% for later stages of the disease, although the survival rate is more than 90% for the approximately 15% of women diagnosed at earlier stages of the disease when the tumor is still confined to the ovary (1). These data support the need for the development of early detection strategies for the disease. Unfortunately, efforts to identify a widely acceptable screening strategy have thus far failed and so cancer prevention remains the most viable method to limit development of fatal ovarian neoplasms. Chemopreventive agents, such as oral contraceptives, may act

to protect women from the development of ovarian cancer.

Epidemiologic studies have consistently shown that ovarian cancer risk is decreased in women who use oral contraceptives (2). In fact, a recent study showed that oral contraceptive use is associated with a 20% decrease in relative risk of ovarian cancer for every 5 years of use and longer duration of use further decreases the risk (3). In addition, the risk is reduced for 30 years or more after use has stopped (3). Several mechanisms have been proposed to explain how oral contraceptives decrease the risk of ovarian cancer, including inhibition of ovulation, induction of apoptosis, and inhibition of proliferation (4). Animal models can be used to test the efficacy and mechanism of action of chemopreventive agents.

Previous studies have used the domestic hen (*Gallus domesticus*) as a model of ovarian cancer. Like humans, the hen spontaneously develops aggressive ovarian cancers and the incidence increases with age (5). Previous studies have shown that chicken ovarian tumors express antigens that are frequently expressed in human ovarian cancer as well as those that are useful as surrogate biomarker endpoints in chemoprevention trials (6). Hens have also been used in studies testing the efficacy of putative chemopreventive agents including aspirin (7) and flaxseed (8) in preventing ovarian cancers. One promising study determined that treatment with medroxyprogesterone acetate (MPA; Depo-Provera), a common constituent

Authors' Affiliations: Departments of ¹Animal Science and ²Biomedical Sciences, Cornell University, Ithaca, New York

Current address for L.S. Treviño: One Baylor Plaza, BCM-130, M512, Houston, TX 77030.

Corresponding Author: Patricia A. Johnson, 202 Morrison Hall, Cornell University, Ithaca, NY 14853. Phone: 607-255-3077; Fax: 607-255-9829; E-mail: pat.johnson@cornell.edu

doi: 10.1158/1940-6207.CAPR-11-0344

©2011 American Association for Cancer Research.

used in progestin-only formulations of contraceptives, resulted in a 15% reduction of risk of ovarian cancer in treated hens compared with control hens (9).

Our objective was to compare the efficacy of progestin (P), estrogen (E), and progestin and estrogen in combination (P+E) in preventing ovarian cancer in the hen. These hormones are commonly delivered together in commercially available human contraceptives. To determine a possible mechanism by which the hormones might prevent cancer, we examined how the treatments affected apoptosis and cellular proliferation in normal hen ovaries. Our results suggest that ovulation is related to the prevalence of ovarian cancer, and the effect of ovulation may be separate from the effects of steroid hormones.

Materials and Methods

Animals

A total of 231, approximately 1-year-old single comb White leghorn hens were randomly divided into 4 treatment groups. All birds were individually caged with access to food and water *ad libitum* and maintained on a 15-hour light and 9-hour dark schedule. Treatment groups consisted of: control ($n = 59$), progestin and estrogen treatment combined (P+E; $n = 56$), progestin alone (P; $n = 59$), and estrogen alone (E; $n = 57$). Hens were treated as described below. Egg production was monitored daily as a marker of ovulation and hens were weighed monthly. Necropsies were done on hens that died before the termination of the experiment ($n = 71$) as well as those that were euthanized by CO₂ asphyxiation at the end of the experiment ($n = 160$). All animal procedures were approved by the Institutional Animal Care and Use Committee of Cornell University.

Treatments

Supplementary Table S1 summarizes the treatment scheme. Hens in the control group were injected with 1 mL of the sesame oil vehicle and implanted with an empty silastic tube. Hens in the P+E treatment group were injected with 50 mg of MPA (Spectrum Chemical) dissolved in 1 mL of sesame oil and implanted with 25 mg estradiol implants (Compudose 200; Elanco Animal Health) previously reported to be bioactive in the hen (10, 11). Hens in the P treatment group were injected with MPA as described above and implanted with an empty silastic tube. Finally, hens in the E treatment group were injected with 1 mL of sesame oil and implanted with estradiol implants as described above.

Injections of either sesame oil or MPA were administered into the breast muscle (i.m) every 3 to 4 weeks throughout the treatment period. Initially, the hens were injected with 100 mg as previously described (9) resulting in an almost complete cessation of egg production; however, due to adverse effects, the dose was reduced to 20 mg. Unfortunately, 20 mg was not sufficient to suppress ovulation long term and, as a result, after approximately 8 months, the hens were injected with 50 mg which was maintained throughout the experiment. Compared with 100 mg, this dose was

better tolerated and yet still reduced egg production (although to a lesser extent).

For implantation of the silastic tube or estradiol implant, hens were administered a local anesthetic (bupivacaine; 5 mg/mL) between the wings in which implants were inserted through an incision made with a scalpel. The incision was closed with tissue adhesive (VetBond). A second implant was inserted in the same location 180 days after the first implant to ensure estradiol levels were elevated throughout the treatment period. Treatments were administered for a total of 16 months similar to the previous study in which progestin was administered to hens (9).

Tissue collection

Hens that died during the course of the experiment ($n = 71$) or were terminated at the end of the experiment received a full necropsy. Tumors in hens were identified grossly by the presence of firm, nodular outgrowths on the ovary, often accompanied by ascites and implants on the serosa of tissues within the abdominal cavity as described previously (5, 12–14). Sections of ovary were fixed in 10% neutral buffered formalin and processed for histopathology by the Cornell University College of Veterinary Medicine Histopathology Laboratory. Slides were stained with hematoxylin and eosin (H&E) and examined by 2 independent observers, one of whom is a board certified veterinary pathologist (ELB). Ovarian neoplasms were verified based on histology. Ovarian tumors identified in hens were staged based on gross examination as previously described (7, 15). Briefly, stage 1 tumors are restricted to the ovary and only detectable by histology. Stage 2 tumors are restricted to the ovary and observable at necropsy. Stages 3 and 4 tumors have abdominal seeding without or with ascites, respectively.

Immunofluorescence

Paraffin sections of ovary were deparaffinized and rehydrated, followed by antigen retrieval by boiling in sodium citrate buffer for 20 minutes. Sections were blocked in PBS with 5% nonfat dry milk plus 10% goat serum and incubated with mouse anti-chicken ovalbumin (A6075; Sigma-Aldrich) at 115 µg/mL overnight at 4 degrees. Control slides were incubated with mouse immunoglobulin (IgG). Detection was achieved by incubating with AlexaFlour 488 goat anti-mouse IgG at 1 µg/mL (A-11001; Molecular Probes) for 1 hour at 39 degrees. Slides were viewed by a Nikon eclipse E600, and pictures were taken with a Spot RT Slider camera. Images were taken at 3 seconds exposure.

Estradiol radioimmunoassay

Blood samples were collected from the wing vein of a subset of hens throughout the experiment at 30, 60, 120, 180, and 360 days after the implantation of the first estradiol or control implants. Plasma isolated from the blood samples was assayed for estradiol using the Coat-A-Count estradiol RIA Kit (Siemens). All samples were assayed in duplicate. The average intraassay coefficient of variation was 22%.

Terminal deoxynucleotidyl transferase-mediated dUTP nick end labeling assay

Serial sections of ovarian tissue from a subset of the animals without cancer in each treatment group ($n = 6$ per group) were analyzed for relative amounts of cellular apoptosis in the surface epithelium and within the follicular wall. Apoptosis was assessed using the ApopTag Plus Peroxidase *In Situ* Apoptosis Detection Kit (Chemicon International) according to the manufacturer's instructions. Slides were scanned at 40× with the Aperio Scanscope (Aperio Inc.). Twenty random images of ovarian surface epithelium and 30 random images of the stroma for each hen were obtained with the ImageScope Viewer program (Aperio Inc.). Positive staining of apoptotic nuclei was quantified in the images using the color range function of Adobe Photoshop. The intensity of positive staining was then graded on a scale from 0 to 3 (0, no staining; 1, low; 2, medium; and 3, high intensity staining).

Proliferation assay

Serial sections from normal hens in each treatment group ($n = 6$) were analyzed for proliferation by assessing expression of proliferating cell nuclear antigen (PCNA) protein by immunofluorescence. For this procedure, deparaffinized sections were rehydrated through a series of incubations with xylene and ethanol. Sections were boiled in citrate buffer for antigen retrieval, blocked in 10% goat serum in PBS for 30 minutes at 37 degrees, and then incubated with a mouse anti-rat PCNA antibody previously validated in the chicken (PC-10; Santa Cruz Biotechnology) at a dilution of 1:50 for 1 hour at 37 degrees (16). Control slides were incubated with mouse IgG. This was followed by incubation with AlexaFluor 488-conjugated goat anti-mouse secondary antibody for 1 hour at 37 degrees. Slides were viewed by a Nikon eclipse E600, and 6 random images of OSE and the stroma for each hen were obtained at 20× magnification. PCNA-positive nuclei were identified in the images using the color range function of Adobe Photoshop, and the intensity of positive staining was graded on a scale from 0 to 3 (0, no staining; 1, low; 2, medium; and 3, high intensity staining).

Statistical analysis

All tests were carried out using SAS (version 9.2) with a significance level of $P < 0.05$. The effect of treatment on ovarian cancer incidence was analyzed by proc GENMOD as recommended by staff at the Cornell Statistical Consulting Unit. Egg production and plasma estradiol level among treatments were analyzed using proc MIXED. The effects of treatment on apoptosis and proliferation in the OSE and the stroma were analyzed by proc GLM.

Results

Effect of treatment on cancer prevalence and stage

We observed a significant effect of treatment on the prevalence of ovarian cancer ($P < 0.01$; Table 1). Nineteen percent of the hens in the control treatment group were

Table 1. Prevalence of ovarian cancer among treatments

Treatment	Total hens	Hens diagnosed with cancer (%)
Control	59	11 (19)
P+E	56	2 (4) ^a
P	59	1 (2) ^b
E	57	11 (19)

^aDecreased prevalence compared to control ($P < 0.01$).
^bDecreased prevalence compared to control ($P < 0.005$).

diagnosed with ovarian cancer. This is similar to the percentages previously reported (10%–23%) in hens at this age (7, 17). Treatment with P alone ($P < 0.005$) and P+E ($P < 0.01$) significantly decreased prevalence of ovarian cancer compared with the control treatment, whereas administration of E alone had no significant effect.

On the basis of gross evaluation, we found no significant effect of treatment on stage of ovarian cancer (Table 2), and the majority of the tumors were late stage (metastases present outside of the ovary, with or without ascites). Four tumors (all in the control group) were identified as early stage after examination of the H&E-stained section. At necropsy, these ovaries had no visible signs of cancer, and 2 out of the 4 ovaries were regressed (no large or small yellow follicles present).

Treatment-associated mortality

A total of 71 out of the original 231 (31%) birds died before experiment termination (Supplementary Table S2). Out of the birds that died, a larger proportion of hens treated with P alone (37%) or P+E (34%) died compared with the control (22%) or E alone (30%) groups, however, we found no statistically significant effect of treatment on mortality. The higher mortality in the hens treated with MPA may be due to the fact that a higher dose of MPA (100 mg) was used at the beginning of the experiment because decreasing the dose resulted in less mortality. The higher dose was also used in the Barnes and colleagues study (2002) and they reported a higher mortality rate for hens treated with MPA (32%) compared with the control

Table 2. Stage of ovarian cancer (7) for hens diagnosed with the disease

Treatment	Stage 1 (%)	Stage 2 (%)	Stage 3 (%)	Stage 4 (%)
Control	4 (36)	0 (0)	4 (36)	3 (27)
P+E	0 (0)	0 (0)	0 (0)	2 (100)
P	0 (0)	0 (0)	1 (100)	0 (0)
E	0 (0)	0 (0)	5 (45)	6 (55)

Downloaded from http://aacrjournals.org/cancerpreventionresearch/article-pdf/5/2/343/2250874/343.pdf by guest on 14 April 2024

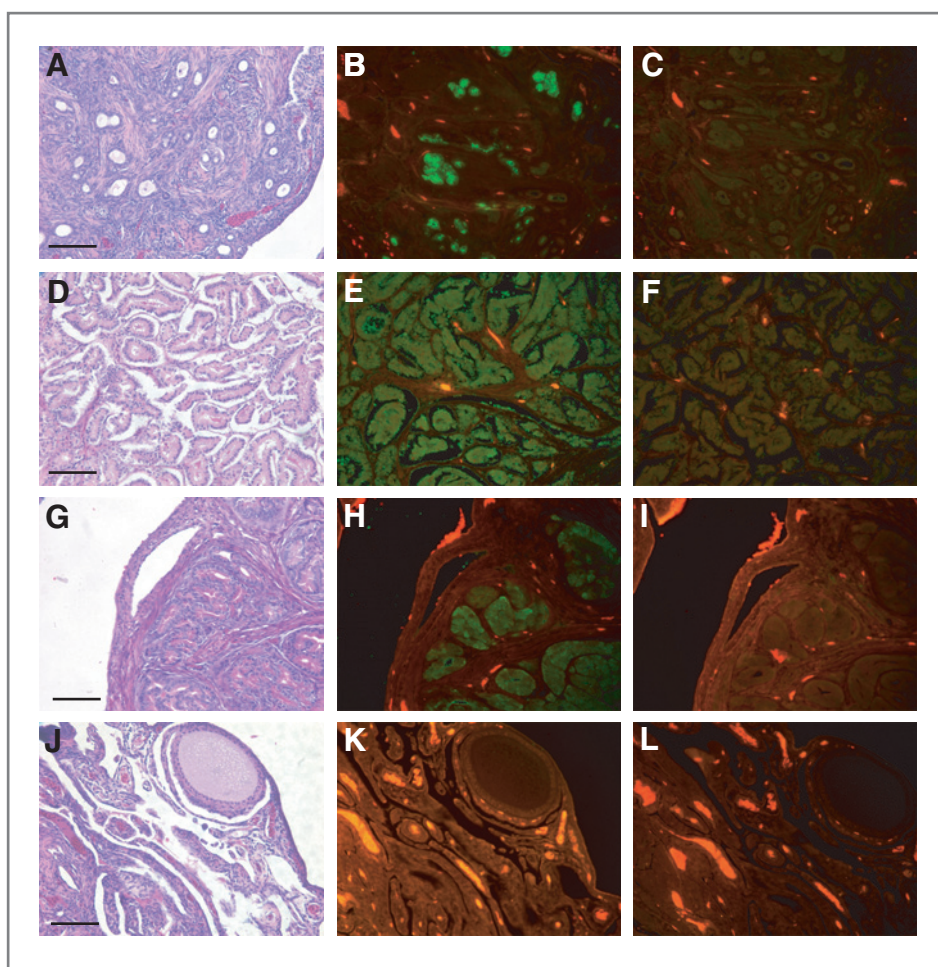


Figure 1. Immunofluorescence with antibodies against ovalbumin in chicken ovarian tumor subtypes. Representative H&E (A), ovalbumin (B), and IgG (C) images of an endometrioid tumor. Representative H&E (D), ovalbumin (E), and IgG (F) images of a serous tumor. Representative H&E (G), ovalbumin (H), and IgG (I) images of an "oviduct" tumor. Representative H&E (J), ovalbumin (K), and IgG (L) images of normal ovary. Ovalbumin protein expression (green) is obvious in endometrioid (B), serous (E), and "oviduct" (H) tumors and not present in normal ovary (K). Autofluorescence of red blood cells is visible in the normal ovary. Scale bar, 100 μ m.

treatment (9). The mechanism of this effect is unclear; however, MPA treatment can result in polyuria, weight gain, liver damage, and diabetes in birds (18). We also observed no significant effect of treatment on body weight (data not shown).

Histologic classification of ovarian tumors

Microscopically, we identified 3 separate morphologies of the ovarian tumors: endometrioid, serous, and oviduct like. Figure 1 illustrates examples of all 3 types. The endometrioid tumors resemble a type found in women and are generally solid with a dense stromal component. They can exhibit glands (Fig. 1A), as well as squamous differentiation and are positive for ovalbumin (Fig. 1B), a known marker for chicken ovarian tumors (15, 19). Note the lack of staining in the IgG control (Fig. 1C). The serous tumors (Fig. 1D) also resemble a type found in women and have very little stroma associated with the tumor cells (compared with endometrioid tumors) and also express ovalbumin (Fig. 1E). These tumors can have papillary projections. Again, the IgG control is negative (Fig. 1F). The third type, oviduct-like, does not have a tumor counterpart in women.

These tumors are associated with the production of secretory granules (Fig. 1G), resemble the oviduct in the chicken and express ovalbumin as well (Fig. 1H). The IgG control is negative (Fig. 1I). They may represent a subtype of the other 2 main types, but this is not clear at this time. As expected, normal ovary (Fig. 1J) does not express ovalbumin (Fig. 1K) and the IgG control is negative (Fig. 1L). In hens treated with progestin, either alone or in combination with estrogen, we found no "oviduct" type of tumors (Table 3).

Table 3. Histologic subtypes of chicken ovarian tumors among treatments

Treatment	Endometrioid (%)	Serous (%)	"Oviduct" (%)
Control	5 (45)	1 (9)	5 (45)
P+E	1 (50)	1 (50)	0 (0)
P	1 (100)	0 (0)	0 (0)
E	3 (27)	4 (36)	4 (36)

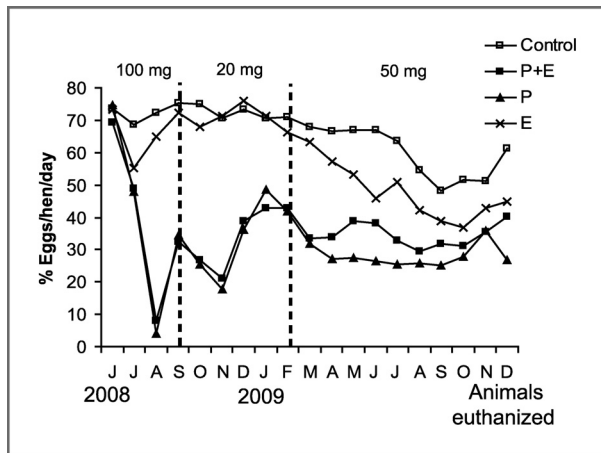


Figure 2. Effect of treatment on egg production ($n = 231$). P+E or P significantly decreased egg production compared with control ($P < 0.01$). There was no significant effect on egg production for the hens treated with E compared with control.

Egg production

Administration of progestin alone or in combination with estrogen significantly decreased egg production compared with the control treatment ($P < 0.01$; Fig. 2). There was no significant effect on egg production for the hens treated with estrogen alone compared with the control treatment.

Plasma estradiol levels

Hens treated with estrogen alone ($P < 0.01$) or in combination with progestin ($P < 0.05$) had significantly higher plasma estradiol levels than the control group (Fig. 3). As expected, treatment with progestin alone had no effect on plasma estradiol levels compared with the control treatment.

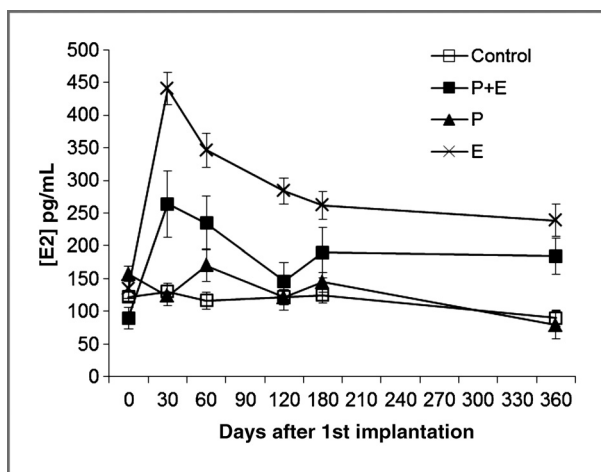


Figure 3. Effect of treatment on plasma estradiol levels ($n = 8$ to 14 hens per treatment). E ($P < 0.01$) or P+E ($P < 0.05$) significantly elevated plasma estradiol levels compared with control. Treatment with P had no effect on plasma estradiol levels compared with control.

Terminal deoxynucleotidyl transferase-mediated dUTP nick end labeling assay

We analyzed apoptosis in ovaries of hens lacking neoplasms and found no significant effect of hormone treatment on apoptosis in either the OSE or the stroma (data not shown).

Proliferation assay

PCNA expression was also assessed in ovaries of hens lacking neoplasms and we observed positive expression mainly in the granulosa cell layer of ovarian follicles in all treatment groups. There was no significant effect of treatment on proliferation in either the OSE or the stroma (data not shown).

Discussion

We have shown that administration of progestin, either alone or in combination with estrogen, decreases ovarian cancer prevalence in the hen (Table 1). In fact, treatment with progestin alone, or in combination with estrogen, significantly reduced the risk by 91% and 81%, respectively. These results extend a previous study which reported a 15% reduction in ovarian cancer in hens treated with MPA (9). One difference between the previous study and the current one is the duration of MPA administration. In the Barnes and colleagues study, hens were injected with MPA 3 times during the treatment period, resulting in decreased egg production for 4 weeks immediately following each injection and increased egg production thereafter. On average, egg production was decreased by an estimated 24% in the hens treated with MPA. In contrast, we injected hens with MPA every 3 to 4 weeks suppressing egg production for approximately 16 months (Fig. 2), effectively reducing egg production by 57% and 52% in the P and P+E treatment groups, respectively, compared with control treatment. This treatment scheme resulted in a larger reduction in risk than the Barnes and colleagues study, suggesting that the onset of ovarian cancer is related to ovulatory events.

In the 1970's Fathalla proposed the "incessant ovulation" hypothesis (20). This hypothesis is based on the idea that ovulation results in the repeated rupture and repair of the OSE. Over time, this cyclical damage could result in genetic mutations that predispose these cells to become cancerous. Women with high lifetime ovulation numbers would therefore have an increased risk of developing ovarian cancer. Epidemiologic studies in women support this hypothesis. Pregnancy and oral contraceptive use are associated with decreased risk of ovarian cancer and both reduce the number of ovulatory events (21).

In addition to our results, other studies in the hen indicate an association between the number of ovulatory events and the risk of ovarian cancer. Fredrickson observed a difference in ovarian cancer prevalence between 2 flocks of hens with different ovulation rates (5). In his study, 1 flock of hens exhibited a higher rate of egg production as well as a higher incidence of genital tumors (including ovarian tumors) than another flock (5). Giles and colleagues reported a

Downloaded from http://aacrjournals.org/cancerpreventionresearch/article-pdf/5/2/343/2250874/343.pdf by guest on 14 April 2024

significantly decreased incidence of ovarian cancer in restricted ovulator (RO) hens than wild-type (WT) hens (14). RO hens have a mutation that affects their ability to incorporate yolk into the developing follicle and consequently ovulate significantly fewer times than their WT siblings (22). Interestingly, RO hens have a hormone profile associated with a high risk of ovarian cancer (low progesterone and high estrogen; refs. 23, 24) further suggesting that ovulation is linked to ovarian cancer risk. More recently, Carver and colleagues (2011) have shown that caloric restriction in hens decreases ovulatory events, as well as prevalence of ovarian adenocarcinoma (25).

Collectively, these studies in the hen support the "incessant ovulation" hypothesis because decreased ovulation (egg production) results in a decreased incidence of ovarian cancer. Other studies in the hen have tested alternative chemopreventive agents, including aspirin (7) and flaxseed (8). Administration of these agents resulted in a decrease in ovarian cancer stage, but did not affect cancer incidence. Interestingly, no effect on egg production was observed with these agents. This is in contrast to the significant decrease of egg production and ovarian cancer prevalence with the progestin treatment, but without an effect on tumor stage, in the current study. Taken together, evidence from ovarian cancer in both women and hens highlights the link between the prevalence of ovarian cancer and ovulation.

The hormonal components of oral contraceptives, progestin and estrogen, are thought to affect the development and/or progression of ovarian cancer. Progesterone has been proposed to protect against ovarian tumor development (26). This protective effect might be independent of the effect of progestin on ovulation because women on progestin-only formulations of oral contraceptives are also at reduced risk of ovarian cancer even though ovulation is only suppressed in about 40% of users (27). Progesterone/progestin inhibition of proliferation and induction of apoptosis in normal OSE (28, 29) has been suggested to explain the protective effect observed with oral contraceptive use. In our study, however, we did not find a significant effect of progestin on apoptosis or proliferation in the OSE or the stroma from normal hens (data not shown). Therefore, it appears that, in the hen, induction of apoptosis or inhibition of proliferation does not account for the protective effect of the treatments that we observed.

Interestingly, tumors we have classified as oviduct like did not develop in hens treated with P+E or P alone (Table 3). These tumors resemble normal chicken oviduct and are characterized by the presence of large numbers of secretory granules (Fig. 1). They may represent subtypes of the endometrioid or serous types which we identified, or higher degrees of tumor differentiation. Further characterization of these tumors, including analysis of molecular markers specific to these subtypes (30, 31), is needed to determine the significance of this result.

In contrast to progesterone, estrogens are thought to promote ovarian tumor progression (32). Studies have shown that women who undergo estrogen-only hormone

replacement therapy have an increased risk of developing ovarian cancer (33–35). In this study, hens treated with estrogen (either alone or in combination with progestin) exhibited significantly increased plasma estradiol levels compared with control hens (Fig. 3), but there was no effect of estrogen treatment on cancer prevalence (Table 1). Estrogens have been shown to promote cellular proliferation and inhibit apoptosis in ovarian cancer cells (36). Similar to our results with progestin alone, we did not observe an effect of estrogen on apoptosis or proliferation in the OSE or the stroma from normal hens (data not shown).

Although not statistically significant, a larger percentage of hens diagnosed with serous-type tumors were treated with either P+E or E (83%) versus those that were in the control and P treatment groups (17%; Table 3). In humans, serous tumors are considered more aggressive than the other subtypes, and the association of estrogen treatment with the serous subtype suggests that estrogen may promote tumor progression in the hen. These results are similar to those seen in a recent study in which exogenous estrogen was shown to accelerate the onset of ovarian tumor development and decrease survival in a mouse model of the disease (37). Although we did not directly measure tumor onset in this study, hens treated with estrogen alone exhibit a decline in egg production before the hens in the control group (Fig. 2). Egg production has been shown to decline in hens with ovarian cancer (7), and it is possible that this decline in egg production signifies an earlier onset of the disease in these hens. Furthermore, a previous study from our laboratory showed that ovarian tumors in the hen exhibit an upregulation of estrogen-regulated genes compared with normal ovary (15). These results suggest that estrogen might play a role in the progression of ovarian cancer in the hen.

Our results indicate that ovulatory events might set the level of risk of the disease and other factors (such as hormones) may modulate this risk. The low incidence of ovarian cancer in hens with suppressed ovulation may be due to a decrease of ovulation-associated genotoxic stress. Studies have shown that nonsteroidal anti-inflammatory drugs (NSAID) inhibit tumor growth in rodents (38) and decrease tumor stage in hens (7), highlighting the potential role of inflammation in the etiology of ovarian cancer. Genotoxic insults may target either the OSE or the fimbrial mucosa, both proposed sites of origin of ovarian cancer (39). Administration of oral contraceptives to hens significantly decreased ovarian cancer prevalence, supporting the use of oral contraceptives as chemopreventive agents for ovarian cancer.

Disclosure of Potential Conflicts of Interest

No potential conflicts of interest were disclosed.

Acknowledgments

The authors thank Dr. James Giles for technical assistance and aid with manuscript preparation, as well as Ms. Katherine Backel, Ms. Elizabeth McCalley, Ms. Jessye Wojtusik, and Ms. Mila Kundu for technical assistance.

Grant Support

This work was supported in part by grant number F31GM078742 from the National Institute of General Medical Sciences. The content is solely the responsibility of the authors and does not necessarily represent the views of the National Institute of General Medical Sciences or the NIH.

The costs of publication of this article were defrayed in part by the payment of page charges. This article must therefore be hereby marked *advertisement* in accordance with 18 U.S.C. Section 1734 solely to indicate this fact.

Received July 9, 2011; revised October 28, 2011; accepted November 12, 2011; published OnlineFirst December 1, 2011.

References

- Howlander N, Noone AM, Krapcho M, Neyman N, Aminou R, Waldron W, et al. (editors). SEER Cancer Statistics Review, 1975–2008, National Cancer Institute. Bethesda, MD. Available from: http://seer.cancer.gov/csr/1975_2008/, based on November 2010 SEER data submission, posted to the SEER web site, 2011.
- Sueblinvong T, Carney ME. Current understanding of risk factors for ovarian cancer. *Curr Treat Opt Oncol* 2009;10:67–81.
- Collaborative Group on Epidemiological Studies of Ovarian Cancer. Ovarian cancer and oral contraceptives: collaborative reanalysis of data from 45 epidemiological studies including 23,257 women with ovarian cancer and 87,303 controls. *Lancet* 2008;371:303–14.
- Ho S. Estrogen, progesterone and epithelial ovarian cancer. *Reprod Biol Endocrinol* 2003;1:73.
- Fredrickson TN. Ovarian tumors of the hen. *Environ Health Perspect* 1987;73:33–51.
- Rodriguez-Burford C, Barnes MN, Bery W, Partridge EE, Grizzle WE. Immunohistochemical expression of molecular markers in an avian model: a potential model for preclinical evaluation of agents for ovarian cancer chemoprevention. *Gynecol Oncol* 2001;81:373–9.
- Urick ME, Giles JR, Johnson PA. Dietary aspirin decreases the stage of ovarian cancer in the hen. *Gynecol Oncol* 2009;112:166–70.
- Ansenberger K, Richards C, Zhuge Y, Barua A, Bahr JM, Luborsky JL, et al. Decreased severity of ovarian cancer and increased survival in hens fed a flaxseed-enriched diet for 1 year. *Gynecol Oncol* 2010;117:341–7.
- Barnes MN, Bery WD, Straughn JM, Kirby TO, Leath CA, Huh WK, et al. A pilot study of ovarian cancer chemoprevention using medroxyprogesterone acetate in an avian model of spontaneous ovarian carcinogenesis. *Gynecol Oncol* 2002;87:57–63.
- Klandorf H, Blauwiel R, Qin X, Russell RW. Characterization of a sustained-release estrogen implant on oviduct development and plasma Ca concentrations in broiler breeder chicks: modulation by feed restriction and thyroid state. *Gen Comp Endocrinol* 1992;86:469–82.
- Qin X, Klandorf H. Effect of estrogen on egg production, shell quality, and calcium metabolism in molted hens. *Comp Biochem Physiol C Pharmacol Toxicol Endocrinol* 1995;110:55–9.
- Barua A, Abramowicz JS, Bahr JM, Bitterman P, Dirks A, Holub KA, et al. Detection of ovarian tumors in chicken by sonography. A step toward early diagnosis in humans? *J Ultrasound Med* 2007;26:909–19.
- Barua A, Bitterman P, Abramowicz JS, Dirks AL, Bahr JM, Hales DB, et al. Histopathology of ovarian tumors in laying hens: a preclinical model of human ovarian cancer. *Int J Gynecol Cancer* 2009;19:531–9.
- Giles JR, Elkin RG, Trevino LS, Urick ME, Ramachandran R, Johnson PA. The restricted ovulator chicken: a unique model for investigating the etiology of ovarian cancer. *Int J Gynecol Oncol* 2010;20:738–44.
- Trevino LS, Giles JR, Wang W, Urick ME, Johnson PA. Gene expression profiling reveals differentially expressed genes in ovarian cancer of the hen: support for oviductal origin? *Hormones and Cancer* 2010;1:177–86.
- Giles JR, Olson LM, Johnson PA. Characterization of ovarian surface epithelial cells from the hen: a unique model for ovarian cancer. *Exp Biol Med* 2006;231:1718–25.
- Johnson PA, Giles JR. Use of genetic strains of chickens in studies of ovarian cancer. *Poult Sci* 2006;85:246–50.
- Joyner KL. Theriogenology. In: Ritchie BW, Harrison GJ, Harrison LR, editors. *Avian medicine: principles and application*. West Palm Beach, FL: Zoological Education Network; 1994.
- Giles JR, Shavaprasad HL, Johnson PA. Ovarian tumor expression of an oviductal protein in the hen: a model for human serous ovarian adenocarcinoma. *Gynecol Oncol* 2004;95:950–3.
- Fathalla MF. Incessant ovulation—a factor in ovarian neoplasia? *Lancet* 1971;2:163.
- Lukanova A, Kaaks R. Endogenous hormones and ovarian cancer: epidemiology and current hypotheses. *Cancer Epidemiol Biomarkers Prev* 2005;14:98–107.
- Elkin RG, Zhong Y, Porter RE, Walzem RL. Validation of a modified PCR-based method for identifying mutant restricted ovulator chickens: substantiation of genotypic classification by phenotypic traits. *Poult Sci* 2003;82:517–25.
- Leszczynski DE, Hagan RC, Rowe SE, Kummerow FA. Plasma sex hormone and lipid patterns in normal and restricted-ovulator chickens. *Gen Comp Endocrinol* 1984;55:280–8.
- Ocon-Grove OM, Maddineni S, Hendricks GL, Elkin RG, Proudman GA, Ramachandran R. Pituitary progesterone receptor expression and plasma gonadotrophin concentrations in the reproductively dysfunctional mutant restricted ovulator chicken. *Domest Anim Endocrinol* 2007;32:201–15.
- Carver DK, Barnes HJ, Anderson KE, Pettite JN, Whitaker R, Berchuck A, et al. Reduction of ovarian and oviductal cancer in calorie-restricted laying chickens. *Cancer Prev Res* 2011;4:562–7.
- Risch HA. Hormonal etiology of epithelial ovarian cancer, with a hypothesis concerning the role of androgens and progesterone. *J Natl Cancer Institute* 1998;90:1774–86.
- Fleming JS, Beaugie CR, Haviv I, Chenevix-Trench G, Tan OL. Incessant ovulation, inflammation and epithelial ovarian carcinogenesis: revisiting old hypotheses. *Mol Cell Endocrinol* 2006;247:4–21.
- Ivarsson K, Sundfeldt K, Brännström M, Janson PO. Production of steroids by human ovarian surface epithelial cells in culture: possible role of progesterone as growth inhibitor. *Gynecol Oncol* 2001;82:116–21.
- Rodriguez GC, Walmer DK, Cline M, Krigman H, Lessey BA, Whitaker RS, et al. Effect of progestin on the ovarian epithelium of macaques: cancer prevention through apoptosis? *J Soc Gynecol Invest* 1998;5:271–6.
- McCluggage WG. My approach to and thoughts on the typing of ovarian carcinomas. *J Clin Pathol* 2008;61:152–63.
- Soslow RA. Histologic subtypes of ovarian cancer: an overview. *Int J Gynecol Pathol* 2008;27:161–74.
- Cunat S, Hoffman P, Pujol P. Estrogens and epithelial ovarian cancer. *Gynecol Oncol* 2004;94:25–32.
- Pearce CL, Chung KC, Pike MC. Increased ovarian cancer risk associated with menopausal estrogen therapy is reduced by adding a progestin. *Cancer* 2009;115:531–9.
- Morch LS, Lokkegaard E, Andreason AH, Kruger-Kjaer S, Lidegaard O. Hormone therapy and ovarian cancer. *JAMA* 2009;302:298–305.
- Sueblinvong T, Carney ME. Current understanding of risk factors for ovarian cancer. *Curr Treat Opt Oncol* 2009;10:67–81.
- Zheng H, Kavanagh JJ, Hu W, Liao Q, Fu S. Hormonal therapy in ovarian cancer. *Int J Gynecol Oncol* 2007;17:325–38.
- Laviolette LA, Garson K, Macdonald EA, Senterman MK, Courville K, Crane CA, et al. 17 β -estradiol accelerates tumor onset and decreases survival in a transgenic mouse model of ovarian cancer. *Endocrinology* 2010;151:929–38.
- Daikoku T, Wang D, Tranguch S, Morrow JD, Orsulic S, DuBois RN, et al. Cyclooxygenase-1 is a potential target for prevention and treatment of ovarian epithelial cancer. *Cancer Res* 2005;65:3735–44.
- Jarboe EA, Folkins AK, Drapkin R, Ince TA, Agoston ES, Crum CP. Tubal and ovarian pathways to pelvic epithelial cancer: a pathological perspective. *Histopathology* 2008;53:127–38.