

Megaloblastic Erythropoiesis in Acquired Hemolytic Anemia

By M. L. N. WILLOUGHBY, M. A. PEARS, A. A. SHARP AND M. J. SHIELDS

ERYTHROPOIESIS in hemolytic anemia is usually normoblastic or macro-normoblastic,¹ but occasionally is found to be megaloblastic.² When this latter state is found, there is usually an additional factor, predisposing to deficiency of folic acid or vitamin B₁₂, such as pregnancy,³⁻⁷ poor nutrition,⁷⁻⁹ Addisonian pernicious anemia,^{2,10,11} hepatic cirrhosis¹² or chronic leukemia.² Megaloblastic erythropoiesis may also develop in uncomplicated hemolytic anemia if this is of long duration such as thalassemia^{2,13-15} or sickle cell anemia.⁷ Only rarely have cases been reported where megaloblastic^{16,17} or transitional megaloblastic^{2,18} erythropoiesis has developed in uncomplicated acute hemolytic anemia.

The purpose of this report is to describe a case of acquired autoimmune hemolytic anemia with a macrocytic peripheral blood picture and a megaloblastic bone marrow and in which there was no predisposing cause for folic acid or vitamin B₁₂ deficiency. The clinical course, laboratory findings and therapy are described and the diagnostic problem discussed.

METHODS

Standard hematological and serological methods were performed as described by Dacie.¹⁹ The augmented Histamine test meal was performed as described by Kay.²⁰ The serum B₁₂ level was estimated by the Lactobacillus Leishmanii biological assay method of Meynell, Cooke, Cox and Gaddie.²¹ Radiochromium red-cell survival studies were performed according to the method of Mollison and Veall,²² and surface counting by the method of Jones and Szur.²³

Blood levels of bilirubin, urea and plasma proteins were measured by standard methods.²⁴⁻²⁶ Fecal fat excretion was measured by the method of van de Kamer et al.²⁷

CASE HISTORY

A 60 year old English housewife was referred to the Radcliffe Infirmary on February 5, 1958, because of the progressive development of anemia. She had noticed progressively increasing dyspnea on exertion and tiredness over the previous eight months and a darkening of the urine for six months. A few days before admission, she noticed for the first time that her skin and the whites of her eyes had become yellow. At no time had she noticed any symptoms referable to the digestive system and her appetite had remained good. There had been no obvious weight loss. Her bowel habits had been unchanged and there had been no alteration in the color of the stools.

There was no past or family history of jaundice or blood disease. The only drugs which had been administered were iron tablets and Benadryl. The latter had been given for attacks of angioneurotic edema following domestic worries and had been discontinued three months before her present history began. Drowsiness was the only ill effect noticed from this drug.

She was pale, rather icteric and slightly obese. There was no cheilosis or koilonychia and

From the Radcliffe Infirmary, Oxford, England.

Submitted June 7, 1960; accepted for publication Dec. 10, 1960.

the tongue was normal. There was no ulceration of the legs. The temperature was 100 F., pulse 80 per minute with forearm pulsation and the blood pressure was 125/75 mm.Hg. The jugular venous pressure was raised to 15 cm. above the sternal angle. There was considerable sacral and ankle edema. The respiratory rate was 25 per minute and the alae nasi were working. The apex beat was 4 inches from the mid line in the fifth intercostal space. The impulse was diffuse and the whole praecordium moved in systole. There was a soft praecordial systolic murmur. The spleen was enlarged to 4½ inches below the left costal margin and the liver to 1 inch below the right costal margin. No other clinical abnormality was found.

Initial laboratory investigations disclosed a severe degree of anemia (Hb 4.7 Gm. per cent), mild leukopenia (W.B.C. 3,000 per cu. mm.), mild thrombocytopenia (108,000 per cu. mm.), and a reticulocytosis of 9.8 per cent with the red cells showing macrocytosis (M.C.D. 8.1), poikilocytosis and Howell-Jolly bodies. A sternal puncture showed a

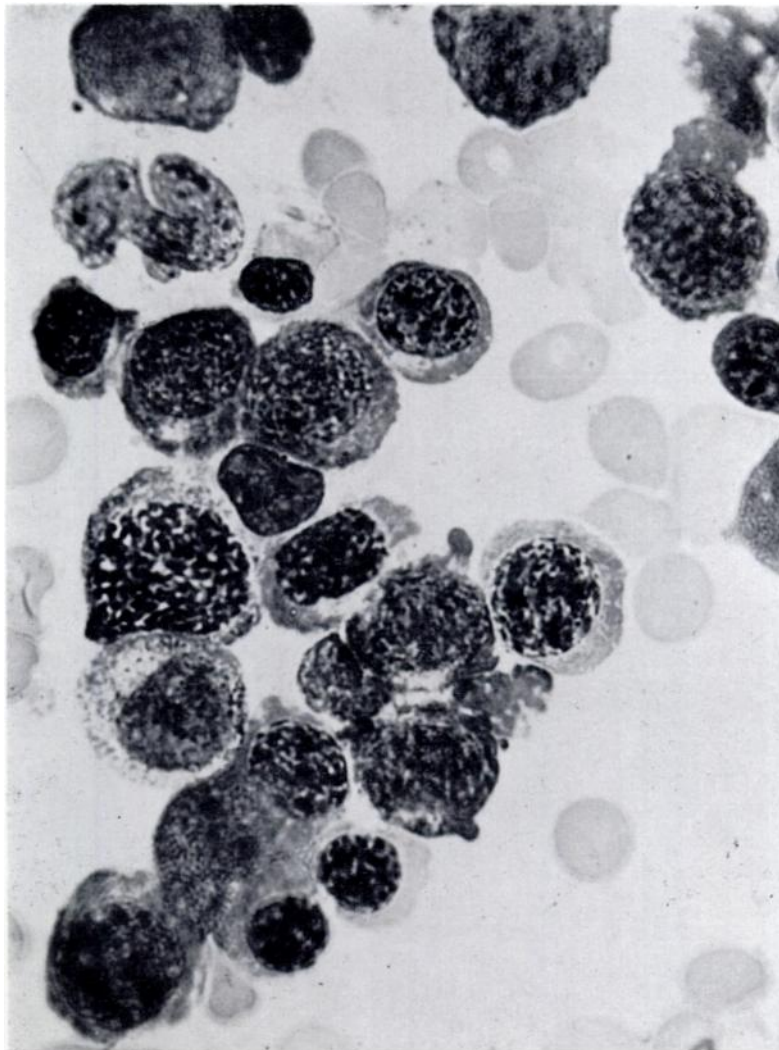


Fig. 1.—Photomicrograph of megaloblastic marrow smear (X1530).

hyperplastic, megaloblastic marrow (fig. 1). These findings suggested the diagnosis of Addisonian pernicious anemia, but the reticulocyte level of 9.8 per cent and the degree of splenomegaly raised the possibility of increased red cell destruction. The finding of a positive direct Coombs test confirmed this suspicion but the relative importance of hemolysis, B₁₂ deficiency or folic acid deficiency could not be assessed from the results then available. Blood for serum B₁₂ estimation was taken.

Further serological investigations showed that the direct Coombs test was positive to a titer of 1 in 40 with a specific anti-gamma globulin serum and to the same titer with a "broad-spectrum" antiglobulin serum. This reaction was only partially inhibited by gamma globulin and to a low titer (1 in 64). An eluate from the red cells contained a weak non-specific antibody reacting at 37 C. with papain-treated cells. The patient's serum contained cold agglutinins, active against her own red cells at 4 C. in saline to a titer of 1 in 32, and warm incomplete antibodies, active against papainised red cells at 37 C. to a titer of 1 in 4. No Rh or other specificity was demonstrable in these antibodies or in a red-cell eluate. The patient's serum did not lyse enzyme-treated or PNH red cells. These findings indicated that the antibodies possessed characters intermediate between the typical "warm" or "cold" type¹⁹ found in acquired auto-immune hemolytic anemia.

On February 8, 1959, she developed bronchopneumonia, with a fever of 103 F. The onset of bilateral bronchopneumonia made the correction of her anemia a matter of urgency. She was given 200 micrograms of vitamin B₁₂ parenterally and this was continued daily for 12 days. She was also treated with a small blood transfusion of packed cells from 1½ pints, 250 mg. erythromycin 6-hourly and digoxin.

By February 12, 1958, her pulmonary condition had somewhat improved and a second sample of sternal marrow showed an almost complete reversion to normoblastic hyperplasia. This was thought to represent a significant response to B₁₂ treatment. The peripheral blood at this time was showing a daily increase in reticulocyte count (fig. 2) and

Relationship of Haemoglobin & Reticulocyte levels to Treatment.

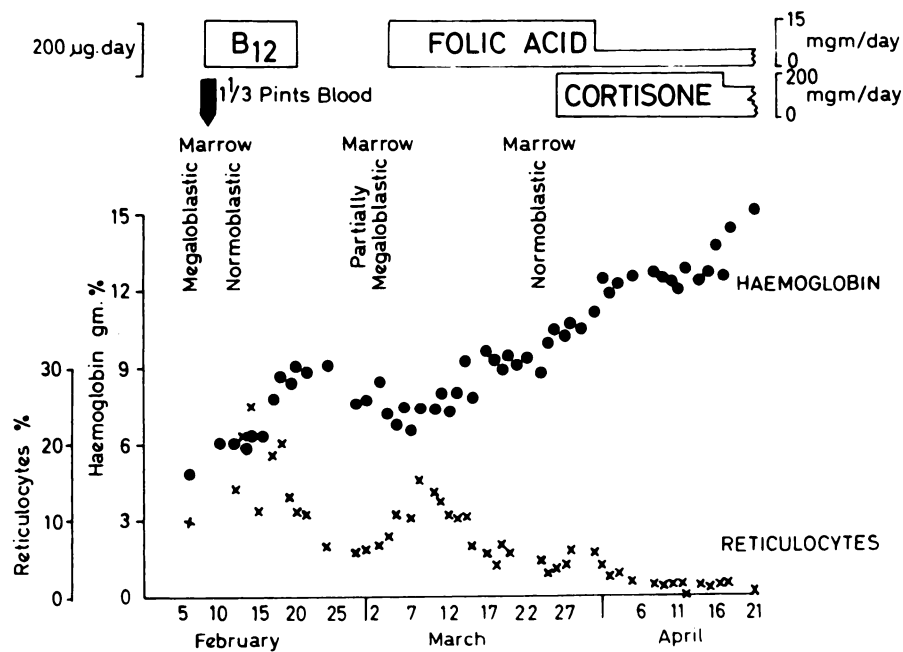


Fig. 2.—Hematological data in a case of autoimmune hemolytic anemia.

by February 14, six days after B₁₂ treatment had commenced, the reticulocytes reached a peak count of 25 per cent. This appeared to confirm that this was a case of pernicious anemia complicated by hemolytic anemia. On February 15, the result of the serum B₁₂ estimation became available and was found to be 300 micro-micrograms per ml., in the middle of the normal range. Also a histamine test meal revealed the presence of free HCl (pH 2.0). The diagnosis of hemolytic anemia had, however, now been substantiated from preliminary points of a ⁵¹Cr red-cell survival test, using compatible cells corresponding closely to the patient's cells with respect to many of the blood group systems. The mean cell life of these cells was in the region of seven days, indicating an unusually severe degree of hemolysis. Also the red-cell fragility in saline was increased at this time.

By March 3, 1958, the reticulocyte count had fallen to between 6 and 7 per cent and the Hb level was now no longer rising. A further marrow biopsy was performed and this showed a partial return to the megaloblastic type of hyperplasia. Since B₁₂ deficiency could not be responsible for this, it was suspected that there must be a deficiency of folic acid. Treatment with 15 mg. of folic acid intramuscularly per day was commenced on March 4. There was rapid subjective improvement. The reticulocytes rose to a peak of 15.1 per cent on March 8 followed by a small rise in Hb (fig. 2). A ⁵¹Cr red-cell survival test on March 13, using the patient's own cells, still showed a grossly reduced mean cell life of 11 days. Surface counts showed that the red cells were sequestered in both liver and spleen. A further sample of sternal marrow was obtained on March 24 and this showed a complete disappearance of megaloblasts with an entirely normoblastic type of erythroblastic hyperplasia, consistent with uncomplicated hemolytic anemia. No evidence of intestinal abnormality, such as could independently cause folic acid deficiency, was revealed by barium meal and follow-through studies, the small-intestine pattern being normal. A fat balance showed absorption of 93 per cent of a dietary fat intake.

Cortisone treatment, 50 mg. q.d.s., was commenced on March 26, 1958, in an attempt to control the hemolytic anemia. The hemoglobin level rose steadily to 14.8 Gm. per cent and the reticulocyte level fell to less than 0.5 per cent (fig. 2). The plasma bilirubin fell, from being consistently above 1.0 mg. per cent, to 0.7 mg. per cent. A third ⁵¹Cr red cell survival test was commenced 14 days after cortisone treatment had been instituted and showed a mean cell life of 24 days using the patient's own cells. The patient has now remained on reduced steroid dosage for 18 months and the anemia has not recurred. The direct Coombs test, however, has remained positive although somewhat weaker.

In September, 1959, the patient was readmitted for cholecystectomy. A gall stone consisting partly of pigment was found.

COMMENT

This patient presented with symptoms, signs and laboratory findings that initially suggested a diagnosis of Addisonian pernicious anemia. Although the number of reticulocytes was higher and the spleen larger than usually encountered, such have been reported in typical examples of pernicious anemia.²⁸⁻³⁰ Similarly, while other findings indicated that hemolysis was taking place, a significant degree of hemolysis is often encountered in pernicious anemia,³¹ while Weiner³² has drawn attention to occasional occurrence of a weakly positive Coombs test in this disease. However, the successful elution of antibodies from the patient's red cells, increased red cell osmotic fragility and markedly reduced red cell survival showed that an auto-immune hemolytic process existed. There still remained the possibility that this patient could have pernicious anemia complicated by antibody-induced hemolysis. However, this was ruled out by the finding of a normal serum B₁₂ level. Similarly, the presence of normal fat absorption and the fact that no drugs with known antifolic acid activity had been administered made folic acid deficiency appear unlikely.

The apparent hematological response to parenteral B₁₂ therapy in spite of a normal serum level may be similar to the phenomenon reported by Mollin and Ross³³ who described a suboptimal or incomplete response to B₁₂ therapy in patients with megaloblastic anemia but normal serum B₁₂ levels. The similar hematological response that followed folic acid therapy (fig. 2) may have been due to a depletion of this vitamin. Spray and Witts³⁴ have suggested that such a folic-acid depletion can occur when the output of red cells by the marrow is considerably increased. Also Chanarin, Dacie and Mollin² have found an increased rate of plasma folic acid clearance in 13 cases of hemolytic anemia. A further observation consistent with the concept that increased folic-acid utilization occurs with excessive erythroid turnover is that of Jonssen.⁹ He reported that the drug Pyrimethamine, a known folic acid antagonist, produced a megaloblastic change more rapidly in the marrow of patients with hemolytic anemia than in normal subjects.

There is a danger that a case such as has been described here may be diagnosed incorrectly unless it is recognized that hemolytic anemias may present in this way. It is particularly in the acquired form of auto-immune hemolytic anemia that the diagnosis may be overlooked. Such an omission may be serious as it is in this group that a sudden severe episode of hemolysis may cause death. Fortunately, the direct Coombs test on the patient's red cells will usually reveal the presence of the antibodies and prevent this diagnostic error. It may profitably be performed in all cases of megaloblastic anemia.

SUMMARY

1. A case of auto-immune hemolytic anemia complicated by megaloblastic erythropoiesis is described. The possible mechanism is discussed.
2. The direct Coombs test is a useful adjunct in the diagnosis of megaloblastic anemias.

SUMMARIO IN INTERLINGUA

1. Es describe un caso de auto-immun anemia hemolytic, complicate per erythropoiese megaloblastic. Le mecanismo possibile es discutate.
2. Le directe test de Coombs es un utile adjuncto in le diagnose de anemias megaloblastic.

ACKNOWLEDGEMENTS

We wish to thank Professor Sir George Pickering for permission to report this case, and also the Director and Staff of the Department of Chemical Pathology, Radcliffe Infirmary, Oxford, for making available the results of the biochemical tests.

REFERENCES

1. Dacie, J. V. and White, J. C.: Bone marrow biopsy. *J. Clin. Path.* 2:1, 1949.
2. Chanarin, I., Dacie, J. V. and Mollin, D. L.: Folic-acid deficiency in haemolytic anaemia. *Brit. J. Haemat.* 5: 245, 1959.
3. Davidson, L. S. P.: Thirty years experience of the megaloblastic anaemias. *Edinburgh Med. J.* 59:315, 1952.
4. Goldberg, M. A. and Schwartz, S. O.: Mediterranean anaemia in a Negro complicated by pernicious anaemia of pregnancy. *Blood* 9:648, 1954.
5. Drury, M. I. and Georghagan, F.: Congenital haemolytic anaemia complicated by megaloblastic anaemia of pregnancy. *Brit. Med. J.* 2:393, 1957.

6. Gross, R. and Ludwig, H.: Schwangerschaftsherniciosa bei einem Fall von familiärem hämolytischen Ikterus (Sphaerocytose). *Aertze. Wschr.* 12: 992, 1957.
7. Jonsson, U., Roath, O. S. and Kirkpatrick, C. I. F.: Nutritional megaloblastic anaemia associated with sickle cell states. *Blood* 14:535, 1959.
8. Girdwood, R. H.: The Megaloblastic anaemias. *Scot. Med. J.* 87:49, 1956.
9. Jonsson, U.: Nutritional megaloblastic anemia in sickle cell states and the relation of folic acid to blastic crises in haemolytic anemias. 7th Congr. Int. Soc. Haemat., Rome, p. 155.
10. Waugh, T. R.: Pernicious anemia in individual with familiar haemolytic jaundice. *Fol. Haematol.* 53:291, 1935.
11. Rubio, F. and Burgin, L.: Hemolytic disease complicated by pernicious anaemia. *Bull. Tufts-New England Med. Center* 3:77, 1957.
12. Hefferman, C. K. and Jaswon, N.: A case of paroxysmal nocturnal haemoglobinuria associated with secondary haemochromatosis, a lower nephron nephrosis, and a megaloblastic anaemia. *J. Clin. Path.* 8:211, 1955.
13. Crosby, W. H. and Sacks, H. J.: The coincidence of Mediterranean anaemia and pernicious anaemia in a young Sicilian. *Blood* 4:1267, 1959.
14. Haenel, in discussion of paper by Gasser, C.: Erythroblastopenie aigue dans les anemies hemolytiques. *Sang* 21: 237, 1950.
15. Jandl, J. H. and Greenberg, M. S.: Painful erythropoietic crises produced by "pharmacologic" doses of folic acid. *Clin. Res. Proc.* 6:194, 1958.
16. Baikie, A. G. and Pirrie, R.: Megaloblastic erythropoiesis in idiopathic acquired haemolytic anaemia. *Scot. Med. J.* 1:330, 1, 1956.
17. Grunwald, S.: Megaloblastic haemolytic anaemia. *Acta Med. Scand.* 138:101, 1950.
18. Fisher, J. A.: The cryptogenic acquired haemolytic anaemias. *Quart. J. Med.* 40:245, 1947.
19. Dacie, J. V.: *Practical Haematology.* London: Churchill, 1956.
20. Kay, A. W.: Effect of large doses of histamine on the gastric secretion of HCl for augmented histamine test. *Brit. Med. J.* 2:77, 1953.
21. Meynell, M. J., Cooke, W. T., Cox, E. V. and Gaddie, R.: Serum cyanocobalamin level in chronic intestinal disorders. *Lancet* 1:901, 1957.
22. Mollison, P. L. and Veall, N.: The use of the isotope ^{51}Cr as a label for red cells. *Brit. J. Haemat.* 1:62, 1955.
23. Jones, N. C., Hughes and Szur, L.: Determination of the sites of red-cell destruction using ^{51}Cr -labelled cells. *Brit. J. Haemat.* 3:320, 1957.
24. Thannhauser, S. J. and Andersen, E.: Bilirubin in blood serum. *Deutsches Arch. f. klin. Med.* 137:179, 1921.
25. Archer, H. E. and Robb, G. D.: The tolerance of the body for urea in health and disease. *Quart. J. Med.* 18: 274, 1925.
26. Weichselbaum, T. E.: Accurate and rapid method for determination of proteins in small amounts of blood serum and plasma. *Amer. J. Clin. Path., Tech. Sect.* 7:40, 1946.
27. van de Kamer, J. H., ten Bokkel Huinink, H. and Weyers, H. A.: Rapid method for the determination of fat in feces. *J. Biol. Chem.* 177:347, 1949.
28. Davidson, L. S. P.: Clinical picture of pernicious anaemia prior to introduction of liver therapy in 1926 and in Edinburgh subsequent to 1944. *Brit. Med. J.* 1:241, 1957.
29. Sturgis, C. C. and Isaacs, R.: *Handbook of Haematology*, ed. H. Downey. Vol. 3, p. 223, 1938.
30. Cooke, W. T.: Unusual reticulocytosis in an untreated case of pernicious anaemia. *Brit. Med. J.* 2:806, 1941.
31. Whitby, L. E. H. and Britton, C. J. C.: *Disorders of the Blood.* London, Churchill, 1957, p. 231.
32. Weiner, W.: Editorial: To Be or Not 'To Be an Antibody: The "Agent" in Autoimmune Hemolytic Anemia. *Blood* 14:1057.
33. Mollin, D. L. and Ross, G. I. M.: Vitamin B_{12} deficiency in the megaloblastic anaemias. *Proc. Roy. Soc. Med.* 47:428, 1954.
34. Spray, G. H. and Witts, L. J.: The utilisation of folic acid in anaemia and leukaemia. *Clin. Sci.* 12:385, 1953.