

Helicobacter pylori Eradication Prevents Progression of Gastric Cancer in Hypergastrinemic INS-GAS Mice

Chung-Wei Lee,^{1,2} Barry Rickman,¹ Arlin B. Rogers,¹ Zhongming Ge,¹ Timothy C. Wang,³ and James G. Fox^{1,2}

¹Division of Comparative Medicine and ²Department of Biological Engineering, Massachusetts Institute of Technology, Cambridge, Massachusetts and ³Division of Digestive and Liver Disease, Department of Medicine, Columbia University, New York, New York

Abstract

***Helicobacter pylori* infection results in chronic gastritis, which may progress to gastric cancer. In this study, we investigated the efficacy of *H. pylori* eradication in preventing the progression of gastritis to gastric cancer in *H. pylori*-infected transgenic INS-GAS mice. *H. pylori* infection induced severe dysplasia and gastric cancer classified as high-grade and low-grade gastrointestinal intraepithelial neoplasia (GIN) in INS-GAS mice at 28 weeks postinfection (WPI). *H. pylori* eradication therapy using omeprazole, metronidazole, and clarithromycin was administered p.o. at 8, 12, or 22 WPI. Compared with untreated infected mice, *H. pylori* eradication at 8, 12, and 22 WPI significantly reduced the severity of dysplasia ($P < 0.01$). Moreover, *H. pylori* eradication at 8 WPI completely prevented the development of GIN ($P < 0.001$). Although not as effective as early antimicrobial treatment, prevention of progression to high-grade GIN was achieved by *H. pylori* eradication at 12 and 22 WPI ($P < 0.05$). Consistent with reduced gastric pathology, *H. pylori* eradication at all time points significantly down-regulated gastric Interferon- γ , tumor necrosis factor- α , inducible nitric oxide synthase, and Reg 1 mRNA levels ($P < 0.05$) and reduced epithelial proliferation in the corpus ($P < 0.01$) compared with untreated infected mice. We concluded that *H. pylori* eradication prevented gastric cancer to the greatest extent when antibiotics are given at an early point of infection, but that eradication therapy given at a later time point delayed the development of severe dysplastic lesions. [Cancer Res 2008;68(9):3540–8]**

Introduction

Helicobacter pylori was first identified in the antrum of patients with active chronic gastritis and peptic ulcers (1). *H. pylori* is now recognized as the major cause of gastric cancer and has been classified as a group I carcinogen by WHO (2, 3). *H. pylori* infection causes persistent chronic gastritis, which in susceptible individuals may progress to atrophy, intestinal metaplasia, dysplasia, and finally, intestinal-type gastric cancer (3, 4). Therefore, *H. pylori* eradication should, in theory, prevent the development of *H. pylori*-associated gastric diseases. Eradication of *H. pylori* in humans has been associated with prevention or regression of preneoplastic lesions including atrophic gastritis and intestinal metaplasia (5–9). The effectiveness of *H. pylori* eradication in

preventing the development of gastric cancer remains controversial. Antibiotic treatment during knee or hip replacement surgery reduced the incidence of gastric cancer in these patients during the postoperative period, probably due to eradication of *H. pylori* (10, 11). The optimal effect of antibiotic eradication therapy in preventing gastric cancer has been observed in *H. pylori*-infected patients who did not have precancerous gastric lesions before *H. pylori* eradication therapy (12). However, in other studies, *H. pylori* eradication did not reduce the overall prevalence of dysplasia or gastric cancer (6, 9, 12, 13). Because it typically requires several decades for gastric cancer to develop in susceptible hosts acquiring *H. pylori* infection at an early age (4), *H. pylori* eradication trials continue to raise key questions about which patients would benefit from *H. pylori* eradication and at what stage of gastric disease would *H. pylori* antimicrobial eradication prevent the progression to gastric cancer.

Several animal models have been used to examine whether *H. pylori* eradication is effective in the reversal of preneoplastic lesions and in preventing the progression of these preneoplastic lesions to gastric cancer. Antibiotic eradication therapy reversed the histologic progression of dysplasia in *H. pylori*-infected Mongolian gerbils (14). In *Helicobacter felis*-infected C57BL/6 mice that developed gastric cancer within 16 months postinfection, gastric cancer was completely prevented by *H. felis* antimicrobial eradication therapy given within the first 6 months of infection. In contrast, antibiotics given to *H. felis*-infected mice at 12 months postinfection did not arrest progression of dysplasia but reduced the incidence of invasive gastric cancer (15).

Recent studies suggest an association between hypergastrinemia, *Helicobacter* infection, and gastric cancer in humans and mice (16–19). In the absence of *Helicobacter* infection, transgenic INS-GAS mice that overexpress amidated gastrin have elevated gastric acid secretion and an increased parietal cell number at 1 to 3 months of age. With increasing age, these INS-GAS mice lose parietal cell mass and develop hypochlorhydria, gastric atrophy, metaplasia, and dysplasia. At 20 months of age, INS-GAS mice spontaneously develop invasive gastric cancer (18, 20). The development of gastric cancer is accelerated by gastric *Helicobacter* spp. infection, and lesion severity is more profound in male INS-GAS mice (16, 18, 19, 21). The purpose of this study was to examine the effect of *H. pylori* eradication at different stages of progression from gastritis to gastric cancer in INS-GAS male mice.

Materials and Methods

Mice. The animal protocol was reviewed and approved by the Massachusetts Institute of Technology Committee on Animal Care. Specific pathogen-free (including *Helicobacter* spp.) male INS-GAS mice on a FVB/N background were used in this study (20). Mice were maintained in a facility accredited by the Association for Assessment and Accreditation of

Requests for reprints: James G. Fox, Division of Comparative Medicine, Massachusetts Institute of Technology, #16-825, 77 Massachusetts Avenue, Cambridge, MA 02139. Phone: 617-253-1757; Fax: 617-258-5708; Email:jgfox@mit.edu.
©2008 American Association for Cancer Research.
doi:10.1158/0008-5472.CAN-07-6786

Laboratory Animal Care International and housed on hard wood bedding in microisolator, solid-bottomed polycarbonate cages, and given a commercial rodent diet (Prolab RMH 3000, PMI Nutrition International) and water *ad libitum*.

Experimental design. Fifty-four 6- to 8-wk-old male mice were infected by oral gavage with 0.2 mL of *H. pylori* SS1 on alternate days for a total of three doses (22, 23). The *H. pylori* inoculum for oral gavage was adjusted with PBS to an absorbance of 1.0 at 600 nm (approximate dose of 10^9 colony-forming units/mL; ref. 23). *Helicobacter*-uninfected mice were sham dosed with 0.2 mL of PBS. Infected mice were dosed p.o. with omeprazole (400 μ mol/kg/d; Sigma-Aldrich), metronidazole (14.2 mg/kg/d; Sigma-Aldrich), and clarithromycin (7.15 mg/kg/d; gift from Chugai Pharmaceutical Co.) in a 0.2-mL volume twice a day for 7 d (24). This antimicrobial regimen previously showed 100% eradication of *H. pylori* in infected C57BL/6 mice (24). Treatment was administered at 8, 12, or 22 weeks post *H. pylori* infection (WPI). Mice were euthanized at 28 WPI.

Tissue collection and histologic analysis. Following CO₂ asphyxiation, blood was immediately collected by cardiac puncture. The stomach and proximal duodenum were removed and the stomach incised along the greater curvature. Linear gastric strips from the lesser curvature were fixed overnight in 10% neutral-buffered formalin, embedded, cut to 4- μ m thickness, and stained with H&E. Tissue sections were scored for gastric lesions using previously published criteria by veterinary pathologists (B.R. and A.B.R.) blinded to sample identity (25). A dysplasia score of 3.0 was considered carcinoma *in situ* or low-grade gastrointestinal intraepithelial neoplasia (GIN). In addition, dysplasia scores ≥ 3.5 represented intramucosal carcinoma or herniated, high-grade GIN (26). Both low-grade and high-grade GIN in mouse stomachs were diagnosed as gastric cancer. Ki67 immunostaining (BD Biosciences) was used to measure epithelial proliferation of gastric mucosa. The ratio of Ki67-positive to total epithelial nuclei in glands occupying the full length of the proximal corpus was quantified manually for the Ki67 labeling index (LI), and results were averaged from three to four mice in each group. The remainder of the gastric tissue was snap-frozen in liquid nitrogen and stored at -70°C for DNA and RNA analyses.

Confirmation of *H. pylori* eradication by quantitative PCR. A longitudinal strip of gastric tissue from the greater curvature was digested with proteinase K at 55°C overnight, followed by DNA extraction with phenol/chloroform/isoamyl alcohol (25:24:1) and ethanol precipitation. *H. pylori* colonization levels in gastric tissue were quantified by a fluorogenic quantitative PCR assay with urease B primers (27). The genomic copies of *H. pylori* were normalized to microgram of murine genomic DNA as determined by quantitative PCR with a eukaryotic 18S endogenous control (User Bulletin #2, Applied Biosystems). Any sample detecting <10 copies of the *H. pylori* genome was considered negative for *H. pylori* colonization.

Quantitative analysis of mRNA expression. A longitudinal strip of gastric tissue from the anterior wall was harvested and snap-frozen in liquid nitrogen. Total RNA was extracted with Trizol reagent (Invitrogen). cDNA was synthesized from 5 μ g of total RNA with High Capacity cDNA Archive kit (Applied Biosystems). *IFN- γ* and tumor necrosis factor- α (*TNF- α*) mRNA levels were quantified with SYBR Green PCR reagent (Qiagen) using primers for *IFN- γ* [CATGGCTGTTTCTGGCTGTTACTG (F) and GTTGCTGATGGCTGATTGTCTTT (R), annealing at 56°C] and *TNF- α* [CATCTTCTCAAATTCGAGTGACAA (F) and TGGGAGTAGACAAGGTACAACC (R), annealing at 60°C]. The final concentration of each primer was 0.3 μ mol/L. Inducible nitric oxide synthase (*iNOS*; Applied Biosystems, Mm00440485_m1), regenerating gene 1 (*Reg 1*; Applied Biosystems, Mm00485651_m1), and glyceraldehyde-3-phosphate dehydrogenase (*GAPDH*; Applied Biosystems) mRNA levels were quantified with TaqMan gene expression assays (Applied Biosystems) in an ABI Prism Sequence Detection System 7700. mRNA levels of each cytokine were normalized to the mRNA level of internal control *GAPDH* and compared with the data of uninfected mice using the $\Delta\Delta\text{C}_T$ method (User Bulletin #2, Applied Biosystems).

Serum *H. pylori*-specific antibodies. Sera collected at necropsy were evaluated for *H. pylori*-specific, Th2-associated IgG1 and Th1-associated IgG2a by ELISA using an outer membrane protein preparation from *H.*

pylori (SS1 strain) as previously described (28). In brief, 96-well flat-bottomed plates were coated with 100 μ L of antigen (10 μ g/mL) overnight at 4°C ; sera were diluted to a ratio of 1:100 and added to the wells. Biotinylated secondary goat anti-mouse antibodies, clones A85-1 and 5.7 (BD PharMingen, San Jose, CA), were used for detecting IgG1 and IgG2a, respectively. Incubation with extravidin peroxidase (Sigma-Aldrich) was followed by treatment with 2,2'-azinobis(3-ethylbenzthiazolinesulfonic acid) substrate (Kirkegaard & Perry Laboratories) for color development. The absorbance was recorded at A_{405} and A_{595} with a plate reader per manufacturer's protocol (Power WaveX Select, Bio-Tek Instruments).

Statistical analysis. Gastric lesion scores and Ki67 LI for proliferation indices were compared by the Mann-Whitney *U* test. Expression levels of cytokines, *iNOS*, *Reg 1*, and IgG titers were compared using Student's *t* test. Incidences of low-grade and high-grade GIN in the treatment groups were compared with controls by Fisher's exact *t* test. Statistical analysis was done using a commercial software (GraphPad Prism 4.0, GraphPad Software, Inc.) with significance at $P < 0.05$.

Results

Confirmation of *H. pylori* eradication in INS-GAS mice that received antimicrobial therapy. To assess the effect of *H. pylori* eradication on progression of gastric cancer in INS-GAS mice, antimicrobial therapy using the combination of omeprazole, metronidazole, and clarithromycin was administered p.o. to mice at 8, 12, or 22 WPI. Quantitative PCR indicated that *H. pylori* was successfully eradicated in all mice (100%) treated at 8 or 12 weeks postinfection (WPI). In 12 of 14 (85.7%) animals treated at 22 WPI, *H. pylori* was successfully eradicated (Fig. 1). Only mice in which *H. pylori* eradication was successful were used for further analysis.

***H. pylori* infection promoted the development of premalignant lesions and gastric cancer in INS-GAS mice.** *Helicobacter* infection promotes gastric carcinogenesis in INS-GAS mice, particularly in males (18, 19). As previously noted (19), uninfected INS-GAS mice at 28 to 34 weeks of age developed progressive gastric lesions including atrophy, epithelial defects, and dysplasia, accompanied with minimal inflammation, severe hyperplasia, and intestinal metaplasia (Fig. 1; Table 1). Corpus hypertrophy was observed at necropsy as thickened mucosal folds in *H. pylori*-infected INS-GAS mice at 22 and 28 WPI. *H. pylori*-infected INS-GAS mice developed chronic atrophic gastritis with profound changes in mucosal architecture, restricted mainly to the corpus and characterized by loss of parietal and chief cells (Fig. 1). Compared with age-matched uninfected mice, infected INS-GAS mice had more severe inflammation ($P < 0.001$), oxyntic atrophy ($P < 0.05$), hyperplasia ($P < 0.05$), epithelial defects ($P < 0.001$), intestinal metaplasia ($P < 0.05$), and dysplasia ($P < 0.001$) at 22 WPI, and higher degrees of inflammation ($P < 0.001$), dysplasia ($P < 0.001$), and hyperplasia ($P < 0.01$) at 28 WPI (Fig. 2; Table 1). Compared with infected mice at 22 WPI, infected mice at 28 WPI had more severe dysplasia and atrophy ($P < 0.05$).

***H. pylori* eradication at 8 WPI significantly reduced gastritis and premalignant lesions.** *H. pylori*-infected INS-GAS mice received antimicrobial eradication therapy at 8, 12, or 22 WPI and were euthanized at 28 WPI. Infected mice that received *H. pylori* antimicrobial eradication therapy at 8 WPI had gastric architecture indistinguishable from that of uninfected age-matched mice (Fig. 1). Compared with untreated *H. pylori*-infected INS-GAS mice, *H. pylori* antimicrobial eradication therapy at 8 WPI inhibited the development of corpus dysplasia, inflammation, atrophy, hyperplasia, epithelial defects (all $P < 0.001$), and intestinal metaplasia ($P < 0.05$; Fig. 2A). Additionally, these mice exhibited less severe corpus inflammation, atrophy, and epithelial defects

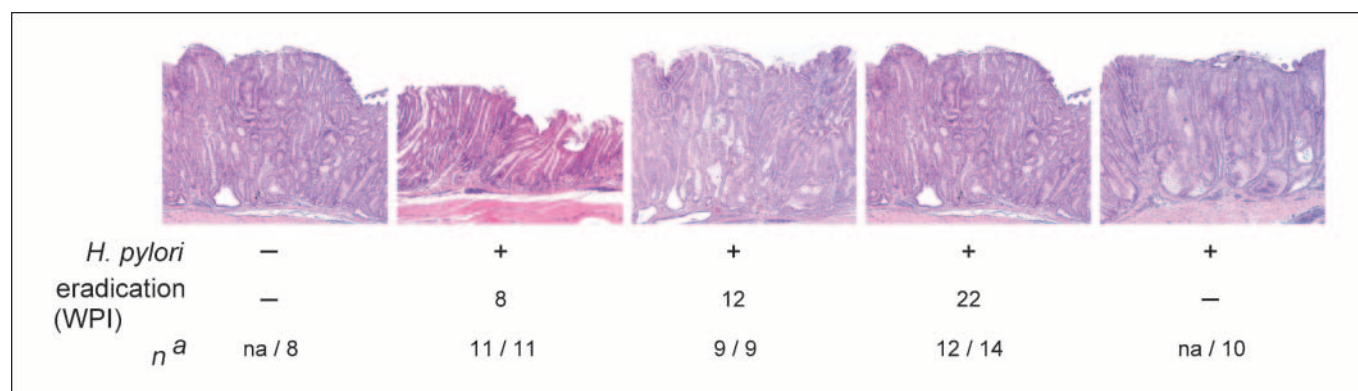


Figure 1. Histopathology of gastric disease induced by *H. pylori* infection in the corpus mucosa of INS-GAS mice with and without eradication therapy. Representative H&E-stained sections of stomachs from *H. pylori*-uninfected INS-GAS mice; infected mice receiving eradication therapy at 8, 12, or 22 WPI; and untreated infected mice. Uninfected mouse stomach showing typical INS-GAS background lesions of mild to moderate dysplasia, mild inflammation, severe atrophy, and mild to moderate hyperplasia on H&E stain. Tissue from a treated INS-GAS mouse 8 WPI, exhibiting mild to moderate dysplasia, mild inflammation, moderate to severe atrophy, and mild to moderate hyperplasia on H&E stain. Tissue from a treated INS-GAS mouse 12 WPI, exhibiting moderate dysplasia, moderate inflammation, severe atrophy, and moderate hyperplasia on H&E stain. Tissue from a treated INS-GAS mouse 22 WPI, exhibiting moderate dysplasia, mild to moderate inflammation, severe atrophy, and moderate hyperplasia on H&E stain. Tissue from an untreated INS-GAS mouse 22 WPI, exhibiting severe dysplasia, moderate inflammation, severe atrophy, and moderate to severe hyperplasia on H&E stain. *n*, numbers of mice with successful *H. pylori* eradication per group size.

than did the uninfected mice ($P < 0.05$, $P < 0.01$, and $P < 0.01$, respectively; Fig. 2A).

Microscopically, *H. pylori*-infected INS-GAS mice that received *H. pylori* antimicrobial eradication therapy at 12 WPI and were euthanized 16 weeks later had distorted mucosal architecture with dilated glands and glandular dysplasia (Fig. 1). Compared with untreated *H. pylori*-infected INS-GAS mice, infected INS-GAS mice that received *H. pylori* antimicrobial eradication therapy at 12 WPI had statistically less severe dysplasia, inflammation, and intestinal metaplasia ($P < 0.01$, $P < 0.05$, and $P < 0.05$, respectively), but both groups had similar degrees of atrophy, hyperplasia, and epithelial defects (Fig. 2A). Compared with uninfected mice, infected INS-GAS mice that received *H. pylori* antimicrobial eradication therapy at 12 WPI had more severe dysplasia and inflammation ($P < 0.001$) but comparable atrophy, hyperplasia, epithelial defects, and intestinal metaplasia.

H. pylori-infected INS-GAS mice that received *H. pylori* antimicrobial eradication at 22 WPI and were euthanized 6 weeks

later had thickened mucosal folds and developed corpus hyperplasia and dysplasia (Fig. 1). Microscopically, these mice developed statistically less severe dysplasia, inflammation, atrophy, and epithelial defects compared with untreated *H. pylori*-infected INS-GAS mice ($P < 0.01$; Fig. 2A). Compared with uninfected mice, infected INS-GAS mice that received *H. pylori* antimicrobial eradication therapy at 22 WPI had more severe dysplasia, hyperplasia, and epithelial defects ($P < 0.05$). Additionally, it is important to note that the two mice in which *H. pylori* was not eradicated developed low-grade or high-grade GIN (data not shown).

Among the infected INS-GAS mice that received *H. pylori* antimicrobial eradication therapy, mice receiving antimicrobial therapy at 8 WPI had significantly lower scores of dysplasia, inflammation, atrophy, and hyperplasia compared with mice receiving antimicrobial therapy at 12 or 22 WPI ($P \leq 0.05$), and had less severe epithelial defects compared with mice receiving antimicrobial therapy at 12 WPI ($P < 0.001$). Most gastric lesions

Table 1. Gastric lesions at 22 and 28 WPI

Weeks*	<i>H. pylori</i>	Lesion indices, median (range)						
		N	D	I	A	H	ED	IM
22	—	9	1.5 (1.5–2) ^{†,‡}	1 (0.5–2) [‡]	2.5 (1.5–3) ^{†,§}	2 (1.5–3) [§]	2 (1.5–2.5) ^{†,‡}	3 (2–3) [§]
22	+	10	3 (2.5–3.5) ^{†,}	2.5 (2–2.5) [‡]	3 (3) ^{§,}	3 (2–3) [§]	3 (3) [‡]	3.5 (3–3.5) [§]
28	—	8	2 (1.5–2.5) ^{†,¶}	1 (1–1.5) [¶]	3 (3–3.5) [†]	2.25 (1.5–3) ^{**}	2.75 (2.5–3) [†]	3 (3–3.5)
28	+	10	3.5 (3–3.5) ^{¶,}	2.25 (2–2.5) [¶]	3.5 (3.5)	3 (3–3.5) ^{**}	3 (3)	3.5 (3–3.5)

Abbreviations: D, dysplasia; I, inflammation; A, atrophy; H, hyperplasia; ED, epithelial defects; IM, intestinal metaplasia.

*Equivalent to WPI.

†Significant difference between 22 and 28 WPI in uninfected mice, $P < 0.05$.

‡Significant difference between uninfected and infected mice at 22 WPI, $P < 0.001$.

§Significant difference between uninfected and infected mice at 22 WPI, $P < 0.05$.

||Significant difference between 22 and 28 WPI in infected mice, $P < 0.05$.

¶Significant difference between uninfected and infected mice at 28 WPI, $P < 0.001$.

**Significant difference between uninfected and infected mice at 28 WPI, $P < 0.01$.

were comparable in infected mice that received eradication therapy at 12 or 22 WPI, except for epithelial defects that were more severe in the 12 WPI group ($P < 0.01$).

***H. pylori* eradication at 8 WPI prevented progression to low-grade and high-grade gastrointestinal intraepithelial neoplasia.** None of the uninfected INS-GAS mice between 34 to 36 weeks of age developed GIN. In contrast, all untreated *H. pylori*-infected INS-GAS mice ($n = 10$) at 28 WPI (34–36 weeks old) developed gastric cancer: 2 (20%) with low-grade GIN and 8 (80%) with high-grade GIN (Fig. 2B). In the *H. pylori*-infected mice that received antimicrobial eradication therapy at 8 WPI ($n = 11$), 10 (91%) of them did not have GIN and 1 (9%) had low-grade GIN. In the infected mice that received antimicrobial eradication therapy at 12 WPI ($n = 9$), 1 (11%) did not have GIN, 7 (78%) had low-grade GIN, and 1 (11%) had high-grade GIN. Six of the 12 (50%) infected mice that received antimicrobial

eradication therapy at 22 WPI did not have GIN, and the remainder (50%) had low-grade GIN.

Compared with uninfected mice, *H. pylori*-infected mice that received antimicrobial eradication therapy at 8 WPI had a similar incidence of GIN ($P = 0.38$). In contrast, infected mice that received antimicrobial eradication therapy at 12 or 22 WPI and untreated *H. pylori*-infected mice had a higher incidence of low-grade and high-grade GIN ($P < 0.05$) when compared with uninfected mice. Compared with *H. pylori*-infected INS-GAS mice that did not receive eradication therapy, the incidences of low-grade and high-grade GIN were statistically lower in infected mice receiving antimicrobial eradication therapy at 8, 12, or 22 WPI ($P \leq 0.05$). Among the infected mice receiving antimicrobial eradication therapy, therapy at 8 WPI resulted in the lowest incidences of GIN compared with eradication therapy at 12 or 22 WPI ($P < 0.05$). The incidences of low-grade and high-grade GIN were statistically

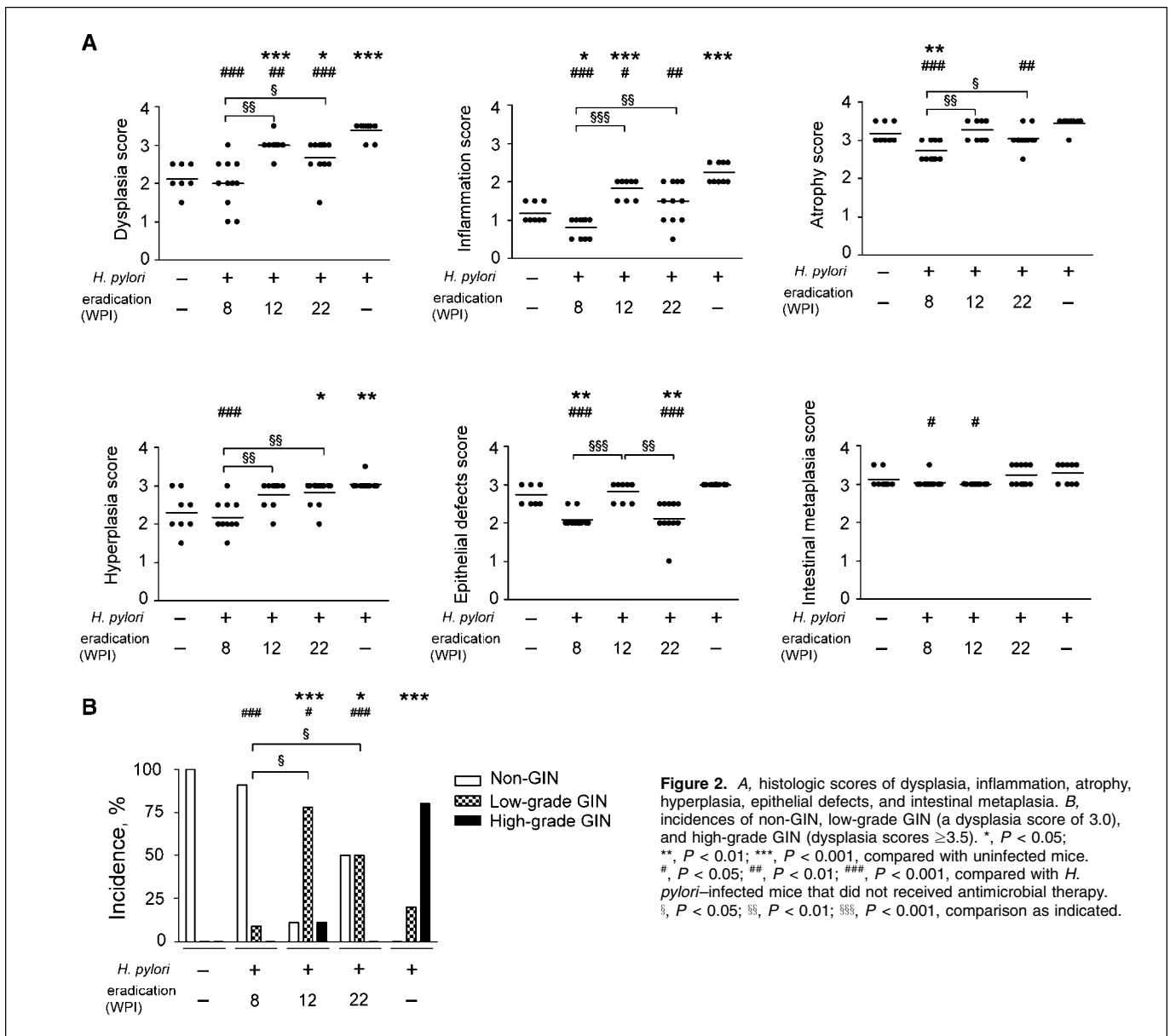


Figure 2. A, histologic scores of dysplasia, inflammation, atrophy, hyperplasia, epithelial defects, and intestinal metaplasia. B, incidences of non-GIN, low-grade GIN (a dysplasia score of 3.0), and high-grade GIN (dysplasia scores ≥ 3.5). *, $P < 0.05$; **, $P < 0.01$; ***, $P < 0.001$, compared with uninfected mice. #, $P < 0.05$; ##, $P < 0.01$; ###, $P < 0.001$, compared with *H. pylori*-infected mice that did not receive antimicrobial therapy. §, $P < 0.05$; §§, $P < 0.01$; §§§, $P < 0.001$, comparison as indicated.

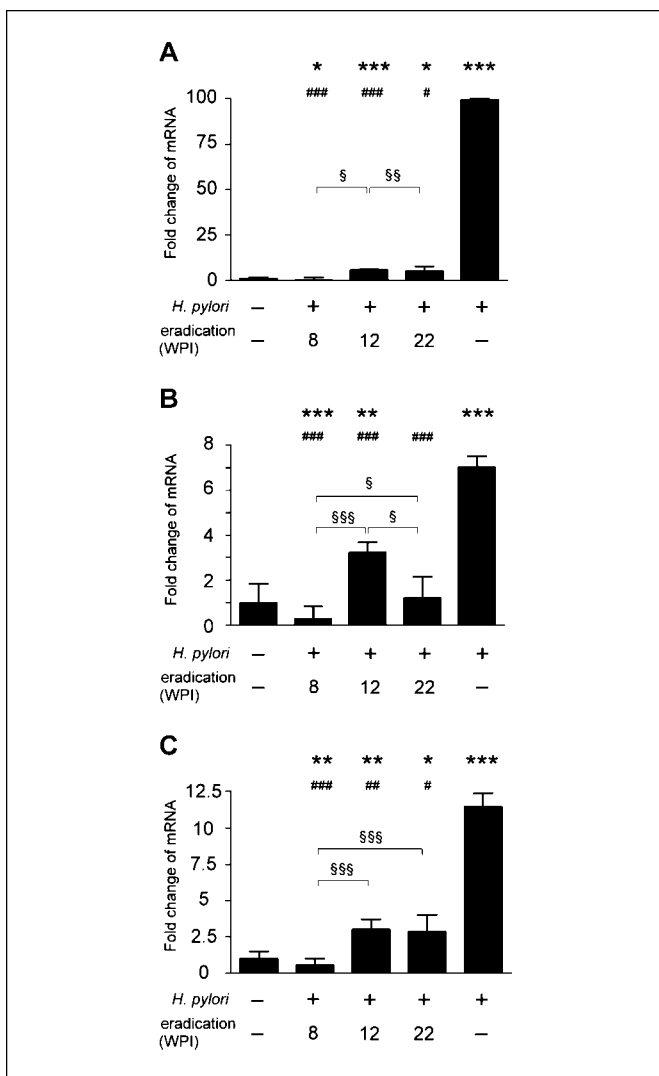


Figure 3. Relative mRNA levels of *IFN- γ* (A), *TNF- α* (B), and *iNOS* (C) in the gastric tissue. Data are presented as fold change relative to uninfected INS-GAS mice. *H. pylori*-infected mice without eradication therapy had significantly higher levels of *IFN- γ* , *TNF- α* , and *iNOS* mRNA ($P < 0.001$). *H. pylori* eradication at 8 WPI had statistically lower *IFN- γ* , *TNF- α* , and *iNOS* mRNA levels compared with uninfected mice and infected mice without eradication therapy. *H. pylori* eradication at 12 or 22 WPI had *IFN- γ* , *TNF- α* , and *iNOS* mRNA levels that were significantly higher than those in uninfected mice but lower than those in infected control mice that did not receive eradication therapy. *, $P < 0.05$; **, $P < 0.01$; ***, $P < 0.001$, compared with uninfected mice. #, $P < 0.05$; ##, $P < 0.01$; ###, $P < 0.001$, compared with uninfected mice that did not receive antimicrobial eradication. §, $P < 0.05$; §§, $P < 0.01$; §§§, $P < 0.001$, comparison as indicated.

similar between infected mice receiving eradication therapy at 12 and 22 WPI ($P = 0.12$).

Antimicrobial eradication therapy was associated with decreased gastric *IFN- γ* , *TNF- α* , and *iNOS* mRNA levels compared with untreated infected mice. Given the importance of the inflammatory response in the pathogenesis of *H. pylori* gastritis, we analyzed selected proinflammatory cytokines and *iNOS* mRNA levels in the gastric tissue at 28 WPI. Compared with uninfected mice, gastric *IFN- γ* mRNA levels were up-regulated in untreated *H. pylori*-infected INS-GAS mice ($P < 0.001$; Fig. 3A). *H. pylori*-infected mice that received *H. pylori* antimicrobial therapy at 12 and 22 WPI also had up-regulated gastric *IFN- γ* mRNA levels compared with uninfected mice ($P < 0.001$ and $P < 0.05$, respectively).

Interestingly, gastric *IFN- γ* mRNA levels were lower in infected mice that received antimicrobial therapy at 8 WPI than in uninfected mice and in mice receiving eradication therapy at 12 or 22 WPI ($P < 0.05$). Compared with untreated *H. pylori*-infected mice, mRNA levels of *IFN- γ* were significantly reduced in infected mice receiving *H. pylori* antimicrobial eradication therapy at 8, 12, and 22 WPI ($P < 0.05$).

Compared with uninfected mice, gastric *TNF- α* mRNA levels were up-regulated in untreated *H. pylori*-infected INS-GAS mice ($P < 0.001$) and in infected mice that received *H. pylori* antimicrobial therapy at 12 WPI ($P < 0.01$; Fig. 3B). Infected mice that received *H. pylori* eradication therapy at 8 WPI had reduced gastric *TNF- α* mRNA levels ($P < 0.001$), whereas infected mice that received *H. pylori* eradication therapy at 22 WPI had similar gastric *TNF- α* mRNA levels ($P = 0.71$), relative to uninfected mice. Compared with untreated *H. pylori*-infected mice, gastric *TNF- α* mRNA levels were significantly reduced in all mice that received eradication therapy ($P < 0.001$). Among the infected mice receiving eradication therapy, infected mice that received antimicrobial eradication therapy at 8 WPI had significantly lower *TNF- α* mRNA levels compared with those mice that received antimicrobial eradication therapy at 12 or 22 WPI ($P < 0.001$ and $P < 0.05$). Infected mice that received antimicrobial eradication therapy at 12 WPI had higher *TNF- α* mRNA levels compared with mice that received antimicrobial eradication therapy at 22 WPI ($P < 0.05$).

Compared with uninfected mice, gastric *iNOS* mRNA levels were up-regulated in untreated *H. pylori*-infected INS-GAS mice ($P < 0.001$; Fig. 3C). Compared with untreated *H. pylori*-infected mice, gastric *iNOS* mRNA levels were significantly down-regulated by *H. pylori* antimicrobial eradication therapy at all time points ($P \leq 0.05$). Among the infected mice that received *H. pylori* antimicrobial eradication therapy, those receiving antimicrobial eradication therapy at 8 WPI had the lowest *iNOS* mRNA levels compared with mice receiving antimicrobial eradication therapy at 12 or 22 WPI ($P < 0.001$).

The magnitude of *H. pylori*-specific antibody responses was affected by *H. pylori* eradication. Compared with uninfected mice, *H. pylori*-specific, Th1-associated IgG2a levels were significantly elevated in all infected mice with or without *H. pylori* antimicrobial eradication therapy ($P < 0.01$; Fig. 4A). *H. pylori* antimicrobial eradication therapy at all time points had no significant effect on *H. pylori*-specific IgG2a levels compared with untreated *H. pylori*-infected mice. However, infected mice that received antimicrobial eradication therapy at 22 WPI had statistically higher *H. pylori*-specific IgG2a levels compared with those receiving antimicrobial eradication therapy at 8 or 12 WPI ($P < 0.05$ and $P < 0.01$, respectively). Compared with uninfected mice, *H. pylori*-specific, Th2-associated IgG1 responses were also elevated in infected mice receiving *H. pylori* antimicrobial eradication therapy at 12 and 22 WPI ($P < 0.05$ and $P = 0.06$, respectively) and in untreated infected mice ($P = 0.08$). Compared with untreated *H. pylori*-infected mice, *H. pylori*-specific IgG1 levels were reduced in mice that received antimicrobial eradication therapy at 8 WPI ($P < 0.01$), but were not affected by antimicrobial eradication therapy at 12 or 22 WPI ($P = 0.11$). *H. pylori*-specific IgG1 levels in mice that received antimicrobial eradication therapy at 8 WPI were also lower than those in mice that received antimicrobial eradication therapy at 12 or 22 WPI ($P < 0.01$ and $P < 0.05$, respectively).

Gastric *Reg 1* expression was reduced by *H. pylori* antimicrobial eradication therapy. *Reg 1*, a downstream growth factor of gastrin, modulates growth and differentiation

of gastric mucosa (29) and is up-regulated in *H. felis*-infected INS-GAS mice (30). To further investigate the possible mechanisms for the inhibitory effect of *H. pylori* antimicrobial eradication therapy on progression of gastric lesions, we analyzed gastric *Reg 1* mRNA levels. Compared with those in uninfected mice, gastric *Reg 1* mRNA levels were up-regulated in untreated *H. pylori*-infected INS-GAS mice ($P < 0.001$; Fig. 5A). Infected mice receiving antimicrobial eradication therapy at 8, 12, or 22 WPI had gastric *Reg 1* mRNA levels that were comparable with each other and with those of uninfected mice. Additionally, antimicrobial eradication therapy at all time points significantly reduced *Reg 1* expression compared with untreated, infected mice ($P < 0.01$).

Gastric mucosal cell proliferation was also reduced in all mice that received *H. pylori* antimicrobial eradication therapy. Epithelial proliferating cells detected by Ki67 immunohistologic staining were mainly in the isthmus regions of corpus mucosa in uninfected INS-GAS mice and *H. pylori*-infected mice that received eradication therapy at 12 WPI (Fig. 5B). Proliferating cells in the corpus expanded from isthmus regions to hypertrophic foveolar regions in untreated *H. pylori*-infected INS-GAS mice. Compared with uninfected mice, corpus epithelial proliferation, measured by Ki67 LIs, was comparable in infected mice that received *H. pylori* eradication at 8 WPI ($P = 0.093$), but was higher in infected mice that received *H. pylori* eradication at 12 or 22 WPI and in untreated *H. pylori*-infected mice ($P < 0.05$; Fig. 5C). *H. pylori* eradication at 8, 12, and 22 WPI significantly reduced Ki67 LI in the corpus compared with untreated *H. pylori*-infected mice ($P < 0.01$). Among the infected mice receiving *H. pylori* eradication therapy, mice receiving eradication therapy at 8 WPI had the lowest corpus epithelial LI when compared with mice receiving eradication therapy at 12 or 22 WPI ($P < 0.05$ and $P = 0.058$, respectively).

Discussion

In this study, we used the well-characterized INS-GAS male mouse model to elucidate the effect of *H. pylori* eradication therapy conducted at different stages of *H. pylori*-associated gastric pathology. *H. pylori*-infected INS-GAS mice developed GIN or gastric cancer at 28 WPI, accompanied by inflammation, loss of parietal and chief cells, and hypertrophy of foveolar glands. When *H. pylori* antimicrobial eradication therapy was instituted at 8 WPI, the risk of GIN was reduced to a comparable level of uninfected mice. Decreases in gastric inflammation, mRNA levels of proinflammatory cytokines and *Reg 1*, and epithelial cell proliferation in infected mice successfully treated with antimicrobials arguably contributed to lower dysplasia and reduced gastric cancer risk, particularly in those mice treated at 8 WPI. Eradication therapy at 12 and 22 WPI also resulted in a statistically lower degree of gastric inflammation, dysplasia, mRNA levels of proinflammatory cytokines and *Reg 1*, and epithelial cell proliferation and prevented progression to high-grade GIN, when compared with the data recorded in untreated *H. pylori*-infected mice. However, eradication therapy at 12 and 22 WPI did not reverse selected histopathologic changes, including inflammation, hyperplasia, and dysplasia, to the levels of uninfected mice. Nevertheless, it is also possible that the protective effect of *H. pylori* eradication at 12 or 22 WPI in INS-GAS mice may not be seen at 28 WPI. A longer period of time after *H. pylori* eradication therapy may be required in INS-GAS mice to observe the benefit of treatment during the late stages of *H. pylori* infection. These data in aggregate indicate that

antimicrobial eradication therapy attenuated progression of *H. pylori*-induced gastric cancer, with early intervention providing the maximum benefit.

In comparable rodent studies, antimicrobial eradication therapy at 50 or 75 WPI prevented dysplasia in *H. pylori*-infected Mongolian gerbils (14). *H. felis*-infected C57BL/6 mice developed gastritis and invasive gastric cancer at 16 months postinfection (15). These lesions could be prevented and mucosal architecture restored if *H. felis* eradication therapy was instituted within 6 months of infection (15). Although *H. felis* eradication therapy at 12 months postinfection reduced the incidence of gastric cancer, it had little effect on the reversal of dysplasia in the C57BL/6 model (15). Consistent with the *H. felis* C57BL/6 model, our data show that *H. pylori* eradication administered at the early stages of *H. pylori* infection attenuated gastric inflammation, restored gastric mucosal architecture, and prevented the development of gastric cancer in INS-GAS mice. Moreover, because mature parietal cells are necessary to maintain the integrity of gastric mucosa, parietal cell loss may have resulted in dysregulation of gastric stem cell homeostasis and migration-associated differentiation of pit and zymogenic cells (31). Independent studies from our laboratory confirmed parietal cell loss in uninfected INS-GAS mice after 5 months of age (approximately equivalent to 12–14 WPI in our current study; ref. 18). Parietal cell mass and epithelial cell

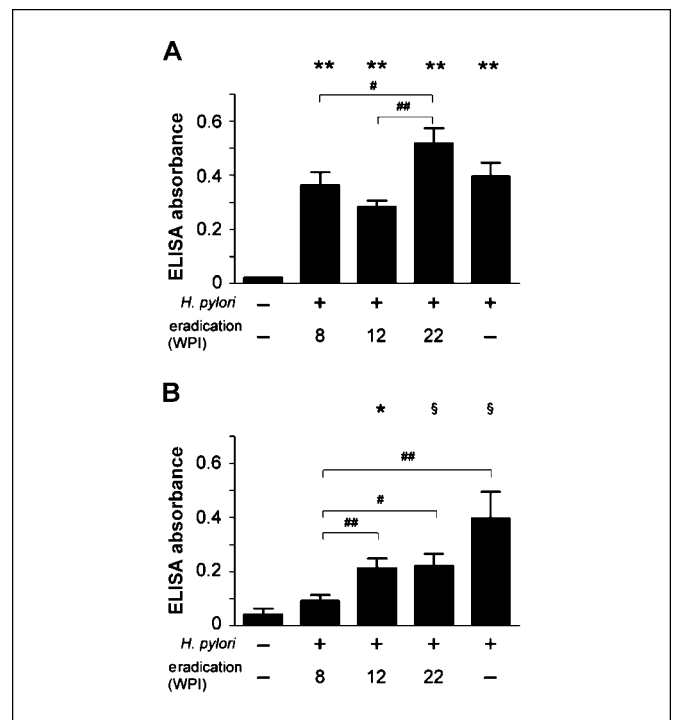


Figure 4. *H. pylori*-specific, Th1-associated IgG2a levels were significantly elevated in infected mice at 28 WPI irrespective of antimicrobial eradication when compared with uninfected controls (**, $P < 0.01$; A). *H. pylori* eradication did not significantly reduce serum levels of *H. pylori*-specific IgG2a. Compared with untreated *H. pylori*-infected mice, mice that received *H. pylori* eradication at 22 WPI had higher IgG2a responses, as well as mice that received *H. pylori* eradication at 8 or 12 WPI (#, $P < 0.05$; ##, $P < 0.01$). *H. pylori*-specific, Th2-associated IgG1 levels were elevated in infected mice that received *H. pylori* eradication at 12 or 22 WPI and in mice that were actively infected with *H. pylori* (*, $P < 0.05$; §, $0.05 < P < 0.10$, compared with uninfected mice; B). Infected mice receiving eradication therapy at 8 WPI had significantly lower *H. pylori*-specific IgG1 levels compared with infected mice given eradication therapy at 12 or 22 WPI (#, $P < 0.05$; ##, $P < 0.01$) and infected mice that did not receive eradication therapy ($P < 0.01$).

Downloaded from http://aacrjournals.org/cancerres/article-pdf/68/9/3540/2602702/3540.pdf by guest on 14 June 2024

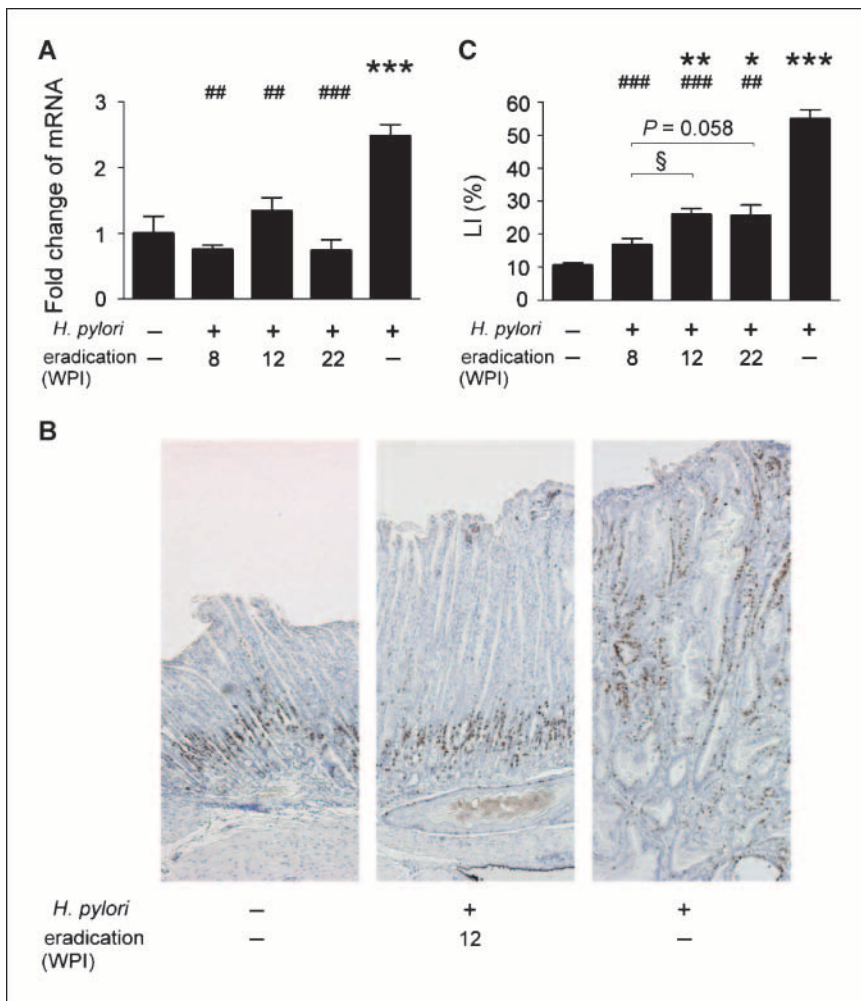


Figure 5. Relative mRNA levels of *Reg 1* in gastric tissue (A), immunohistochemical staining of Ki67 (B), and LIs of Ki67 (C) in the corpus. *Reg 1* data are presented as fold change relative to uninfected INS-GAS mice (A). *H. pylori*-infected mice without eradication therapy had significantly up-regulated *Reg 1* mRNA levels compared with uninfected mice. In contrast, infected mice that received *H. pylori* eradication therapy at all time points had similar *Reg 1* mRNA levels compared with uninfected mice. *H. pylori* eradication therapy at all time points significantly down-regulated *Reg 1* mRNA levels relative to infected mice that did not receive *H. pylori* eradication therapy. There were no different *Reg 1* mRNA levels among infected mice that received *H. pylori* eradication at 8, 12, or 22 WPI. Proliferating cells are positively stained for Ki67 (B). In *Helicobacter*-uninfected INS-GAS mice, proliferating cells were restricted to the isthmus regions irrespective of the hyperplastic foveolar glands in infected mice that received *H. pylori* eradication at 12 WPI. Proliferating cells expanded from isthmus regions to foveolar regions in infected INS-GAS mice that did not receive eradication therapy. Ki67 LIs were significantly increased in *H. pylori*-infected mice that received eradication therapy at 12 or 22 WPI and in untreated infected mice compared with uninfected mice (C). *H. pylori* eradication at 8, 12, and 22 WPI significantly reduced corpus LI compared with infected mice without eradication therapy. Additionally, infected mice receiving *H. pylori* eradication at 8 WPI had lower corpus LI compared with infected mice receiving eradication therapy at 12 WPI. *, $P < 0.05$; **, $P < 0.01$; ***, $P < 0.001$, compared with uninfected mice. ##, $P < 0.01$; ###, $P < 0.001$, compared with *H. pylori*-infected mice that did not receive antimicrobial therapy. §, $P < 0.05$, comparison as indicated.

differentiation in *H. pylori*-infected INS-GAS mice may be partially restored and onset of precancerous lesions may be delayed by *H. pylori* eradication therapy given at 8 WPI, but not by antimicrobial therapy given at 12 WPI or later.

Gastric inflammation in INS-GAS mice positively correlated with epithelial proliferation. Previous studies suggest that *IFN- γ* induces proliferation of gastric epithelial cells (32, 33). Increased cell proliferation is a biomarker of gastric cancer risk, and reversal to a normal epithelial proliferation has been associated with a reduced gastric cancer risk (34, 35). In the current study, gastric epithelial proliferation rates and *Reg 1* mRNA levels in *H. pylori*-infected INS-GAS mice receiving *H. pylori* eradication therapy at 8 WPI returned to levels similar to those of uninfected mice, but not those in mice receiving eradication treatment at 12 or 22 WPI. With accumulated genetic damage in gastric mucosa as a result of long-standing *H. pylori* infection, *H. pylori* infection per se may no longer be necessary for sustained dysplasia and progression to gastric cancer.

Unexpectedly, *H. pylori*-infected mice receiving eradication therapy at 8 WPI had significantly lower degrees of gastric inflammation as evidenced by less severe atrophy and down-regulated *IFN- γ* , *TNF- α* , and *iNOS* mRNA levels relative to the *H. pylori*-unrelated gastric inflammation in uninfected INS-GAS mice. The mechanism by which antimicrobial eradication therapy

exerted a protective effect on spontaneous gastric inflammation in INS-GAS mice is unknown. One possible explanation is that antimicrobial therapy eradicates not only *H. pylori* but also other microorganisms that could cause gastric inflammation, particularly when there is an elevated gastric pH (36, 37). Our laboratory observed that six of the eight bacterial species of altered Schaedler flora (37) were present in the stomach of *H. pylori*-infected INS-GAS mice.⁴ Experimental infection with *Acinetobacter lwoffii* in C57BL/6 mice also causes chronic gastritis as does *H. pylori* (38). Moreover, studies in humans and in various animal models have shown that bacteria are important in triggering inflammation and epithelial damage in the stomach (39), suggesting the potential interaction between *H. pylori* and other bacteria in the induction of gastric disease. In humans, a dynamic change of gastric microbiota has been observed in *H. pylori*-infected dyspeptic patients who received a triple antimicrobial therapy regimen with omeprazole, metronidazole, and clarithromycin. Certain species of bacteria were eradicated (e.g., *Fusobacterium* spp.) whereas some bacteria continued to colonize the stomach (e.g., *Haemophilus* spp. and *Neisseria* spp.;

⁴ C.W. Lee, Z. Ge, J.G. Fox, unpublished data.

ref. 40). These findings in humans and mice suggest that antibiotic treatment potentially changes gastric microbiota and may affect gastric carcinogenesis. Further experimentation is necessary to investigate the role of microbiota in *H. pylori*-associated gastric disease.

Several clinical trials have examined the efficacy of *H. pylori* eradication in preventing the development of preneoplastic gastric lesions and gastric cancer in humans (5–9, 12, 13, 41). Although a positive effect of *H. pylori* eradication therapy in preventing gastric cancer has been observed in infected patients who did not have preneoplastic lesions before *H. pylori* eradication therapy (12), most clinical trials have not noted an overall reduction of dysplasia or gastric cancer prevalence in patients receiving *H. pylori* eradication therapy (6, 9, 12, 13). Whether *H. pylori* eradication therapy reduces the prevalence of gastric cancer remains inconclusive from these studies. One possibility is that the incidence of gastric cancer is <50 per 100,000 even in countries with the highest prevalence of gastric cancer, making statistical influence in studies with smaller numbers of patients difficult (42). Additionally, the regression of preneoplastic gastric lesions following *H. pylori* eradication is positively correlated with the interval that the patient has been free of *H. pylori* infection (9). This suggests that significant improvement of gastric lesions and reduction of gastric cancer prevalence may not be observed during the first few years after

treatment (43). In subsequent studies, it will be necessary to recruit a larger population at risk for clinical trials with longer-term follow-up to validate the efficacy of *H. pylori* eradication in preventing gastric cancer.

In summary, the current study in *H. pylori*-infected INS-GAS mice supports the premise that *H. pylori* eradication therapy is the most beneficial in preventing gastric cancer when antibiotics are given at the early stages of *H. pylori* infection. When infected mice have already developed metaplasia and dysplasia, *H. pylori* eradication therapy substantially prevents progression to high-grade GIN but not to low-grade GIN. Our study using INS-GAS mice is consistent with the Maastricht III Consensus Report, which strongly recommends *H. pylori* eradication for the prevention of gastric cancer, especially in patients with gastric ulcer, atrophy, or family history of gastric cancer (44).

Acknowledgments

Received 12/20/2007; revised 2/19/2008; accepted 3/3/2008.

Grant support: NIH grants R01AI37750, P01CA26731, P30ES02109 (J.G. Fox), and R01 CA093405-07A1 (T.C. Wang and J.G. Fox).

The costs of publication of this article were defrayed in part by the payment of page charges. This article must therefore be hereby marked *advertisement* in accordance with 18 U.S.C. Section 1734 solely to indicate this fact.

We thank Koji Kashimura in Chugai Pharmaceutical Co. (Tokyo, Japan) for providing purified clarithromycin, Kristen Clapp and Juri Miyamae for technical assistance, and Kathy Cormier for her histology expertise.

References

- Marshall BJ, Warren JR. Unidentified curved bacilli in the stomach of patients with gastritis and peptic ulceration. *Lancet* 1984;1:1311–5.
- International Agency for Research on Cancer. Schistosomes, liver flukes, and *Helicobacter pylori*. IARC Monogr Eval Carcinog Risks Hum 1994;61:1–241.
- Fox JG, Wang TC. *Helicobacter pylori*—not a good bug after all! *N Engl J Med* 2001;345:829–32.
- Correa P. A human model of gastric carcinogenesis. *Cancer Res* 1988;48:3554–60.
- Ley C, Mohar A, Guarner J, et al. *Helicobacter pylori* eradication and gastric preneoplastic conditions: a randomized, double-blind, placebo-controlled trial. *Cancer Epidemiol Biomarkers Prev* 2004;13:4–10.
- You WC, Brown LM, Zhang L, et al. Randomized double-blind factorial trial of three treatments to reduce the prevalence of precancerous gastric lesions. *J Natl Cancer Inst* 2006;98:974–83.
- Ito M, Haruma K, Kamada T, et al. *Helicobacter pylori* eradication therapy improves atrophic gastritis and intestinal metaplasia: a 5-year prospective study of patients with atrophic gastritis. *Aliment Pharmacol Ther* 2002;16:1449–56.
- Correa P, Fontham ET, Bravo JC, et al. Chemoprevention of gastric dysplasia: randomized trial of antioxidant supplements and anti-*Helicobacter pylori* therapy. *J Natl Cancer Inst* 2000;92:1881–8.
- Mera R, Fontham ET, Bravo LE, et al. Long-term follow-up of patients treated for *Helicobacter pylori* infection. *Gut* 2005;54:1536–40.
- Nyren O, McLaughlin JK, Gridley G, et al. Cancer risk after hip replacement with metal implants: a population-based cohort study in Sweden. *J Natl Cancer Inst* 1995;87:28–33.
- Akre K, Signorello LB, Engstrand L, et al. Risk for gastric cancer after antibiotic prophylaxis in patients undergoing hip replacement. *Cancer Res* 2000;60:6376–80.
- Wong BC, Lam SK, Wong WM, et al. *Helicobacter pylori* eradication to prevent gastric cancer in a high-risk region of China: a randomized controlled trial. *JAMA* 2004;291:187–94.
- Leung WK, Lin SR, Ching JY, et al. Factors predicting progression of gastric intestinal metaplasia: results of a randomised trial on *Helicobacter pylori* eradication. *Gut* 2004;53:1244–9.
- Cao X, Tsukamoto T, Nozaki K, et al. Eradication of *Helicobacter pylori* induces apoptosis and inhibits proliferation of heterotopic proliferative glands in infected Mongolian gerbils. *Cancer Sci* 2004;95:872–7.
- Cai X, Carlson J, Stoicov C, Li H, Wang TC, Houghton J. *Helicobacter felis* eradication restores normal architecture and inhibits gastric cancer progression in C57BL/6 mice. *Gastroenterology* 2005;128:1937–52.
- Fox JG, Wang TC, Rogers AB, et al. Host and microbial constituents influence *Helicobacter pylori*-induced cancer in a murine model of hypergastrinemia. *Gastroenterology* 2003;124:1879–90.
- Konda Y, Kamimura H, Yokota H, Hayashi N, Sugano K, Takeuchi T. Gastrin stimulates the growth of gastric pit with less-differentiated features. *Am J Physiol* 1999;277:G773–84.
- Wang TC, Dangler CA, Chen D, et al. Synergistic interaction between hypergastrinemia and *Helicobacter* infection in a mouse model of gastric cancer. *Gastroenterology* 2000;118:36–47.
- Fox JG, Rogers AB, Ihrig M, et al. *Helicobacter pylori*-associated gastric cancer in INS-GAS mice is gender specific. *Cancer Res* 2003;63:942–50.
- Wang TC, Koh TJ, Varro A, et al. Processing and proliferative effects of human progastrin in transgenic mice. *J Clin Invest* 1996;98:1918–29.
- Ohtani M, Garcia A, Rogers AB, et al. Protective role of 17 β -estradiol against the development of *Helicobacter pylori*-induced gastric cancer in INS-GAS mice. *Carcinogenesis* 2007;28:2597–604.
- Lee A, O'Rourke J, De Ungria MC, Robertson B, Daskalopoulos G, Dixon MF. A standardized mouse model of *Helicobacter pylori* infection: introducing the Sydney strain. *Gastroenterology* 1997;112:1386–97.
- Lee CW, Rao VP, Rogers AB, et al. Wild-type and interleukin-10-deficient regulatory T cells reduce effector T-cell-mediated gastroduodenitis in Rag2^{-/-} mice, but only wild-type regulatory T cells suppress *Helicobacter pylori* gastritis. *Infect Immun* 2007;75:2699–707.
- van Zanten SJ, Kolesnikov T, Leung V, O'Rourke JL, Lee A. Gastric transitional zones, areas where *Helicobacter* treatment fails: results of a treatment trial using the Sydney strain mouse model. *Antimicrob Agents Chemother* 2003;47:2249–55.
- Rogers AB, Taylor NS, Whary MT, Stefanich ED, Wang TC, Fox JG. *Helicobacter pylori* but not high salt induces gastric intraepithelial neoplasia in B6129 mice. *Cancer Res* 2005;65:10709–15.
- Boivin GP, Washington K, Yang K, et al. Pathology of mouse models of intestinal cancer: consensus report and recommendations. *Gastroenterology* 2003;124:762–77.
- Maurer KJ, Rogers AB, Ge Z, Wiese AJ, Carey MC, Fox JG. *Helicobacter pylori* and cholesterol gallstone formation in C57L/J mice: a prospective study. *Am J Physiol Gastrointest Liver Physiol* 2006;290:G175–82.
- Ihrig M, Whary MT, Dangler CA, Fox JG. Gastric *Helicobacter* infection induces a Th2 phenotype but does not elevate serum cholesterol in mice lacking inducible nitric oxide synthase. *Infect Immun* 2005;73:1664–70.
- Fukui H, Kinoshita Y, Maekawa T, et al. Regenerating gene protein may mediate gastric mucosal proliferation induced by hypergastrinemia in rats. *Gastroenterology* 1998;115:1483–93.
- Takaishi S, Cui G, Frederick DM, et al. Synergistic inhibitory effects of gastrin and histamine receptor antagonists on *Helicobacter*-induced gastric cancer. *Gastroenterology* 2005;128:1965–83.
- Li Q, Karam SM, Gordon JL. Diphtheria toxin-mediated ablation of parietal cells in the stomach of transgenic mice. *J Biol Chem* 1996;271:3671–6.
- Kang W, Rathinavelu S, Samuelson LC, Merchant JL. Interferon γ induction of gastric mucous neck cell hypertrophy. *Lab Invest* 2005;85:702–15.
- Fox JG, Rogers AB, Whary MT, et al. Accelerated progression of gastritis to dysplasia in the pyloric antrum of TFF2/C57BL6 \times Sv129 *Helicobacter pylori*-infected mice. *Am J Pathol* 2007;171:1520–8.
- Biasco G, Paganelli GM, Miglioli M, Barbara L. Cell

- proliferation biomarkers in the gastrointestinal tract. *J Cell Biochem* 1992;16G:73–8.
35. Biasco G, Paganelli GM, Santucci R, Miglioli M, Barbara L. Cell proliferation kinetics as a marker of gastric cancer risk. *Ital J Gastroenterol* 1991;23:24–8.
36. Bik EM, Eckburg PB, Gill SR, et al. Molecular analysis of the bacterial microbiota in the human stomach. *Proc Natl Acad Sci U S A* 2006;103:732–7.
37. Sarma-Rupavtarm RB, Ge Z, Schauer DB, Fox JG, Polz MF. Spatial distribution and stability of the eight microbial species of the altered Schaedler flora in the mouse gastrointestinal tract. *Appl Environ Microbiol* 2004;70:2791–800.
38. Zavros Y, Rieder G, Ferguson A, Merchant JL. Gastritis and hypergastrinemia due to *Acinetobacter lwoffii* in mice. *Infect Immun* 2002;70:2630–9.
39. Fox JG, Wang TC. Inflammation, atrophy, and gastric cancer. *J Clin Invest* 2007;117:60–9.
40. Adamsson I, Nord CE, Lundquist P, Sjostedt S, Edlund C. Comparative effects of omeprazole, amoxicillin plus metronidazole versus omeprazole, clarithromycin plus metronidazole on the oral, gastric and intestinal microflora in *Helicobacter pylori*-infected patients. *J Antimicrob Chemother* 1999;44:629–40.
41. Sung J, Lin S, Ching J, et al. Atrophy and intestinal metaplasia one year after cure of *H. pylori* infection: a prospective, randomized study. *Gastroenterology* 2000;119:7–14.
42. International Agency for Research on Cancer. Cancer incidence in five continents. In: Parkin DM, Whelan SL, Ferlay J, Raymond L, Young J, editors. Vol. 7. Lyon: IARC Sci Publ; 1997.
43. Mera R, Fontham ET, Bravo LE, et al. Re: Randomized double-blind factorial trial of three treatments to reduce the prevalence of precancerous gastric lesions. *J Natl Cancer Inst* 2006;98:1426.
44. Malfertheiner P, Megraud F, O'Morain C, et al. Current concepts in the management of *Helicobacter pylori* infection: the Maastricht III Consensus Report. *Gut* 2007;56:772–81.