

Metabolic Function of Intraportal and Intrasplenic Islet Autografts in Cynomolgus Monkeys

ROBERT SUTTON, DEREK W.R. GRAY, MELANIE BURNETT, PHILIP McSHANE, ROBERT C. TURNER, AND PETER J. MORRIS

Intraportal islet autografting can restore near-normal glucose homeostasis in large diabetic animals, but the long-term failure rate of such grafts remains high. To assess the effect of the site of transplantation, we compared the hormonal responses to glucose (500 mg/kg i.v.) of intraportal (IP) and intrasplenic (IS) islet autografts in the cynomolgus monkey previously rendered diabetic by total pancreatectomy. Intravenous glucose tolerance tests (IVGTTs) 6 wk after IP grafting ($n = 10$) demonstrated nearly normal plasma glucose changes, with qualitatively normal but quantitatively reduced insulin and glucagon responses; only two animals have maintained these responses for >2 yr. IVGTTs 6 wk after IS grafting ($n = 4$) demonstrated more abnormal plasma glucose changes, with qualitatively normal but weak insulin responses and glucagon levels that did not fall in response to hyperglycemia; only one animal has maintained fasting normoglycemia for >9 mo. These results suggest that IS transplantation confers no benefit over IP transplantation in this model. *Diabetes* 38 (Suppl. 1): 182–84, 1989

A method for isolation of human islets of Langerhans has previously been described from our laboratories (1). We have successfully applied this method to the totally excised pancreas of the cynomolgus monkey (*Macaca fascicularis*; 2) and have demonstrated that intraportal (IP) autografts of such islets can maintain near-normal glucose homeostasis for >2 yr (3). However, 8 of 10 IP autografts failed to maintain fasting normoglycemia for >18 mo; indeed, 3 failed within 3 mo of autografting (3). A similarly high failure rate has been reported to follow IP autografting in beagles (4), whereas long-

term autograft function has been reported to follow intrasplenic (IS) islet autografting in mongrel dogs (5). It is possible that the portal venous site is in some way deleterious to an islet graft; alternatively, the spleen may confer some trophic advantage.

Although we have reported successful IS autografting in the cynomolgus monkey, the splenic grafts were excised at 6 wk to demonstrate that diabetes mellitus followed their removal (2). In this article, we compare the early and long-term metabolic function of IP and IS autografts in the cynomolgus monkey.

MATERIALS AND METHODS

Pancreatectomy. Male cynomolgus monkeys weighing 2.5–5.0 kg were fasted overnight, sedated with 10 mg/kg i.m. ketamine, intubated, and anesthetized with 1% halothane in nitrous oxide and oxygen. Total pancreatectomy was performed on 20 animals; 5 underwent total pancreatectomy without an islet transplant (group 1).

Islet isolation. The excised gland was immediately distended with 10 ml prewarmed Hanks' solution (Flow, Irvine, Ayrshire, Scotland, UK) containing 6 mg/ml collagenase (type V, Sigma, St. Louis, MO) and 7.5 mM calcium chloride, incubated at 37°C for 25 min, then plunged into cold Hanks' solution containing 20 mM HEPES buffer and 5 g/L bovine serum albumin (additions used subsequently throughout) in a beaker on ice. The pancreatic tissue was dispersed by gentle syringing and filtered through a 500- μ m and then a 106- μ m nylon filter (Simon, Stockport, England, UK). The final filtrate was mixed with the bottom layer of a Ficoll gradient of 1.090, 1.080, 1.070, and 1.040 sp gravity, then centrifuged at 500 \times g for 10 min at 4°C. The tissue obtained from the upper two interfaces was washed and combined with the tissue collected from the top of the 500- μ m filter. Dissecting-microscope inspection of the final yield showed purities of 5–10%.

Islet transplantation. IP autografting was performed in 10 animals (group 2) through a radicle of the superior mesenteric vein. Portal venous pressure was measured before and

From the Nuffield Department of Surgery, John Radcliffe Hospital, and the Diabetes Research Laboratories, Nuffield Department of Clinical Medicine, Radcliffe Infirmary, University of Oxford, Oxford, England, United Kingdom.

Address correspondence and reprint requests to Robert Sutton, Nuffield Department of Surgery, University of Oxford, John Radcliffe Hospital, Headington, Oxford OX3 9DU, UK.

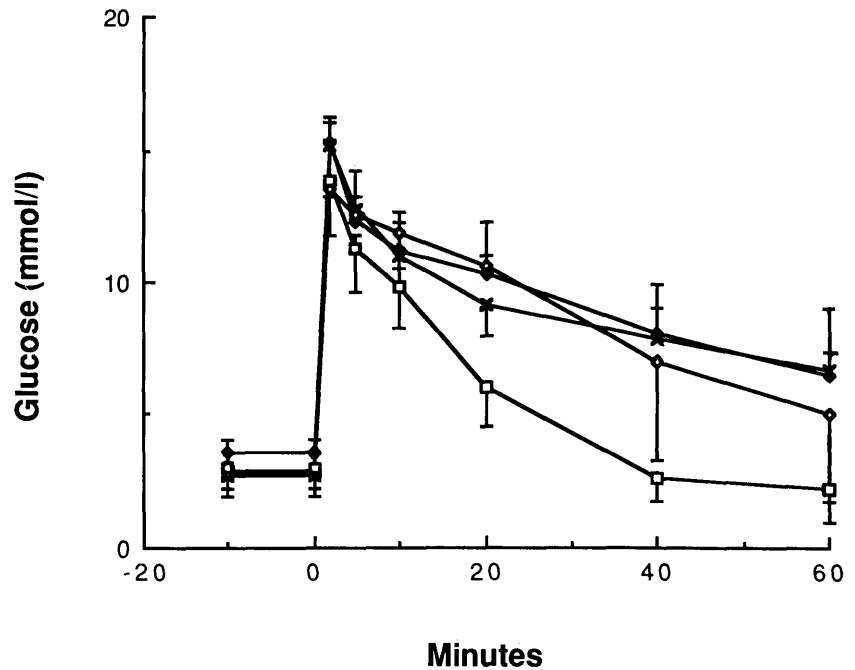


FIG. 1. Plasma glucose changes after glucose bolus of 500 mg/kg i.v. in 8 normal animals (\square), 10 animals 6 wk after intraportal islet autografting (\blacklozenge), 4 animals 6 wk after intrasplenic islet autografting (\times), and 2 animals 2 yr after intraportal islet autografting (\diamond). All animals displayed fasting normoglycemia when tested.

immediately after infusion of the islet graft. IS autografting was performed in 5 animals (group 3) through a short gastric vein cannulated in the direction of the spleen while the splenic artery and vein were temporarily clamped.

Metabolic assessment. All blood-sampling and metabolic tests were carried out under 10 mg/kg i.m. ketamine sedation after an overnight fast, and plasma glucose, insulin, and glucagon were measured on all samples. Intravenous glucose tolerance tests (IVGTTs; 500 mg/kg glucose) were carried out in 8 normal animals before islet transplantation, in 14 of the 15 islet-autografted animals 6 wk after islet transplantation, and in 2 animals 2 yr after well-maintained IP autograft function. Long-term graft function was monitored

by fortnightly measurement of fasting plasma glucose and insulin levels and of weight gain.

Histological studies. Paraffin sections of normal cynomolgus pancreas, isolated islets, autografted liver, and autografted spleen were all stained for insulin, glucagon, somatostatin, and pancreatic polypeptide with a two-layer immunoperoxidase technique.

RESULTS

Group 1. All five animals displayed a steady rise in plasma glucose and complete absence of plasma insulin in the days immediately after total pancreatectomy; diabetic precoma supervened 4–8 days after total pancreatectomy.

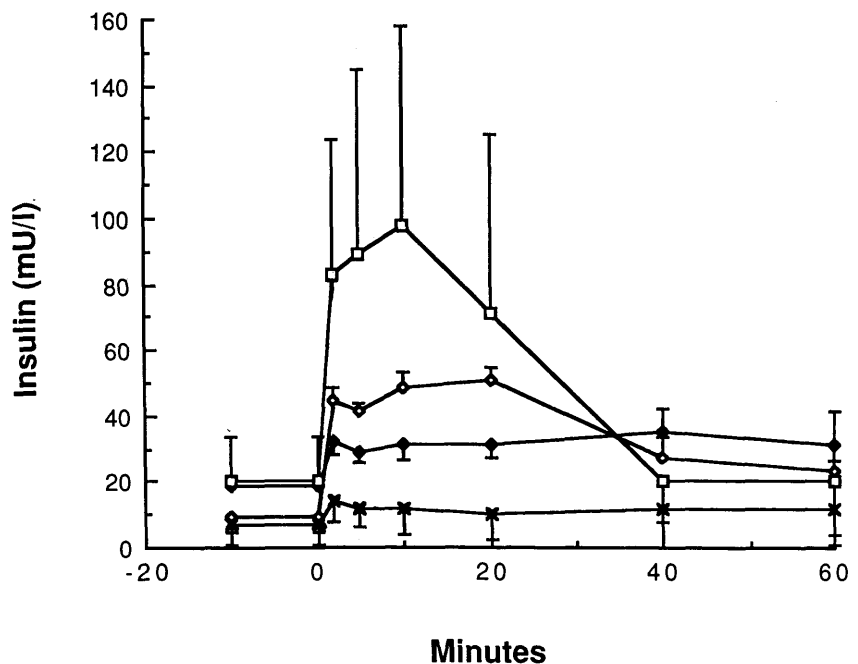


FIG. 2. Plasma insulin changes after glucose bolus of 500 mg/kg i.v. in 8 normal animals (\square), 10 animals 6 wk after intraportal islet autografting (\blacklozenge), 4 animals 6 wk after intrasplenic islet autografting (\times), and 2 animals 2 yr after intraportal islet autografting (\diamond).

Group 2. IVGTTs 6 wk after transplantation demonstrated near-normal glucose changes (Fig. 1), but although qualitatively normal insulin and glucagon responses were observed, the levels of both insulin (Fig. 2) and glucagon attained were significantly lower than normal (mean 2-min IVGTT insulin rise before grafting, 64.2 mU/L, after, 23.4 mU/L; glucagon fall before, -97.0 ng/L, after, -12.2 ng/L). Near-normal fasting plasma glucose levels were maintained in three animals for <3 mo, three for 6 mo, one for 15 mo, one for 18 mo, and two for >2 yr. IVGTTs 24 mo after transplantation in these last two animals demonstrated near-normal glucose changes (Fig. 1); the insulin responses in these animals were similar at 6 wk (not shown separately) and at 2 yr (Fig. 2) and were more nearly normal than the mean insulin response for the whole of group 2 6 wk after transplantation. Portal venous pressure recorded 10 min after IP autografting was never >5 cmH₂O above basal levels.

Group 3. Immediately after grafting, one animal demonstrated a progressive rise in plasma glucose and was subsequently shown to have a complete absence of plasma insulin. At laparotomy 10 days after transplantation, the spleen was found to have shrunk to <33% of normal size, and both the splenic artery and vein were thrombosed. IVGTTs at 6 wk in the remaining four animals showed markedly impaired glucose handling (Fig. 1). Although an increase in plasma insulin levels was recorded after the glucose bolus, the levels attained were significantly lower than in group 2 (Fig. 2); furthermore, glucagon levels did not fall in response to hyperglycemia (mean 2-min IVGTT insulin rise before grafting, 96.8 mU/L, after, 8.1 mU/L; glucagon fall before, -84.2 ng/L, after, rose 29.0 ng/L). Near-normal fasting glucose levels were maintained in one animal for 3 mo, one for 4 mo, one for 8 mo, and one for >9 mo. At laparotomy after autograft failure, no spleen was found in the animal that developed graft failure 8 mo after transplantation, although there were many adhesions.

Histology. Isolated islets, as well as islets within the engrafted liver and spleen, were found to contain cells that stained with primary antibodies directed at all four islet hormones listed above, although the intensity of insulin staining was consistently reduced.

DISCUSSION

We have shown exocrine contamination to impair the implantation of islets transplanted to the renal subcapsular site in the rat (6); a similar impairment of islet implantation may have occurred in this experiment, both in the portal circu-

lation and splenic venous bed. Indeed, although there was no evidence of portal hypertension, splenic vein thrombosis probably occurred in at least two animals receiving IS autografts. The primate spleen is less resilient than the dog spleen (7); similarly, the human spleen may not be a safe site for islet transplantation.

Only one IS autograft has continued to display function, with failure of all others by 8 mo posttransplantation. As in humans, the splenic venous bed of the cynomolgus monkey is smaller than the portal venous bed. As a result, a lower engraftment rate of islets infused into the splenic venous bed probably occurred, because the metabolic function of the IS autografts was so much poorer. Even if the distribution of insulin to the liver from an IS autograft is more complete than that from an IP graft and the extraction of insulin within the liver from an IS graft correspondingly greater, the IS grafts in this series displayed more markedly impaired glucose handling and an absence of suppression of glucagon secretion, which indicate inadequate graft function. If IS islet transplantation is to be successful in the primate, only purer islet preparations of much smaller volume are likely to be successful, because only then may substantial and safe islet engraftment occur.

ACKNOWLEDGMENTS

This work was supported by grants from the Juvenile Diabetes Foundation International, the British Diabetic Association, the Medical Research Council (UK), the Peel Medical Research Trust, and the Mason Medical Research Foundation.

REFERENCES

1. Gray DWR, McShane P, Grant A, Morris PJ: A method for isolation of islets of Langerhans from the human pancreas. *Diabetes* 33:1055-61, 1984
2. Gray DWR, Warnock GL, Sutton R, Peters M, McShane P, Morris PJ: Successful autotransplantation of isolated islets of Langerhans in the cynomolgus monkey. *Br J Surg* 73:850-53, 1986
3. Sutton R, Gray DWR, McShane P, Peters M, Morris PJ: The metabolic efficiency and long-term fate of intra-portal islet grafts in the cynomolgus monkey. *Transplant Proc* 19:3575-76, 1987
4. Alejandro R, Cutfield RG, Shienvold FL, Polonsky KS, Noel J, Olson L, Dillberger J, Miller J, Mintz DH: Natural history of intrahepatic canine islet cell autografts. *J Clin Invest* 78:1339-48, 1986
5. Merrell RC, Maeda M, Basadonna G, Marincola F, Cobb L: Suppression, stress, and accommodation of transplanted islets of Langerhans. *Diabetes* 34:667-70, 1985
6. Gray DWR, Sutton R, McShane P, Peters M, Morris PJ: Exocrine contamination adversely affects the implantation of rat islets transplanted to the kidney capsule site. *Transplant Proc* 18:1823-24, 1986
7. Warnock GL, Rajotte RV, Procyshyn AW: Normoglycemia after reflux of islet-containing pancreatic fragments into the splenic vascular bed in dogs. *Diabetes* 32:452-59, 1983