

## Emerging Biology of Malignant Salivary Gland Tumors Offers New Insights into the Classification and Treatment of Mucoepidermoid Cancer

□□ *Commentary on Okabe et al., p. 3902*

Frederic J. Kaye

In this issue of *Clinical Cancer Research*, Okabe et al. (1) have analyzed 71 cases of mucoepidermoid cancer and 51 cases of non-mucoepidermoid cancer for the presence of the *Mect1-Maml2* fusion oncogene and have made a valuable observation. They confirmed that *Mect1-Maml2* expression is specific for mucoepidermoid cancer and showed that fusion-positive tumors have histologic and prognostic features that are strikingly distinct from fusion-negative tumors. Although these data raise important points for both the diagnosis and management of these patients, it is helpful to first review the recent findings that have led to this retrospective clinical study.

Malignant salivary gland tumors represent a heterogeneous collection of cancers, which, due to their low incidence in the population, have often been grouped together (2). Accordingly, there has been little progress in defining the prognosis and treatment for these distinct neoplastic diseases. For example, although mucoepidermoid cancer is the most common malignant salivary gland tumor, there had been few insights into the genetic or biological basis of this tumor in the 100 years since it was first described by Volkmann in 1895 (3). In 1945, Stewart et al. established the term "mucoepidermoid" and defined this neoplasm as a specific pathologic entity under the designation of "tumor" due to its often benign but unpredictable clinical behavior (4). Only in 1953 did Foote and Frazell establish the term mucoepidermoid carcinoma, considering them all as malignant lesions (5). It was also recognized at this time that a characteristic histologic feature of mucoepidermoid cancer was the presence of varying amounts of three different cell types designated as epidermoid cells, mucin-producing cells, and intermediate cells. The relative amounts of epidermoid and mucin-producing cells, as well as the degree of cyst formation and cell differentiation, subsequently allowed for a prognostic classification of mucoepidermoid cancer, which could be scored as grades 1 to 3 (6), or as low-grade, mid-grade, and high-grade tumors (7). Although Okabe et al. (1) used a

semiquantitative grading system in the present study, which incorporates additional variables of tissue invasion, cell proliferation, and anaplasia (8), each of these classification systems have shown a limited ability to guide clinicians through the variable clinical course of individual cases or to help define the benefit versus morbidity of extensive surgical resection margins and adjuvant radiation therapy.

A first clue toward understanding the etiologic basis for mucoepidermoid cancer was the identification of a recurrent t(11;19) chromosomal translocation in a subset of tumors. Importantly, this translocation was the sole abnormality in a few case reports (9), and the chromosomal rearrangement was detected in both salivary gland and bronchopulmonary mucoepidermoid cancers (10). This latter finding reinforced the observation that primary tumors with a mucoepidermoid cancer-like histologic pattern could arise from many different anatomic locations, which included the upper and lower aerodigestive tract, as well as rare cases from the thyroid, esophagus, pancreas, skin, and several other sites (see ref. 11 for citations). In fact, the initial mapping of the t(11;19) rearrangement and the cloning of the *Mect1-Maml2* transcript arose fortuitously as part of a study of acquired mutations in young patients with lung cancer. An adenosquamous lung tumor sample, which was later reclassified as a case of pulmonary mucoepidermoid cancer, as well as the independently derived H292 (12) and H3118 mucoepidermoid cancer tumor cell lines, showed the t(11;19) rearrangement, which ultimately led to the identification of the identical novel fusion transcript in each case (13).

Because the *Mect1* gene on chromosome 19p only contributed 42 amino acids to the NH<sub>2</sub> terminus of the chimeric gene product and had no known function at the time, initial efforts to define a functional role for the fusion oncogene focused on the *Maml2* gene from chromosome 11q21, which contributed 981 amino acids to the transcript and was a new member of a Notch regulatory gene family called *Mastermind* (Fig. 1). In fact, the related *Maml1* gene on chromosome 5 had been shown to be an essential coactivator for Notch signaling *in vitro* (14), which suggested that the t(11;19) translocation may have aberrantly deregulated *Maml2*/Notch signaling in these salivary gland tumor cells. Two observations supported this model. First, the ectopic expression of *Mect1-Maml2 in vitro* was shown to constitutively activate a prototypic Notch target gene *Hes-1* in the absence of Notch ligand (13) and, second, a t(7;9) translocation that truncated the *Notch1* receptor gene had previously been shown to underlie the genesis of some human T-cell leukemias, serving as a precedent for a connection between constitutive Notch signaling and cancer (15). A challenge to the model of *Mect1-Maml2*-mediated tumorigenesis,

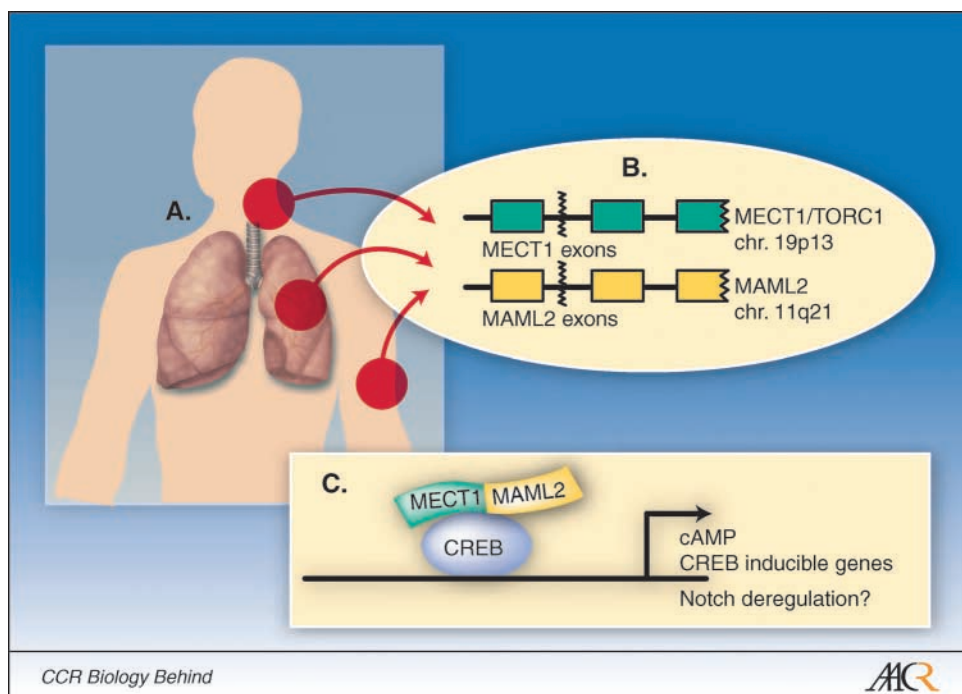
**Author's Affiliations:** Genetics Branch, Center for Cancer Research, National Cancer Institute and the National Naval Medical Center, Bethesda, Maryland  
Received 4/6/06; accepted 4/10/06.

**Grant support:** Intramural Research Program of the Center for Cancer Research, National Cancer Institute.

**Requests for reprints:** Frederic J. Kaye, Naval Medical Oncology Branch, Naval Hospital, National Cancer Institute, Bethesda, MD 20814; Phone: 301-435-5375; Fax: 301-402-2414; E-mail: fkaye@helix.nih.gov.

©2006 American Association for Cancer Research.  
doi:10.1158/1078-0432.CCR-06-0791

**Fig. 1.** *A.* cartoon depicting mucoepidermoid cancer – like tumors arising from major or minor salivary glands of the head and neck, from the bronchopulmonary tree, and from a cutaneous clear cell hidradenoma, which have each been previously shown to express the identical Mect1-Maml2 product. Other rare mucoepidermoid cancer – like tumors that can arise from several different organ sites have not yet been tested for the presence of the fusion oncogene. *B.* mapping of the t(11;19) chromosomal breakpoint, which occurs within intron 1 of both the *Mect1/Torc1* and *Maml2* genes in all cases tested and which results in exon 1 swapping between the genes. Whereas the etiologic events leading to the t(11;19) are unknown in most cases, mucoepidermoid cancer presents commonly as a secondary cancer in children and shows an exceptionally strong radiation dose response risk (30, 31). *C.* simplistic model depicting the ability of Mect1-Maml2 to activate a group of cAMP/cAMP-responsive element binding protein (*CREB*) – inducible genes, which are hypothesized to participate in tumorigenesis (see text for details).



however, was the surprising discovery that ectopic Mect1-Maml2 activated the *Hes-1* promoter independently of the cognate DNA sequences normally required for promoter binding of the heteromeric activated Notch complex (13). An important step to clarify this issue was the subsequent publication of reports, which (a) independently isolated the *Mect1* gene (also called *Torc1*) as an essential coactivator for cyclic AMP (cAMP)–responsive element binding protein/cAMP–inducible transcription (16, 17), (b) identified a cAMP-responsive element binding protein binding site within the *Hes-1* promoter, and (c) mapped the cAMP-responsive element binding protein binding domain to the NH<sub>2</sub>-terminal 42 amino acids of Mect1/Torc1, which were included in the fusion peptide (16). Later studies confirmed that small in-frame deletions within *Mect1/Torc1* exon 1 abolished Mect1-Maml2–transforming activity (18), and that ectopic expression of Mect1-Maml2 induced the activation of a cassette of cAMP/cAMP-responsive element binding protein–regulated genes (18, 19). Therefore, a current working model for Mect1-Maml2–mediated tumorigenesis proposes that the potent COOH-terminal Maml2 transactivation domain is aberrantly recruited to cAMP-responsive element binding protein binding site–containing promoters by the small Mect1/Torc1 domain to activate a set of downstream cAMP-responsive element binding protein–inducible genes. In addition, new insights into the network biology of the Torc family of genes have shown unexpected connections between energy homeostasis, gluconeogenesis, and cancer. For example, the tumor suppressor gene *LKB1* has been shown to participate with AMP-activated protein kinase to inhibit the nuclear localization and transcriptional coactivator function of the Mect1/Torc1 homologue Torc2 to control glucose regulation during fasting (20). Because *LKB1* is a target for mutations in the inherited Peutz-Jeghers cancer syndrome, as well as in sporadic cases of lung and colorectal cancer (21), defining the biology for mucoepi-

dermoid cancer tumorigenesis may offer clues for understanding links between cAMP/energy signaling within other types of malignancies as well. Finally, it is worth remembering that Mect1-Maml2 still retains the potential to also disrupt Notch signaling through dominant-negative mechanisms, and future investigations will be required to ultimately define its functional role in tumorigenesis.

Okabe et al. in this issue of *Clinical Cancer Research* has now addressed several timely clinical and pathologic issues regarding the association of Mect1-Maml2 with mucoepidermoid cancer. Using nested reverse transcription-PCR methods, they observed that 38% (27 of 71) of mucoepidermoid cancer samples expressed the chimeric oncogene, whereas 0% (0 of 51) non-mucoepidermoid salivary gland cases, including Warthin tumor, pleomorphic adenoma, and adenoid cystic carcinoma, were positive for the fusion transcript. Significantly, 56.5% (26 of 46) of low-grade mucoepidermoid tumors were fusion positive, whereas only 11% (1 of 9) of intermediate-grade and 0% (0 of 15) of high-grade mucoepidermoid tumors were fusion positive ( $P < 0.0001$ ). This association also correlated with a significant improvement in overall survival in patients with surgically resected fusion-positive mucoepidermoid cancer compared with fusion-negative mucoepidermoid cancer ( $P = 0.002$ ), although the difference in disease-free survival between the two groups was not as striking ( $P = 0.028$ ).

These observations are strongly supported by an independent study that detected *Mect1-Maml2* expression in 16 of 29 (55%) of mucoepidermoid cancer using similar nested PCR methodology (22). In this study, 92.8% (13 of 14) of well-differentiated, 66.7% (2 of 3) of moderately differentiated, and 0% (0 of 11) of poorly differentiated mucoepidermoid cancer samples were fusion positive. In addition, these authors showed a marked improvement in cancer-specific median survival in the fusion-positive tumors (>10 years) versus fusion-negative tumors (1.6 years).

Taken together, these reports allow us to make several predictions and speculations. First, we can now recognize that high-grade or poorly differentiated mucoepidermoid cancer is a distinct genetic entity from low-grade malignancies. Because a Mect1-Maml1 substitution mutant showed similar transcriptional functional activity to the native Mect1-Maml2 peptide (13), it is possible (and testable) that some cases of Mect1-Maml2 fusion-negative samples might have arisen from variant translocations involving homologous Torc and Maml family members. Alternatively, fusion-negative tumors may contain cryptic epistatic mutations within a unifying LKB1/Torc/cAMP tumor suppressor pathway. For example, papillary thyroid cancer arises from mutually exclusive events involving either a translocation within the *Ret* gene or a missense mutation within the *B-raf* gene, which serves to show the power of genetics to confirm common cancer gene pathways (23). However, given that 0 of 26 cases of high-grade mucoepidermoid cancer express Mect1-Maml2, a more plausible explanation for these data is that fusion-negative high-grade or poorly differentiated tumors represent a completely separate clinical and pathologic entity, which might be more accurately classified as a non-mucoepidermoid "adenosquamous carcinoma." In addition, although the age distribution for mucoepidermoid cancer can be extremely wide, there is evidence from these and other studies that such cases of fusion-negative adenosquamous carcinomas will be particularly prevalent in the most elderly patients.

Second, the difference in the frequency of detecting *Mect1-Maml2* expression in low-grade mucoepidermoid tumors between these two recent retrospective studies may be based more on technical rather than biological explanations. For example, Okabe et al. (1) obtained RNA from formalin-fixed archival specimens (56.5% of these low-grade samples were fusion positive), whereas Behboudi et al. (22) isolated RNA from snap-frozen samples (92.8% of low-grade samples were fusion positive), which may be predicted to give a more accurate yield. These data suggest that the great majority of low-grade mucoepidermoid cancer will have a common genetic origin, and the rare subset of low-grade tumors, which are bona fide fusion-negative samples, might be a good source to search for variant translocations or other epistatic mutations.

Third, several reports had suggested the possibility that *Mect1-Maml2* may be expressed in non-mucoepidermoid tumors, such as Warthin tumor (24). This raised the possibility that *Mect1-*

*Maml2* expression may not be a specific marker for tumors with mucoepidermoid cancer-like histology. The present study by Okabe et al. (1) greatly clarifies this issue by showing that 0 of 26 Warthin tumor samples were fusion positive, confirming an earlier study that had also shown that 0 of 7 Warthin tumors were fusion positive (25). These data suggest that rare single cases of fusion positive non-mucoepidermoid salivary tumors are more likely to represent examples of histologic misdiagnosis or the coincident presence of mucoepidermoid cancer tumor cells within the biopsy sample (26, 27). In addition, the remarkable detection of the identical fusion transcript in mucoepidermoid cancer samples that arise from different major and minor salivary glands as well as from multiple sites within the bronchial tree or from a mucoepidermoid cancer-like cutaneous lesion (28) supports the notion of a unifying Mect1-Maml2-mediated pathobiology that is independent of the primary anatomic tissue of origin (11).

The analysis of Mect1-Maml2, therefore, has helped initiate a preliminary understanding of mucoepidermoid cancer tumorigenesis. How this information might further assist clinicians and their patients in the management of this cancer, however, is still unknown. Okabe et al. (1) has noted that many salivary gland tumors are diagnosed by fine needle aspirates, and it is speculated that the presurgical detection of Mect1-Maml2 expression may allow early confirmation of the diagnosis and, perhaps, the implementation of less morbid surgical margins and adjuvant treatments. Prospective clinical trials, however, will be required to validate these possibilities. In addition, the sustained expression of Mect1-Maml2 has recently been shown to be required for the growth of mucoepidermoid cancer tumor cell lines, validating its role as a molecular target (29). Although activating nuclear transcription cofactors are not readily accessible for small molecule strategies, an understanding of the network biology and the downstream target mediators of Mect1-Maml2 may help organize the empirical or "rational" testing of new agents in future clinical trials. Finally, ongoing research into etiologic molecular markers for other types of malignant salivary gland tumors may ultimately help define a functional classification system that will lead to better strategies of prevention and treatment for the broad group of malignant salivary gland tumors.

## Acknowledgments

I thank Drs. I. Fonseca and C. Martin for careful reading of this article.

## References

- Okabe M, Miyabe S, Nagatsuka H, et al. Mect1-Maml2 fusion transcript defines a favorable subset of mucoepidermoid carcinoma. *Clin Cancer Res* 2006; 12:3902-7.
- Barnes L, Eveson JW, Reichart P, Sidransky D, editors. *World Health Organization classification of tumours. Pathology and genetics of head and neck tumours*. Lyons (France): IARC Press; 2005. pp. 209-81.
- Volkman I. Über endotheliale Geschwülste zugleich ein Beitrag zu den Speicheldrüsen und Caementumoren. *Dtsch Z Chir* 1895;41:1.
- Stewart FW, Foote FW, Becker WF. Mucoepidermoid tumors of the salivary glands. *Ann Surg* 1945;122: 820-44.
- Foote FW, Jr., Frazell EL. Tumors of the major salivary glands. *Cancer* 1953;6:1065-133.
- Healey WV, Perzin KH, Smith L. Mucoepidermoid carcinoma of salivary gland origin. Classification, clinical-pathologic correlation, and results of treatment. *Cancer* 1970;26:368-88.
- Jensen OJ, Poulsen T, Schiodt T. Mucoepidermoid tumors of salivary glands. A long term follow-up study. *APMIS* 1988;96:421-7.
- Goode RK, Auclair PL, Ellis GL. Mucoepidermoid carcinoma of the major salivary glands: clinical and histopathologic analysis of 234 cases with evaluation of grading criteria. *Cancer* 1998;82:1217-24.
- El-Naggar AK, Lovell M, Killary AM, Clayman GL, Batsakis JG. A mucoepidermoid carcinoma of minor salivary gland with t(11;19)(q21;p13.1) as the only karyotypic abnormality. *Cancer Genet Cytogenet* 1996; 87:29-33.
- Stenman G, Petersdottir V, Mellgren G, Mark J. A child with a t(11;19)(q14-21;p12) in a pulmonary mucoepidermoid carcinoma. *Virchows Arch* 1998; 433:579-81.
- Fonseca I, Martins C, Kaye FJ. A unifying proposal for Mect1-Maml2 associated tumorigenesis [letter]. *J Mol Diagn*. In press 2006.
- Barsky SH, Martin SE, Matthews M, Gazdar A, Costa JC. "Low grade" mucoepidermoid carcinoma of the bronchus with "high grade" biological behavior. *Cancer* 1983;51:1505-9.
- Tonon G, Modi S, Wu L, et al. t(11;19)(q21;p13) translocation in mucoepidermoid carcinoma creates a novel fusion product that disrupts a Notch signaling pathway. *Nat Genet* 2003;33:208-13.
- Wu L, Aster JC, Blacklow SC, Lake R, Artavanis-Tsakonas S, Griffin JD. MAML1, a human homologue of *Drosophila* mastermind, is a transcriptional

- co-activator for NOTCH receptors. *Nat Genet* 2000; 26:484–9.
15. Ellisen LW, Bird J, West DC, et al. TAN-1, the human homolog of the *Drosophila* notch gene, is broken by chromosomal translocations in T lymphoblastic neoplasms. *Cell* 1991;66:649–61.
  16. Conkright MD, Canettieri G, Screaton R, et al. TORCs: transducers of regulated CREB activity. *Mol Cell* 2003;12:413–23.
  17. Iourgenko V, Zhang W, Mickanin C, et al. Identification of a family of cAMP response element-binding protein coactivators by genome-scale functional analysis in mammalian cells. *Proc Natl Acad Sci U S A* 2003;100:12147–52.
  18. Coxon A, Rozenblum E, Park YS, et al. Mect1-Maml2 fusion oncogene linked to the aberrant activation of cyclic AMP/CREB regulated genes. *Cancer Res* 2005;65:7137–44.
  19. Wu L, Liu J, Gao P, et al. Transforming activity of Mect1-Maml2 fusion oncoprotein is mediated by constitutive CREB activation. *EMBO J* 2005; 24:2391–402.
  20. Shaw RJ, Lamia KA, Vasquez D, et al. The kinase LKB1 mediates glucose homeostasis in liver and therapeutic effects of metformin. *Science* 2005;310: 1642–6.
  21. Launonen V. Mutations in the human LKB1/STK11 gene. *Hum Mutat* 2005;26:291–7.
  22. Behboudi A, Enlund F, Winnes M, et al. Molecular classification of mucoepidermoid carcinomas: prognostic significance of the Mect1-Maml2 fusion oncogene. *Genes Chromosomes Cancer* 2006;45: 470–81.
  23. Soares P, Trovisco V, Rocha AS, et al. BRAF mutations and RET/PTC rearrangements are alternative events in the etiopathogenesis of PTC. *Oncogene* 2003;22:4578–80.
  24. Enlund F, Behboudi A, Andren Y, et al. Altered Notch signaling resulting from expression of a WAMTP1–2 gene fusion in mucoepidermoid carcinomas and benign Warthin's tumors. *Exp Cell Res* 2004;292:21–8.
  25. Martins C, Cavaco B, Tonon G, Kaye FJ, Soares J, Fonseca I. A study of Mect1-Maml2 in mucoepidermoid carcinoma and Warthin's tumor of salivary glands. *J Mol Diagn* 2004;6:205–10.
  26. Gadiant SE, Kalfayan B. Mucoepidermoid carcinoma arising within a Warthin's tumor. *Oral Surg Oral Med Oral Pathol* 1975;40:391–8.
  27. Williamson JD, Simmons BH, el-Naggar A, Medeiros LJ. Mucoepidermoid carcinoma involving Warthin tumor. A report of five cases and review of the literature. *Am J Clin Pathol* 2000;114:564–70.
  28. Behboudi A, Winnes M, Gorunova L, et al. Clear cell hidradenoma of the skin: a third tumor type with a t(11;19)-associated TORC1–2 gene fusion. *Genes Chromosomes Cancer* 2005;43:202–5.
  29. Komiya T, Park Y, Modi S, Coxon A, Oh H, Kaye FJ. Sustained expression of Mect1-Maml2 is essential for tumor cell growth in salivary gland cancers carrying the t(11;19) translocation. *Oncogene*. Epub 2006 May 1.
  30. Whatley WS, Thompson JW, Rao B. Salivary gland tumors in survivors of childhood cancer. *Otolaryngol Head Neck Surg* 2006;134:385–8.
  31. Land CE, Saku T, Hayashi Y, et al. Incidence of salivary gland tumors among atomic bomb survivors, 1950–1987. Evaluation of radiation-related risk. *Radiat Res* 1996;146:28–36.