

Genomic Landscape of Uterine Sarcomas Defined Through Prospective Clinical Sequencing

Martee L. Hensley^{1,2}, Shweta S. Chavan³, David B. Solit^{2,3,4,5}, Rajmohan Murali⁶, Robert Soslow⁶, Sarah Chiang⁶, Achim A. Jungbluth⁶, Chaitanya Bandlamudi³, Preethi Srinivasan⁶, William D. Tap^{2,5}, Evan Rosenbaum⁵, Barry S. Taylor^{2,3,4,7}, Mark T.A. Donoghue³, and David M. Hyman^{1,2}



ABSTRACT

Purpose: We examined whether prospective molecular characterization of advanced metastatic disease can reveal grade and/or histology-specific differences to inform diagnosis and facilitate enrollment onto clinical trials.

Experimental Design: Patients with uterine sarcoma consented to a prospective study of next-generation sequencing (NGS). Clinical annotations were extracted from their medical record. Tumor and matched normal DNA were subjected to NGS, and the genomic landscape was explored for survival correlations and therapeutic targetability.

Results: Tumors from 107 women were sequenced and included leiomyosarcoma ($n = 80$), high-grade non-leiomyosarcoma ($n = 22$), low-grade endometrial stromal sarcoma (LG-ESS, $n = 4$), and smooth muscle tumor of uncertain malignant potential (STUMP, $n = 2$). Genomic profiling influenced histologic diagnosis in three cases. Common uterine leiomyosarcoma alterations were loss-of-function mutations in *TP53* (56%), *RB1* (51%), and *ATRX* (31%).

Homozygous deletions of *BRCA2* were present in 5% of these patients. *PTEN* alteration frequency was higher in the metastases samples as compared with the primary samples. Genomes of low-grade tumors were largely silent, while 50.5% of high-grade tumors had whole-genome duplication. Two metastatic uterine leiomyosarcoma cases were hypermutated. Both had prolonged disease-free survival. Potentially actionable mutations were identified in 48 patients (45%), 8 (17%) of whom received matched therapy with 2 achieving clinical responses. Among patients with uterine leiomyosarcoma with somatic *BRCA2* alterations, sustained partial responses were observed with PARP inhibitor-containing therapy.

Discussion: Prospective genomic profiling can contribute to diagnostic precision and inform treatment selection in patients with uterine sarcomas. There was evidence of clinical benefit in patients with uterine leiomyosarcoma with somatic *BRCA2* alterations treated with PARP inhibitors.

Introduction

Uterine sarcomas are rare mesenchymal neoplasms that differ in histologic appearance and clinical behavior. Classification of uterine sarcoma has traditionally been based on histologic appearance including key features of cytologic atypia, tumor cell necrosis, mitotic rate, and select use of IHC to support tissue differentiation. The most common subtypes of uterine sarcomas are leiomyosarcoma, low-grade

endometrial stromal sarcoma (LG-ESS), and high-grade endometrial stromal sarcoma (HG-ESS). Immunophenotypes and molecular characterization of uterine sarcomas have increasingly been utilized to improve diagnostic classification and prognostication in uterine sarcomas. For example, LG-ESSs express the estrogen and progesterone receptors, have an indolent disease course, and are molecularly characterized by recurrent chromosomal translocations commonly involving *JAZF1* (1). By comparison, a subset of HG-ESS harbor *t(10;17)(q22;p13)* translocations that result in expression of a *YWHAE-NUTM2A/B* fusion (2) and have an aggressive disease course (3) while others have *BCOR* alterations that are of unknown prognostic significance (4). As such, testing for *YWHAE* and *BCOR* fusions in histologically challenging high-grade sarcomas may facilitate a more precise diagnosis. Uterine leiomyosarcoma, the most common subtype of uterine sarcoma, does not have a single defining molecular abnormality. Instead, these tumors often have multiple chromosomal abnormalities associated with chromothripsis, *TP53* and *RB1* inactivation, and whole-genome duplication (WGD; ref. 5).

To determine whether genomic profiling could improve diagnostic precision, inform prognosis, or aid in therapeutic selection, we prospectively characterized uterine sarcomas, enriching for high-risk subtypes that contribute to the greatest morbidity and mortality. We applied a clinically validated next-generation sequencing (NGS) platform to determine whether molecular profiling could enhance uterine sarcoma classification, provide prognostic information within histologic subtypes, and identify subsets of patients whose tumors harbor targetable mutations. We also evaluated whether patients with potentially actionable alterations received matched therapy, and if so, whether they derived clinical benefit.

¹Gynecologic Medical Oncology Service, Department of Medicine, Memorial Sloan Kettering Cancer Center, New York, New York. ²Weill Cornell Medical College, New York, New York. ³Marie-Josée and Henry R. Kravis Center for Molecular Oncology, Memorial Sloan Kettering Cancer Center, New York, New York. ⁴Human Oncology and Pathogenesis Program, Memorial Sloan Kettering Cancer Center, New York, New York. ⁵Department of Medicine, Memorial Sloan Kettering Cancer Center, New York, New York. ⁶Department of Pathology, Memorial Sloan Kettering Cancer Center, New York, New York. ⁷Department of Epidemiology and Biostatistics, Memorial Sloan Kettering Cancer Center, New York, New York.

Note: Supplementary data for this article are available at Clinical Cancer Research Online (<http://clincancerres.aacrjournals.org/>).

M.L. Hensley, S.S. Chavan, M.T.A. Donoghue, and D.M. Hyman contributed equally to this article.

Corresponding Author: Martee L. Hensley, Memorial Sloan Kettering Cancer Center, 1275 York Avenue, New York, NY 10065. Phone: 646-888-4222; Fax: 646-4268-888; E-mail: hensley@mskcc.org

Clin Cancer Res 2020;26:3881-8

doi: 10.1158/1078-0432.CCR-19-3959

©2020 American Association for Cancer Research.

Translational Relevance

Prospective genomic profiling can contribute to diagnostic precision and inform treatment selection in a subset of patients with uterine sarcomas. Potentially actionable mutations were identified in 45% of patients. There was evidence of clinical benefit in patients with uterine leiomyosarcoma with somatic *BRCA2* alterations treated with PARP inhibitors. These data support the development of clinical trials for uterine sarcomas that incorporate genomic findings and test treatments matched to potential therapeutic targets.

Materials and Methods

Patients

Patients with a histologically confirmed uterine sarcoma (USARC, oncotree.mskcc.org) at Memorial Sloan Kettering Cancer Center (MSK; New York, NY) were consented to a prospective study using NGS under an Institutional Review Board (IRB)-approved protocol (ClinicalTrials.gov, NCT01775072). This study was conducted in accordance with International Ethical Guidelines for Biomedical Research Involving Human Subjects, Good Clinical Practice guidelines, the Declaration of Helsinki, and local laws, and with written consent of the subjects, where necessary.

Histologic diagnosis, stage, and grade

All consecutively sequenced uterine sarcomas and uterine mesenchymal tumors of uncertain malignant potential, regardless of histologic type or grade, successfully profiled between April 2014 and April 2017 were included in this cohort, with the exception of perivascular epithelioid tumors, which lack established standard diagnostic criteria. All tumors were reviewed and histopathologically confirmed to be uterine sarcoma by gynecologic sarcoma pathologists at MSK (New York, NY). To facilitate genomic and outcome analysis, we grouped cases into four diagnostic entities on the basis of histology: (i) uterine leiomyosarcoma, (ii) high-grade non-leiomyosarcoma uterine sarcomas, (iii) LG-ESS, and (iv) smooth muscle tumor of uncertain malignant potential (STUMP). As grading of uterine leiomyosarcoma is not standardized and because most tumors meeting histologic criteria for a diagnosis of leiomyosarcoma at MSK (New York, NY) are considered high-grade, leiomyosarcoma cases were not further subdivided by grade. The two STUMP tumors were included, because both patients had an original diagnosis of STUMP in the uterus, followed by metastatic disease, which in one case was histologically shown to be leiomyosarcoma. In both cases, the genomic profiling was performed on the tissue that had been classified as STUMP. Tumors were staged according to the 2009 International Federation of Gynecology and Obstetrics (FIGO) staging system. Primary and metastatic sites were sequenced on the basis of tissue availability.

Genomic sequencing

NGS of DNA extracted from formalin-fixed, paraffin embedded tumor and patient-matched blood was performed in the Clinical Laboratory Improvement Amendments–certified MSK Molecular Diagnostics Service Laboratory using MSK-IMPACT, an exon capture assay targeting all coding exons of 341 ($n = 44$ samples), 410 ($n = 44$ samples), or 468 ($n = 20$ samples) cancer-associated genes, as described previously (6, 7). DNA was sequenced to an average of 646-fold sequence coverage. All somatic variant genomic results were

reviewed by a molecular pathologist for quality and accuracy prior to adding the results into the patient's medical record, as described previously (7). All patient-level clinical and genomic data are available at the cBioPortal (https://cbioportal.mskcc.org/study/summary?id=usarc_msk_2020).

Fusion detection

Fusion genes were identified either via MSK-IMPACT, which targets breakpoint-containing introns of known oncogenic fusion partners, or an RNA-based custom solid tumor fusion panel, MSK-Fusion (8), which was used as part of the diagnostic work-up for a subset of patients.

Microsatellite instability

The presence of microsatellite instability (MSI) was assessed genomically using MSIsensor (version 0.2; ref. 9). MSIsensor assigns a numeric score based on the percentage of unstable microsatellite sites divided by the total number of microsatellite sites tested from aligned sequencing data. On the basis of the prior clinical validation of MSIsensor using MSK-IMPACT data, MSI status was defined as follows: <3 : microsatellite stable; ≥ 3 and <10 : MSI-indeterminate (MSI-I); and ≥ 10 : MSI-high (MSI-H; ref. 10). For tumor samples in which genomic sequencing yielded an MSIsensor score ≥ 10 , the MSI phenotype was confirmed by IHC staining of mismatch repair (MMR) proteins (MLH1, MSH2, MSH6, and PMS2).

Mutational signature decomposition

To better characterize the mutational processes driving acquisition of somatic alterations, mutational signature decomposition analysis was performed for tumor samples with 10 or more single-nucleotide variant somatic mutations, as described previously (11). For cases in which more than one signature was present, a weighted combination of signatures was calculated reflecting the proportion of mutations in the sample attributed to that signature.

Allele-specific copy-number analysis

We performed FACETS analysis to determine allele-specific and absolute DNA copy-number genome-wide in all patients (FACETS version 0.5.6, $c_{val} = 100$; ref. 12). We used these allele-specific copy-number data to estimate tumor purity and ploidy. Prior to further analysis, total copy-number log ratios were corrected for ploidy and purity. Tumors with WGD were those in which greater than 50% of the autosomal genome had a major copy number ≥ 2 , where major copy number is defined as the number of copies of the most prevalent allele present in the sample (13). Cancer cell fractions were calculated using a binomial distribution and maximum likelihood estimation normalized to produce posterior probabilities, and were used to infer the sequence/timing of mutations (14).

Germline analysis

Germline annotation for pathogenic or likely pathogenic variants was performed by MSK-IMPACT for 76 genes previously associated with cancer predisposition syndromes using a clinically validated platform (15, 16). In accordance with local IRB guidelines and protocol-mandated procedures, the germline variant annotation and the assessment of pathogenicity were performed after irreversible anonymization of patients. Histologic type and allele-specific absolute copy number were retained prior to irreversible anonymization, permitting subsequent determination of LOH. No other clinical data were retained following anonymization.

Programmed cell death protein 1 IHC

To confirm that deletions of *PDCD1* (the gene that encodes PD-1) were associated with loss of protein expression in tumor samples with homozygous deletion of *PDCD1*, IHC with an anti-PD-1 (programmed cell death protein 1) mAb (clone NAT105; Abcam) using a Leica Bond-3 automated platform (Leica) was performed. A polymeric secondary kit (Refine, Leica) was used for the detection of the primary antibody.

Annotation of somatic alterations

To classify the individual identified somatic genomic variants, we utilized the OncoKB knowledgebase (OncoKB.org), which provides disease-specific levels of evidence for the actionability of individual mutant alleles, DNA copy-number alterations, and translocations (17). A level 1 alteration is an FDA-recognized biomarker in the patient's tumor type; a level 2 alteration is a biomarker routinely used to guide prescribing of an FDA-approved drug in the patient's tumor type (2A) or another indication (2B); and a level 3 alteration has compelling clinical evidence to support its use as a biomarker predictive of treatment response. These annotations and integration with clinical data were performed as of October 2019.

Statistical analysis

We evaluated for enrichment of genomic alterations within this cohort across histologic subtypes and sample type (primary vs. metastasis), as well as between this cohort and other cohorts, including MSK non-uterine leiomyosarcoma and The Cancer Genome Atlas (TCGA) uterine leiomyosarcoma cohorts (18). Comparisons were conducted utilizing the Fisher exact test, and nominal *P* values were specified. Survival analyses were performed using univariate Cox proportional hazards model and Kaplan–Meier estimation of overall survival (OS) using the R “survival” package (2.41–3).

Results

Patient demographics

As part of the previously described MSK-IMPACT clinical sequencing cohort (6), which at the time of data freeze stood at 15,816 patients for tumor types with at least 25 cases, the tumors of 107 women with uterine sarcoma were successfully sequenced. At the time of diagnosis, 57% (*n* = 61) of patients had uterine-confined disease (FIGO stage I). At the time of sequencing, 89% (*n* = 95) had recurrent/metastatic disease (Fig. 1A). As expected for a cohort of patients with recurrent/metastatic uterine sarcoma, the majority of cases (94.3%, *n* = 101) were histologically high-grade. Histologic sarcoma subtypes included uterine leiomyosarcoma (*n* = 80), high-grade non-leiomyosarcoma (*n* = 21), LG-ESS (*n* = 4), and STUMP (*n* = 2). High-grade non-leiomyosarcomas were further classified as: (HG-ESS; *n* = 7), undifferentiated (*n* = 5), high-grade adenosarcoma with sarcomatous overgrowth (*n* = 4), high-grade uterine sarcoma with heterologous elements (*n* = 2) uterine sarcoma with focal dedifferentiation, high-grade uterine sarcoma not otherwise specified, atypical myxoid neoplasm with differential including leiomyosarcoma or myofibroblastic sarcoma (one each). All patients are represented by a single sample, except for a high-grade non-leiomyosarcoma patient with two metastasis samples (pelvic and abdomen). In contrast to TCGA, both primary (39%, *n* = 42) and metastatic (61%, *n* = 66) samples were profiled (Fig. 1B). At the time of analysis, 45% of patients had died of disease. Median survival from diagnosis for the entire cohort was 5.6 years (range, 0.2–23.1 years). Survival for patients with high-grade non-leiomyosarcoma was significantly worse than for patients with

uterine leiomyosarcoma (3.4 years vs. 6.3 years, respectively; HR = 0.48, CI = 0.24–0.96, *P* = 0.03; Fig. 1C).

Genomic alterations and comparisons across uterine sarcoma histologies

The most common alterations in uterine leiomyosarcoma were loss-of-function mutations or homozygous deletions in *TP53* (56%), *RBI* (51%), and *ATRX* (31%; Fig. 2A). *TP53*, *RBI*, and *ATRX* alterations were less common in high-grade non-leiomyosarcoma cases (14%, 14%, and 5%, respectively; *P* < 0.01 for all). Compared with other cancer types, uterine sarcomas have high frequency of homozygous deletions of *BRCA2* (19), and these were found exclusively in uterine leiomyosarcoma (Fig. 2A). Uterine leiomyosarcoma was also characterized by recurrent homozygous deletions of *PDCD1*, which encodes PD-1. Indeed, uterine leiomyosarcoma had the highest rate of *PDCD1* homozygous deletions among all cancer types with at least 25 cases in the contemporary MSK-IMPACT clinical series cohort of prospective sequenced cancers (*n* = 15,816; Fig. 2B). To determine whether *PDCD1* homozygous deletion was associated with loss of *PDCD1* expression, we performed IHC in affected cases with sufficient archival material (*n* = 2/7), which confirmed *PDCD1* was negative in both cases (Supplementary Fig. S1). Similarly, amplifications of *MAP2K4* and *RIT1* were most common in uterine sarcomas compared with the same contemporary MSK-IMPACT clinical cohort (Fig. 2C and D). Furthermore, *RIT1* was amplified at a significantly higher frequency in high-grade non-leiomyosarcomas at 24% (5/21), compared with only 2.5% (2/80) of uterine leiomyosarcomas (*P* = 0.004).

There were no significant differences in mutation patterns between primary and metastatic samples except for *PTEN* alterations which were more frequent in the metastasis samples (*P* = 0.046). This difference remained significant within the uterine leiomyosarcoma subset (*P* = 0.04). Only 11% of patients with uterine leiomyosarcoma harbored *MED12* mutations, an alteration present in an estimated 70% of benign uterine leiomyomas (20). The genomic landscape of LG-ESS (*n* = 4) and uterine STUMP cases (*n* = 2) had few oncogenic alterations, with only four identified likely oncogenic alterations across 3 patients (Fig. 2A). A total of 50.5% (50/99) of the high-grade uterine sarcomas (uterine leiomyosarcoma and high-grade non-leiomyosarcoma combined) displayed evidence of WGD (Supplementary Fig. S2). In contrast, none of the low-grade tumors displayed (WGD), supporting the association between WGD and high-grade uterine sarcomas (*P* = 0.04).

We identified two extreme outliers in terms of tumor mutational burden among the high-grade uterine leiomyosarcoma cases, hitherto referred to as hypermutated (Supplementary Fig. S3A). Both possessed MSI based upon MSIsensor analysis (Supplementary Fig. S3B). Using an orthogonal approach, mutational signature decomposition confirmed both cases as possessing MSI/MMR-D mutational signatures (Supplementary Fig. S3C). IHC identified loss of MSH2 protein expression in one case and MSH6 in the other. Neither case had somatic oncogenic alterations in these genes that would explain the MSI phenotype, implying that the cause of the MSI phenotype could be epigenetic or germline. Both patients had distant metastatic disease, were managed with both systemic cytotoxic and local therapies, achieved complete responses, and have remained disease-free 5.9 and 13 years from initial diagnosis. Neither received treatment with immune checkpoint inhibitors. Excluding the two MSI-H hypermutated cases, tumor mutation burden was higher for the remaining uterine leiomyosarcomas compared with high-grade non-leiomyosarcomas (2.5 mutations/Mb, range 0–7.9 and 1.1 mutations/Mb, range 0–10.6, respectively; *P* = 0.05). Following permanent anonymization (excluding the 2 patients with MSI

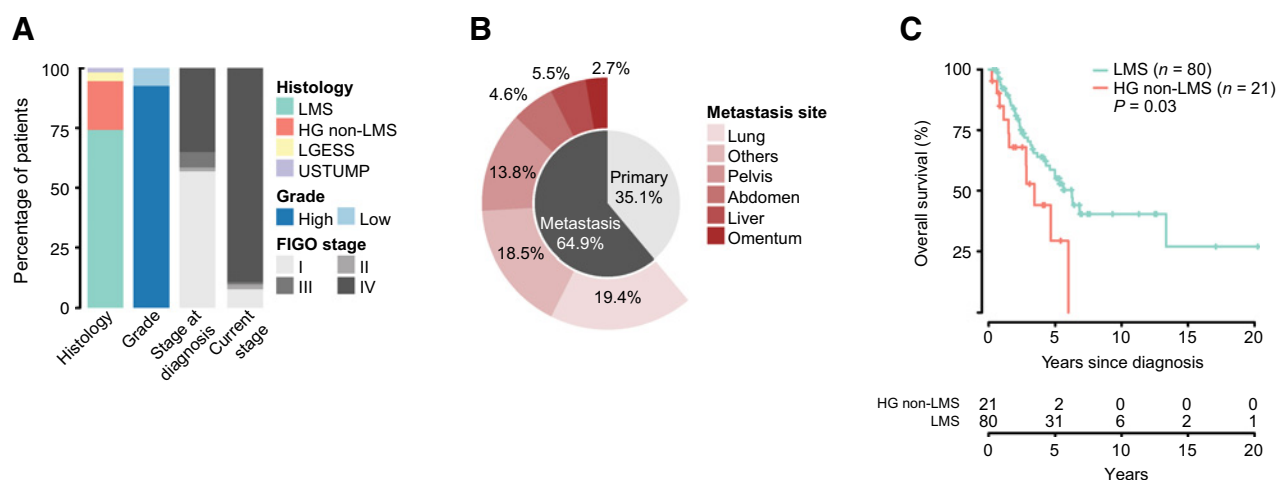


Figure 1. **A**, Composition of the MSK uterine sarcoma cohort by histology, grade, and stage. **B**, Distribution of the biopsied primary and metastatic disease sites and sample numbers in the cohort. **C**, Overall survival of high-grade uterine sarcoma cohort split by leiomyosarcoma (LMS) and HG non-leiomyosarcoma.

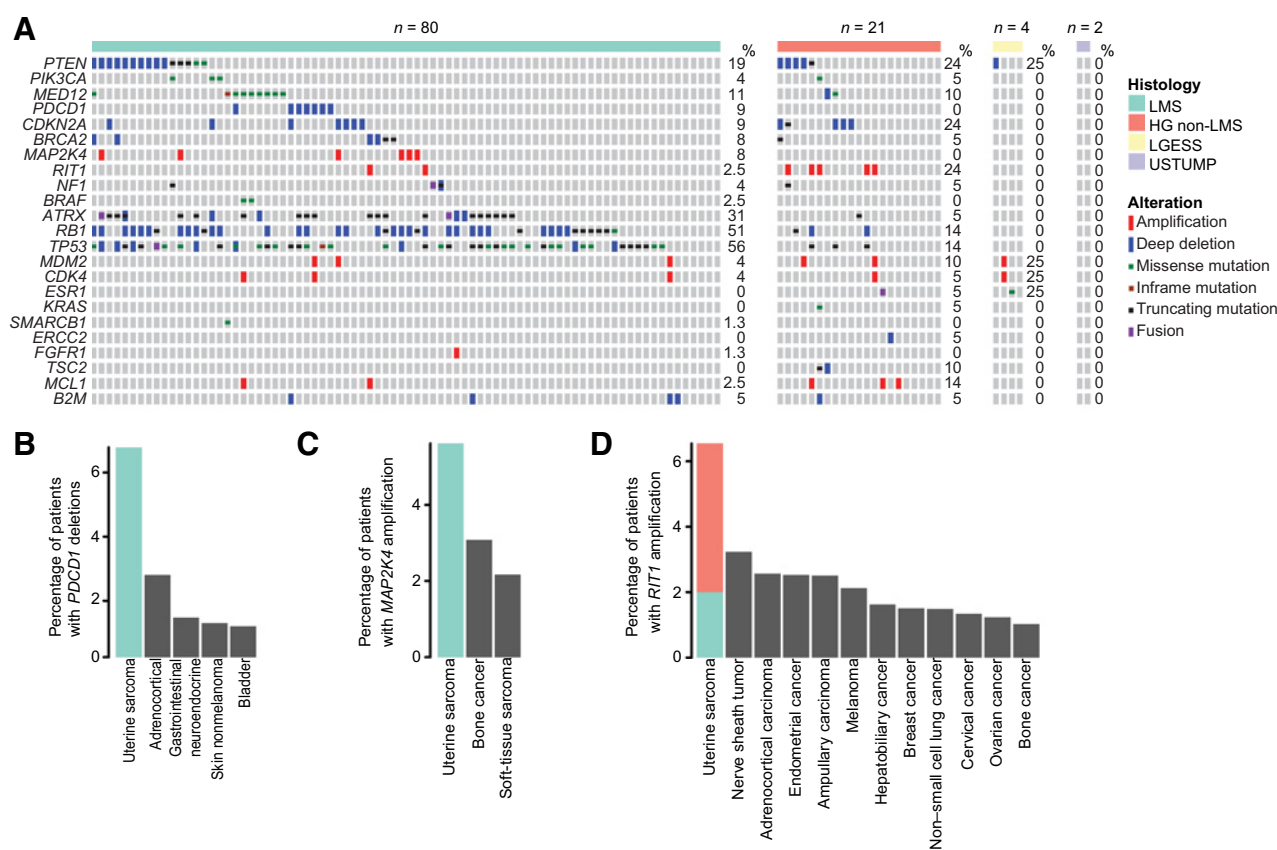


Figure 2. **A**, Oncoprint of genomic alterations in the cohort split by histology. Alterations represented were selected by the following criteria: (i) All actionable alterations (OncoKB); (ii) All genes with oncogenic alterations (OncoKB) in at least 5% of cases; (iii) An alteration type in a given gene was found to be most frequent in uterine sarcomas when compared with the contemporary MSK-IMPACT clinical series cohort of prospectively sequenced cancers ($n = 15,816$). **B**, Frequency of *PDCD1* homozygous deletions in the MSK-IMPACT clinical sequencing cohort compared with other cancer types with at least 25 cases and 1% altered cases. **C** and **D**, Frequency of *MAP2K4* and *RIT1* amplifications in the MSK-IMPACT clinical sequencing cohort compared with other cancer types with at least 25 cases and 1% altered cases.

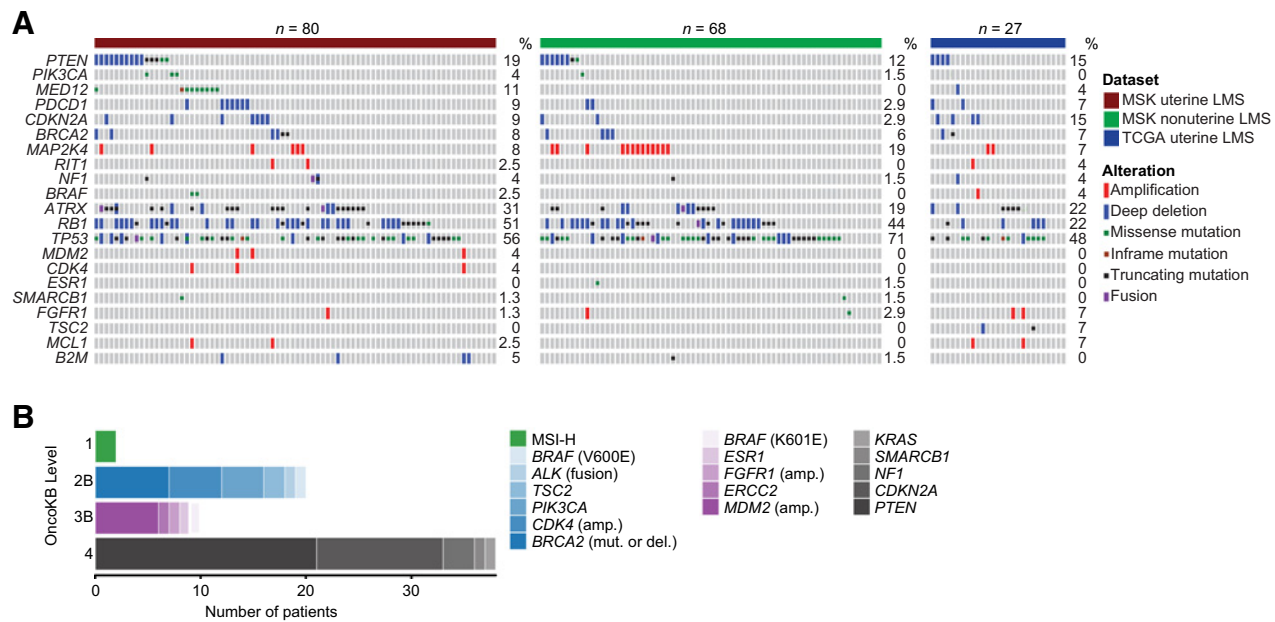


Figure 3. **A**, Comparison of genomic alterations across MSK uterine leiomyosarcoma (LMS), MSK nonuterine leiomyosarcoma, and TCGA uterine leiomyosarcoma. **B**, All clinically actionable alterations identified via MSK-IMPACT or MSK-Fusion, split by OncoKB levels of evidence.

phenotype), 2 patients were found to be carriers of pathogenic germline *TP53* mutations, one of which was accompanied by somatic biallelic inactivation of *TP53*. One of these patients was known to have Li-Fraumeni syndrome. No other known or likely pathogenic germline variants were identified in the anonymized analysis.

Genomic comparison of uterine versus non-uterine leiomyosarcoma

We next sought to determine how the genomic landscape of uterine leiomyosarcomas in our cohort ($n = 80$) differed from non-uterine leiomyosarcomas sequenced at MSK ($n = 68$; **Fig. 3A**). Alterations in *TP53* were significantly more common in non-uterine leiomyosarcoma, 71% (52/68) compared with uterine leiomyosarcoma 56% (45/80), $P = 0.01$. Similarly, *MAP2K4* was amplified at a higher frequency in non-uterine leiomyosarcoma 19% (13/68) compared with uterine leiomyosarcoma 8% (6/80), $P = 0.06$. Uterine leiomyosarcomas had a significantly higher frequency of *MED12* mutations, 11% (9/80) compared with non-uterine leiomyosarcomas where *MED12* alterations are absent, $P = 0.01$. Furthermore, in a comparison of uterine leiomyosarcomas from this study to those of a small cohort ($n = 27$) from TCGA, *RB1* alterations were significantly more frequent in the MSK cohort, 51% (41/80) versus 22% (6/27), $P = 0.02$.

Genomic alterations not prognostic for OS

To determine whether any of the alterations detected were prognostic for OS, we performed univariate Cox regression analysis on all USARC-relevant genes with oncogenic (or likely oncogenic) alterations in at least five of the leiomyosarcoma and high-grade non-leiomyosarcoma cases [LG-ESS and STUMP tumors were excluded from the survival analysis due to small sample size ($n = 6$) and their known long-survival prognoses]. Notably, none of the alterations in these genes, nor broader somatic features like WGD were associated with OS in this study cohort.

Therapeutic actionability and diagnostic utility

In addition to IMPACT sequencing, 7 patients received MSK-Fusion (a targeted multiplex RNA sequencing assay; ref. 8) as part of their diagnostic work-up (Supplementary Table S1). Overall, from IMPACT and MSK-Fusion, we identified potentially therapeutically actionable alterations in 45% of all patients profiled ($n = 48/107$; **Fig. 3B**). Among these was a tumor with an *LBH-ALK* fusion, which was initially missed by IMPACT DNA-based sequencing as the breakpoint was located in an intron not commonly targeted by *ALK* fusions found in lung cancers. Previously classified as an atypical uterine leiomyosarcoma, pathology rereview revealed a myxoid spindle cell neoplasm with moderate-to-severe nuclear pleomorphism, with IHC positive for smooth muscle actin and negative for desmin. The *ALK* fusion prompted revision of the diagnosis to inflammatory myofibroblastic tumor (IMT), a rare sarcoma subtype in which *ALK* fusions are characteristic (21). This patient was subsequently treated with an *ALK* inhibitor, crizotinib, and had radiographic stabilization of disease for 30+ months. Subsequent to the data freeze, a second uterine leiomyosarcoma was found to harbor an *ALK* fusion via IMPACT sequencing, again prompting review and reclassification as an IMT. This patient was treated with crizotinib, achieving a brief radiographic response followed by progression. The patient further progressed on the second-generation *ALK* inhibitor ceritinib. One patient had a *BCOR-ZC3H7B* fusion identified by IMPACT sequencing. This patient was originally diagnosed with a metastatic high-grade myxoid uterine leiomyosarcoma and survived for 3.4 years. *BCOR* mutations have been described as diagnostic markers of a specific subset of HG-ESSs, and as histologic mimickers of myxoid leiomyosarcoma (4, 22). In this case, genomic profiling led to reclassification of the tumor as a *BCOR*-mutated high-grade stromal sarcoma, which has implications for therapeutic choices because certain sarcoma chemotherapy agents are approved only for leiomyosarcoma, and clinical trial eligibility may be histology-specific. Additional diagnostically relevant fusions were identified in three more patients by MSK-Fusion—*YWHAE/NUTM2*

Downloaded from http://aacrjournals.org/clincancerres/article-pdf/26/14/3881/2060937/3881.pdf by guest on 16 April 2024

rearrangements in two high-grade, nonpleomorphic stromal sarcomas (3), and one *JAZF1-SUZ12* in a LG-ESS (23).

Additional potentially actionable alterations included seven *BRCA2* alterations [four homozygous deletions (all high-grade uterine leiomyosarcoma), three somatic *BRCA2* mutations (two high-grade uterine leiomyosarcoma, one high-grade non-leiomyosarcoma), two *BRAF*-activating mutations (V600E and K601E; both uterine leiomyosarcoma), two MSI tumors, and one *ESR1* Y537S ligand-binding domain mutation]. Overall, 17% (8/48) of patients received therapy matched to their potentially actionable genomic alteration. Two patients achieved radiographic responses, one achieved prolonged stable disease (the *ALK* fusion patient), and five experienced progression. One of the two patients who achieved a radiographic response to matched therapy had metastatic LG-ESS, treated with antiestrogen therapy for more than 20 years. Biopsy at progression confirmed *JAZF1* fusion-positive LG-ESS, and IMPACT detected an *ESR1* ligand-binding domain mutation (Y537S). Because *ESR1* mutations have been described in the context of estrogen receptor-positive breast cancer to confer ligand-independent signaling and thus resistance to aromatase inhibitors (24, 25), her hormonal therapy was changed to the selective estrogen modulator fulvestrant, resulting in tumor regression. The second patient to achieve radiographic response had high-grade uterine leiomyosarcoma with somatic *BRCA2* deletion. She was treated on a clinical trial with a PARP inhibitor, achieving an objective partial response lasting over 6 months.

Both *BRAF*-mutant patients received matched therapy. The *BRAF* V600-mutant patient was treated with an oral *BRAF* inhibitor on a basket trial, experiencing progression within 4 weeks. The patient with the *BRAF* K601E mutation, a class 2 dimer-dependent *BRAF* mutant which has been previously biologically characterized and is resistant to first-generation *BRAF* inhibitors (26), was enrolled on a clinical trial of a pan-RAF inhibitor. Her best response was stable disease lasting 4 months. As detailed above, both patients with MSI-H high-grade leiomyosarcoma remained disease-free following multimodality management of metastatic disease and have not received immune checkpoint inhibitor treatment.

Given the activity of PARP inhibitors in *BRCA*-mutated advanced breast and ovarian cancers (27, 28), we sought to validate the actionability of *BRCA2* alterations that our analysis identified as common in patients with uterine leiomyosarcoma. Post data freeze, five subsequent patients with high-grade uterine leiomyosarcoma with *BRCA2* alterations were identified by routine clinical MSK-IMPACT testing (three with somatic biallelic inactivation and one each with a somatic and germline truncating mutations accompanied by LOH). Four received PARP inhibitor-containing therapy as part of various clinical trials, and the remaining patient harboring a germline *BRCA2* mutation received PARP inhibitor off-label. As with the *BRCA2*-altered patient with uterine leiomyosarcoma from the study cohort, all five had at least some radiographic regression, including one patient who achieved a complete radiographic response with treatment durations ranging from 6 to 28 months (2 of 5 patients remain on therapy at the time of submission). These results demonstrate the potential actionability of *BRCA2* alterations in uterine leiomyosarcoma and the potential durability of responses.

Discussion

Uterine sarcomas are a histologically and clinically heterogeneous group of tumors. A subset of uterine sarcomas have distinct molecular diagnostic characteristics (e.g., fusion rearrangements involving *JAZF1* in LG-ESS and *YWHAE/NUTM2* rearrangements in high-

grade, nonpleomorphic stromal sarcomas). However, leiomyosarcoma, the most common histologic subtype of uterine sarcoma, has complex karyotypes with numerous structural aberrations and lacks a characteristic translocation or single driving or defining mutation (29, 30). Three core molecular mechanisms in sarcomagenesis have been described for soft-tissue sarcomas. These include DNA copy-number alterations, somatic mutations in key signaling pathways, and transcriptional dysregulation from chimeric transcriptional factors (31). In our cohort of uterine sarcomas, we found evidence to support these three molecular mechanisms for sarcomagenesis.

Findings of clinical utility included *BCOR* rearrangement for more precise diagnosis, detection of potentially actionable mutations in *ALK*, *BRAF*, *ESR1*, and *BRCA2*, and identification of MSI-H tumors, each of which could guide selection of FDA-approved therapies or influence clinical trial eligibility. The discovery of the *BCOR* fusion illustrates that prospective molecular characterization can lead to refinements in histologic classifications or distinguish among challenging histologic appearances such as true myxoid or epithelioid leiomyosarcoma from high-grade stromal sarcomas. Moreover, the further subclassification of HG-ESSs into either *YWHAE* or *BCOR* altered cases will ultimately facilitate studies to determine their prognostic or therapeutic implications. Prolonged disease stabilization with an *ALK* inhibitor in the patient with an *ALK* fusion sarcoma is consistent with recent results of a phase II trial of crizotinib in IMT in which 50% of *ALK*-positive patients achieved an objective response (32). The frequency of *MED12* mutations in patients with uterine leiomyosarcoma (11%) was much lower than one would expect if uterine leiomyosarcoma commonly evolved from antecedent benign leiomyomas, which harbor *MED12* mutations in approximately 70% of cases. This finding suggests that uterine leiomyosarcoma may not evolve from antecedent benign leiomyomas, but rather arise independently as *de novo* cancers. This observation may have potential clinical implications because women with stable-appearing leiomyomas on imaging may be reassured; however, new and growing uterine masses may be considered more concerning for harboring malignancy.

In total, prospective sequencing yielded diagnostic and therapeutic information with clinical utility for at least 17% of sequenced patients. Although actionable mutations were identified in 45% of patients only 17% (7% of the whole cohort) of those received matched therapy, so the broader therapeutic relevance of these data will require further research. Given the complex chromosomal abnormalities characteristic of uterine sarcomas, it will be a continuing challenge to characterize mutations to be either likely drivers or passengers.

Our data, albeit limited, indicate that clinical response to *BRAF* inhibition in *BRAF*-mutant uterine leiomyosarcoma may be modest. In contrast, the prolonged disease control achieved with PARP inhibition among the 6 patients with IMPACT detected *BRCA2* alterations, which occur in 8% of high-grade uterine leiomyosarcomas, suggests that *BRCA2* may be a therapeutically relevant target. Recent work has highlighted the importance of lineage specificity of *BRCA* dependency in relation to PARP response (19), and there is growing evidence to ascribe uterine sarcomas as a *BRCA*-related tumor type. In addition to relatively high incidences of homozygous deletions in *BRCA2*, *BRCA1* promoter hypermethylation as a potential mechanism of *BRCA1* downregulation in uterine leiomyosarcoma (33) and other hallmarks of “*BRCA*ness” such as homologous recombination deficiency (HRD) mutational signatures (5) have been identified in uterine sarcomas. It seems likely that a subset of uterine sarcomas, in particular uterine leiomyosarcomas, may be driven by HRD, and given the responses seen in *BRCA*-positive tumors to PARP inhibition, *BRCA* testing on all

patients seems justified. However, whether *BRCA1* promotor hypermethylated uterine sarcoma tumors would respond to PARP inhibition requires further investigation, not least identifying whether hypermethylation of the *BRCA1* promotor leads to an HRD phenotype in uterine leiomyosarcoma tumors. Unlike other established BRCA-related tumor types, uterine sarcomas seem to almost exclusively harbor *BRCA2* DNA alterations.

Genomic alterations such as *RIT1* and *MAP2K4* amplifications, despite their association with poor prognosis and other phenotypes in other cancer types (34–37), were not associated with prognostic differences in our cohort. None of the common oncogenic or likely oncogenic genomic alterations in uterine sarcoma genes were associated with prognosis in the study cohort. Similarly, although WGD was present in more than half of high-grade sarcomas, WGD was not associated with OS. In a recent study of undifferentiated uterine sarcomas, high DNA copy-number variation was found in 62% (25/40 cases), but did not have statistically significant association with poorer OS (38). In contrast, the 2 patients with MSI-H disease both achieved complete responses with multimodality interventions and have had long disease-free survivals, suggesting that MSI-H may be prognostic for chemotherapy sensitivity and/or disease-free survival in uterine leiomyosarcoma. Furthermore, our cohort identified *PDCD1* deletions as more common in uterine leiomyosarcoma than in non-uterine leiomyosarcoma. Such discrepancies may be relevant given the paucity of objective responses seen in phase II trials of immunotherapeutic agents in uterine leiomyosarcoma (39, 40).

Our study illustrates the complementary value of specialized gynecologic pathology review coupled with molecular characterization of patient tumors. Detecting rare or pathognomonic fusions can refine uterine sarcoma diagnoses, as previous reports have indicated for high-grade endometrial sarcomas and myxoid mesenchymal uterine tumors (41, 42). However, incorporating the iterative changes in pathologic classification as new molecular diagnostic technologies become available will be an ongoing challenge. Key considerations in terms of the generalizability of our findings include the fact that all patients in the cohort had to be alive to enroll in the study and have their tumors sequenced. Thus, the cohort may overrepresent patients with a more favorable survival who were able to seek consultation and care at a comprehensive cancer center. The absence of prognostically significant genomic alterations may be due to the clinical characteristics of the study cohort, which is likely biased to include patients with favorable survival. Patients who die very shortly after diagnosis may be underrepresented, and their tumors may have a different genomic profile.

References

- Nucci MR, Harburger D, Koontz J, Dal Cin P, Sklar J. Molecular analysis of the JAZF1-JJAZ1 gene fusion by RT-PCR and fluorescence *in situ* hybridization in endometrial stromal neoplasms. *Am J Surg Pathol* 2007; 31:65–70.
- Lee CH, Ou WB, Marino-Enriquez A, Zhu M, Mayeda M, Wang Y, et al. 14-3-3 fusion oncogenes in high-grade endometrial stromal sarcoma. *Proc Natl Acad Sci U S A* 2012;109:929–34.
- Lee CH, Marino-Enriquez A, Ou W, Zhu M, Ali RH, Chiang S, et al. The clinicopathologic features of YWHAE-FAM22 endometrial stromal sarcomas: a histologically high-grade and clinically aggressive tumor. *Am J Surg Pathol* 2012; 36:641–53.
- Lewis N, Soslow RA, Delair DF, Park KJ, Murali R, Hollmann TJ, et al. ZC3H7B-BCOR high-grade endometrial stromal sarcomas: a report of 17 cases of a newly defined entity. *Mod Pathol* 2018;31:674–84.
- Chudasama P, Mughal SS, Sanders MA, Hubschmann D, Chung I, Deeg KI, et al. Integrative genomic and transcriptomic analysis of leiomyosarcoma. *Nat Commun* 2018;9:144.
- Cheng DT, Mitchell TN, Zehir A, Shah RH, Benayed R, Syed A, et al. Memorial sloan kettering-integrated mutation profiling of actionable cancer targets (MSK-IMPACT): a hybridization capture-based next-generation sequencing clinical assay for solid tumor molecular oncology. *J Mol Diagn* 2015;17:251–64.
- Zehir A, Benayed R, Shah RH, Syed A, Middha S, Kim HR, et al. Mutational landscape of metastatic cancer revealed from prospective clinical sequencing of 10,000 patients. *Nat Med* 2017;23:703–13.
- Benayed R, Offin M, Mullaney K, Sukhadia P, Rios K, Desmeules P, et al. High yield of RNA sequencing for targetable kinase fusions in lung adenocarcinomas with no mitogenic driver alteration detected by DNA sequencing and low tumor mutation burden. *Clin Cancer Res* 2019;25:4712–22.

In conclusion, analysis of this large cohort of patients with uterine sarcomas demonstrates that genomic profiling can provide clinical utility for patients, contributing to genome-driven diagnostic precision and elucidating potential novel treatment options for a subset of patients.

Disclosure of Potential Conflicts of Interest

M.L. Hensley is a paid consultant for Research To Practice, Up To Date, GOG Foundation, Tesaro, Lilly Oncology, and Merck, and reports an immediate family member's employment with Sanofi. D.B. Solit is an employee/paid consultant for Pfizer, Lilly Oncology, LOXO Oncology, Illumina, QED Therapeutics, and Vivideon Therapeutics. R. Soslow is an employee/paid consultant for Ebix/Oakstone. B.S. Taylor reports receiving other commercial research support from and reports receiving speakers bureau honoraria from Genentech, and is an advisory board member/unpaid consultant for Boehringer Ingelheim and LOXO Oncology. D.M. Hyman is an employee/paid consultant for Eli Lilly, LOXO Oncology, Chugai Pharma, Boehringer Ingelheim, AstraZeneca, Pfizer, Bayer, Genentech, Kinnate/Fount, and Eli Lilly, and reports receiving commercial research grants from AstraZeneca, Puma Biotechnology, LOXO Oncology and Bayer. No potential conflicts of interest were disclosed by the other authors.

Authors' Contributions

Conception and design: M.L. Hensley, D.B. Solit, B.S. Taylor, M.T.A. Donoghue, D.M. Hyman

Development of methodology: D.B. Solit, P. Srinivasan, M.T.A. Donoghue, D.M. Hyman

Acquisition of data (provided animals, acquired and managed patients, provided facilities, etc.): M.L. Hensley, D.B. Solit, R. Soslow, A.A. Jungbluth, W.D. Tap, M.T.A. Donoghue, D.M. Hyman

Analysis and interpretation of data (e.g., statistical analysis, biostatistics, computational analysis): M.L. Hensley, S.S. Chavan, D.B. Solit, R. Murali, C. Bandlamudi, P. Srinivasan, W.D. Tap, B.S. Taylor, M.T.A. Donoghue, D.M. Hyman

Writing, review, and/or revision of the manuscript: M.L. Hensley, S.S. Chavan, D.B. Solit, R. Murali, R. Soslow, S. Chiang, P. Srinivasan, W.D. Tap, E. Rosenbaum, B.S. Taylor, M.T.A. Donoghue, D.M. Hyman

Administrative, technical, or material support (i.e., reporting or organizing data, constructing databases): M.L. Hensley, D.B. Solit, W.D. Tap

Study supervision: D.B. Solit, M.T.A. Donoghue, D.M. Hyman

Acknowledgments

This work is supported in part by the NIH/NCI MSK Cancer Center Support Grant P30 CA008748 (institutional support covering all MSK faculty).

The costs of publication of this article were defrayed in part by the payment of page charges. This article must therefore be hereby marked *advertisement* in accordance with 18 U.S.C. Section 1734 solely to indicate this fact.

Received December 3, 2019; revised March 16, 2020; accepted April 10, 2020; published first April 16, 2020.

9. Niu B, Ye K, Zhang Q, Lu C, Xie M, McLellan MD, et al. MSIsensor: microsatellite instability detection using paired tumor-normal sequence data. *Bioinformatics* 2014;30:1015–6.
10. Middha S, Zhang L, Nafa K, Jayakumaran G, Wong D, Kim HR, et al. Reliable pan-cancer microsatellite instability assessment by using targeted next-generation sequencing data. *JCO Precis Oncol* 2017;2017.
11. Alexandrov LB, Nik-Zainal S, Wedge DC, Aparicio SA, Behjati S, Biankin AV, et al. Signatures of mutational processes in human cancer. *Nature* 2013;500:415–21.
12. Shen R, Seshan VE. FACETS: allele-specific copy number and clonal heterogeneity analysis tool for high-throughput DNA sequencing. *Nucleic Acids Res* 2016;44:e131.
13. Bielski CM, Zehir A, Penson AV, Donoghue MTA, Chatila W, Armenia J, et al. Genome doubling shapes the evolution and prognosis of advanced cancers. *Nat Genet* 2018;50:1189–95.
14. McGranahan N, Favero F, de Bruin EC, Birkbak NJ, Szallasi Z, Swanton C. Clonal status of actionable driver events and the timing of mutational processes in cancer evolution. *Sci Transl Med* 2015;7:283ra54.
15. Cheng DT, Prasad M, Chekaluk Y, Benayed R, Sadowska J, Zehir A, et al. Comprehensive detection of germline variants by MSK-IMPACT, a clinical diagnostic platform for solid tumor molecular oncology and concurrent cancer predisposition testing. *BMC Med Genomics* 2017;10:33.
16. Mandelker D, Zhang L, Kemel Y, Stadler ZK, Joseph V, Zehir A, et al. Mutation detection in patients with advanced cancer by universal sequencing of cancer-related genes in tumor and normal DNA vs guideline-based germline testing. *JAMA* 2017;318:825–35.
17. Chakravarty D, Gao J, Phillips SM, Kundra R, Zhang H, Wang J, et al. OncoKB: a precision oncology knowledge base. *JCO Precis Oncol* 2017.
18. Comprehensive and integrated genomic characterization of adult soft tissue sarcomas. *Cell* 2017;171:950–65.
19. Jonsson P, Bandlamudi C, Cheng ML, Srinivasan P, Chavan SS, Friedman ND, et al. Tumour lineage shapes BRCA-mediated phenotypes. *Nature* 2019;571:576–9.
20. Makinen N, Mehine M, Tolvanen J, Kaasinen E, Li Y, Lehtonen HJ, et al. MED12, the mediator complex subunit 12 gene, is mutated at high frequency in uterine leiomyomas. *Science* 2011;334:252–5.
21. Mohammad N, Haimes JD, Mishkin S, Kudlow BA, Leong MY, Chew SH, et al. ALK is a specific diagnostic marker for inflammatory myofibroblastic tumor of the uterus. *Am J Surg Pathol* 2018;42:1353–9.
22. Hoang LN, Aneja A, Conlon N, Delair DF, Middha S, Benayed R, et al. Novel high-grade endometrial stromal sarcoma: a morphologic mimicker of myxoid leiomyosarcoma. *Am J Surg Pathol* 2017;41:12–24.
23. Koontz JI, Soreng AL, Nucci M, Kuo FC, Pauwels P, van Den Berghe H, et al. Frequent fusion of the JAZF1 and JJAZ1 genes in endometrial stromal tumors. *Proc Natl Acad Sci U S A* 2001;98:6348–53.
24. Bardia A, Iafate JA, Sundaresan T, Younger J, Nardi V. Metastatic breast cancer with ESR1 mutation: clinical management considerations from the Molecular and Precision Medicine (MAP) Tumor Board at Massachusetts General Hospital. *Oncologist* 2016;21:1035–40.
25. Friebens C, O'Leary B, Kilburn L, Hrebien S, Garcia-Murillas I, Beaney M, et al. Plasma ESR1 mutations and the treatment of estrogen receptor-positive advanced breast cancer. *J Clin Oncol* 2016;34:2961–8.
26. Yao Z, Yaeger R, Rodrik-Outmezguine VS, Tao A, Torres NM, Chang MT, et al. Tumours with class 3 BRAF mutants are sensitive to the inhibition of activated RAS. *Nature* 2017;548:234–8.
27. Oza AM, Tinker AV, Oaknin A, Shapira-Frommer R, McNeish IA, Swisher EM, et al. Antitumor activity and safety of the PARP inhibitor rucaparib in patients with high-grade ovarian carcinoma and a germline or somatic BRCA1 or BRCA2 mutation: integrated analysis of data from Study 10 and ARIEL2. *Gynecol Oncol* 2017;147:267–75.
28. Robson M, Im SA, Senkus E, Xu B, Domchek SM, Masuda N, et al. Olaparib for metastatic breast cancer in patients with a germline BRCA mutation. *N Engl J Med* 2017;377:523–33.
29. Gibault L, Perot G, Chibon F, Bonnin S, Lagarde P, Terrier P, et al. New insights in sarcoma oncogenesis: a comprehensive analysis of a large series of 160 soft tissue sarcomas with complex genomics. *J Pathol* 2011;223:64–71.
30. Halbweil I, Ullmann R, Kremser ML, Man YG, Isadi-Moud N, Lax S, et al. Chromosomal alterations in low-grade endometrial stromal sarcoma and undifferentiated endometrial sarcoma as detected by comparative genomic hybridization. *Gynecol Oncol* 2005;97:582–7.
31. Taylor BS, Barretina J, Maki RG, Antonescu CR, Singer S, Ladanyi M. Advances in sarcoma genomics and new therapeutic targets. *Nat Rev Cancer* 2011;11:541–57.
32. Schoffski P, Sufliarsky J, Gelderblom H, Blay JY, Strauss SJ, Stacchiotti S, et al. Crizotinib in patients with advanced, inoperable inflammatory myofibroblastic tumours with and without anaplastic lymphoma kinase gene alterations (European Organisation for Research and Treatment of Cancer 90101 CREATE): a multicentre, single-drug, prospective, non-randomised phase 2 trial. *Lancet Respir Med* 2018;6:431–41.
33. Xing D, Scangas G, Nitta M, He L, Xu X, Ioffe YJ, et al. A role for BRCA1 in uterine leiomyosarcoma. *Cancer Res* 2009;69:8231–5.
34. Finegan KG, Tournier C. The mitogen-activated protein kinase kinase 4 has a pro-oncogenic role in skin cancer. *Cancer Res* 2010;70:5797–806.
35. Li JT, Liu W, Kuang ZH, Chen HK, Li DJ, Feng QS, et al. [Amplification of RIT1 in hepatocellular carcinoma and its clinical significance]. *Ai Zheng* 2003;22:695–9.
36. Pavese JM, Ogden IM, Voll EA, Huang X, Xu L, Jovanovic B, et al. Mitogen-activated protein kinase kinase 4 (MAP2K4) promotes human prostate cancer metastasis. *PLoS One* 2014;9:e102289.
37. Xu F, Sun S, Yan S, Guo H, Dai M, Teng Y. Elevated expression of RIT1 correlates with poor prognosis in endometrial cancer. *Int J Clin Exp Pathol* 2015;8:10315–24.
38. Binzer-Panchal A, Hardell E, Viklund B, Ghaderi M, Bosse T, Nucci MR, et al. Integrated molecular analysis of undifferentiated uterine sarcomas reveals clinically relevant molecular subtypes. *Clin Cancer Res* 2019;25:2155–65.
39. Ben-Ami E, Barysaukas CM, Solomon S, Tahlil K, Malley R, Hohos M, et al. Immunotherapy with single agent nivolumab for advanced leiomyosarcoma of the uterus: results of a phase 2 study. *Cancer* 2017;123:3285–90.
40. Tawbi HA, Burgess M, Bolejack V, Van Tine BA, Schuetze SM, Hu J, et al. Pembrolizumab in advanced soft-tissue sarcoma and bone sarcoma (SARC028): a multicentre, two-cohort, single-arm, open-label, phase 2 trial. *Lancet Oncol* 2017;18:1493–501.
41. Busca A, Parra-Herran C. Myxoid mesenchymal tumors of the uterus: an update on classification, definitions, and differential diagnosis. *Adv Anat Pathol* 2017;24:354–61.
42. Hoang L, Chiang S, Lee CH. Endometrial stromal sarcomas and related neoplasms: new developments and diagnostic considerations. *Pathology* 2018;50:162–77.