

REFERENCES

1. Saußele S, Krauß MP, Hehlmann R, et al. Impact of comorbidities on overall survival in patients with chronic myeloid leukemia: results of the randomized CML Study IV. *Blood*. 2015;126(1):42-49.
2. Viganò I, Di Giacomo N, Bozzani S, Antolini L, Piazza R, Gambacorti Passerini C. First-line treatment of 102 chronic myeloid leukemia patients with imatinib: a long-term single institution analysis. *Am J Hematol*. 2014;89(10):E184-E187.
3. Hehlmann R, Lauseker M, Jung-Munkwitz S, et al. Tolerability-adapted imatinib 800 mg/d versus 400 mg/d versus 400 mg/d plus interferon- α in newly diagnosed chronic myeloid leukemia. *J Clin Oncol*. 2011;29(12):1634-1642.
4. Charlson ME, Pompei P, Ales KL, MacKenzie CR. A new method of classifying prognostic comorbidity in longitudinal studies: development and validation. *J Chronic Dis*. 1987;40(5):373-383.
5. Larson RA, Hochhaus A, Hughes TP, et al. Nilotinib vs imatinib in patients with newly diagnosed Philadelphia chromosome-positive chronic myeloid leukemia in chronic phase: ENESTnd 3-year follow-up. *Leukemia*. 2012;26(10):2197-2203.
6. Jabbour E, Kantarjian HM, Saglio G, et al. Early response with dasatinib or imatinib in chronic myeloid leukemia: 3-year follow-up from a randomized phase 3 trial (DASISION). *Blood*. 2014;123(4):494-500.

© 2015 by The American Society of Hematology

● ● ● LYMPHOID NEOPLASIA

Comment on Bonzheim et al, page 76

Look into my eyes, please

Maurilio Ponzoni VITA-SALUTE UNIVERSITY SAN RAFFAELE

In this issue of *Blood*, Bonzheim et al have reported the diagnostic value of the assessment of *MYD88 L265P (MYD88)* mutations in vitreoretinal lymphoma.¹ In general terms, the diagnosis of lymphoma classically requires standard histopathologic, immunophenotypic, genetic, and molecular criteria that are combined to a variable extent to define individual clinicopathologic entities recognized by World Health Organization classification. These gold standard requisites may not be fulfilled in some rare particular instances, resulting in diagnostic difficulties. One challenging example of this latter occurrence is represented by vitreoretinal diffuse large B-cell lymphoma. The identification of vitreoretinal diffuse large B-cell lymphoma is crucial for 2 main reasons. First, this type of lymphoma is particularly aggressive and must be distinguished from low-grade marginal-zone B-cell lymphomas of the choroid, and second, vitreoretinal diffuse large B-cell lymphoma could represent the intraocular dissemination of a concomitant diffuse large B-cell lymphoma of the central nervous system (PCNSL). PCNSL is another and more frequent type of aggressive B-cell lymphoma that needs to be promptly recognized and treated.

Easy morphologic diagnosis is not the rule in vitreoretinal diffuse large B-cell lymphoma; in fact, the evaluable material is usually obtained by vitreous body aspirate, and this implies that cytologic instead of histologic assessment is often performed in routine practice. Moreover, the diagnosis is further hampered by the low number of cells, the poor conservative status of these free-floating elements in the vitreous, and the prevalent admixture of non-neoplastic components, including smaller lymphocytes. Clearly enough, the most difficult differential diagnosis arises with uveitis and infections. Useful diagnostic tools mainly used in systemic lymphomas, such as flow cytometry and molecular biology, have a limited

value in vitreoretinal diffuse large B-cell lymphoma. This is mainly a result of the overall limited amount of material in the case of flow cytometry and the risk of detecting pseudoclonal/oligoclonal B-cell populations by polymerase chain reaction owing to the few cells occurring in the vitreous. Importantly, this latter occurrence may be encountered also in benign/reactive conditions, thus increasing the difficulty in diagnosing vitreoretinal diffuse large B-cell lymphoma. A significant achievement has been reached with the demonstration that increased IL-10 levels are associated with vitreoretinal diffuse large B-cell lymphoma,² but not all diagnostic laboratories are equipped to measure these levels.

On these grounds, Bonzheim et al introduce a new strategy able to improve the diagnostic accuracy of vitreoretinal diffuse large B-cell lymphoma, through the detection of *MYD88* mutations in vitreous aspirates of patients suspected of having vitreoretinal diffuse large B-cell lymphoma. Some cases interpreted as reactive with currently available techniques were reclassified as neoplastic on the basis of the presence of *MYD88* mutations and, most importantly, their malignant nature was confirmed by clinical follow-up. Although comparative studies on the diagnostic accuracy between IL-10 levels and *MYD88* mutations deserve to be tested in a prospective study, the strategy of the detection of *MYD88* mutations is particularly attractive. In fact, it should be taken into account that these molecular assessments are usually already in use within well-equipped diagnostic hematopathology laboratories, because they are equally useful for the recognition of some lymphoproliferative disorders such as lymphoplasmacytic lymphomas often associated with Waldenström macroglobulinemia and diffuse large B-cell neoplasms of activated B-cell-like type, mostly represented by testicular lymphomas, PCNSL, and “leg-type” entities of the skin.³ Therefore, no additional technical efforts would be required to better diagnose vitreoretinal diffuse large B-cell lymphoma.

The results herein provided have further implications. In fact, 65% to 90% of patients with vitreoretinal diffuse large B-cell lymphoma eventually progress to PCNSL,² and thus it appears critical to assess lymphomatous involvement of the vitreous to properly treat these patients. Another critical feature is that this concept could be extended also to vitreoretinal involvement by systemic or extranodal lymphomas, as confirmed by the experience of Bonzheim et al,¹ who reported the intraocular dissemination by 2 cases of primary testicular lymphomas without a concomitant PCNSL. Because one of these patients developed mutated *MYD88* vitreoretinal diffuse large B-cell lymphoma 10 years after the diagnosis of a testicular lymphoma carrying the identical mutation, these results show that this molecular approach also deserves to be tested as a powerful method to detect late relapses and assess the prognostic implications of the occurrence of *MYD88* mutations in the vitreous of patients with testicular lymphomas.

Taken together, these issues point toward the need for prospective studies aimed at assessing the actual clinical impact of the detection of *MYD88* mutations in primary and secondary vitreoretinal diffuse large B-cell lymphoma.

Conflict-of-interest disclosure: The author declares no competing financial interests. ■

REFERENCES

1. Bonzheim I, Giese S, Deuter C, et al. High frequency of *MYD88* mutations in vitreoretinal B-cell lymphoma:

a valuable tool to improve diagnostic yield of vitreous aspirates. *Blood*. 2015;126(1):76-79.

2. Chan CC, Rubenstein JL, Coupland SE, et al. Primary vitreoretinal lymphoma: a report from an International Primary Central Nervous System Lymphoma Collaborative Groups symposium. *Oncologist*. 2011;16(11):1589-1599.

3. Pham-Ledard A, Beylot-Barry M, Barbe C, et al. High frequency and clinical prognostic value of *MYD88* L265P mutation in primary cutaneous diffuse large B-cell lymphoma, leg-type. *JAMA Dermatol*. 2014;150(11):1173-1179.

© 2015 by The American Society of Hematology

whereas the proline serine threonine phosphatase interacting protein (PSTPIP) subfamily member, PSTPIP1, finely tunes WASP activity by mediating its interaction with and dephosphorylation by the nonreceptor protein tyrosine phosphatase, PTPN12.² Extensive research has focused on the role of F-BAR proteins in the development and homeostasis of the nervous system. However, although well represented in the hematopoietic system,² their functions in blood cells are less understood.

PACSINs (also known as syndapins) are F-BAR proteins that control multiple processes, including the generation of membrane curvature, the assembly and fission of caveolae and actin, and microtubule polymerization, which are important for morphogenesis, endocytosis, synaptic vesicle recycling, cell migration, and cytokinesis.⁴ PACSINs have 3 structurally different isoforms that differ in their biochemical properties and patterns of expression, reflecting different tissue-specific functions.^{2,4}

The demarcation membrane system (DMS) of megakaryocytes forms the plasma membrane of future platelets. During megakaryocyte maturation, development of the DMS is initiated by focal tubular membrane invagination at the cell periphery followed by expansion of the tubular membranes through membrane delivery from the Golgi complex and endoplasmic reticulum-mediated lipid transfer. This gives rise to an extensive intracellular membrane network that remains continuous with the cell surface.⁵ Begonja et al show that the ubiquitously expressed PACSIN2

● ● ● PLATELETS AND THROMBOPOIESIS

Comment on Begonja et al, page 80

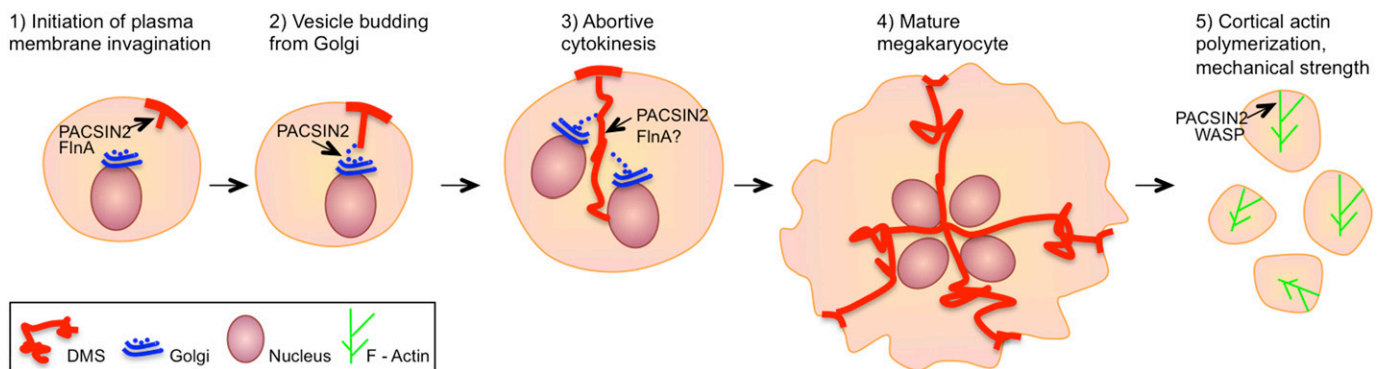
PACSIN2: a BAR-rier forming the megakaryocyte DMS

Violeta Chitu and E. Richard Stanley ALBERT EINSTEIN COLLEGE OF MEDICINE

In this issue of *Blood*, Begonja et al describe a role for the membrane sculpting protein PACSIN2 (protein kinase C and casein kinase II substrate 2 in neurons) in membrane organization in megakaryocytes and platelets.¹

F-BAR (Fes-CIP4 homology [FCH] Bin-amphiphysin-Rvs) proteins are structurally well-characterized proteins that mediate the formation of complex membrane structures by binding membranes through their conserved amino-terminal F-BAR domains.² Many of these proteins have adaptor functions mediated by their carboxy-terminal muniscin homology (μ HD) or Src homology 3 (SH3) domains. FCH-only proteins, FCHo1 and FCHo2, initiate the formation of

clathrin-coated pits and recruit components of the endocytic machinery through their μ HD domains, thus acting both as membrane-sculpting proteins and endocytic hubs.³ Through their SH3 domains, other F-BAR family members, such as the PACSINs and CIP4 (Cdc42-interacting protein 4), recruit and activate members of the Wiskott-Aldrich syndrome (WASP) family of proteins, thus coordinating membrane reshaping with cytoskeletal remodeling,



Proposed roles of PACSIN2 in megakaryocyte and platelet biology. (1) DMS formation is initiated by the activation of PACSIN2 tubulating activity by FlnA, leading to focal plasma membrane invagination. (2) PACSIN2 promotes vesicle budding from Golgi, thus facilitating the expansion of the DMS network. PACSIN normally localizes to the cleavage furrow of mitotic cells, where it couples the actomyosin contractile ring to the plasma membrane. (3-4) During megakaryocyte endomitosis, PACSIN2 could recruit FlnA that may decrease actomyosin activity, leading to abortive cytokinesis and multinucleation. (5) In platelets, PACSIN could support plasma membrane stability by activating WASP in the vicinity of the plasma membrane, thus promoting the polymerization of cortical actin.