

Dichotomous ALK-IHC Is a Better Predictor for ALK Inhibition Outcome than Traditional ALK-FISH in Advanced Non-Small Cell Lung Cancer



A.J. van der Wekken¹, R. Pelgrim², N. 't Hart², N. Werner², M.F. Mastik², L. Hendriks³, E.H.F.M. van der Heijden⁴, M. Looijen-Salamon⁵, A.J. de Langen⁶, J. Staal-van den Brekel⁷, S. Riemersma⁸, B.E. van den Borne⁹, E.J.M. Speel¹⁰, A-M.C. Dingemans³, T.J.N. Hiltermann¹, A. van den Berg², W. Timens², E. Schuuring², and H.J.M. Groen¹

Abstract

Purpose: ALK rearrangement detection using FISH is the standard test to identify patients with non-small cell lung carcinoma (NSCLC) eligible for treatment with ALK inhibitors. Recently, ALK protein expression in resectable NSCLC showed predictive value. We evaluated tumor response rate and survival after crizotinib treatment of patients with advanced NSCLC with ALK activation using both dichotomous immunohistochemical (IHC) staining and FISH.

Experimental Design: Patients with stage IV NSCLC treated with crizotinib were selected. Tumor response was assessed. ALK rearrangements were detected by FISH (Vysis ALK-break-apart FISH-Probe KIT) and IHC [Ventana ALK (D5F3) CDx assay]. Cohorts of patients with ALK-FISH-positive advanced NSCLC from four other hospitals were used for validation.

Results: Twenty-nine consecutive patients with ALK-positive advanced NSCLC diagnosed by FISH and/or IHC on small biopsies or fine-needle aspirations (FNA) were treated with ALK

inhibitors. All ALK-IHC-positive patients responded to crizotinib except three with primary resistance. No tumor response was observed in 13 ALK-FISH-positive but ALK-IHC-negative patients. This was confirmed in an external cohort of 16 patients. Receiver operator characteristic (ROC) curves for ALK-IHC and ALK-FISH compared with treatment outcome showed that dichotomous ALK-IHC outperforms ALK-FISH [tumor response area under the curve: (AUC), 0.86 vs. 0.64, $P = 0.03$; progression-free survival (PFS): AUC 0.86 vs. 0.36, $P = 0.005$; overall survival (OS): AUC, 0.78 vs. 0.41, $P = 0.01$, respectively].

Conclusions: Dichotomous ALK-IHC is superior to ALK-FISH on small biopsies and FNA to predict tumor response and survival to crizotinib for patients with advanced NSCLC. Our data strongly suggest adapting the guidelines and using dichotomous ALK-IHC as standard companion diagnostic test to select patients with NSCLC who benefit from ALK-targeting therapy. *Clin Cancer Res*; 23(15); 4251–8. ©2017 AACR.

Introduction

In 2007, the first report of an echinoderm microtubule-associated protein like 4 -anaplastic lymphoma kinase (*EML4/ALK*) fusion gene on chromosome 2p in lung cancer has been published (1). *EML4/ALK* variants with different breakpoints and other fusion partners for *ALK* have been identified, for example, *KIF5B*, *TRK*, *TPR*, *KLC1*, *DCTN*, and *SQSTM* (1–4). *EML4/ALK* rearrangement occurs in approximately 5% of patients with

advanced non-squamous non-small cell lung carcinoma (NSCLC; refs. 1, 5–7). In stages I to III, NSCLC ALK rearrangement frequency is 3.2% (8).

In 2010, crizotinib has been registered as the first drug for treating *EML4/ALK*-positive patients with advanced NSCLC. Phase II studies in patients with ALK-break-positive NSCLC defined by FISH revealed tumor response rates up to 65% (4, 9). Phase III studies confirmed the response rate and showed an improved survival compared with chemotherapy (10). In these

¹Department of Pulmonary Diseases, University of Groningen, University Medical Centre Groningen, Groningen, the Netherlands. ²Department of Pathology and Medical Biology, GROW-School for Oncology & Developmental Biology, Maastricht University Medical Centre, Maastricht, the Netherlands. ³Department of Pulmonary Diseases, GROW-School for Oncology & Developmental Biology, Maastricht University Medical Centre, Maastricht, the Netherlands. ⁴Department of Pulmonary Diseases, Radboud University Medical Center, Nijmegen, the Netherlands. ⁵Department of Pathology, Radboud University Medical Center, Nijmegen, the Netherlands. ⁶Department of Pulmonary Diseases, Free University Medical Centre, Amsterdam, the Netherlands. ⁷Department of Pulmonary Diseases, ZGT Almelo/Hengelo, Hengelo, the Netherlands. ⁸Department of Pathology/LabPON, ZGT Almelo/Hengelo, Hengelo, the Netherlands. ⁹Department of Pulmonary Diseases, Catharina Cancer Institute, Catharina Hospital Eindhoven, the Netherlands. ¹⁰Department of Pathology, GROW-School for Oncology & Developmental Biology, Maastricht University Medical Centre, Maastricht, the Netherlands.

Note: Supplementary data for this article are available at Clinical Cancer Research Online (<http://clincancerres.aacrjournals.org/>).

E. Schuuring and H.J.M. Groen contributed equally to this study.

Ethics information: In Groningen, the study protocol was consistent with the Research Code of the University Medical Center Groningen (<http://www.umcg.nl/EN/Research/Researchers/General/ResearchCode/Paginas/default.asp>) and Dutch national ethical and professional guidelines (<http://www.federa.org>).

Corresponding Author: A.J. van der Wekken, Department of Pulmonary Diseases, University of Groningen and University Medical Center Groningen, Hanzeplein 1, PO Box 30.001, 9700 RB Groningen, the Netherlands. Phone: 31-50-361-6161; Fax: 31-50-361-9320; E-mail: a.j.van.der.wekken@umcg.nl

doi: 10.1158/1078-0432.CCR-16-1631

©2017 American Association for Cancer Research.

Translational Relevance

ALK rearrangement detection using FISH is the standard test to identify patients with non-small cell lung carcinoma (NSCLC) eligible for treatment with ALK inhibitors. Recently, ALK protein expression in resectable NSCLC showed predictive value. In this study, we evaluated tumor response rate and survival after crizotinib treatment of patients with advanced NSCLC with ALK activation using both dichotomous immunohistochemical (IHC) staining and FISH. We have found that dichotomous ALK-IHC is superior to ALK-FISH on small biopsies and fine-needle aspirations (FNA) to predict tumor response and survival to crizotinib for patients with advanced NSCLC. Our data strongly suggest adapting the guidelines and using dichotomous ALK-IHC as standard companion diagnostic test to select patients with NSCLC who benefit from ALK-targeting therapy.

studies, no major differences were observed between ALK rearrangements, expression of fusions at RNA, and ALK detection at protein level. However, the explanation why some patients with an ALK rearrangement did not respond to initial ALK inhibitors was not solved.

In the United States, the CE-IVD-marked Abbott FISH kit was registered as a companion diagnostic for crizotinib. The Ventana ALK (D5F3) CDx assay is approved as a CE-IVD in Europe, China (www.ventana.com), and the United States (www.fda.gov) since 2012, 2013, and June 2015, respectively. This test is used on a fully automatic BenchMark XT and with a dichotomous scoring system. This test is unambiguous and only provides a positive or negative outcome (11). In Japan, ALK-RT-PCR is most commonly used in the diagnosis of ALK status (12). In Europe, the European Medicines Agency (EMA) allows the use of clinically validated methods to detect ALK positivity either by FISH or IHC. The FDA-approved Abbott break-apart ALK-FISH probe and scoring using the international guidelines (www.Abbott.com) is labor-intensive, time-consuming, and operator-dependent (13). Furthermore, the detection of ALK rearrangements by FISH is not always concordant with ALK protein expression, although most studies show a concordance close to 100% (7, 8, 12, 14, 15).

Recently, several articles have been published on the comparison of different ALK-IHC and ALK-FISH tests. Most of these studies used resection samples of which tissue microarrays (TMA) were made (8, 12, 14, 15). In those studies only few patients have been treated with crizotinib, probably at recurrence of disease. In clinical practice, however, most patients with ALK-positive NSCLC present with stage IV disease upon diagnosis. This is often based on small biopsies and/or fine-needle aspiration (FNA), which is usually not enough to build TMAs. In previous studies, tests have been compared without investigating the predictive value for treatment outcome.

Therefore, we explored the predictive value of Ventana ALK (D5F3) CDx assay and the Abbott break-apart ALK-FISH test, on small biopsies and FNA, taken for predictive screening in our referral center. Cases were those who routinely tested and those where the interpretation of the FISH test result was difficult for tumor response to crizotinib in patients with stage IV NSCLC. We hypothesized that dichotomous ALK-IHC, measuring the expression of the ALK protein containing the active kinase part, has a

better predictive value than ALK-FISH for ALK-positive patients with high tumor responses and prolonged survival (11).

Materials and Methods

Patients

Screening group. All consecutive patients with stage IV non-squamous carcinoma tested in our national referral center for ALK-FISH testing resulted in a selected cohort of cases who had a positive ALK test either by ALK-FISH or dichotomous ALK-IHC scoring algorithm. Consecutive patients were those with routinely established FISH and a highly selected group with difficult interpretable FISH test results. From 2013 in parallel to ALK-FISH, analysis was performed with Ventana ALK-IHC. Tissue blocks were collected from all patients with ALK-FISH-positive tumors, but without ALK-IHC data (mainly before 2013), used for ALK-FISH, and when sufficient neoplastic cells were present, dichotomous ALK-IHC was performed. Twenty-nine ALK-positive patients (either FISH or IHC positive) were treated with ALK inhibitors and prospectively evaluated for patients' characteristics, for example, smoking and performance score, and treatment outcome. Tumor response was assessed on CT using RECIST 1.1 (16).

External validation group. An external validation set of ALK-FISH-positive tumor samples from patients treated with crizotinib in 4 other hospitals was collected. To exclude laboratory quality differences (e.g., FISH operator dependency) between hospitals as potential bias, exchange of tumor samples and test results is necessary. The samples were tested with the dichotomous ALK-IHC at University Medical Centre Groningen (UMCG; Groningen, the Netherlands). Response rates, duration of crizotinib treatment, and survival were compared with dichotomous ALK-IHC results.

Detection of ALK status by FISH

FISH was performed with the commercial LSI ALK dual-color, break-apart rearrangement probe kit (Abbott Molecular Inc. 06N38-020) for the evaluation of ALK genomic status (ALK-FISH). In brief, 4- μ m formalin-fixed, paraffin-embedded (FFPE) tissue or CytoLyt block sections were mounted on positively charged glass slides and dried overnight at 60°C. Areas with sufficient neoplastic cells were marked after review of the corresponding hematoxylin and eosin (H&E) slide by a pathologist. After deparaffinization, slides were pretreated in Tris-EDTA, pH 9.0, buffer at 120°C for 7 minutes in a pressure cooker, washed and incubated in RNase (0.1 mg/mL diluted in 2 \times SSC) at 37°C for 1 hour, washed again, and treated with pepsin (0.1% diluted in 0.01 N HCl) at 37°C for 10 minutes (biopsies and FNA: 5 minutes); denaturation (12 minutes at 80°C) and hybridization (overnight at 37°C) were performed. After hybridization, slides were washed 2 \times SSC/0.3% NP-40 at 73°C for 2 minutes followed by 2 \times SSC/0.1% NP-40 for 1 minute at room temperature, dehydrated, air-dried (2 \times alcohol 96% and air-dried), and finally, slides were mounted manually in Vectashield with 4',6-diamidino-2-phenylindole (DAPI; 0.33 μ g/mL diluted in Vectashield). Stained sections were stored at 2°C to 8°C in the dark until evaluation was performed to prevent fading of the fluorescent signals. Using the appropriated filters, scoring was performed according to the international guidelines (www.Abbott.com; ref. 13) and analyzed independently by 2 experienced FISH

evaluators. A case was considered ALK-FISH–positive when more than 15% of the evaluated 100 neoplastic nuclei had the break-apart pattern. In case of discordance, a third independent experienced assessor scored the sample. FISH was performed in the laboratory of Molecular Pathology Department at the UMCG. Moreover, in case, enough tumor tissue was present, ALK-FISH was also performed at an international ALK-FISH laboratory (Dr. P. Pauwels, Antwerp, Belgium) to confirm our test data.

The ALK-FISH for the external validation cohort was performed in the local laboratories of Maastricht University Medical Centre (MUMC+; Maastricht, the Netherlands), ZGT (Hengelo, the Netherlands), Vanderbilt University Medical Center (VUMC; Nashville, TN), and Radboud UMC (Nijmegen, the Netherlands).

Detection of ALK expression status by immunohistochemistry and dichotomous scoring

ALK-IHC was performed on 4- μ m-thick FFPE tissue sections or CytoLyt block sections using the Ventana ALK (D5F3) CDx assay on a Ventana BenchMark XT automated slide-processing system (Ventana Medical Systems Inc.). Briefly, slides of NSCLC tumor were subjected to deparaffinization using EZ Prep (VMSI) and `extended' Cell Conditioning 1. Tissue sections were incubated with anti-ALK antibody (clone D5F3, VMSI) for 20 minutes. OptiView DAB IHC Detection Kit (VMSI) and OptiView Amplification Kit (VMSI) were used according to the manufacturer's recommendations for the visualization of the bound primary antibody (<http://www.uclad.com/newsletters/ALK-LUNG-IHC-INTERPRETATION-GUIDE.pdf>; ref. 11). Tissue slides were counterstained with Hematoxylin II and Bluing Reagent (VMSI). An ALK-positive cell line embedded in agar/FFPE or sections of normal appendix containing ALK-positive ganglion cells were used as dichotomous ALK-IHC external controls in each run (VMSI). For evaluating the staining results, a dichotomous scoring system (positive or negative for ALK status) was used [package insert for Ventana anti-ALK (D5F3) Rabbit Monoclonal Primary Antibody, Cat. No. 790-4794 / 06679072001]. ALK expression was assessed independently by one trained scientist and one pathologist without knowledge of the FISH results or treatment outcome. Strong granular cytoplasmic staining of neoplastic cells (any percentage) is considered positive, only (11).

Validation of the fusion products by RT-PCR

cDNA was synthesized using 500 ng total RNA input with Superscript II reverse transcriptase and random primers according to the company instruction (Invitrogen). PCR was performed using 10 ng cDNA as input in a final volume of 30 μ L containing 1 \times PCR buffer and MgCl₂ (final concentration. 1.5 mmol/L), 0.2 μ L Taq DNA polymerase (5 unit/ μ L; Invitrogen), and 10 mmol/L primers designed using Clone Manager Suite (Sci-Ed Software). Amplification consisted of 45 cycles using a thermocycler (Bio-Rad). Primers detecting the known *EML4/ALK* fusion variants are listed in Supplementary Table S1.

Statistical analysis

Statistics for patient characteristics were descriptive and χ^2 test was used for comparison. ALK test performance of FISH and the dichotomous IHC for screening and validation were compared with receiver operating characteristics (ROC) method with primary outcome tumor response and survival. To test for confounders, uni- and multivariate analyses were performed. Progression-free survival (PFS) was defined from the date of treatment start

until the date of disease progression or death. Overall survival (OS) was defined from treatment start until the date of death. To compare survival of different groups by Kaplan–Meier method, log-rank test was used. For evaluating the influence of the percentage of breaks by FISH on PFS and OS, *t* test was used. *P* < 0.05 was considered significant. Statistical analyses were performed with SPSS 22.0.

Results

Between January 2011 and July 2015, 29 patients with advanced non-squamous NSCLC showed a positive ALK status (Supplementary Fig. S1), based on ALK-FISH (*n* = 16), ALK-IHC (*n* = 3), or both (*n* = 10). They were selected at a University Medical Center and treated with crizotinib with a median follow up of 5.8 months [95% confidence interval (CI), 0.0–15.4]. In 22 of 29 patients, ALK tests were performed on endobronchial biopsies or transthoracic punctures and in 8 patients on FNA obtained by endoscopic ultrasound and/or endobronchial ultrasound. The median age of the screening cohort was 58 years (range, 21–79). Twenty patients were diagnosed with adenocarcinoma and 10 with NSCLC favoring adenocarcinoma. Most patients were non-smokers (9 of 29) or previous smokers (11 of 29) and had a good performance score of 0 to 1 (Table 1). Crizotinib (250 mg twice a day) was used as the second-line treatment after chemotherapy in 22 of 29 patients and in others as first-line therapy.

Treatment response of patients with ALK-positive NSCLC as determined by break-apart FISH analysis

Twenty-six of 29 patients were ALK-FISH–positive with more than 15% of 100 neoplastic nuclei with break-apart pattern. Response rate (RR) in the FISH-positive group, including 13 dichotomous ALK-IHC–negative patients, was low (23%); the median PFS (mPFS) was 1.8 months (95% CI, 1.4–2.2) and median OS (mOS) was 5.3 months (95% CI, 0.0–15.4). Three patients who were dichotomous ALK-IHC–positive and FISH-negative had a RR of 67% with an mPFS of 5.0 months (95% CI, 0.0–11.2) and mOS of 5.8 months (95% CI, 0.5–11.1).

The median percentage of neoplastic nuclei with ALK breaks was 35% (range, 2%–78%). No association was observed between the percentage of ALK breaks and treatment outcome as determined by RR, PFS, and OS (Table 2). Also, cases with ALK rearrangement based on the loss of the 5'-ALK-FISH probe resulting in the typical pattern with a single red FISH signal were found

Table 1. Patient characteristics of screening cohort of ALK-positive patients with advanced non-squamous NSCLC by dichotomous ALK expression levels

	ALK-IHC ⁺	ALK-IHC ⁻	<i>P</i>
No. of patients	13	13	—
Male/Female	2/11	8/5	0.02
Median age (Range), years	55 (21–73)	61 (38–79)	0.41
ECOG performance score			
0–1	11	12	0.78
2	1	0	—
3	1	1	—
Smoking status			
Never smoker	6	3	0.35
Current smoker	2	5	—
Former smoker	5	5	—
Time on crizotinib (95% CI), mo	8.4 (3.1–13.7)	1.5 (0.9–2.1)	<0.001

NOTE: In 26 of 29 patients, dichotomous ALK-IHC could be performed. Available tissue blocks previously used for ALK-FISH do not contain any neoplastic cells and dichotomous ALK-IHC and could therefore not be performed in 3 patients.

Table 2. Overview of the screening cohort with different ALK tests and clinical outcome in 29 patients with stage IV NSCLC treated with crizotinib

Patient	ALK-IHC	FISH, %	Copies	RT-PCR	Response	PFS, mo	OS, mo	Variants in EML4/ALK-RT-PCR
1	+	45	N/A	+	PR	12.0	18.3	var 1
2	N/A	15	N/A	–	PD	1.4	13.9	–
3	+	15	ER	+ ^a	PR	6.8	13.8	E20; A20-var 2
4	+	2	1	+	PR	15.9	47.5	E6; A20-var 3
5	+	6	1–4	N/A	PR	5.0	5.8	–
6	+	78	1–2; ER	+	PR	9.5	24.5	E6; A20-var 3
7	+	69	1–3	N/A	PR	39.0	39.0	–
8	N/A	52	ER	–	PD	1.6	2.4	–
9	–	25 ^b	1–2	–	PD	0.2	0.9	–
10	+	55	1–2	N/A	SD	9.6	14.2	–
11	+	59	N/A	N/A	PR	22.0	31.0	–
12	–	22	N/A	N/A	PD	3.5	10.1	–
13	–	35	2–4	N/A	PD	1.9	16.1	–
14	+	47	1–2	+	PR	8.4	31.5	E6; A20-var 3
15	–	15	N/A	N/A	PD	1.0	2.1	–
16	+	64	ER	+	PR	4.1	18.9	E6; A20-var 3
17	N/A	20	1	N/A	PD	1.5	3.1	–
18	–	35	ER	N/A	PD	0.5	0.5	–
19	–	64	ER	N/A	PD	2.6	11.2	–
20	+	47	1	N/A	PD	1.6	1.9	–
21	+ ^c	12	1	N/A	PD	1.1	2.5	–
22	–	21	1	N/A	PD	2.0	5.0	–
23	–	19	1	N/A	PD	1.3	5.3	–
24	+	40	1	N/A	PD	0.9	0.9	–
25	–	17	1	N/A	PD	1.5	4.6	–
26	–	18	1	N/A	PD	0.7	4.4	–
27	–	66	1	N/A	PD	0.7	4.8	–
28	–	41	1	N/A	PD	1.8	5.2	–
29	–	16	1	N/A	PD	1.1	6.0	–

NOTE: Dichotomous ALK-IHC is called either positive or negative and N/A means no neoplastic cells in the available pretreatment biopsy; ALK-FISH is positive if >15% of 100 counted neoplastic nuclei show the defined break-apart patterns.

Abbreviations: ER, extra red (5' allele); PD, progressive disease; PR, partial response; SD, stable disease.

^aALK translocation confirmed by RNA seq (Saber and colleagues; ref. 30).

^bALK-FISH-positive (ALK-IHC not tested in 2012) in a very small area of tumor tissue (<2%), the largest part of tumor is ALK-FISH, ALK-IHC, and EML4/ALK-RT-PCR-negative.

^cDichotomous ALK-IHC shows heterogeneous immunostaining of positive and negative neoplastic cells (see Fig. 2B).

in 6 of 29 patients. This pattern was not associated with a better treatment outcome.

The international ALK-FISH referral center confirmed our ALK-FISH data in 14 cases of which enough tumor was present.

Treatment response of dichotomous patients with ALK-IHC-positive NSCLC

In 26 of 29 patients, tumor tissue with sufficient neoplastic cells was left to perform the dichotomous ALK-IHC test. Thirteen tumors showed ALK expression whereas 13 were negative (all 13 were ALK-FISH-positive). In the dichotomous ALK-IHC-positive group, the RR was 69% with an mPFS of 8.4 months (95% CI, 3.1–13.7) and an mOS of 18.3 months (95% CI, 12.4–24.2). No responses were observed in the dichotomous ALK-IHC-negative group with an mPFS of 1.5 months (95% CI, 0.9–2.1) and an mOS of 5.0 months (95% CI, 4.3–5.7). Univariate and multivariate analyses revealed that dichotomous ALK-IHC was associated with better treatment outcome as determined by tumor response ($P < 0.001$), mPFS ($P < 0.001$), and mOS ($P = 0.01$). The duration of tumor responses is outlined in Fig. 1.

Three patients with dichotomous ALK-IHC-positive tumor had no response to crizotinib, 1 patient died because of complications of brain radiotherapy shortly after starting crizotinib (ALK24). One patient died because of liver failure due to metastases with necrosis on therapy (ALK20). In another patient, only a part of the

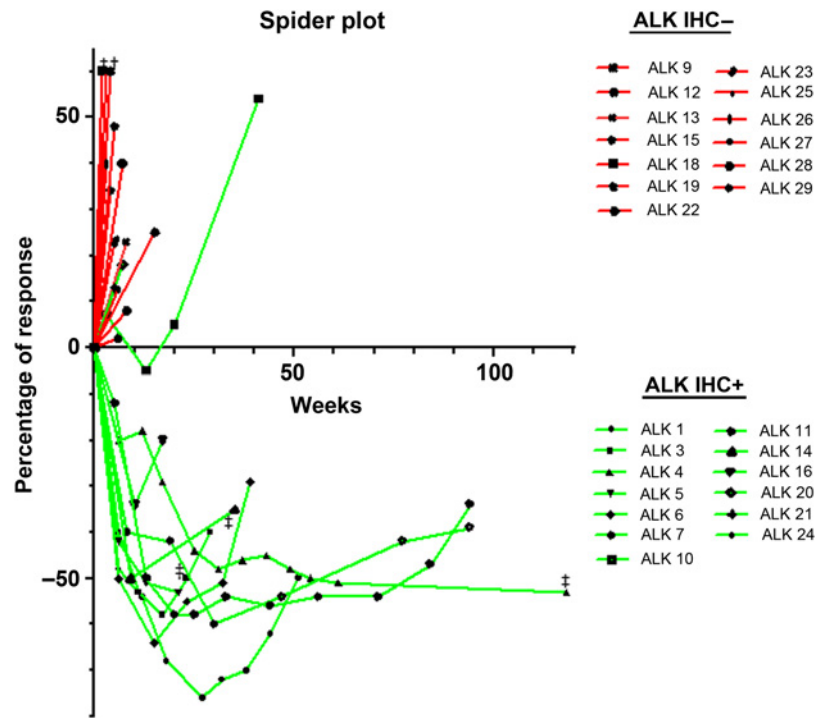
tumor at the border of the tissue section showed ALK-FISH positivity while most neoplastic cells were ALK-FISH negative. Retesting of the residual tissue using both ALK-FISH and dichotomous ALK-IHC revealed that the earlier observed FISH-positive tumor area was not present anymore. All neoplastic cells were negative for both ALK-FISH and dichotomous ALK-IHC (ALK09; Fig. 2A). This could explain lack of tumor response. In the third resistant patient (ALK 21; Fig. 2B), dichotomous ALK-IHC showed heterogeneous immunostaining of the neoplastic cells. Since all other dichotomous ALK-IHC-positive cases in this study showed a homogeneously strong ALK expression of all neoplastic cells (see Fig. 2C and D for examples), the presence of the ALK-negative neoplastic cells in case ALK21 might explain the short PFS.

One patient (ALK 10) without tumor response had stable disease for 10 months.

Comparison of break-apart FISH, EML4/ALK-RT-PCR and dichotomous ALK-IHC

Comparison of both dichotomous ALK-IHC and ALK-FISH test performances showed a better prediction of tumor response shifting the ROC from 0.64 to 0.86 ($P = 0.03$) in favor of dichotomous ALK-IHC (Fig. 3). This has been observed for survival outcomes as well. Using PFS as the primary outcome, ROC increased from 0.36 to 0.86 ($P = 0.005$), and for OS, ROC

Figure 1. Tumor response duration upon crizotinib treatment in 26 patients with ALK-FISH-positive advanced non-squamous NSCLC stratified in dichotomous ALK-IHC-positive and -negative tumors from the screening cohort. Dichotomous ALK-IHC is depicted as positive (green) or negative (red) for tumor response outcome, measured on CT using RECIST 1.1. Tumor progression is determined when there is >20% increase in size, partial response is determined when there is >30% decrease in size, stable disease is determined between 20% increase and 30% decrease in size. Time of tumor response is in weeks. †, deceased; ‡, progressive disease due to new lesion.

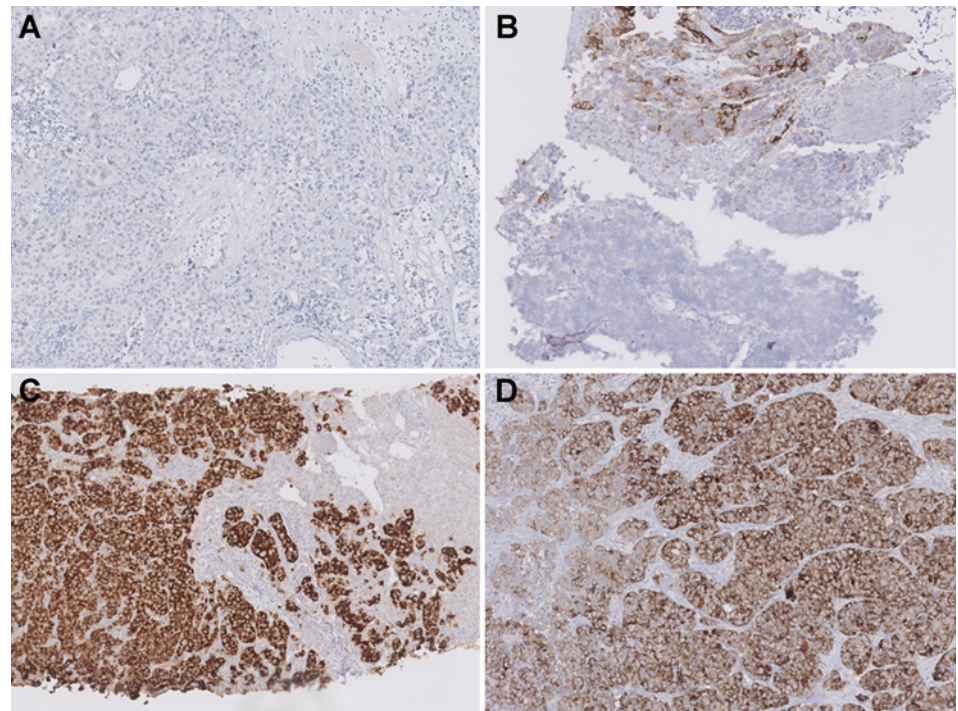


increased from 0.41 to 0.78 ($P = 0.01$). When dichotomous ALK-IHC and ALK-FISH data were combined, tumor response and survival were associated with ALK-IHC, independent of ALK-FISH outcome in multivariate analysis. Dichotomous ALK-IHC outcome was not associated with the percentage of neoplastic nuclei

with ALK break-apart patterns (range, 2%–78%; Supplementary Fig. S2) which is in line with a previous study (17).

To explain the discrepancy between FISH and IHC, we performed RT-PCR or exome sequencing. In one patient (ALK04), RT-PCR confirmed the presence of ALK rearrangement (E20; A20,

Figure 2. Normal and exceptional staining patterns in dichotomous ALK-IHC-positive patients using Ventana ALK (D5F3) CDx assay. **A**, ALK09 shows no immunostaining of the neoplastic cells (ALK-IHC-negative). **B**, ALK21 shows heterogeneous immunostaining of the neoplastic cells. **C** and **D**, Examples of the common homogeneous strong ALK expression of all neoplastic cells (ALK-IHC-positive).



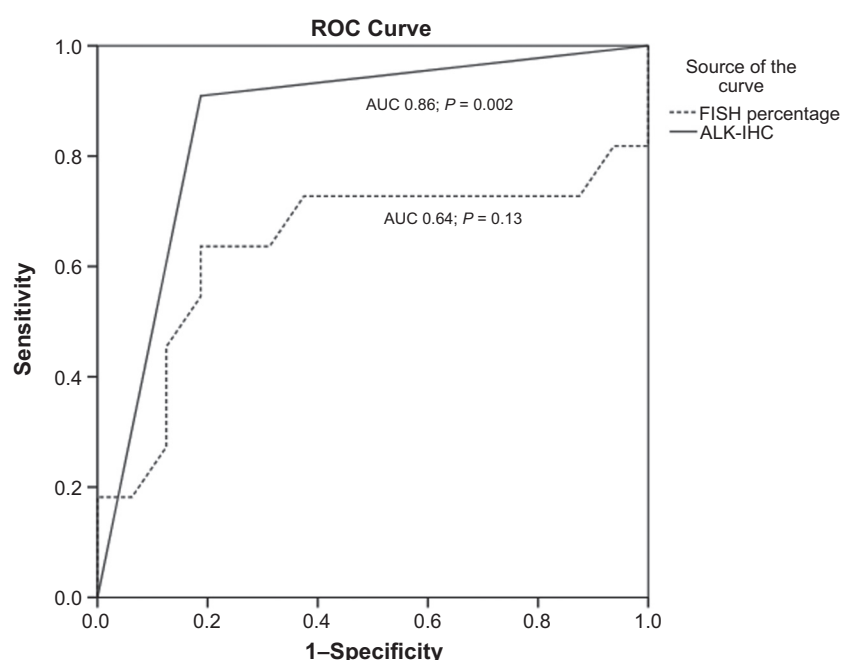


Figure 3. ROC plot of dichotomous ALK-IHC Ventana and the Abbott break-apart ALK-FISH to predict tumor response to crizotinib. In our cohort, there were ALK-FISH-positive patients without a tumor response to crizotinib while all except 2 patients with dichotomous ALK-IHC responded. The ROC curves with survival as endpoint were similar. *P* value relates to comparison with area under the ROC curve of 0.5.

variant 2) that was not detected by ALK-FISH. This patient had one of the longest PFS in our treatment cohort (15.9 months). Patient (ALK09) was positive for ALK-FISH in a small area of neoplastic cells only (<2%). Dichotomous ALK-IHC and EML4/ALK-RT-PCR were both negative on the same tissue block that did not contain the earlier small FISH-positive area anymore. This patient did not respond to crizotinib. In 2 patients, dichotomous ALK-IHC could not be performed, ALK-FISH was positive, and EML4/ALK-RT-PCR was negative. Both patients did not respond to crizotinib.

In 5 responding patients, all 3 tests (dichotomous ALK-IHC, ALK-FISH, ALK-RT-PCR) were positive (Table 2).

Table 3. Overview of the validation cohort with ALK-IHC, FISH, and tumor responses to crizotinib in 16 patients with stage IV NSCLC from 4 hospitals treated with crizotinib

Patient	ALK-IHC	FISH	Response	PFS, mo	OS, mo
EV1	-	+	PD	3.9	3.9
EV2	+	+	PR	10.3	45.6
EV3	+	+	PR	4.4	9.2
EV4	+	+	CR	19.7	20.1
EV5	+	+	SD	4.9	8.2
EV6	+	+	PR	10.6	17.5
EV7	+	+	PR	6.1	9.2
EV8	+	+	SD	1.9	5.1
EV9	+	+	PR	1.4	1.4
EV10	-	+	PD	1.8	3.7
EV11	+	+	SD	10.6	10.6
EV12	+	+	PR	13.8	15.6
EV13	-	+	PD	4.0	7.6
EV14	+	+	PR	6.2	8.7
EV15	-	+	PD	1.0	1.7
EV16	-	+	PD	1.6	18.1

NOTE: Dichotomous ALK-IHC is called either positive or negative. ALK-FISH is positive if >15% of 100 counted neoplastic nuclei show the defined break-apart pattern.

Abbreviations: CR, complete response; PD, progressive disease; PR, partial response; SD, stable disease.

Validation cohort of dichotomous ALK-IHC compared with response

In the 4 Dutch hospitals 53 patients were treated with crizotinib on the basis of a positive ALK-FISH (Supplementary Fig. S1). Of those, 16 patients had enough tumor tissue available to perform the dichotomous Ventana (D5F3) ALK-IHC. Eleven patients had a positive dichotomous ALK-IHC and 5 were negative. All 5 dichotomous ALK-IHC-negative patients did not have a response to crizotinib. Response percentage in the IHC-positive patients was 72. Three positive patients showed stable disease and 8 of 11 patients had a partial or complete response with crizotinib (Table 3).

Discussion

This is the first systematic study in advanced NSCLC with small amounts of tumor tissue to compare the value of the dichotomous ALK-IHC and ALK-FISH test on the basis of tumor response and survival as primary outcome. The dichotomous ALK-IHC largely outperformed the ALK-FISH as measured by ROC in a screening (one hospital) and validation (4 other hospitals) cohort of patients with advanced ALK-positive NSCLC. All patients with a negative dichotomous ALK-IHC did not respond to crizotinib. Therefore, patients who were tested with the Ventana ALK (D5F3) IHC did not need additional ALK-FISH testing. This is in contrast to current guidelines (e.g., CAP/IASL/AMP 2013) that ALK-FISH is required to confirm ALK-IHC status. We demonstrated that these guidelines would even harm ALK-IHC-positive/ALK-FISH-negative patients from not receiving the appropriate ALK inhibitors.

Despite the large number of reports on the prevalence of ALK positivity in NSCLC and the comparison of various detection assays, few studies report on the optimal biomarker predicted by tumor response to ALK inhibitors. ALK-IHC with 5A4 antibodies were used in comparison with Vysis FISH in a French

study of 45 patients, an Italian study with the ETOP consortium, and a Japanese study (7, 12, 14). Importantly, none of these studies took patient outcome as a measurement of test efficacy. Other ALK-IHC and ALK-FISH tests are described in Supplementary File.

The low response rate for the whole group was due to a substantial number of patients with ALK-FISH-positive and ALK-IHC-negative patients, indicating a selected population. All those patients did not respond to crizotinib. The higher frequency of these patients was due to the fact that our center not only performs routinely FISH testing but also difficult interpretable FISH testing. Therefore, we confirmed our ALK-FISH results in the international ALK-FISH center. The dichotomous ALK-IHC-positive group showed response rates and survival comparable to second-line treatment as shown in the studies by Kwak and colleagues and Shaw and colleagues (4, 10). Moreover, 2 dichotomous ALK-IHC-positive but ALK-FISH-negative patients responded to crizotinib. This is similar as in a study by Pekar and colleagues, where 2 such patients also responded to crizotinib. These (ALK-IHC-positive and ALK-FISH-negative) patients showed an ALK translocation as measured with next-generation sequencing (NGS; ref. 18). Other patient reports showed a similar outcome (14, 19, 20).

Comparison of ALK expression levels with the presence of ALK rearrangements detected with FISH revealed an agreement between 90% and 100% (11, 21–28).

Occasionally, patients have been described who were ALK-FISH-positive but ALK-IHC-negative and who responded to crizotinib. Ilie and colleagues showed 3 patients (EML4/ALK break RT-PCR-negative also) who responded due to the fact that they were cMET amplification-positive, as crizotinib is a MET inhibitor as well (29). This could also be the case for the patient mentioned in the article by Marchetti and colleagues (8), although this was not evaluated.

We also showed that heterogeneous staining was only observed in patients who did not respond to treatment. So, only those patients respond effectively to ALK treatment who have a homogeneously positive dichotomous ALK-IHC staining.

In conclusion, this is the largest report where dichotomous ALK-IHC and FISH tests are evaluated in small biopsies and cytology alone. Dichotomous ALK-IHC (either positive or negative) outcome is superior to ALK-FISH on small biopsies and FNA to predict tumor response and survival to anti-ALK therapy for patients with advanced NSCLC. Our data strongly suggest that guidelines should be adapted, and dichotomous ALK-IHC should be the standard companion diagnostic test

to select patients with NSCLC who benefit from anti-ALK therapy.

Disclosure of Potential Conflicts of Interest

A.J. van der Wekken has received speakers' bureau honoraria from and is a consultant/advisory board member for Pfizer. N.'t Hart is a consultant/advisory board member for Pfizer advisory meeting. L. Hendriks has received financial support for printing PhD thesis from Pfizer. E.H.F.M. van der Heijden reports receiving other commercial research support from Pentax Medical and Astra-Zeneca Oncology; has received speakers' bureau honoraria from MSD Oncology; and is a consultant/advisory board member for MediGlobe Corporation. S. Riemersma has received speakers' bureau honoraria from Lilly and is a consultant/advisory board member for Pfizer and Amgen. E.J.M. Speel is a consultant/advisory board member for Pfizer, Roche, MSD, and BMS. A.-M.C. Dingemans is a consultant/advisory board member for Pfizer and Roche. W. Timens is a consultant/advisory board member for MSD, Roche/Ventana, and Pfizer. E. Schuurin has received speakers' bureau honoraria from Novartis and Pfizer and is a consultant/advisory board member for Pfizer. H.J.M. Groen is a consultant/advisory board member for Pfizer and Roche. No potential conflicts of interest were disclosed by the other authors.

Authors' Contributions

Conception and design: A.J. van der Wekken, E.J.M. Speel, T.J.N. Hiltermann, E. Schuurin, H.J.M. Groen

Development of methodology: A.J. van der Wekken, W. Timens, E. Schuurin, H.J.M. Groen

Acquisition of data (provided animals, acquired and managed patients, provided facilities, etc.): A.J. van der Wekken, N.'t Hart, L. Hendriks, E.H.F.M. van der Heijden, M. Looijen-Salamon, A. J. de Langen, J.S.-van den Brekel, S. Riemersma, B.E. van den Borne, E.J.M. Speel, A.-M.C. Dingemans, T.J.N. Hiltermann, W. Timens, H.J.M. Groen

Analysis and interpretation of data (e.g., statistical analysis, biostatistics, computational analysis): A.J. van der Wekken, L. Hendriks, E.H.F.M. van der Heijden, B.E. van den Borne, E. Schuurin, H.J.M. Groen

Writing, review, and/or revision of the manuscript: A.J. van der Wekken, L. Hendriks, E.H.F.M. van der Heijden, A. J. de Langen, J.S.-van den Brekel, S. Riemersma, B.E. van den Borne, E.J.M. Speel, A.-M.C. Dingemans, T.J.N. Hiltermann, A. van den Berg, W. Timens, E. Schuurin, H.J.M. Groen

Administrative, technical, or material support (i.e., reporting or organizing data, constructing databases): A.J. van der Wekken, R. Pelgrim, N. Werner, M. Mastik, L. Hendriks, M. Looijen-Salamon, E.J.M. Speel, E. Schuurin

Supervision: E.H.F.M. van der Heijden, E. Schuurin, H.J.M. Groen

Acknowledgments

For sending tumor tissue, we would like to acknowledge H. Sietsma, P. Nederlof, P. van Zwam, and E. Thunnissen. We are also grateful to Tineke van der Sluis, Geert Harms, and Jan Donga for technical assistance.

The costs of publication of this article were defrayed in part by the payment of page charges. This article must therefore be hereby marked *advertisement* in accordance with 18 U.S.C. Section 1734 solely to indicate this fact.

Received July 11, 2016; revised September 5, 2016; accepted February 1, 2017; published OnlineFirst February 9, 2017.

References

- Soda M, Choi YL, Enomoto M, Takada S, Yamashita Y, Ishikawa S, et al. Identification of the transforming EML4-ALK fusion gene in non-small-cell lung cancer. *Nature* 2007;448:561–6.
- Choi YL, Lira ME, Hong M, Kim RN, Choi SJ, Song JY, et al. A novel fusion of TPR and ALK in lung adenocarcinoma. *J Thorac Oncol* 2014;9:563–6.
- Sasaki T, Rodig SJ, Chirieac LR, Janne PA. The biology and treatment of EML4-ALK non-small cell lung cancer. *Eur J Cancer* 2010;46:1773–80.
- Kwak EL, Bang YJ, Camidge DR, Shaw AT, Solomon B, Maki RG, et al. Anaplastic lymphoma kinase inhibition in non-small-cell lung cancer. *N Engl J Med* 2010;363:1693–703.
- Rikova K, Guo A, Zeng Q, Possemato A, Yu J, Haack H, et al. Global survey of phosphotyrosine signaling identifies oncogenic kinases in lung cancer. *Cell* 2007;131:1190–203.
- Camidge DR, Doebele RC. Treating ALK-positive lung cancer—early successes and future challenges. *Nat Rev Clin Oncol* 2012;9:268–77.
- Blackhall FH, Peters S, Bubendorf L, Dafini U, Kerr KM, Hager H, et al. Prevalence and clinical outcomes for patients with ALK-positive resected stage I to III adenocarcinoma: results from the European Thoracic Oncology Platform Lungscape Project. *J Clin Oncol* 2014;32:2780–7.
- Marchetti A, Di Lorito A, Pace MV, Iezzi M, Felicioni L, D'Antuono T, et al. ALK protein analysis by IHC staining after recent regulatory changes: a comparison of two widely used approaches, revision of the literature, and a new testing algorithm. *J Thorac Oncol* 2016;11:487–95.
- Camidge DR, Bang YJ, Kwak EL, Iafrate AJ, Varella-Garcia M, Fox SB, et al. Activity and safety of crizotinib in patients with ALK-positive non-small-cell lung cancer: updated results from a phase 1 study. *Lancet Oncol* 2012;13:1011–9.

10. Shaw AT, Kim DW, Nakagawa K, Seto T, Crino L, Ahn MJ, et al. Crizotinib versus chemotherapy in advanced ALK-positive lung cancer. *N Engl J Med* 2013;368:2385–94.
11. Wynes MW, Sholl LM, Dietel M, Schuurin E, Tsao MS, Yatabe Y, et al. An international interpretation study using the ALK IHC antibody D5F3 and a sensitive detection kit demonstrates high concordance between ALK IHC and ALK FISH and between evaluators. *J Thorac Oncol* 2014;9:631–8.
12. Yatabe Y. ALK FISH and IHC: you cannot have one without the other. *J Thorac Oncol* 2015;10:548–50.
13. Thunnissen E, Bubendorf L, Dietel M, Elmberger G, Kerr K, Lopez-Rios F, et al. EML4-ALK testing in non-small cell carcinomas of the lung: a review with recommendations. *Virchows Arch* 2012;461:245–57.
14. Cabillic F, Gros A, Dugay F, Begueret H, Mesturoux L, Chiforeanu DC, et al. Parallel FISH and immunohistochemical studies of ALK status in 3244 non-small-cell lung cancers reveal major discordances. *J Thorac Oncol* 2014;9:295–306.
15. Ali G, Proietti A, Pelliccioni S, Niccoli C, Lupi C, Sensi E, et al. ALK rearrangement in a large series of consecutive non-small cell lung cancers: comparison between a new immunohistochemical approach and fluorescence *in situ* hybridization for the screening of patients eligible for crizotinib treatment. *Arch Pathol Lab Med* 2014;138:1449–58.
16. Eisenhauer EA, Therasse P, Bogaerts J, Schwartz LH, Sargent D, Ford R, et al. New response evaluation criteria in solid tumours: Revised RECIST guideline (version 1.1). *Eur J Cancer* 2009;45:228–47.
17. Camidge DR, Theodoro M, Maxson DA, Skokan M, O'Brien T, Lu X, et al. Correlations between the percentage of tumor cells showing an anaplastic lymphoma kinase (ALK) gene rearrangement, ALK signal copy number, and response to crizotinib therapy in ALK fluorescence *in situ* hybridization-positive nonsmall cell lung cancer. *Cancer* 2012;118:4486–94.
18. Pekar-Zlotin M, Hirsch FR, Soussan-Gutman L, Ilouze M, Dvir A, Boyle T, et al. Fluorescence *in situ* hybridization, immunohistochemistry, and next-generation sequencing for detection of EML4-ALK rearrangement in lung cancer. *Oncologist* 2015;20:316–22.
19. Togashi Y, Mizuuchi H, Kobayashi Y, Hayashi H, Terashima M, Sakai K, et al. An activating ALK gene mutation in ALK IHC-positive/FISH-negative nonsmall-cell lung cancer. *Ann Oncol* 2015;26:1800–1.
20. Sun JM, Choi YL, Won JK, Hirsch FR, Ahn JS, Ahn MJ, et al. A dramatic response to crizotinib in a non-small-cell lung cancer patient with IHC-positive and FISH-negative ALK. *J Thorac Oncol* 2012;7:e36–8.
21. Lantuejoul S, Rouquette I, Blons H, Le Stang N, Ilie M, Begueret H, et al. French multicentric validation of ALK rearrangement diagnostic in 547 lung adenocarcinomas. *Eur Respir J* 2015;46:207–18.
22. Cruz-Rico G, Aviles-Salas A, Segura-Gonzalez M, Espinosa-Garcia AM, Ramirez-Tirado LA, Morales-Oyarvide V, et al. Diagnosis of EML4-ALK translocation with FISH, immunohistochemistry, and real-time polymerase chain reaction in patients with non-small cell lung cancer. *Am J Clin Oncol* 2015 Aug 11. [Epub ahead of print].
23. Savic S, Diebold J, Zimmermann AK, Jochum W, Baschiera B, Grieshaber S, et al. Screening for ALK in non-small cell lung carcinomas: 5A4 and D5F3 antibodies perform equally well, but combined use with FISH is recommended. *Lung Cancer* 2015;89:104–9.
24. Lee JA, Bubendorf L, Stahel R, Peters S. Testing for anaplastic lymphoma kinase rearrangement to target crizotinib therapy: oncology, pathology and health economic perspectives. *Expert Rev Anticancer Ther* 2013;13:625–36.
25. Yi ES, Boland JM, Maleszewski JJ, Roden AC, Oliveira AM, Aubry MC, et al. Correlation of IHC and FISH for ALK gene rearrangement in non-small cell lung carcinoma: IHC score algorithm for FISH. *J Thorac Oncol* 2011;6:459–65.
26. Yi ES, Chung JH, Kulig K, Kerr KM. Detection of anaplastic lymphoma kinase (ALK) gene rearrangement in non-small cell lung cancer and related issues in ALK inhibitor therapy: a literature review. *Mol Diagn Ther* 2012;16:143–50.
27. Conde E, Suarez-Gauthier A, Benito A, Garrido P, Garcia-Campelo R, Biscuola M, et al. Accurate identification of ALK positive lung carcinoma patients: novel FDA-cleared automated fluorescence *in situ* hybridization scanning system and ultrasensitive immunohistochemistry. *PLoS One* 2014;9:e107200.
28. Conklin CM, Craddock KJ, Have C, Laskin J, Couture C, Ionescu DN. Immunohistochemistry is a reliable screening tool for identification of ALK rearrangement in non-small-cell lung carcinoma and is antibody dependent. *J Thorac Oncol* 2013;8:45–51.
29. Ilie MI, Bence C, Hofman V, Long-Mira E, Butori C, Bouhlel L, et al. Discrepancies between FISH and immunohistochemistry for assessment of the ALK status are associated with ALK 'borderline'-positive rearrangements or a high copy number: a potential major issue for anti-ALK therapeutic strategies. *Ann Oncol* 2015;26:238–44.
30. Saber A, van der Wekken AJ, Kok K, Terpstra MM, Bosman LJ, Mastik MF, et al. Genomic aberrations in crizotinib resistant lung adenocarcinoma samples identified by transcriptome sequencing. *PLoS One* 2016;11:e0153065.