

THROMBOCYTOPENIC PURPURA COMPLICATING INFECTIOUS MONONUCLEOSIS

REPORT OF A CASE AND SERIAL PLATELET COUNTS DURING
THE COURSE OF INFECTIOUS MONONUCLEOSIS

By RICHARD M. ANGLE, M.D., AND HOWARD L. ALT, M.D.

THE OCCURRENCE of thrombocytopenic purpura during the course of infectious mononucleosis is rare. A review of the literature revealed only six detailed reports of a definite association between these two conditions. It is the purpose of this paper to report another case and to present the results of serial blood platelet counts during the course of 7 consecutive cases of infectious mononucleosis.

REPORT OF A CASE

Miss I. B., a 19 year old white female student nurse, entered the hospital on April 23, 1945, because of petechiae of the lower part of the legs and ecchymoses of the upper extremities.

Family history was irrelevant.

Past history revealed the usual childhood diseases which were without incident. A tonsillectomy and appendectomy had been performed during adolescence and recovery was normal. The menstrual history was not unusual. There had been no previous hemorrhagic tendency. No medication had been used except aspirin-phenacetin-caffeine compound one month before the onset of symptoms.

Present illness. Ten days prior to admission the patient had had a mild sore throat lasting one day. She thereafter felt well until three days before admission, when she noticed numerous small petechial hemorrhages of the lower part of the legs. The following day she noted several bruised areas of her arms and hands but recalled no injuries. Puffiness of the eyes was also present. She was admitted to the hospital on the evening of the third day of illness.

Physical Examination. The patient was a well developed white female who did not appear ill. The pulse was 96, temperature 98.4 F. and blood pressure 138/80. Many petechial hemorrhages were noted in the buccal mucosa. A mucopurulent postnasal discharge was present. Several small lymph nodes were palpated below the angle of the mandible bilaterally. The heart and lungs were normal. The abdomen was not remarkable, and the liver and spleen were not palpated. Axillary and inguinal adenopathy was absent. Numerous petechiae were noted below the knees and several small ecchymoses were present on the arms and dorsum of the hands. The remainder of the examination was normal.

Laboratory Studies. The admission laboratory examination revealed a red blood cell count of 5.09 million per cu. mm., hemoglobin 14.0 grams per 100 cc., and a white blood cell count of 14,300 per cu. mm. Urinalysis was normal. Serology was negative. A differential white blood cell count showed 30 per cent segmented neutrophils, 49 per cent lymphocytes, 20 per cent atypical lymphocytes, and 1 per cent monocytes. Platelets were greatly reduced. A tourniquet test was positive.

On the day after admission, the blood platelet count was 4,600 per cu. mm. Coagulation time was 6 minutes, and the Duke bleeding time was 12 minutes. There was no clot retraction after six hours and only slight retraction after twenty-four hours. The blood nonprotein nitrogen level was 38.5 mg. per 100 cc. Ascorbic acid level was 0.42 mg. The heterophil antibody test was positive in a dilution of 1:112. A stool specimen gave a negative chemical test for blood. A summary of serial blood studies will be found in table 1.

Course. The hospital course was essentially afebrile and treatment was symptomatic. On the second

From the Department of Medicine, Northwestern University Medical School and Passavant Memorial Hospital, Chicago, Ill.

Aided by a grant from Armour and Company.

hospital day, the spleen was easily palpable 2 fingerbreadths below the left costal margin. On the fourth hospital day, the patient began to menstruate. Menstrual bleeding was far more copious than usual and was accompanied by a significant drop in the erythrocyte and hemoglobin levels. On the eighth hospital day, menstruation ceased. The spleen was barely palpable and petechiae and ecchymoses were fading. On the ninth hospital day, the spleen could no longer be felt, and the platelet count had risen to 38,400 per cu. mm. The heterophil antibody test was positive (1:224). As convalescence progressed, the platelet count gradually returned to normal. The patient was discharged asymptomatic on the twenty-second hospital day.

Six months after discharge, the blood picture was normal. The platelet count was 286,600 per cu. mm. Coagulation and bleeding times were normal, as was the clot retraction. Three years after discharge, the patient was well and had no further bleeding tendency.

TABLE I.—Blood Studies during Course of Infectious Mononucleosis

Hosp. Day	RBC Mil./cu.mm.	Hb. Grams/100 cc.	WBC Thous./cu.mm.	Differential Blood Count						Platelets per cu. mm.	Heterophil Antibody Test	
				Neutrophils		Eosinophils	Basophils	Lymphocytes	Aty. lymphocytes			Monocytes
				Bands	Segmented							
1	5.09	14.0	14.3		30			49	20	1		
2	4.61		14.8	1	23	1		50	24	1	4,600	1:112
3	4.86	14.5	13.2		23	2	1	32	42		29,100	
4*	4.70	14.5	12.2		33	2	1	28	32	4	37,600	
5	4.84	14.5	6.9		32			29	32	7	9,600	1:112
6	4.14	12.0	9.0	4	37			41	11	7	12,400	
7	4.35	12.0	7.7		44	1		50	5		13,000	
8†	4.58	13.5	5.1	8	22	3	1	48	8	10	9,100	
9‡	4.81	13.5	9.7		23	3	3	55	9	7	38,400	1:224
10	4.67										88,700	
11	4.57										132,500	1:112
12			6.4	4	49	1	3	36		7		
18												1:112
20			5.6	4	50	2		36		8		
21	4.78	13.5									243,700	

* Onset of menstruation.

† Cessation of menstruation.

‡ Spleen no longer palpable.

REVIEW OF LITERATURE

In the above case a mild form of infectious mononucleosis was associated with a thrombocytopenic purpura. As recovery from the infectious mononucleosis occurred, the platelet count gradually increased and bleeding manifestations ceased. Bleeding was never severe and no treatment was necessary. There was no recurrence of the purpura during a follow-up period of three years. Only 4 identical cases have been recorded. In 1942, Magner and Brooks¹ reported the case of a 20 year old white male who had hematuria, gingival bleeding, excessive bleeding after trauma, and hemorrhagic spots on his legs seven days after the onset of occipital headache and fatigue. In addition to evidence of bleeding, physical examination revealed a palpable spleen and inguinal adenopathy. The white blood cell count was 18,500

per cu. mm., and 78 per cent of the cells were lymphocytes, many of which were abnormal. The blood platelets were greatly reduced. A Paul-Bunnell test gave a positive reaction in a dilution of 1:800. Bleeding gradually subsided and the patient recovered.

Tager and Klinghoffer² in 1943 reported the case of a 20 year old female who developed fever, ecchymoses and petechiae, gingival bleeding, hematuria and bloody stools. There was no adenopathy and the spleen was not palpable. The Duke bleeding time was 24 minutes and the blood clot failed to retract. The leukocyte count was 14,000, of which 90 per cent were normal and pathologic lymphocytes. The heterophil antibody test was positive in a 1:32 dilution after absorption with guinea pig kidney. On admission, no platelets were seen on the blood film. Six small blood transfusions were given during the illness. The blood picture gradually returned to normal and all hemorrhagic phenomena disappeared. The platelet count rose to 700,000 by the thirty-fifth day. There is little doubt that this patient had an infectious mononucleosis, although the authors did not feel that this diagnosis was justified.

In 1944, Lloyd³ reported the case of a 30 year old white male who noticed hemorrhagic spots on the tongue and lips two and one-half weeks after the onset of weakness, fever and sweats. Three days after admission to the hospital, epistaxis and gross hematuria developed. Physical examination showed petechiae and ecchymoses and cervical and axillary adenopathy. The spleen was not palpated. The white blood cell count was 11,800 per cu. mm. with 54 per cent lymphocytes. The platelet count was 66,000 per cu. mm. The Paul-Bunnell test was positive in a dilution of 1:512. Bleeding persisted for five days and then ceased. The platelet count rose to 116,000 per cu. mm. and recovery was uneventful.

Goldbloom and Denton⁴ in 1948 reported the case of a 9 year old boy who became ill with fever, epistaxis, bleeding gums and hemoptysis. Four days later he developed petechiae and ecchymoses on the trunk and lower extremities. The examination revealed petechiae on the oral and buccal mucosa, cervical and axillary adenopathy and an enlarged spleen. The white blood cell count was 9,900, 46 per cent of which were lymphocytes; many were atypical. The platelet count was 90,000 and the heterophil antibody test was positive in a titer of 1:1024. The sternal marrow nucleated cell count was 52,000 per cu. mm., of which 1400 were megakaryocytes. The platelet count remained below 100,000 for twelve days. The patient then recovered and the platelets numbered 180,000 on the forty-fifth day.

In these 4 cases, as in our own, thrombocytopenic purpura paralleled the course of infectious mononucleosis. None of the patients had a past history of bleeding tendency.

Two cases have been reported where infectious mononucleosis apparently aggravated a previously existing hemorrhagic diathesis. In 1940, Bernstein⁵ reported a 16 year old white female who had experienced "episodes of bleeding from various sites." She was admitted to the hospital because of fever, purpura, and epistaxis. The liver and spleen were palpable. The white blood cell count was 10,000 per cu. mm. with 40 per cent lymphocytes. A platelet count was 70,000 per cu. mm.

The Paul-Bunnell test reaction was positive and the Wassermann falsely positive. The patient recovered after receiving blood transfusions, but she continued to have a thrombocytopenia and further bleeding episodes.

Likewise, Dameshek and Grassi⁶ in 1946 reported the case of a 22 year old white female who for two years had noted intermenstrual vaginal bleeding and bleeding following minor cuts or tooth extraction. Following a sore throat with swollen cervical lymph nodes, she developed gingival bleeding and hemorrhagic spots over her chest and arms. After one week, profuse vaginal bleeding occurred and persisted for two and one-half weeks. On admission to the hospital her condition was serious. Physical examination revealed cervical and axillary adenopathy and a palpable spleen. The white blood cell count was 12,800 per cu. mm. with 64 per cent lymphocytes. Platelets were less than 10,000 per cu. mm. A sternal marrow examination was normal. The heterophil antibody test was positive in a dilution of 1:640. In spite of blood transfusions, severe bleeding continued and splenectomy was finally performed. Bleeding quickly ceased and an increase in platelets occurred. Convalescence was uneventful. In the cases of Bernstein and of Dameshek and Grassi, infectious mononucleosis appears to have aggravated markedly an existing hemorrhagic tendency. In the former, thrombocytopenia and bleeding episodes persisted, and in the latter, splenectomy was necessary for recovery.

In addition to the cases discussed above, a number of reports have appeared in which thrombocytopenic purpura was possibly associated with infectious mononucleosis. In 1929, Minot⁷ presented a case seen by him eight years previously with findings of thrombocytopenic purpura, lymphadenopathy, a palpable spleen and anemia. The differential blood count revealed 81 per cent lymphocytes, many of which were abnormal and immature. A diagnosis of acute lymphoblastic leukemia was made, but after eight years the patient was apparently normal. In retrospect this may have been infectious mononucleosis with thrombocytopenic purpura. In 1931, Williams⁸ commented on the presence of purpura, a positive tourniquet test reaction, and prolonged bleeding time during the course of infectious mononucleosis in himself. No further studies were made.

In 1936, Minot⁹ reported 3 patients in whom thrombocytopenic purpura was associated with a lymphocytosis. Many of the lymphocytes were abnormal. In one patient, a single Paul-Bunnell test reaction was negative, and in the others this test was not performed. In these cases infectious mononucleosis cannot be excluded. Cooley¹⁰ in 1938 reported a 56 year old white female with a bleeding episode during which the platelet count was 56,000 per cu. mm., but there was no lymphocytosis. The spleen was palpable. The patient died from a cerebral hemorrhage. At autopsy an enlarged spleen and enlarged abdominal lymph nodes were found. There was round cell infiltration of the liver. The author likened this patient to Minot's 3 cases, although the possibility of infectious mononucleosis must be considered. In 1939, Rosenthal¹¹ reported that "in 4 cases [of thrombocytopenic purpura] the picture resembled infectious mononucleosis, and one adult had purpura during the course of infectious monocytosis." Details of the 4 cases were not given.

Goldbloom and Lieberson¹² in 1948 reported the case of a 21 year old male who had purpura, epistaxis, bleeding gums, and hematemesis one week after the onset

of malaise and fever. The physical examination revealed mild jaundice, but there was no adenopathy or splenomegaly. The white blood cell count was 7,800 with 50 per cent lymphocytes, many of which were atypical. The heterophil antibody test reaction was negative on two occasions. The serum bilirubin was 6.1 mg. and the cephalin-cholesterol flocculation test was four plus. The day after admission the platelet count was 30,000 per cu. mm., but rose rapidly to 296,000 four days later. A diagnosis of infectious mononucleosis complicated by thrombocytopenic purpura was made, but it seems more likely that this patient had an infectious hepatitis.

From this review of the literature, it is apparent that the association of thrombocytopenic purpura with infectious mononucleosis has been fairly well established in only 6 cases. In 12 other reports this association is suggested.

SERIAL PLATELET DETERMINATIONS IN SEVEN CONSECUTIVE CASES OF INFECTIOUS MONONUCLEOSIS

The platelet count in infectious mononucleosis is said to be normal,¹³⁻¹⁵ and several authors have considered this to be important in distinguishing infectious mononucleosis from acute leukemia. However, no report of serial platelet counts in infectious mononucleosis has been found in the literature. We have performed platelet counts at frequent intervals in 7 consecutive patients with infectious mononucleosis.

Methods

The patients comprising this study were students reporting to the Student Health Service at the Chicago Campus of Northwestern University. In all cases the diagnosis was established on the basis of the blood studies, the heterophil antibody test and the clinical course. The heterophil antibody test was performed by the revised method of Davidsohn,¹⁶ in which agglutination in a titer of 1:224 or over is considered diagnostic. The liver function was assayed by means of the cephalin-cholesterol flocculation¹⁷ and the sulfbromophthalein excretion¹⁸ tests. In the latter, readings were made forty-five minutes after the injection of 5 mg. of the dye per kilogram of body weight.

Determinations of the red and white blood cell counts, the differential count, and the blood platelet count were made as soon as infectious mononucleosis was suspected and repeated two or three times a week until the acute phase of the disease had subsided. The indirect method of counting platelets was used in this study. A drop of refrigerated platelet solution (sodium citrate 3.0 grams, distilled water 100 cc., and neutral formalin 5.0 cc.) is placed in a paraffin cup. Blood from a deep puncture of the finger is introduced directly into the solution in a ratio of approximately 1:1. The mixture is pipetted into a white blood pipet and mixed briefly by gentle agitation. Blood films are made from the mixture on clean glass slides which are then air-dried and stained with Wright's stain. The count is determined by recording the number of platelets seen in counting 100 red blood cells in each of ten different areas on three slides. The number of platelets is then calculated on the basis of a red blood cell count done at the same time. By this technic, the platelet count of normal individuals falls between 200,000 and 300,000 per cu. mm.

Results

Of the 7 cases studied, 6 were seen during the first week of symptoms. In 4 of these patients the initial platelet count fell below the lower limit of normal (see figures 1 and 2). In another (Case 2), the initial count was normal, but a count two days later was definitely low. In Case 4, the initial platelet count was just above the

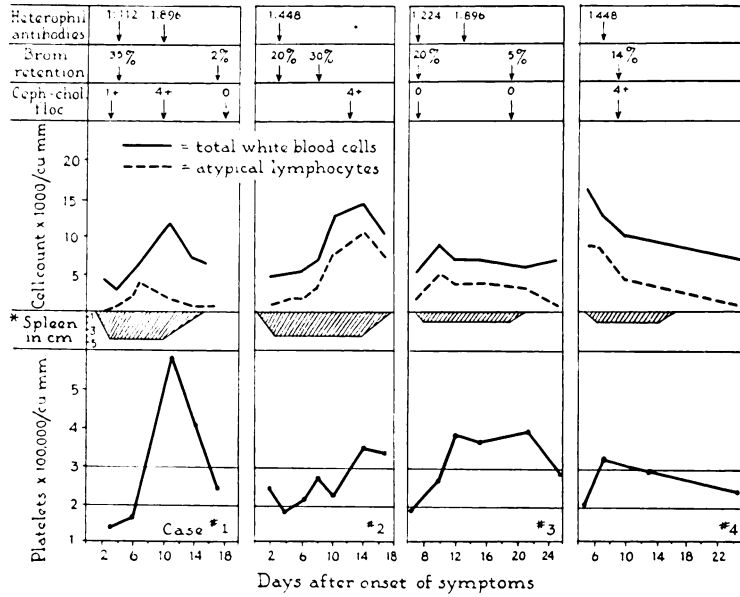


FIG. 1.—Serial Platelet Counts in Infectious Mononucleosis. (* Centimeters spleen palpable below costal margin.)

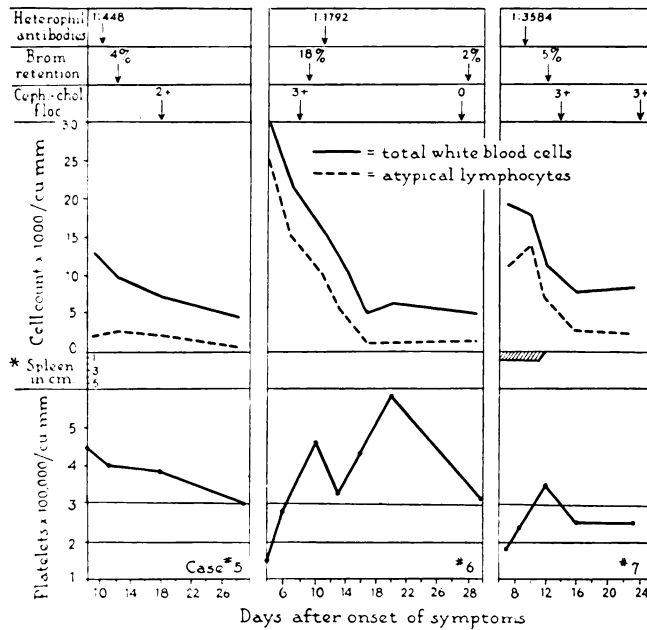


FIG. 2.—Serial Platelet Counts in Infectious Mononucleosis. (* Centimeters spleen palpable below costal margin.)

lower limit of normal. All 6 of these patients showed a subsequent rise to above the upper limit of normal. The increase varied from one and one-half to over four times the lowest count and occurred during the second week of the disease. Usually the platelet count returned to normal limits after the end of the third week, but in one case it was still elevated in the fifth week. One patient (Case 5) was not seen until the second week of illness, when the platelet count was well above the normal range. The count gradually decreased and reached normal during the fourth week.

All patients except Case 2 had a relatively mild febrile course. Six of the 7 cases showed evidence of abnormal liver function as determined by cephalin-cholesterol flocculation and/or the sulfbromophthalein excretion tests. In Case 5, there was no definite evidence of liver involvement. The spleen was palpable in 5 cases, but it was not possible to correlate spleen size with the depression of platelets. There was also no consistent correlation between the leukocyte and platelet counts. In 3 patients in whom the initial white blood cell count was normal or low (Cases 1, 2, and 3), the maximum thrombocytosis occurred with or shortly after the maximum elevation of the leukocyte count. In Cases 4, 6, and 7, the thrombocytosis occurred while the white blood cell count was falling. In Case 5, the maximum white blood cell and platelet counts were present at the first examination and the fall to normal of both counts was parallel. In general, thrombocytosis could be correlated only with regression of symptoms. In all patients a feeling of marked improvement was noted at about the time the maximum platelet count was observed.

COMMENT

It is quite possible that the occasional association of thrombocytopenic purpura with infectious mononucleosis and the mild platelet depression demonstrated in uncomplicated cases of this disease represent different degrees of the same phenomenon.

Thrombocytopenic purpura, usually of the transient type, has been reported in a variety of viral and bacterial infections.^{14, 19-21} Also, an early depression of the platelets with a subsequent rise above normal has been observed in measles, typhoid fever, typhus, influenza, pneumonia, and other infections.^{22, 23} Suggested causes for the thrombocytopenia during infection are increased utilization and destruction of platelets and toxic depression of the bone marrow.²² The possible role of the spleen must also be considered.

Abnormal splenic function or so-called hypersplenism may cause a reduction in any or all of the formed elements of the blood. The abnormal spleen destroys and/or inhibits the formation and delivery of the blood cells. Primary hypersplenic syndromes include congenital hemolytic anemia, splenic neutropenia,²⁴ idiopathic thrombocytopenic purpura, and splenic panhematopenia.²⁵ Thrombocytopenia due to hypersplenism is encountered in a number of diseases involving the spleen, e.g., cirrhosis of the liver, Gaucher's disease, Felty's syndrome, and sarcoidosis.²⁶ The megakaryocytes in the bone marrow are increased and splenectomy is usually followed by a rapid rise in the platelet count.

Thrombocytopenia in infectious mononucleosis might also be due to splenic dysfunction. The spleen is palpable in over half of the cases of this disease and is undoubtedly involved in all cases. Limarzi et al.²⁷ noted a mild increase in the bone marrow megakaryocytes in 15 out of 25 cases of infectious mononucleosis. Hemolytic anemia, another manifestation of hypersplenism, has been reported in 3 cases of infectious mononucleosis.²⁸⁻³⁰ One patient, a Negro, recovered following splenectomy,³⁰ while the other patients recovered spontaneously.

Practically all patients with infectious mononucleosis have some degree of hepatitis^{31, 32} and the disease at times closely resembles infectious hepatitis. Three cases have been reported of thrombocytopenic purpura complicating infectious hepatitis.³³⁻³⁵ Here again, the spleen may be an important factor in the pathogenesis of the thrombocytopenia.

SUMMARY

A case has been presented in which thrombocytopenic purpura was a complication of infectious mononucleosis. A review of the literature revealed 6 other cases in which there was an association between these conditions. Serial platelet counts were made in 7 consecutive cases of infectious mononucleosis. There was a slight depression of the platelets early in the illness, followed by a thrombocytosis and a subsequent return to normal. Hypersplenism is considered as a possible cause for the thrombocytopenia in infectious mononucleosis.

REFERENCES

- ¹ MAGNER, W., AND BROOKS, E. F.: Infectious mononucleosis with acute thrombopenic purpura. *Canad. M. A. J.* 47: 35, 1942.
- ² TAGER, M., AND KLINGHOFFER, K. A.: Acute thrombocytopenic purpura hemorrhagica with lymphocytosis; Report of a case. *Ann. Int. Med.* 18: 96, 1943.
- ³ LLOYD, P. C.: Acute thrombocytopenic purpura in infectious mononucleosis. *Am. J. M. Sc.* 207: 620, 1944.
- ⁴ GOLDBLOOM, A. A., AND DENTON, R.: Infectious mononucleosis complicated by thrombocytopenic purpura. *Canad. M. A. J.* 58: 189, 1948.
- ⁵ BERNSTEIN, A.: Infectious mononucleosis. *Medicine* 19: 85, 1940.
- ⁶ DAMESHEK, W., AND GRASSI, M. H.: Infectious lymphadenosis (mononucleosis) and thrombocytopenic purpura; Recovery after splenectomy; Report of a case. *Blood* 1: 339, 1946.
- ⁷ MINOT, G. R.: A non-fatal case simulating acute leukemia with anemia and thrombopenic purpura. *M. Clin. North America* 13: 1 (July), 1929.
- ⁸ WILLIAMS, H. J.: Discussion on glandular fever. *Proc. Roy. Soc. Med.* 25: 155, 1931.
- ⁹ MINOT, G. R.: Purpura hemorrhagica with lymphocytosis: An acute type and an intermittent menstrual type. *Am. J. M. Sc.* 192: 445, 1936.
- ¹⁰ COOLEY, L. E.: Lymphoid hyperplasia associated with thrombopenic purpura. *Arch. Path.* 26: 390, 1938.
- ¹¹ ROSENTHAL, N.: The course and treatment of thrombopenic purpura. *J. A. M. A.* 112: 101, 1939.
- ¹² GOLDBLOOM, A. A., AND LIEBERSON, A.: A case of infectious mononucleosis with jaundice and thrombocytopenic purpura. *Am. J. Med.* 5: 912, 1948.
- ¹³ DOWNEY, H. M.: *Handbook of Hematology*. New York, Paul B. Hoeber, 1938. Vol. IV, p. 2677.
- ¹⁴ WINTROBE, M. M.: *Clinical Hematology*, ed. 2. Philadelphia, Lea & Febiger, 1946.
- ¹⁵ MEYER, O. O.: Estimation of the blood platelets as an aid in diagnosis. *Wisconsin M. J.* 35: 894, 1936.
- ¹⁶ DAVIDSOHN, I., AND WALKER, P. H.: The nature of the heterophilic antibodies in infectious mononucleosis. *Am. J. Clin. Path.* 5: 455, 1935.

- ¹⁷ NEEFE, J. R., AND REINHOLD, J. G.: Photosensitivity as a cause of falsely positive cephalin-cholesterol flocculation tests. *Science* 100: 82, 1944.
- ¹⁸ MATEER, J. G., BALTZ, J. I., COMANDURAS, P. D., STEELE, H. H., AND BROUWER, S. W.: Further advances in liver function tests and the value of a therapeutic test in facilitating the earlier diagnosis and treatment of liver impairment. *Gastroenterology* 8: 52, 1947.
- ¹⁹ FOX, M. J., AND WALTON, W. P.: Thrombocytopenia complicating rubella. *Marquette Med. Rev.* 11: 208, 1946.
- ²⁰ FOWLER, W. M.: Thrombopenic purpura; An analysis of 160 cases. *Ann. Int. Med.* 9: 1475, 1936.
- ²¹ McLEAN, S., KREIDEL, K., AND CAFFEY, J.: Hemorrhagic thrombocytopenia in childhood; Clinical study of twenty-one cases. *J.A.M.A.* 98: 387, 1932.
- ²² TOCANTINS, L. M.: The mammalian blood platelet in health and disease. *Medicine* 17: 155, 1938.
- ²³ REIMANN, H. A.: The blood platelets in pneumococcus infections. *J. Exper. Med.* 40: 553, 1924.
- ²⁴ WISEMAN, B. K., AND DOAN, C. A.: Primary splenic neutropenia; A newly recognized syndrome closely related to congenital hemolytic icterus and essential thrombocytopenic purpura. *Ann. Int. Med.* 16: 1097, 1942.
- ²⁵ DOAN, C. A., AND WRIGHT, C.: Primary congenital and secondary acquired splenic panhematopenia. *Blood* 1: 10, 1946.
- ²⁶ DAMESHEK, W., AND MILLER, E. B.: The megakaryocytes in idiopathic thrombocytopenic purpura, a form of hypersplenism. *Blood* 1: 27, 1946.
- ²⁷ LIMARZI, L. R., PAUL, J. T., AND PONCHER, H. G.: Blood and bone marrow in infectious mononucleosis; A review of the literature and a report of twenty-five cases. *J. Lab. & Clin. Med.* 31: 1079, 1946.
- ²⁸ ELLIS, L. B., WOLLENMAN, O. J., AND STETSON, R. P.: Autohemagglutinins and hemolysins with hemoglobinuria and acute hemolytic anemia in an illness resembling infectious mononucleosis. *Blood* 3: 419, 1948.
- ²⁹ APPLEMAN, D. H., AND MORRISON, M. M.: Concomitant infectious mononucleosis and hemolytic icterus. *Blood* 4: 186, 1949.
- ³⁰ WILSON, S. J., WARD, C. E., AND GRAY, L. W.: Infectious lymphadenosis (mononucleosis) and hemolytic anemia in a Negro; Recovery following splenectomy. *Blood* 4: 189, 1949.
- ³¹ COHN, C., AND LIDMAN, B. I.: Hepatitis without jaundice in infectious mononucleosis. *J. Clin. Investigation* 25: 145, 1946.
- ³² DEMARSH, Q. B., AND ALT, H. L.: Hepatitis without jaundice in infectious mononucleosis. *Arch. Int. Med.* 80: 257, 1947.
- ³³ ALT, H. L., AND SWANK, R. L.: Thrombopenic purpura associated with catarrhal jaundice; Report of a case. *Ann. Int. Med.* 10: 1049, 1937.
- ³⁴ —, CARROLL, H. B., AND DOHERTY, C. C.: Thrombopenic purpura associated with catarrhal jaundice; Report of a case during pregnancy. *Quart. Bull. Northwestern Univ. M. School* 14: 183, 1940.
- ³⁵ WOODWARD, T. E.: Thrombocytopenic purpura complicating acute catarrhal jaundice; Report of a case, review of the literature, and review of 48 cases of purpura at University Hospital. *Ann. Int. Med.* 19: 799, 1943.