

Increased Expression of the *Cyclin D1* Gene in Barrett's Esophagus¹

Nadir Arber, Charles Lightdale, Heidrun Rotterdam, Edward Kyu-Ho Han, Alessandro Sgambato, Eric Yap, Habibul Ahsan, Jonathan Finegold, Peter D. Stevens, Peter H. R. Green, Hanina Hibshoosh, Alfred I. Neugut, Peter R. Holt, and I. Bernard Weinstein²

Columbia-Presbyterian Cancer Center [N. A., E. K-H. H., A. S., A. I. N., I. B. W.], Departments of Medicine [C. L., E. Y., J. F., P. D. S., P. H. R. G., A. I. N., I. B. W.] and Pathology [H. R., H. H.], School of Public Health [H. A., A. I. N., I. B. W.], and Division of Gastroenterology, Saint Luke's-Roosevelt Hospital Center [N. A., P. R. H.], Columbia University, New York, New York 10032

Abstract

Previous studies have found a 3–10-fold amplification and overexpression of the *cyclin D1* gene in about 32% of human esophageal squamous cell carcinoma. The purpose of this study was to evaluate the prevalence of increased expression of the cyclin D1 protein in Barrett's esophagus. Using 69 formalin-fixed and paraffin-embedded human esophageal specimens, which had been removed endoscopically or obtained at surgery during 1993 and 1994, all immunohistochemical analyses were performed using an avidin-biotin complex immunoperoxidase technique. Increased nuclear expression of the cyclin D1 protein was noted in 32 of 69 samples (46%; 44% of the samples from males and 50% of the samples from females). Positive nuclear staining for the cyclin D1 protein in Barrett's disease with intestinal metaplasia was found in 38% of the male cases and 25% of the female cases, whereas in gastric metaplasia it was positive in 33% of men and 48% of women. Nuclear accumulation of the cyclin D1 protein was also found in both dysplastic and nondysplastic lesions, and it was not associated with sex, age, or cigarette or alcohol consumption. Samples from patients taking proton pump inhibitors tended to be less frequently positive (32%) for cyclin D1 nuclear staining when compared to patients taking H₂ antagonists (45%) or antacids (55%). These studies suggest that increased expression of *cyclin D1* is an early event in the tumorigenic process of esophageal adenocarcinomas and that the increased expression of this gene might predispose the epithelium to malignant transformation.

Received 11/7/95; revised 3/8/96; accepted 3/11/96.

The costs of publication of this article were defrayed in part by the payment of page charges. This article must therefore be hereby marked *advertisement* in accordance with 18 U.S.C. Section 1734 solely to indicate this fact.

¹ This study was supported by funding from the Dorot Foundation and the National Dairy Council (to N. A. and P. R. H.), the Italian Association for Cancer Research (to A. S.), and the National Foundation for Cancer Research and the Lucille Markey Charitable Trust (to I. B. W.).

² To whom requests for reprints should be addressed, at Columbia Presbyterian Cancer Center, Columbia University, College of Physicians and Surgeons, HHSC-1509, 701 West 168th Street, New York, NY 10032.

Introduction

Adenocarcinomas arising in Barrett's esophagus were once rare, but in the 1970s and 1980s their incidence increased more rapidly than that of any other cancer in the United States. Adenocarcinomas now constitute up to 34% of all esophageal cancers. They are especially common in white males, in whom adenocarcinoma of the esophagus is now as frequent as squamous cell carcinoma (1–3).

The exact pathological progression from Barrett's metaplasia to carcinoma is still unknown, although progression from metaplasia to low-grade dysplasia through high-grade dysplasia and finally to adenocarcinoma has been suggested (4–6). Thus, identification of changes in the molecular genetics and cellular physiology that take place in the progression from Barrett's esophagus to esophageal adenocarcinoma would be of interest for developing prevention and treatment strategies.

Progression of cells through the cell cycle is governed by the sequential formation, activation, and degradation of a series of cyclins and CDK³ complexes. These complexes play a critical role in cell proliferation and differentiation. There are at least 11 distinct cyclin genes in the human genome that can bind to and activate a series of at least seven CDKs (for review, see Ref. 7).

Rearrangement, amplification, and/or increased expression of the *cyclin D1* gene have been reported in human parathyroid adenomas, B-cell lymphomas, breast, colon, lung, and bladder cancers, hepatomas, and squamous cell carcinomas of the esophagus and head and neck (7–11). Thus, *cyclin D1* may act as a cellular oncogene. A 3–10-fold amplification and overexpression of the *cyclin D1* gene was found in 32% of human esophageal squamous cell carcinomas and in two out of four esophageal carcinoma cell lines (8). Using immunohistochemistry, we have noted overexpression of this protein in 64% of a series of 22 samples of esophageal adenocarcinomas.⁴ Therefore, we undertook the present study to evaluate the levels of expression of the cyclin D1 protein in a series of biopsies of Barrett's esophagus lesions.

Materials and Methods

A total of 84 tissue sections from 69 patients with Barrett's esophagus were studied. Formalin-fixed, paraffin-embedded specimens were obtained from the Department of Pathology at Columbia-Presbyterian Medical Center in New York. The tissues had been removed endoscopically or obtained at surgery during 1993 and 1994 and had been processed by routine clinical histopathological methods. Barrett's esophagus was diagnosed if biopsies showed either intestinal or gastric metaplasia. Intestinal metaplasia was defined as columnar mucosa with a villiform surface and intestinal-type crypts lined by mucus-secreting columnar cells and goblet cells. Gastric meta-

³ The abbreviation used is: CDK, cyclin-dependent kinase.

⁴ N. Arber, M. Gammon, H. Hibshoosh, J. Britton, Y. Zhang, J. Schoenberg, H. Rotterdam, P. Holt, and I. B. Weinstein, submitted for publication.

Table 1 Increased expression of cyclin D1 in Barrett's esophagus

	No. of cases	Cyclin D1 nuclear staining (%)
Male	39	17 (44)
Intestinal metaplasia	38	15 (38)
Gastric metaplasia	36	12 (33)
Female	30	15 (50)
Intestinal metaplasia	24	6 (25)
Gastric metaplasia	29	14 (48)
Drugs		
Proton pump inhibitors	22	7 (32)
H ₂ antagonist	20	9 (45)
Antacids	22	12 (55)
Race		
Caucasian	35	20 (57)
Non-Caucasian	17	9 (53)
Smoking		
Ever	23	13 (57)
Never	23	12 (52)
Alcohol		
No	19	9 (47)
Yes	22	13 (59)
Total	69	32 (46)

plasia was defined as columnar lined mucosa with cardiac-type mucinus glands, or gastric glands with chief and parietal cells.

All immunohistochemical analyses were performed with an avidin-biotin complex immunoperoxidase technique. Tissue sections 5 μ m thick were mounted on poly-L-lysine coated slides. After deparaffinization in Americlear (Baxter, McGaw Park, IL) and absolute ethanol, sections were hydrated through a series of graded alcohols, distilled water, and PBS at pH 7.4. Slides were then immersed in 10 mM citrate buffer (pH 6) and microwaved at 750 W (to enhance antigen exposure) for a total of 10 min. After blocking with goat serum for 20 min, the primary antibody, polyclonal IgG rabbit antihuman cyclin D1 (Upstate Biotechnology, Lake Placid, NY) was applied and incubated overnight at 4°C in a high-humidity chamber. As a negative control, a duplicate section of each tissue sample was immunostained in the absence of the primary antibody. A breast carcinoma with known cyclin D1 overexpression served as a positive control. Subsequent steps used the Vectastain Elite ABC kit (Vector laboratories, Burlingame, CA) according to the manufacturer's instructions. Color development was accomplished with a 0.375 mg/dl solution of 3,3'-diamino-benzidine tetrahydrochloride (Sigma Chemical Co., St. Louis, MO), containing 0.003% hydrogen peroxide. Slides were counterstained with hematoxylin and dehydrated, and coverslips were applied using Acrytol mounting medium (Surgipath Medical Industries, Richmond, IL). The specificity of the antibody has been demonstrated (data not shown) by inhibition of immunohistochemical staining in positive controls by preincubating the antibody with 1 μ g of cyclin D1 immunizing peptide (M_r 1413, amino acids 285–295) for 1 h at 4°C (Upstate Biotechnology, Lake Placid, NY, Catalog No. 12-167), representing an approximately 100-fold excess of peptide over antibody. We should emphasize that the polyclonal antibodies used in this study recognize both the cyclin D1 and cyclin D2 proteins. However, Jiang *et al.* (8, 12) showed that increased expression in esophageal tumors is mainly cyclin D1. It is therefore likely that the immunostaining results obtained in the

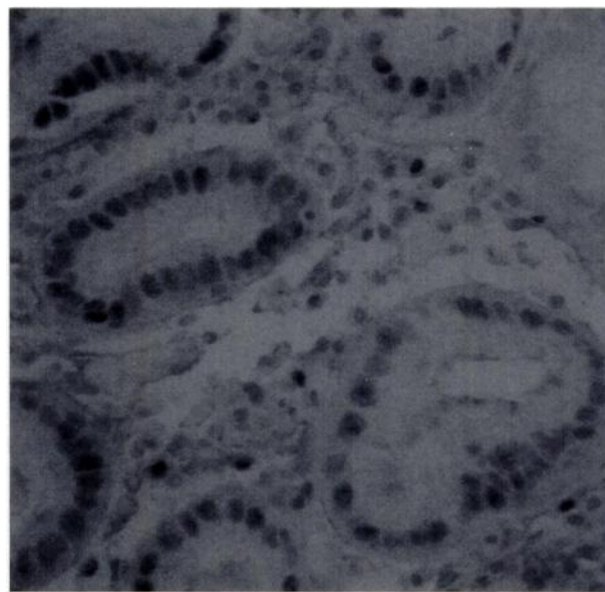


Fig. 1. Example of cyclin D1-positive nuclear staining. The immunoreactivity is located in the nuclei of a Barrett's esophagus lesion displaying gastric metaplasia. $\times 250$.

present study mainly reflect the abundance of the cyclin D1 protein.

All slides were independently interpreted by two of the authors (H. R. and N. A.). Positive and negative control slides were included within each batch of immunostained slides. Twenty-five % of the slides were randomly chosen and scored twice in the same batch. All batches were coded and scored blind twice. All duplicate slides resulted in similar interpretations. Nuclear staining was considered positive if the chromogen was detected in at least 5% of the nuclei within a microscopic field. Staining intensity included four scales: no staining (scale 0), weakly positive compared to adjacent nonneoplastic epithelium (scale 1), moderately positive (scale 2), and strongly positive (scale 3). Scales 0 and 1 were regarded as negative and scales 2 and 3 as positive. Nonneoplastic epithelial cells and stromal and inflammatory cells were also evaluated for cyclin D1 expression.

Results and Discussion

Samples from 69 patients were evaluated. In 15 patients, 2 biopsies from different levels of the lesions were evaluated. In all of these cases the same results were obtained in the two samples. The patients were 39 men and 30 women with a mean age \pm SE of 65.8 ± 7.9 and 63.7 ± 8.5 years, respectively (range, 27–89 years). As can be seen in Table 1, increased nuclear expression of the cyclin D1 protein (Fig. 1) was noted in 32 patients (46%), 44% of the males and 50% of the females. Positive nuclear staining for cyclin D1 protein in lesions displaying intestinal metaplasia was found in 38% of males and 25% of females, whereas in lesions displaying gastric metaplasia, nuclear staining was positive in 33% of males and 48% of females. Eight patients had dysplastic lesions and four of them showed positive nuclear staining for cyclin D1. There was no specific pattern of staining in this group. Nuclear staining for cyclin D1 was negative (on the 0–4 scale, 0 or 1) in the normal mucosa of all the 84 biopsies evaluated, and the small number

of positive cells was restricted to the basal layer. Only 32% of the samples from patients treated with proton pump inhibitors showed increased expression of cyclin D1, as compared to 45 and 55% of samples from patients treated with H₂ antagonists or other drugs, respectively. However, the series was too small to demonstrate that these differences were statistically significant. Nuclear staining was not significantly associated with age, gender, race, alcohol, smoking, type of metaplasia, or degree of dysplasia. Thus, about 46% of Barrett's esophagus samples showed increased nuclear expression of the cyclin D1 protein when compared to normal esophageal mucosa. This was found in both dysplastic and nondysplastic lesions, and in lesions with intestinal or gastric metaplasia. An approximately similar percent of esophageal squamous cell carcinomas and adenocarcinomas also display increased expression of cyclin D1 (8).⁴ Previous studies of squamous carcinomas of the esophagus, obtained from patients in China, Italy, France, South Africa, or the United States, indicated that about 30–50% of these cases display a 3 to 10-fold amplification of the *cyclin D1* gene, as well as increased expression of this gene at the mRNA and protein levels (8, 12–14). Similar findings have been seen with cell lines established from squamous carcinomas of the esophagus (12, 14). On the other hand, a study by Wang *et al.* (15) detected only a slight increase in cyclin D1 protein in squamous carcinomas of the esophagus and adenocarcinomas of the gastric cardia obtained from China, but their immunostaining method may not have been sufficiently sensitive.

The present study suggests that increased expression of cyclin D1 may be an early event in the development of adenocarcinomas of the esophagus. Other changes described previously in Barrett's lesions include microsatellite instability; loss of p53; APC mutations; and increased expression of C-NEU, TGF α , and PCNA (16–21). Reid *et al.* (16) have suggested that an early event in neoplastic progression in Barrett's esophagus is mobilization of cells from the G₀ phase to G₁, loss of control of the G₁-S transition, and accumulation in G₂. Increased expression of the *cyclin D1* gene in Barrett's esophagus might be responsible for some of these events, through the interactions of cyclin D1 and its associated CDK4 and CDK6 kinases with the *Rb* tumor suppressor gene (8). Southern blot analysis on 18 pairs of DNA samples from Barrett's lesions and adjacent normal mucosa indicated no evidence of significant amplification of the *cyclin D1* gene. Therefore, the increased expression of cyclin D1 protein seen in 46% of the Barrett's lesions does not appear to be due to gene amplification. This is similar to the situation in colon cancer (22).⁵ We believe that increased expression of cyclin D1 is an early event that may precede the expansion of the Ki-67 proliferative compartment since it was seen in equal percentage in both gastric and intestinal metaplasia, and dysplastic and nondysplastic lesions, while the expansion of the Ki-67 compartment gradually increases from low-grade to high-grade dysplastic Barrett's lesions. Thus, although increased expression of cyclin D1 may predispose the epithelium to malignant transformation, other events have to occur for progression to a fully malignant tumor. Nevertheless the increased expression of cyclin D1 in Barrett's esophagus may be useful as a biomarker of early premalignant changes. Prospective studies are needed to evaluate the course of patients with Barrett's esophagus whose lesions do or do not show increased expression of cyclin D1.

⁵ T. Sutter, N. Arber, and I. B. Weinstein, unpublished studies.

Acknowledgments

We are grateful to Dr. Wei Jiang for his valuable advice.

References

- Blot, W. J., Devesa, S. S., Kneller, R. W., and Fraumeni, J. F. Rising incidence of adenocarcinoma of the esophagus and gastric cardia. *JAMA*, 265: 1287–1289, 1991.
- Blot, W. J., Devesa, S. S., and Fraumeni, J. F. Continuing climb in rates of esophageal adenocarcinoma: an update. *JAMA*, 270: 1320, 1993.
- Pera, M., Cameron, A. J., Trastek, V. F., Carpenter, H. A., and Zinmeister, A. R. Increasing incidence of adenocarcinoma of the esophagus and esophago-gastric junction. *Gastroenterology*, 104: 510, 1993.
- Skinner, D. B., Walther, B. C., Riddell, R. H., Schmidt, H., Iacone, C., and De-Meester, T. R. Barrett's esophagus: comparison of benign and malignant cases. *Ann. Surg.*, 198: 554–566, 1983.
- Hameeteman, W., Tytgat, G. N. J., Houthoff, H. J., and van den Tweel, J. G. Barrett's esophagus: development of dysplasia and adenocarcinoma. *Gastroenterology*, 96: 1249–1256, 1989.
- Reid, B. J. Barrett's esophagus and esophageal adenocarcinoma. *Gastroenterol. Clin. North. Am.*, 20: 817–834, 1991.
- Pines, J., and Hunter, T. Cyclins and cancer II: cyclin D1 and CDK inhibitors come of age. *Cell*, 79: 573–582, 1994.
- Jiang, W., Zhang, Y.-J., Kahn, S. M., Hollstein, M. C., Santella, R. M., Lu, S.-H., Harris, C. C., Montesano, R., and Weinstein, I. B. Altered expression of the cyclin D1 and retinoblastoma genes in human esophageal cancer. *Proc. Natl. Acad. Sci. USA*, 90: 9026–9030, 1993.
- Arber, N., Hibshoosh, H., Moss, S. F., Sutter, S., Zhang, Y., Begg, M., Wang, S., Weinstein, I. B., and Holt, P. R. Increased expression of cyclin D1 is an early event in multistage colorectal carcinogenesis. *Gastroenterology*, 110: 669–674, 1996.
- Berenson, J. R., Koga, H., Yang, J., Pearl, J., Holmes, E. C., and Figlin, R. Frequent amplification of the *bcl-1* locus in poorly differentiated squamous cell carcinoma of the lung. *Oncogene*, 5: 1343–1348, 1990.
- Proctor, A., Coombs, L., Cairns, J., and Knowels, M. Amplification at chromosome 11q13 in transitional cell tumors of the bladder. *Oncogene*, 6: 789–795, 1991.
- Jiang, W., Kahn, S. M., Tomita, N., Zhang, Y. J., Lu, S. H., and Weinstein, I. B. Amplification and expression of the human cyclin D gene in esophageal cancer. *Cancer Res.*, 52: 2980–2983, 1992.
- Adelaide, J., Monges, G., Derderian, C., Seitz, J. F., and Birnbaum, D. Oesophageal cancer and amplification of the human *cyclin D1* gene CCND1/PRAD1. *Br. J. Cancer*, 71: 64–68, 1995.
- Nakagawa, H., Zukerberg, L., Togawa, K., Meltzer, S. J., Nishihara, T., and Rustagi, A. K. Human cyclin D1 oncogene and esophageal squamous cell carcinoma. *Cancer (Phila.)*, 76: 541–549, 1995.
- Wang, L. D., Shi, T. S., Zhou, Q., Goldstein, S., Hong, J. Y., Shao, P., Qui, S. L., and Yang, C. S. Changes in p53 and cyclin D1 protein levels and cell proliferation in different stages of human esophageal and gastric-cardia carcinogenesis. *Int. J. Cancer*, 59: 514–519, 1994.
- Reid, B. J., Sanchez, C. A., Blount, P. L., and Levine, D. S. Barrett's esophagus: cell cycle abnormalities in advancing stages of neoplastic progression. *Gastroenterology*, 105: 119–129, 1993.
- Redd, J. L., Manin, B., Yin, J., Bell, J. D., Finkel, R. G., Rhyu, M.-G., *et al.* Microsatellite instability in esophageal cancer and Barrett's esophagus. *Gastroenterology*, 106: 431A, 1994.
- Flejou, J.-F., Muzeau, F., Hamelin, R., Laurent-Puig, P., Potet, F., and Thomas, G. TP53 gene mutations and p53 protein immunoreactivity in malignant and premalignant Barrett's esophagus. *Gastroenterology*, 106: 386A, 1994.
- Bilir, N., Sato, J., Appelman, H. D., Cherian, S., and Boland, C. R. Sequential loss of tumor suppressor genes in the evolution of cancer in Barrett's esophagus. *Gastroenterology*, 106: 372A, 1994.
- Finkel, R. G., Greenwald, B. D., Belani, C. P., Bell, J. D., Redd, J. L., Silverstein, R. J., Yin, J., Hudson, E., Cottrell, J., Krasna, M. J., and Meltzer, S. J. Loss of heterozygosity as a predictor of survival in esophageal carcinomas. *Gastroenterology*, 106: 385A, 1994.
- Kim, R., Clarke, M. C., Melhem, M. F., Finley, G. G., Meissler, A. L., Zary, J. T., and Reynolds, J. C. Expression of p53, C-NEU, TGF alpha and PCNA in Barrett's metaplasia and adenocarcinoma. *Gastroenterology*, 106: 402A, 1992.
- Leach, F. S., Elledge, J. E., Sherr, C. J., Wilson, J. K. V., Markowitz, S., Kinzler, K. W., and Vogelstein, B. Amplification of cyclin genes in colorectal carcinomas. *Cancer Res.*, 53: 1986–1989, 1993.