

# Pernicious Anemia without Gastric Atrophy and in the Presence of Free Hydrochloric Acid

## Report of a Case

By J. N. HARRIS-JONES, H. T. SWAN AND G. R. TUDHOPE

**A**DDISONIAN pernicious anemia is an expression of the deficiency of vitamin B<sub>12</sub> which results from lack of secretion of Castle's intrinsic factor in the stomach. It has been known to be associated with atrophy of the gastric mucosa for about 80 years<sup>1</sup> and with gastric achlorhydria for 70 years.<sup>2</sup> The latter has been so constant a finding that it has almost always been regarded as essential for the diagnosis. Sturgis<sup>3</sup> states that the diagnosis of pernicious anemia should not even be considered if free hydrochloric acid is present in the gastric secretions. Occasional reports have been published of apparent pernicious anemia associated with free hydrochloric acid in the stomach.<sup>4</sup> Proof is lacking in almost all such cases that the megaloblastic anemia has been due to deficiency of intrinsic factor and not to intestinal malabsorption, pregnancy, nutritional deficiency, or to other rarer causes, most of which are usually associated with free hydrochloric acid in the stomach.

The preparation of vitamin B<sub>12</sub> labeled with a radioactive isotope of cobalt has made available a more accurate technic for the study of intrinsic factor activity.<sup>5-6</sup> In addition, technics have been developed recently for the estimation of vitamin B<sub>12</sub> levels in the serum<sup>7-9</sup>; for the demonstration of folic acid malabsorption from the gut,<sup>10</sup> and for obtaining a biopsy of the gastric mucosa by a flexible gastric biopsy tube.<sup>11</sup>

Only one case has so far been published<sup>12</sup> using such technics to confirm the diagnosis of Addisonian pernicious anemia in a patient whose gastric mucosa showed a normal histologic pattern and secreted normal amounts of hydrochloric acid. We are reporting a second case, developing at the age of 16 years, and showing certain differences from the patient reported by Mollin, Baker and Doniach.<sup>12</sup>

### CASE REPORT

I. R., a girl 16 years old, was referred to hospital on December 6, 1955, because of increasing pallor, which had become particularly conspicuous in the preceding three months.

Fatigue and dyspnea on slight exertion, and soreness of the tongue had been present for six months. There had been no paresthesia. She had lost 21 pounds (9.5 Kg.) in weight and had vomited after meals for one month before admission. There was no history of diarrhea or gastrointestinal blood loss, and although her appetite was impaired there was no evidence that her diet was inadequate. She had had a transient attack of stomatitis at the age of 14 years.

She had been treated before admission with an oral preparation of iron, but she had not taken any anticonvulsants, sedatives or other drugs.

From the Royal Hospital, Sheffield and the Department of Pharmacology and Therapeutics, University of Sheffield, England.

Submitted Sept. 1, 1956; accepted for publication Nov. 26, 1956.

Her parents were healthy and unrelated; her brother and sister were also healthy. Examination of the blood and estimation of serum vitamin B<sub>12</sub> in father, mother and sister showed no abnormality. There was no history of pernicious anemia in her family.

The patient was of normal height and build, but there was evidence of recent weight loss. She was pale with icterus of the skin and sclera. There was a small solitary hemorrhage in the right retina. The tongue was smooth without being atrophic, and showed superficial ulceration along the right border. The spleen was enlarged to 5 cm. below the left costal margin, and was firm; the liver edge was just palpable. Examination of the respiratory, cardiovascular and nervous systems did not reveal any abnormalities.

A provisional clinical diagnosis of acute hemolytic anemia was not supported by the hematological findings, which showed a severe megaloblastic anemia consistent with pernicious anemia.

During the three days following her admission there was an alarming deterioration in her condition, associated with pyrexia rising to 40 C., and a drop in hemoglobin level from 7.4 Gm. (50%) to 5.0 Gm. (34%) per 100 ml. She was transfused with 1,000 ml. of packed red cells and she improved considerably. Intramuscular injections of 100 µg. vitamin B<sub>12</sub> were then given daily for three days, weekly for one month and thereafter at fortnightly intervals. From the end of the first month of treatment, ferrous gluconate, 1 Gm. daily, was given orally in addition to the parenteral vitamin B<sub>12</sub>. The peripheral blood rapidly returned to normal and she has remained in complete remission. By the end of the first month, the spleen was no longer palpable.

## INVESTIGATIONS

### *Hematology*

At the time of admission the peripheral blood showed anisocytosis and poikilocytosis, on the whole appearing macrocytic and normochromic with large granulocytes and occasional megaloblasts. The blood film was indistinguishable from one of true Addisonian pernicious anemia. Marrow smears obtained from iliac puncture showed megaloblastic erythropoiesis.

A reticulocyte peak of 20 per cent (dry method) was recorded on the seventh day of treatment with parenteral vitamin B<sub>12</sub>. Clinical recovery followed and was accompanied by a complete return to normal of all the elements of the blood which had been affected. Folic acid was not given for diagnostic purposes until the peripheral blood had returned to normal.

Details of some of the hematologic findings, and treatment are recorded in table 1.

Serum vitamin B<sub>12</sub> was kindly estimated by Dr. G. H. Spray of Oxford, who used a modification<sup>13</sup> of the method described by Girdwood<sup>9</sup> using *Lactobacillus leichmanii* as the test organism.

Duplicate assays of the serum vitamin B<sub>12</sub> before treatment showed the low levels of 50 µµg./ml. and 58 µµg./ml. (normal range 150 µµg./ml.–860 µµg./ml.).

### *Gastric function tests*

The fasting gastric juice contained the equivalent of 15 ml. of N/10 free hydrochloric acid per 100 ml.; this increased to 45 ml. following the subcutaneous injection of 0.25 mg. of histamine hydrochloride.

The peptic activity of the gastric juice was assayed by its effect on plasma substrate as described by Hunt,<sup>14</sup> digestion being estimated colorimetrically using the reagent of Folin and Ciocalteu.

The gastric juice was found to contain 75 Hunt units of pepsin per ml. This figure lies within the normal range for the method.

TABLE 1.—*Summary of Hematologic Data and Treatment*

Hematinic therapy	Date	Hb. Gm. %	R.B.C. mill. cu.mm.	W.B.C. cu.mm.	Platelets (Lempert) cu.mm.	Reticulo- cytes %
Nil	6/12/55	7.4	1.7	3,000	126,000	—
Packed red cells (1,000 ml.) Vit. B <sub>12</sub> commenced (100 µg. daily i.m.)	9/12/55	5.0	1.2	2,500	125,000	2
Vit. B <sub>12</sub> (100 µg. weekly i.m.)	12/12/55	7.4	2.0	2,300	100,000	3
	14/12/55	—	—	—	—	14
	15/12/55	9.2	2.4	2,500	—	20
	16/12/55	—	—	—	—	12
	19/12/55	12.0	3.6	5,000	497,000	6
Ferrous gluconate 1 Gm. daily Vit. B <sub>12</sub> (100 µg. i.m. fortnightly)	12/ 1/56	13.5	4.4	7,000	200,000	1
	7/ 3/56	15.8	5.0	8,000	—	—

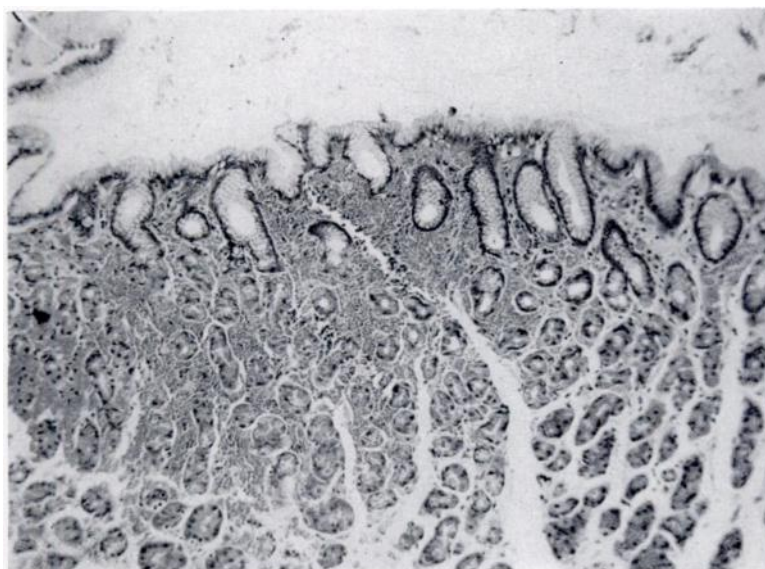


FIG. 1. — Section of mucosa from body of stomach showing normal histologic appearance  $\times 100$ .

#### *Gastric biopsy*

The two fragments of gastric mucosa (see figure 1) obtained by Wood's flexible gastric biopsy tube<sup>11</sup> showed a normal histologic picture.

#### *Radiology of small gut*

Using a nonflocculating opaque medium, radiologic studies failed to reveal a structural abnormality, and the mucosal pattern was normal.

*Fat balance*

The patient was given a diet containing 70 Gm. of fat daily, and following a preliminary period of two days, feces were collected over a four day period. By this method the fecal fat should not exceed 7 Gm. in 24 hours, representing an absorption of 90 per cent of dietary fat. In this patient there was an absorption of 92 per cent of dietary fat intake.

*Differential folic acid excretion test* was carried out as recommended by Girdwood.<sup>10</sup> Before the test the patient was given folic acid, 5 mg. by mouth three times daily for three weeks, in order to correct any tissue desaturation. On the first day of the test, 5 mg. of folic acid ("Folvite," Lederle) were injected subcutaneously and the urine passed in the subsequent 24 hours collected and assayed for the total amount of folic acid present. On the second day the same dose was given by mouth and the output of folic acid in the urine measured similarly.

The recovery from a 24 hour collection of urine after 5 mg. folic acid by subcutaneous injection was 3.2 mg. and after the same dose by mouth was 1.9 mg. The assays quoted here were kindly performed by Dr. R. H. Girdwood in Edinburgh, using microbiological methods with *Streptococcus fecalis* as the test organism. Dr. Girdwood considered that these figures did not represent intestinal malabsorption of folic acid.

*Studies with cobalt<sup>56</sup>-labeled vitamin B<sub>12</sub>*

The absorption of Co<sup>56</sup>-labeled vitamin B<sub>12</sub> was studied by measuring the urinary radioactivity following an oral dose of the isotope, together with intramuscular 'flushing' doses of unlabeled vitamin B<sub>12</sub> given simultaneously and again 24 hours later. The procedure was based on the method first described by Schilling<sup>6</sup> and modified by Ellenbogen and others.<sup>15</sup>

Vitamin B<sub>12</sub> labeled with cobalt<sup>56</sup>, with original activity 1.4  $\mu\text{c.}/\mu\text{g.}$ , was obtained in a concentration of 5  $\mu\text{g.}/\text{ml.}$  The dose given in each test was 0.6  $\mu\text{g.}$  or 1.0  $\mu\text{g.}$  made up to 10 ml. with distilled water and given as a drink, or by an intragastric tube, when gastric juice was also being given. The patient received this dose, with or without intrinsic factor, when fasting, and was allowed nothing else by mouth for at least two hours thereafter. Simultaneously with the oral dose of labeled vitamin B<sub>12</sub>, an intramuscular injection of 1 mg. of unlabeled vitamin B<sub>12</sub> was given as the first flushing dose. A second injection of 1 mg. of unlabeled vitamin B<sub>12</sub> was given after 24 hours. All urine was collected for two consecutive periods of 24 hours after the oral dose. Each 24 hour collection of urine was mixed, the volume was measured, and samples were taken for measurement of radioactivity.

In each test, duplicate standard dilutions were prepared with distilled water from the residue of the solution of Co<sup>56</sup>-labeled vitamin B<sub>12</sub> after the oral dose had been given.

The radioactivity of all samples and standard dilutions was measured with a scintillation counter (Ekeo type X 550). The mean coefficient of variation of repeated counts of the same solution of Co<sup>56</sup> was 1.9 per cent.

From the counts of the standard dilution, the total administered radioactivity was calculated. The total activity excreted in the urine in each 24 hour period was calculated and expressed as a percentage of the administered activity.

In one test with patient I.R., 0.25 mg. of carbachol was injected subcutaneously 15 minutes before the oral dose of labeled vitamin B<sub>12</sub> in order to stimulate the secretion of intrinsic factor.<sup>12</sup>

Human gastric juice was collected from normal adult subjects, filtered through butter muslin, pooled and stored at 4 C. until required. The duration of storage did not exceed 14 days. One hundred ml. of gastric juice was then given by intragastric tube. Gastric juice from patient I.R. was stored and given in the same manner.

An intrinsic factor preparation (Armour) from hog's duodenum was also used. Its potency had been tested previously and was further demonstrated by comparison with normal gastric juice (table 3). Fifty mg. of the dried powder was suspended in 50 ml. of water, half of this being drunk just before the oral dose of labeled vitamin B<sub>12</sub> and the other half immediately afterwards.

*Absorption of Co<sup>56</sup>-labeled vitamin B<sub>12</sub> by the patient I.R.* was assessed after the administration of the isotope, first by itself, then together with intrinsic factor, and finally after a subcutaneous injection of carbachol. The results are summarized in table 2. The amount of labeled vitamin B<sub>12</sub> excreted in the urine when the isotope was given without intrinsic factor is less than in any of the normal subjects studied by Schilling<sup>6</sup> or by Ellenbogen and his co-workers,<sup>15</sup> but it is slightly greater than the highest excretions in pernicious anemia in either of these previous reports. Ellenbogen and his associates<sup>15</sup> found that the urinary radioactivity during the first 24 hours after an oral dose of labeled vitamin B<sub>12</sub> in pernicious anemia was 0.0–2.6 per cent of the dose.

*Intrinsic factor activity* of the patient's gastric juice was studied in a known case of treated pernicious anemia. H., a man aged 69 years, who had pernicious anemia, volunteered to have these tests carried out when their nature and significance had been explained to him. H. had been treated with vitamin B<sub>12</sub> for 30 months and his blood was normal at the time of the tests. The effect of I.R.'s gastric juice on the absorption of labeled vitamin B<sub>12</sub> by H. was compared with that of normal pooled gastric juice and a preparation of animal intrinsic factor of proved activity.

The results are summarized in table 3. Gastric juice was collected from the

TABLE 2.—Tests of Absorption of Co<sup>56</sup>-Labeled Vitamin B<sub>12</sub> in Patient I.R.

Date	Co <sup>56</sup> -vitamin B <sub>12</sub> orally (μg.)	Intrinsic factor or carbachol	Unlabeled vitamin B <sub>12</sub> i.m. (mg.)	Radioactivity in 24 hour collection of urine (% of dose)
13/4/56	1.0	—	1	3.7
14/4/56	—	—	1	1.1
16/4/56	1.0	50 mg. intrinsic factor (Armour)	1	9.0
17/4/56	—	—	1	8.5
19/4/56	1.0	0.25 mg. carbachol s.c., 15 minutes before isotope given	1	10.5
20/4/56	—	—	1	5.2

TABLE 3.—*Tests of Intrinsic Factor Activity of Gastric Juice from Patient I.R., Carried Out on Subject H., A Known Case of Pernicious Anemia*

Date	Co <sup>56</sup> -vitamin B <sub>12</sub> orally (μg.)	Gastric juice or intrinsic factor	Unlabeled vitamin B <sub>12</sub> i.m. (mg.)	Radioactivity in 24 hour collection of urine (% of dose)
6/2/56	0.6	—	1	1.2
7/2/56	—	—	1	0.3
9/2/56	0.6	100 ml. gastric juice from patient I.R.	1	1.4
10/2/56	—	—	1	0.5
16/2/56	0.6	50 mg. intrinsic factor (Armour)	1	11.0
17/2/56	—	—	1	5.0
8/3/56	0.6	100 ml. pooled normal gastric juice	1	10.5
9/3/56	—	—	1	2.5
3/5/56	0.6	100 ml. gastric juice from patient I.R.	1	1.4
4/5/56	—	—	1	0.3

patient I.R. one month and again three months after admission to hospital. Both samples showed negligible intrinsic factor activity when given along with labeled vitamin B<sub>12</sub> to the known case of pernicious anemia. In this same subject, absorption of vitamin B<sub>12</sub> was increased to the normal range by pooled normal gastric juice and by animal intrinsic factor.

#### DISCUSSION

The interest aroused by a case of pernicious anemia with free hydrochloric acid in the stomach is due to its extreme rarity, and to the difficulty of proving that a patient who has had a megaloblastic marrow and who made an excellent response to vitamin B<sub>12</sub> therapy, has been suffering from the results of deficient intrinsic factor secretion.

A histamine-fast achlorhydria has long been considered mandatory for the diagnosis of pernicious anemia,<sup>16, 3</sup> but from time to time cases have been reported where the authors have claimed to present the exception to this rule. Askey<sup>4</sup> reviewed 47 such cases, which had been reported up to that time in adults and could accept only 15 of them as having clinical data which made pernicious anemia a reasonable possibility, but in his opinion none of the 15 was proved by "complete precise criteria" to be Addisonian pernicious anemia. He concluded that a histamine-fast achlorhydria was essential to the diagnosis.

Mollin and his associates<sup>12</sup> have reported one case in which a confident diagnosis of Addisonian pernicious anemia could be made, although the gastric mucosa was normal and free hydrochloric acid was present in the stomach.

In children, pernicious anemia is very rare, but when it does occur, free gastric hydrochloric acid appears to be less exceptional. Reisner and his co-workers<sup>17</sup> reviewed the reported cases of pernicious anemia in childhood and accepted

twelve, of whom five had free gastric hydrochloric acid. They described four more cases, of whom three had free acid at some stage; two of these patients responded promptly to oral vitamin B<sub>12</sub> accompanied by normal gastric juice, but oral vitamin B<sub>12</sub> alone was without effect.

The patient we report had a megaloblastic anemia which responded to parenteral vitamin B<sub>12</sub>. There was no evidence of malabsorption of fat or folic acid, of intestinal lesions, or of nutritional deficiency. Gastric juice was deficient in intrinsic factor. She absorbed subnormal amounts of Co<sup>56</sup>-labeled vitamin B<sub>12</sub> when this was given alone by mouth, but normal absorption occurred when the labeled vitamin B<sub>12</sub> was given either with intrinsic factor or when given 15 minutes after an injection of carbachol. In the case reported by Mollin and his associates<sup>12</sup> vitamin B<sub>12</sub> absorption remained subnormal after carbachol stimulation, whereas in our case it resulted in apparently normal absorption of vitamin B<sub>12</sub>. It is presumed that this effect resulted from increased secretion of intrinsic factor. In this respect it may be significant that the patient of Mollin and his associates had suffered from pernicious anemia for 17 years at the time of their investigations.

Thus, it seems reasonable to conclude that in our patient deficient intrinsic factor production led to failure of absorption of vitamin B<sub>12</sub>, resulting in a megaloblastic anemia which can, by definition, be called Addisonian pernicious anemia. The differences from typical pernicious anemia as seen in older patients were that intrinsic factor production was still possible, but only as a result of artificial stimulation, and that gastric function and histology were, in other respects normal. From biopsy studies, Joske, Finckh and Wood<sup>18</sup> found varying degrees of atrophy of the gastric mucosa to be the rule in pernicious anemia. Necropsy studies<sup>19, 20</sup> have also demonstrated the close association of gastric atrophy and pernicious anemia. The patient we report had a normal gastric mucosal histology, as had the patient studied by Mollin and his associates,<sup>12</sup> who suggested that the gastric atrophy of pernicious anemia might result from prolonged subclinical vitamin B<sub>12</sub> deficiency secondary to failure of intrinsic factor secretion. Evidence is presented which suggests that deficient production of intrinsic factor may occur at a time when the gastric mucosa is otherwise normal both histologically and functionally.

#### SUMMARY

A case is described of Addisonian pernicious anemia in a girl aged 16 years, associated with a normal gastric mucosa and free hydrochloric acid in the stomach. Partial, but significant deficiency of intrinsic factor activity was demonstrated in her gastric juice by the use of Co<sup>56</sup>-labeled vitamin B<sub>12</sub>.

#### SUMMARIO IN INTERLINGUA

Es describe un caso de anemia perniciose de Addison in un puera de 16 annos de etate, associate con normal mucosa gastric e libere acido chlorhydric in le stomacho. Un partial sed significative carentia del activitate de factor intrinsec esseva demonstrate in le succo gastric per medio de vitamin B<sub>12</sub> a Co<sup>56</sup>.

#### ACKNOWLEDGMENTS

We are grateful to patient H. for his willing co-operation; to Dr. C. E. Davies for permission to study cases under his care; to Dr. D. L. Mollin for his interest and advice,

and for supplies of Co<sup>56</sup>-vitamin B<sub>12</sub> and intrinsic factor; to Dr. Lester Smith of Glaxo Laboratories Ltd. for supplies of Co<sup>56</sup>-vitamin B<sub>12</sub> and to Armour Laboratories Ltd. for supplies of intrinsic factor. We are indebted to Dr. F. Lee for the gastric biopsy, to Professor D. H. Collins for the histological preparations and advice, and to Dr. A. Jordan for biochemical investigations. We are grateful to Professor G. M. Wilson, Dr. E. K. Blackburn and Dr. C. E. Davies for their helpful criticisms of this paper.

## REFERENCES

- <sup>1</sup> FENWICK, S.: Atrophy of the stomach. *Lancet* 2: 1-4, 1877.
- <sup>2</sup> CAHN, A. AND VON MERING, J.: Die Säuren des gesunden und kranken Magens. *Dtsch. Arch. klin. Med.* 39: 233, 1886.
- <sup>3</sup> STURGIS, C. C.: *Hematology*, 2nd ed. Springfield, Illinois, Charles C Thomas, 1955.
- <sup>4</sup> ASKEY, J. M.: Addisonian pernicious anemia without achlorhydria. Does it exist? *Gastroenterology* 2: 1-12, 1944.
- <sup>5</sup> HEINLE, R. W., WELCH, A. D., SCHARF, V., MEACHAM, C. AND PRUSOFF, W. H.: Studies of excretion (and absorption) of Co<sup>60</sup>-labeled vitamin B<sub>12</sub> in pernicious anemia. *Trans. A. Am. Phys.* 65: 214-222, 1952.
- <sup>6</sup> SCHILLING, R. F.: Intrinsic factor studies: II. The effect of gastric juice on the urinary excretion of radioactivity after the oral administration of radioactive vitamin B<sub>12</sub>. *J. Lab. & Clin. Med.* 42: 860-866, 1953.
- <sup>7</sup> ROSENTHAL, H. L. AND SARETT, H. P.: The determination of vitamin B<sub>12</sub> activity in human serum. *J. Biol. Chem.* 199: 433-442, 1952.
- <sup>8</sup> ROSS, G. I. M.: Vitamin B<sub>12</sub> assay in body fluids using *Euglena Gracilis*. *J. Clin. Path.* 5: 250-256, 1952.
- <sup>9</sup> GIRDWOOD, R. H.: Rapid estimation of the serum vitamin B<sub>12</sub> level by a microbiological method. *Brit. M. J.* 2: 954-956, 1954.
- <sup>10</sup> —: A folic-acid excretion test in the investigation of intestinal malabsorption. *Lancet* 2: 53-60, 1953.
- <sup>11</sup> WOOD, I. J., DOIG, R. K., MOTTERAM, R. AND HUGHES, A.: Gastric biopsy. Report on fifty-five biopsies using a new flexible gastric biopsy tube. *Lancet* 1: 18-21, 1949.
- <sup>12</sup> MOLLIN, D. L., BAKER, S. J. AND DONIACH, I.: Addisonian pernicious anemia without gastric atrophy in a young man. *Brit. J. Haemat.* 1: 278-290, 1955.
- <sup>13</sup> SPRAY, G. H.: An improved method for the rapid estimation of vitamin B<sub>12</sub> in serum. *Clin. Sc.* 14: 661-667, 1955.
- <sup>14</sup> HUNT, J. N.: A method for estimating peptic activity in gastric contents. *Biochem. J.* 42: 104-109, 1948.
- <sup>15</sup> ELLENBOGEN, L., WILLIAMS, W. L., RABINER, S. F. AND LICHTMAN, H. C.: An improved urinary excretion test as an assay for intrinsic factor. *Proc. Soc. Exper. Biol. & Med.* 89: 357-362, 1955.
- <sup>16</sup> MOSHCOWITZ, E.: The relation of achlorhydria to pernicious anemia. *Arch. Int. Med.* 48: 171-186, 1931.
- <sup>17</sup> REISNER, E. H., WOLFF, J. A., MCKAY, R. J. AND DOYLE, E. F.: Juvenile pernicious anemia. *Pediatrics* 8: 88-106, 1951.
- <sup>18</sup> JOSKE, R. A., FINCKH, E. S. AND WOOD, I. J.: Gastric biopsy. A study of 1,000 consecutive successful gastric biopsies. *Quart. J. Med.* 24: 269-294, 1955.
- <sup>19</sup> MAGNUS, H. A. AND UNGLEY, C. C.: The gastric lesion in pernicious anemia. *Lancet* 1: 420-421, 1938.
- <sup>20</sup> COX, A. J.: The stomach in pernicious anemia. *Am. J. Path.* 19: 491-502, 1943.