

# Microscopic and Early-Stage Ovarian Cancers in *BRCA1/2* Mutation Carriers: Building a Model for Early *BRCA*-Associated Tumorigenesis

Melinda S. Yates<sup>1</sup>, Larissa A. Meyer<sup>1</sup>, Michael T. Deavers<sup>2</sup>, Molly S. Daniels<sup>1</sup>, Elizabeth R. Keeler<sup>1</sup>, Samuel C. Mok<sup>1</sup>, David M. Gershenson<sup>1</sup>, and Karen H. Lu<sup>1</sup>

## Abstract

Risk-reducing salpingo-oophorectomy (RRSO) is the cornerstone of ovarian cancer prevention in *BRCA1/2* mutation carriers. Occult fallopian tube and ovarian cancers have been reported in a small percentage of *BRCA1/2* mutation carriers undergoing RRSO. Here, we review our single-institution experience with RRSO in *BRCA1/2* mutation carriers to characterize cases of microscopic cancers in these patients. At the time of RRSO, 7.9% of *BRCA1* mutation carriers were diagnosed with microscopic fallopian tube or ovarian cancers and no cases were diagnosed in *BRCA2* mutation carriers. The majority of the microscopic cancers include cases that were confined to the fallopian tubes, although there were also cases involving ovaries only or peritoneal washings only. This suggests that the site of origin may be in the ovary, fallopian tube, or peritoneum for *BRCA*-associated serous cancers. However, an analysis of early-stage (stages I and II) ovarian and fallopian tube cancers diagnosed in *BRCA1/2* mutation carriers confirms that the ovary is a preferred site for tumor growth with 11 of 14 early-stage cancers having a dominant ovarian mass. Overall, these data suggest that cancer initiation may occur in the ovary, fallopian tube, or peritoneum, but tumor growth and progression are favored in the ovary. We present an updated model for *BRCA1/2* mutation-associated ovarian and fallopian tube carcinogenesis, which may aid in identifying improved prevention strategies for high-risk women who delay or decline RRSO. *Cancer Prev Res*; 4(3); 463–70. ©2011 AACR.

## Introduction

Women with germline mutations of the tumor suppressor genes *BRCA1* or *BRCA2* have a high lifetime risk of developing ovarian cancer (~39% and 22%, respectively; ref. 1). Currently, there are no effective screening strategies for ovarian cancer (2, 3); therefore, prevention for this population focuses on prophylactic removal of the fallopian tubes and ovaries. Risk-reducing salpingo-oophorectomy (RRSO) reduces the risk of ovarian, fallopian tube, and peritoneal cancer by 85% to 90% for *BRCA1/2* mutation carriers (4–6). Recent reports have shown that occult cancers in the fallopian tubes and ovary are diagnosed in approximately 3% to 10% of RRSO surgical specimens (5, 7–15). Given this risk, consensus groups have recom-

mended that a complete pathology review, including serial sectioning of the ovaries and fallopian tubes, is necessary for identification of occult cancers (16).

Studying occult microscopic cancers can provide insight into the natural history of *BRCA*-associated ovarian cancers. Significant debate is ongoing related to the tissue site of origin (ovarian, fallopian tube, or peritoneal surfaces) and also the cell type of origin (ovarian surface epithelial cells, ciliated cells in the fallopian tube, or tubal secretory cells). Furthermore, it is not clear how the ovarian, tubal, or peritoneal microenvironments may differentially impact tumor initiation or progression.

This study reports our single-institution experience with microscopic and early-stage cancers diagnosed in *BRCA1* and *BRCA2* mutation carriers. Observations from these cases are combined with a review of the literature to build an updated model of the early steps of *BRCA*-associated ovarian and fallopian tube carcinogenesis. By generating a data-driven model of ovarian/fallopian tube carcinogenesis, we can begin to address the many remaining questions that hinder the field of ovarian cancer prevention research.

## Materials and Methods

### Case selection and review

From August 2000 to July 2010, 136 patients with known *BRCA* mutations underwent RRSO at The University

**Authors' Affiliations:** Departments of <sup>1</sup>Gynecologic Oncology and <sup>2</sup>Pathology, The University of Texas MD Anderson Cancer Center, Houston, Texas

**Note:** Supplementary data for this article are available at Cancer Prevention Research Online (<http://cancerprevres.aacrjournals.org/>).

**Corresponding Author:** Department of Gynecologic Oncology, The University of Texas MD Anderson Cancer Center, Unit 1362, PO Box 301439, Houston, TX 77230. Phone: 713-563-4579; Fax: 713-792-7586. E-mail: khlu@mdanderson.org

doi: 10.1158/1940-6207.CAPR-10-0266

©2011 American Association for Cancer Research.

of Texas MD Anderson Cancer Center. All tissues underwent the recommended complete pathology review, which included full serial sectioning of fallopian tubes and ovaries. Microscopic cancers were undetected prior to RRSO and were surgically occult, diagnosed only at subsequent pathology review. Cases were reviewed by a gynecologic pathologist (M.T.D.) to verify histologic diagnosis.

We have chosen to adopt terminology that is different from that which is frequently used to define microscopic cancers of the fallopian tube. Recent studies that include extensive sampling of the fallopian tube for histologic analysis have identified small lesions confined to the tubal mucosa, often labeled serous tubal intraepithelial carcinoma (STIC) or carcinoma *in situ*. We have chosen to use descriptive definitions instead (e.g., high-grade serous carcinoma involving the fimbria, confined to the mucosa). By using a descriptive label that is entirely case-specific, we hope to avoid the connotations often associated with the labels *in situ* or STIC. In our experience, these labels are sometimes interpreted to indicate disease of minimal severity that does not require chemotherapy. As some fallopian tube lesions identified as carcinoma *in situ* have been shown to recur (17), it is essential that we do not inadvertently diminish the significance of disease.

Early-stage ovarian or fallopian tube cancer cases (stages I and II) were identified by reviewing records from patients with known germline *BRCA1* or *BRCA2* mutations who sought genetic counseling, treatment, or an opinion at MD Anderson from January 1999 to March 2010. This group includes patients with early-stage cancers who were initially diagnosed at outside institutions. These early-stage cancers

were not surgically occult. This study was approved by the MD Anderson Institutional Review Board.

### Literature review

Literature search included the following terms: *BRCA1*, *BRCA2*, prophylactic, ovarian, fallopian tube, cancer, occult, and unexpected. For inclusion in our analysis, literature reports were required to meet the following criteria: microscopic cancers occurred in known *BRCA1/2* mutation carriers (germline testing required) without suspicion of cancer prior to surgery (risk-reducing salpingo-oophorectomy), cancers were surgically occult, and diagnosed only upon further pathology review. In addition, a description of the fallopian tube review methodology was required for inclusion. Individual case reports were not included in our analysis.

### Results

As of July 2010, 136 patients with known *BRCA* mutations have undergone RRSO at MD Anderson (76 women with *BRCA1* mutations and 60 women with *BRCA2* mutations). Age at RRSO ranged from 28 to 73 years for *BRCA1* mutation carriers (mean age = 47 years) and 30 to 67 years for *BRCA2* mutation carriers (mean age = 48 years).

Six of 76 patients with *BRCA1* mutations (7.9%) and 0 of 60 patients with *BRCA2* mutations had a diagnosis of microscopic cancers at the time of RRSO at MD Anderson (Table 1). These 6 microscopic cancers were all high-grade serous carcinoma (HGSCa). Of the 6 HGSCas, 4 cases involved the fallopian tubes only, and 1 case (case 2) was confined to the ovary (Fig. 1). The other case (case 1)

**Table 1.** Microscopic cancers identified at the time of RRSO for *BRCA* mutation carriers

Case no.	Age at RRSO, y	<i>BRCA1/2</i> mutation	Primary site	Histology	Washings
1	51	<i>BRCA1</i>	Primary peritoneal (washings only)	Washings–HGSCa. No carcinoma identified in ovaries or fallopian tubes	HGSCa
2	53	<i>BRCA1</i>	Ovary	HGSCa near the surface of the ovary (1 mm)	NE
3	60	<i>BRCA1</i>	Fallopian tube	2 foci of HGSCa involving the fimbria of RFT, confined to mucosa (1.7 and 0.4 mm)	Negative
4	52	<i>BRCA1</i>	Fallopian tube	2 foci of HGSCa confined to mucosa in RFT, first focus is in tube proper (1 mm), second focus in fimbria (0.4 mm)	Negative
5	70	<i>BRCA1</i>	Fallopian tube	HGSCa involving the fimbria, confined to mucosa (2 × 3 mm)	Negative
6	55	<i>BRCA1</i>	Fallopian tube	HGSCa involving fimbria comprising mucosa and submucosa (2 mm)	Negative

Abbreviations: NE, not evaluated; RFT, right fallopian tube.

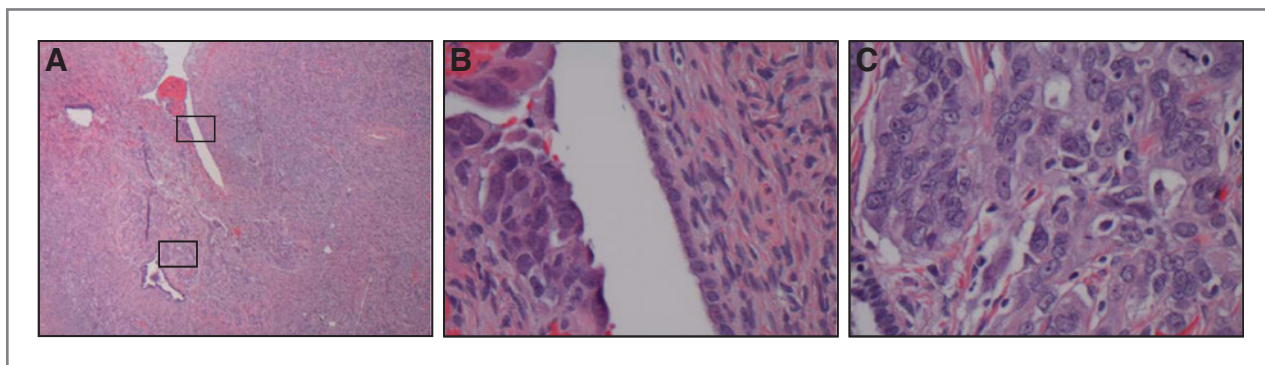


Figure 1. A, microscopic high-grade serous carcinoma near the surface of the ovary (case 2); boxes indicate area shown at higher magnification in B and C.

involved HGSCa in only the peritoneal washings and no carcinoma was identified in the tubes or ovaries. Three of the 4 fallopian tube cancer cases were confined to the mucosa, and 1 case involved the mucosa and submucosa. All patients with a diagnosis of microscopic cancer at the time of RRSO were without symptoms and CA-125 (serum cancer antigen 125) levels were within normal limits. In addition, 2 *BRCA1* mutation carriers were diagnosed with ovarian serous tumors of low malignant potential at the time of RRSO at MD Anderson (not shown).

We have performed a comprehensive review of reports of microscopic cancer cases in *BRCA1/2* mutation carriers at the time of RRSO to determine whether our observation holds true in a larger sample set (9–15, 18–22). In total, 38 cases of microscopic cancer were reported in the literature (Table 2). Of these, 23 cases (60.5%) were confined to the fallopian tube only. In addition, 8 cases (21.1%) involved the ovary only. An additional 6 cases (15.8%) involved both the fallopian tube and the ovaries. One case (2.6%) of primary peritoneal cancer was also identified. Although a thorough description is not present for all cases, reported ovarian tumors include those confined to the surface of the ovary and an intracystic tumor. (Supplementary Table S1). Furthermore, 7 cases were diagnosed with bilateral disease.

To expand our study to include the process of tumor progression, we have also reviewed all cases of early stage ovarian and fallopian tube cancers in *BRCA1/2* mutation carriers. MD Anderson has identified 131 ovarian and fallopian tube cancer cases in *BRCA1/2* mutation carriers (84 *BRCA1*, 46 *BRCA2*, and 1 patient with both *BRCA1* and *BRCA2* mutations). From these cases, 14 cases of early-stage ovarian and fallopian tube cancers were identified (Table 3). We define early stage to include stages IA to IIC.

Early-stage cancers were identified in 8 *BRCA1* mutation carriers (5 stage I and 3 stage II). Many of these cases were high-grade serous carcinoma, though undifferentiated and poorly differentiated cases were also observed. Of these 8 early-stage *BRCA1* cases, 5 cases had dominant ovarian masses and 3 cases had dominant masses in the fallopian tube. Two early-stage cases with *BRCA1* mutations were diagnosed with bilateral ovarian disease.

Five early-stage ovarian cancers were identified in *BRCA2* mutation carriers (1 stage I and 4 stage II). These cases were predominantly serous. Three of these 5 patients had a diagnosis of bilateral ovarian disease. There were no women with a diagnosis of fallopian tube primaries. In addition, 1 case (case 20) of early-stage ovarian cancer was diagnosed in a patient with germline mutations in both *BRCA1* and *BRCA2*. This woman had a diagnosis of a stage IIB high-grade serous ovarian carcinoma.

Overall, 11 of 14 stage I and II cancers in *BRCA1/2* mutation carriers occurred with a dominant ovarian mass. The other 3 cases were fallopian tube primaries. This is in contrast to the majority of our microscopic cancers which occurred more frequently in the fallopian tubes.

## Discussion

The data reported here provide a view of the early natural history of ovarian and fallopian tube cancers in women with *BRCA1/2* mutations, including differences between *BRCA1* and *BRCA2* mutation carriers. Although 76 women with *BRCA1* mutations and 60 women with *BRCA2* mutations underwent RRSO at MD Anderson, 6 cases of microscopic cancer were diagnosed in *BRCA1* patients but no microscopic cancer cases were observed in *BRCA2* patients. This is consistent with previous estimates of higher risk of ovarian cancer and earlier age of onset of ovarian cancer in *BRCA1* mutation carriers than in *BRCA2* mutation carriers (1, 23). Furthermore, while microscopic cancers were identified primarily in the fallopian tubes, they also occurred in the ovaries and peritoneal washings of *BRCA1/2* mutation carriers. A review of microscopic cancers reported in the literature confirms our observation in *BRCA1/2* mutation carriers and adds a case of an intracystic ovarian tumor. Our data also suggest that while many ovarian cancers actually originate from the fallopian tube, the ovary may be the preferred site for tumors to progress beyond the microscopic stage in *BRCA1/2* mutation carriers.

With the data described here, we propose an updated model of the early stages of BRCA-associated ovarian cancer (Fig. 2), which expands the number of potential sites for

**Table 2.** Literature review of microscopic ovarian, fallopian tube, and peritoneal tumors in *BRCA1/2* mutation carriers

ID	<i>BRCA1/2</i> mutation	Primary site	Washings	Reference
L1	<i>BRCA1</i>	Fallopian tube	Positive	18
L2	<i>BRCA1</i>	Fallopian tube	Negative	19
L3	<i>BRCA1</i>	Fallopian tube	Negative	19
L4	<i>BRCA1</i>	Fallopian tube	Negative	19
L5	<i>BRCA1</i>	Fallopian tube	Negative	9
L6	<i>BRCA1</i>	Fallopian tube	Negative	9
L7	<i>BRCA1</i>	Fallopian tube	Negative	9
L8	<i>BRCA1</i>	Fallopian tube	Negative	9
L9	<i>BRCA1</i>	Fallopian tube	Negative	10, 20
L10	<i>BRCA1</i>	Fallopian tube	Negative	11
L11	<i>BRCA1</i>	Fallopian tube	Negative	11
L12	<i>BRCA1</i>	Fallopian tube	Negative	21
L13	<i>BRCA1</i>	Fallopian tube	Negative	21
L14	<i>BRCA1</i>	Fallopian tube	Positive	12, 21
L15	<i>BRCA1</i>	Fallopian tube	Positive	12, 21
L16	<i>BRCA1</i>	Fallopian tube	NR	14
L17	<i>BRCA1</i>	Fallopian tube	NR	14
L18	<i>BRCA1</i>	Fallopian tube	Positive	15
L19	<i>BRCA2</i>	Fallopian tube	Positive	19
L20	<i>BRCA2</i>	Fallopian tube	Negative	19
L21	<i>BRCA2</i>	Fallopian tube	Negative	12, 21
L22	<i>BRCA2</i>	Fallopian tube	Negative	15
L23	<i>BRCA2</i>	Fallopian tube	Negative	15
L24	<i>BRCA1</i>	Ovary	Positive	10, 20
L25	<i>BRCA1</i>	Ovary	NR	13
L26	<i>BRCA1</i>	Ovary	NR	14
L27	<i>BRCA1</i>	Ovary	NR	14
L28	<i>BRCA1</i>	Ovary	Negative	15
L29	<i>BRCA2</i>	Ovary	NR	13
L30	<i>BRCA1</i>	Both ovaries	Negative	9
L31	<i>BRCA1</i>	Both ovaries	Negative	11
L32	<i>BRCA1</i>	Both ovaries, 1 fallopian tube	Negative	10
L33	<i>BRCA1</i>	Both ovaries, 1 fallopian tube	Positive	10, 20
L34	<i>BRCA1</i>	Both ovaries, 1 fallopian tube	NR	13
L35	<i>BRCA1</i>	Ovary and fallopian tube	Negative	19
L36	<i>BRCA1</i>	Ovary and both fallopian tubes	NR	14
L37	<i>BRCA2</i>	Both ovaries and 1 fallopian tube	Negative	11
L38	<i>BRCA2</i>	Primary peritoneal	Negative	10

Abbreviation: NR, not reported.

ovarian cancer initiation. The fallopian tube epithelium, ovarian surface epithelium, ovarian cystic structures, and peritoneum may give rise to the early steps of carcinogenesis. Our single-institution experience and cases reported in the literature show that most "ovarian" cancers begin in the distal fallopian tube and fimbria. Some of these microscopic fallopian tube cancers progress and grow larger but remain confined to the tube, creating a primary tubal cancer (Fig. 2A). However, because of the close association between the fimbria and ovarian surface, fallopian tube

tumor cells could also spread to the ovary. This tumor may appear confined to the ovarian surface (Fig. 2B), or due to the cyclic rupture, repair, and invaginations that occurs with ovulation, the tumor may be incorporated into the ovarian stroma, where it grows and expands (Fig. 2C). Alternatively, early carcinogenic changes may occur in the ovary (either on the surface or within cystic structures) where it quickly grows (Fig. 2D). In many cases, the ovary seems to provide a particularly rich environment to support tumor growth and most tumor mass is associated with the

Downloaded from <http://aacrjournals.org/cancerpreventiononresearch/article-pdf/14/3/463/2337727/463.pdf> by guest on 22 July 2024

**Table 3.** Early-stage ovarian or fallopian tube cancers identified in *BRCA* mutation carriers

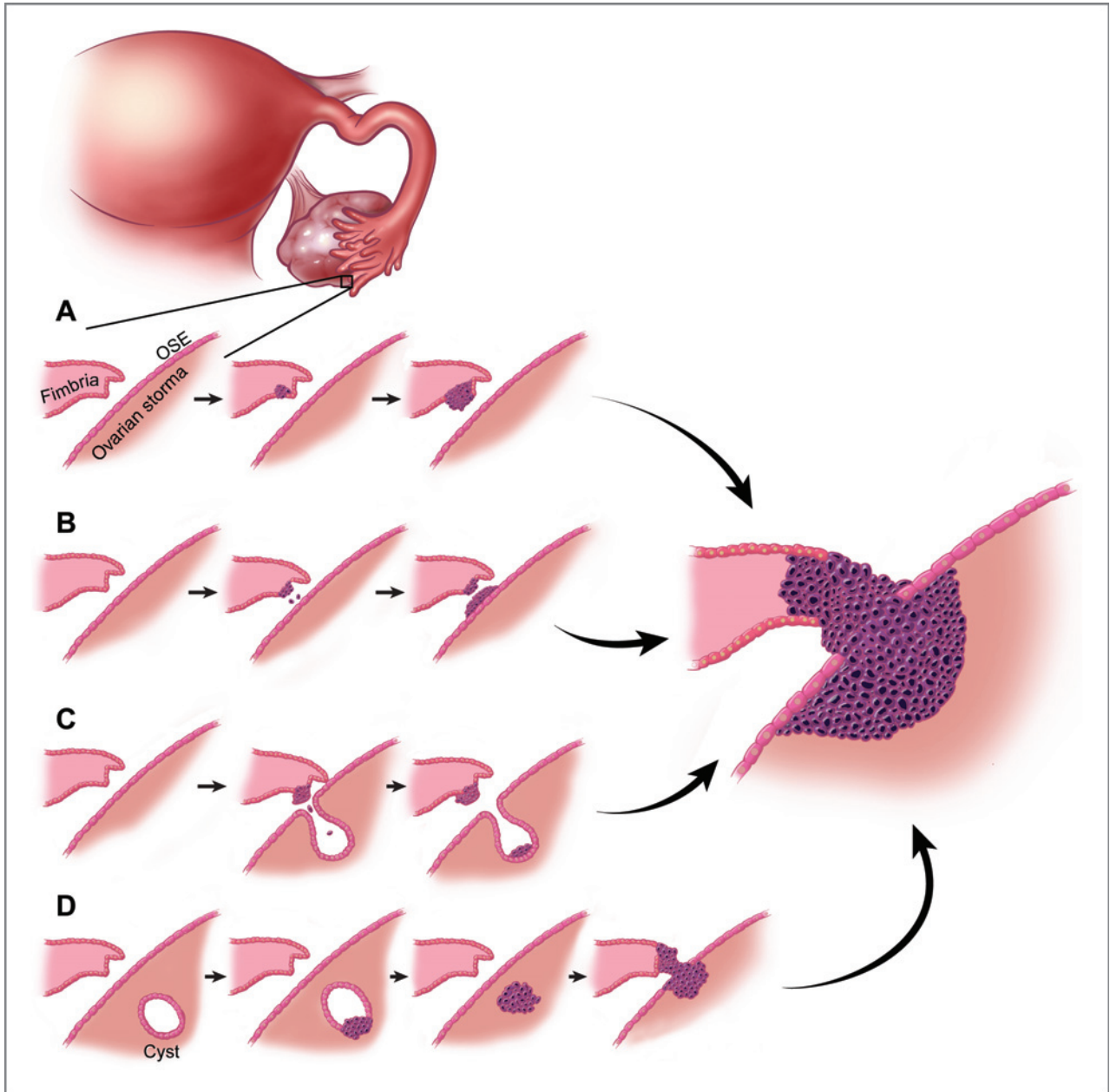
Case no.	Age at diagnosis, y	<i>BRCA1/2</i> mutation	Grade	Dominant mass	Histology	Bilateral or unilateral?	Primary size	Stage
7	32	<i>BRCA1</i>	High	Ovary	Serous carcinoma	Bilateral	12 × 6 × 6 cm	IB
8	43	<i>BRCA1</i>	High	Ovary	Serous carcinoma	Unknown	Unknown	IIA
9	56	<i>BRCA1</i>	High	Ovary	Serous carcinoma	Bilateral	11 cm	IC
10	55	<i>BRCA1</i>	High	Ovary	Serous carcinoma	Unilateral	8 cm	IIC
11	54	<i>BRCA1</i>	High	Ovary	Undifferentiated carcinoma	Unilateral	Unknown	IA
12	50	<i>BRCA1</i>	High	Fallopian tube	Poorly differentiated carcinoma	Unilateral	2 cm	IA
13	40	<i>BRCA1</i>	High	Fallopian tube	Serous carcinoma	Unilateral	8 × 5 × 3 cm	II
14	50	<i>BRCA1</i>	High	Fallopian tube	Serous carcinoma	Unilateral	2 × 1 × 1 cm	IA
15	54	<i>BRCA2</i>	High	Ovary	Poorly differentiated carcinoma	Unilateral	7 × 7 × 5 cm	IIB
16	59	<i>BRCA2</i>	High	Ovary	Serous carcinoma	Bilateral	7 cm	IIC
17	55	<i>BRCA2</i>	High	Ovary	Serous carcinoma	Bilateral	14 × 7 × 6 cm	IB
18	50	<i>BRCA2</i>	High	Ovary	Serous carcinoma	Bilateral	7 × 5 × 3 cm	IIA
19	61	<i>BRCA2</i>	High	Ovary	Serous carcinoma	Unilateral	15 cm	IIA
20	41	<i>BRCA1</i> and <i>BRCA2</i>	High	Ovary	Serous carcinoma involving left ovary and detached fragments in RFT lumen	Unilateral	6 cm	IIB

Abbreviation: RFT, right fallopian tube.

ovary. As the tumor grows larger, involving both the fallopian tube and the ovaries, it becomes difficult to identify whether the site of origin was ovaries or the fallopian tube. The observation of carcinoma in isolated peritoneal washings suggests that, less commonly, tumorigenesis might also begin in the peritoneum (not shown). However, additional cases with isolated positive peritoneal washings or cases of early peritoneal disease alone would be required to better address this issue. Furthermore, this study does not have sufficient cases to comment on other possible sequences of initiation or progression involving the peritoneum.

The dominant size of ovarian masses observed in stage I and stage II ovarian/fallopian tube cancers in *BRCA1/2* mutation carriers indicates that the ovary may be the preferred site for tumor growth. While early-stage cancers are rarely reported, our observation is also confirmed in a screening study by Lewin and colleagues (24). Three early-stage cancers were identified in *BRCA1* mutation carriers (1 case at stage IA and 2 cases at stage IC). All 3 of these cancers were ovarian primaries. These observations imply that the ovarian microenvironment provides a permissive environment for tumor progression, regardless of the site of tumor initiation. We can hypothesize factors that may play a role (inflammation, hormonal changes, etc.), but detailed molecular studies will be required to better understand the contributions of the ovarian microenvironment during these early steps in tumorigenesis.

This updated model of ovarian cancer initiation and progression has implications for current clinical management strategies for *BRCA* mutation carriers. In recent years, a great deal of momentum has gathered behind the idea that the fallopian tube is the singular site of origin for ovarian cancer. However, our data indicate that caution should be exercised in allowing this hypothesis to impact clinical management. For example, because of the emphasis on the fallopian tube as the primary site of initiation, there has been discussion about the possibility of risk-reducing surgery to remove the fallopian tubes only. By leaving the ovaries, patients would avoid estrogen deprivation symptoms and perhaps be more likely to undergo surgery at a younger age. However, on the basis of this updated model of *BRCA*-associated ovarian carcinogenesis, salpingectomy may not be an effective preventive strategy. Initiated cells may have spread to the ovary at a very early point, resulting in a risk of carcinogenesis even if the tubes were removed. In addition, some *BRCA*-associated cancers may initiate in the ovaries or peritoneum and this cancer risk would be unaffected by salpingectomy alone. In both of these scenarios, the patient might have a false sense of protection against ovarian cancer. We propose that future, large-scale collaborative studies should evaluate the relationship between age at diagnosis of microscopic cancers and early-stage invasive cancers to determine whether there might be an age at which salpingectomy alone could be used as a temporizing risk-reducing strategy.



**Figure 2.** Possible pathways of BRCA-associated ovarian/fallopian tube cancer initiation and progression. A, some tumors begin in the fallopian tube and continue to grow larger, while remaining confined to the tube, creating a primary tubal cancer. However, because of the close association between the fimbria and ovarian surface, fallopian tube tumor cells could also spread to the ovary (B and C). B, cancer initiation occurs in the fallopian tube fimbria and a small number of cancer cells are deposited on to the ovarian surface, which provides a supportive environment for tumor growth. C, because of the cyclic rupture, repair, and invaginations that occurs with ovulation, cancer cells from the fimbria can be transferred into the ovarian stroma where it grows and expands. D, alternatively, early carcinogenic changes may occur within ovarian cysts where the tumor grows, again producing a dominant ovarian mass. As the tumor grows larger, involving both the fallopian tube and the ovaries, it becomes difficult to identify whether the site of origin was ovary or fallopian tube. OSE, ovarian surface epithelium.

Several fundamental issues regarding ovarian cancer initiation and progression remain to be addressed. Future studies must address preneoplastic lesions that could be part of the continuum of BRCA-associated ovarian/fallopian tube carcinogenesis. For example, Crum and colleagues have proposed the "p53 signature" as an early lesion

in the fallopian tube that precedes microscopic tumor development. The "p53 signature" is defined as 12 or more consecutive cells with strongly positive p53 nuclear staining within benign-appearing epithelium (25, 26). Further analysis of p53 signatures and continued efforts to identify additional precancerous lesions will be advanced through

studying microscopic ovarian/fallopian tube cancers identified in BRCA mutation carriers. Studies are also necessary to evaluate the molecular implications of an updated model of ovarian cancer initiation and progression. For example, are the same early molecular events responsible for carcinogenesis in cancers that initiate in the ovary, fallopian tube, or peritoneum? Furthermore, are there common microenvironment contributions to carcinogenesis at these different sites? Bilateral microscopic cancers were diagnosed in several cases described here. This raises the question of whether metastasis occurs early in tumor development or whether this is an indication of multifocal initiation. Future studies must also determine whether all ovarian cancers proceed through a linear progression from early-stage to late-stage disease or perhaps some microscopic tubal carcinomas might bypass early-stage ovarian disease and progress directly to advanced stage disease. Addressing these basic issues in BRCA-associated ovarian tumorigenesis will be essential to creating improved *in vitro* and *in vivo* models to support development of prevention strategies for these high-risk patients.

It is important to note that this model is specific to BRCA-associated ovarian carcinogenesis; the relevance to sporadic ovarian cancer is unknown. Developing this type of model for sporadic ovarian cancer is problematic because microscopic cancers are rarely diagnosed in average-risk women and the intensive pathology review applied to BRCA1/2 mutation carriers is rarely performed in average-risk women. Because of the rarity of these cancers, large-scale collaborative studies will be invaluable to successfully creating a model of early events in sporadic ovarian cancer. While late-stage ovarian tumor tissues

are readily available, it is difficult to extrapolate late-stage molecular findings to understand early molecular events.

In conclusion, our data suggest that the fallopian tube, ovary, and peritoneal surfaces may give rise to cancer initiation. Interestingly, most BRCA-associated early-stage cancers have a dominant ovarian mass, suggesting that the ovarian microenvironment should be further explored to better understand factors that support tumor progression. This updated model is important for an improved understanding of early events in BRCA-associated ovarian and fallopian tube carcinogenesis and may aid in identifying improved prevention strategies for women with BRCA1/2 mutations who delay or decline RRSO. By highlighting the many gaps in our basic knowledge of ovarian cancer, this study also emphasizes the need for a broad cooperative effort to continue to refine this data-driven model of early events in BRCA-associated ovarian carcinogenesis.

### Disclosure of Potential Conflicts of Interest

No conflict of interest was disclosed.

### Grant Support

This research was supported, in part, by a cancer prevention fellowship for M.S. Yates (National Cancer Institute grant R25T CA57730, Shine Chang, PhD, Principal Investigator). This research was also supported by the NIH through MD Anderson's Cancer Center Support Grant CA016672.

The costs of publication of this article were defrayed in part by the payment of page charges. This article must therefore be hereby marked *advertisement* in accordance with 18 U.S.C. Section 1734 solely to indicate this fact.

Received October 1, 2010; revised January 7, 2011; accepted January 11, 2011; published OnlineFirst January 28, 2011.

### References

- Chen S, Iversen ES, Friebel T, Finkelstein D, Weber BL, Eisen A, et al. Characterization of BRCA1 and BRCA2 mutations in a large United States sample. *J Clin Oncol* 2006;24:863-71.
- Van Der Velde NM, Mourits MJ, Arts HJ, de Vries J, Leegte BK, Dijkhuis G, et al. Time to stop ovarian cancer screening in BRCA1/2 mutation carriers? *Int J Cancer* 2009;124:919-23.
- Woodward ER, Sleightholme HV, Considine AM, Williamson S, McHugo JM, Cruger DG. Annual surveillance by CA125 and transvaginal ultrasound for ovarian cancer in both high-risk and population risk women is ineffective. *BJOG* 2007;114:1500-9.
- Finch A, Beiner M, Lubinski J, Lynch HT, Moller P, Rosen B, et al. Salpingo-oophorectomy and the risk of ovarian, fallopian tube, and peritoneal cancers in women with a BRCA1 or BRCA2 Mutation. *JAMA* 2006;296:185-92.
- Kauff ND, Satagopan JM, Robson ME, Scheuer L, Hensley M, Hudis CA, et al. Risk-reducing salpingo-oophorectomy in women with a BRCA1 or BRCA2 mutation. *N Engl J Med* 2002;346:1609-15.
- Rebbeck TR, Lynch HT, Neuhausen SL, Narod SA, Van't Veer L, Garber JE, et al. Prophylactic oophorectomy in carriers of BRCA1 or BRCA2 mutations. *N Engl J Med* 2002;346:1616-22.
- Domchek SM, Friebel TM, Garber JE, Isaacs C, Matloff E, Eeles R, et al. Occult ovarian cancers identified at risk-reducing salpingo-oophorectomy in a prospective cohort of BRCA1/2 mutation carriers. *Breast Cancer Res Treat* 2010;124:195-203.
- Hirst JE, Gard GB, McIlroy K, Nevell D, Field M. High rates of occult fallopian tube cancer diagnosed at prophylactic bilateral salpingo-oophorectomy. *Int J Gynecol Cancer* 2009;19:826-9.
- Carcangiu ML, Peissel B, Pasini B, Spatti G, Radice P, Manoukian S. Incidental carcinomas in prophylactic specimens in BRCA1 and BRCA2 germ-line mutation carriers, with emphasis on fallopian tube lesions: report of 6 cases and review of the literature. *Am J Surg Pathol* 2006;30:1222-30.
- Finch A, Shaw P, Rosen B, Murphy J, Narod SA, Colgan TJ. Clinical and pathologic findings of prophylactic salpingo-oophorectomies in 159 BRCA1 and BRCA2 carriers. *Gynecol Oncol* 2006;100:58-64.
- Laki F, Kirova YM, This P, Plancher C, Asselain B, Sastre X, et al. Prophylactic salpingo-oophorectomy in a series of 89 women carrying a BRCA1 or a BRCA2 mutation. *Cancer* 2007;109:1784-90.
- Leeper K, Garcia R, Swisher E, Goff B, Greer B, Paley P. Pathologic findings in prophylactic oophorectomy specimens in high-risk women. *Gynecol Oncol* 2002;87:52-6.
- Lu KH, Garber JE, Cramer DW, Welch WR, Niloff J, Schrag D, et al. Occult ovarian tumors in women with BRCA1 or BRCA2 mutations undergoing prophylactic oophorectomy. *J Clin Oncol* 2000;18:2728-32.
- Olivier RI, van Beurden M, Lubsen MA, Rookus MA, Mooij TM, van de Vijver MJ, et al. Clinical outcome of prophylactic oophorectomy in BRCA1/BRCA2 mutation carriers and events during follow-up. *Br J Cancer* 2004;90:1492-7.
- Powell CB, Kenley E, Chen LM, Crawford B, McLennan J, Zaloudek C, et al. Risk-reducing salpingo-oophorectomy in BRCA mutation carriers: role of serial sectioning in the detection of occult malignancy. *J Clin Oncol* 2005;23:127-32.
- ACOG. ACOG Practice Bulletin No. 103: hereditary breast and ovarian cancer syndrome. *Obstet Gynecol* 2009;113:957-66.

17. Agoff SN, Garcia RL, Goff B, Swisher E. Follow-up of *in situ* and early-stage fallopian tube carcinoma in patients undergoing prophylactic surgery for proven or suspected BRCA-1 or BRCA-2 mutations. *Am J Surg Pathol* 2004;28:1112-4.
18. Agoff SN, Mendelin JE, Grieco VS, Garcia RL. Unexpected gynecologic neoplasms in patients with proven or suspected BRCA-1 or -2 mutations: implications for gross examination, cytology, and clinical follow-up. *Am J Surg Pathol* 2002;26:171-8.
19. Callahan MJ, Crum CP, Medeiros F, Kindelberger DW, Elvin JA, Garber JE, et al. Primary fallopian tube malignancies in BRCA-positive women undergoing surgery for ovarian cancer risk reduction. *J Clin Oncol* 2007;25:3985-90.
20. Colgan TJ, Murphy J, Cole DE, Narod S, Rosen B. Occult carcinoma in prophylactic oophorectomy specimens: prevalence and association with BRCA germline mutation status. *Am J Surg Pathol* 2001;25:1283-9.
21. Lamb JD, Garcia RL, Goff BA, Paley PJ, Swisher EM. Predictors of occult neoplasia in women undergoing risk-reducing salpingo-oophorectomy. *Am J Obstet Gynecol* 2006;194:1702-9.
22. Medeiros F, Muto MG, Lee Y, Elvin JA, Callahan MJ, Feltmate C, et al. The tubal fimbria is a preferred site for early adenocarcinoma in women with familial ovarian cancer syndrome. *Am J Surg Pathol* 2006;30:230-6.
23. Iversen ES, Chen S. Population-calibrated gene characterization: estimating age at onset distributions associated with cancer genes. *J Am Stat Assoc* 2005;100:399-409.
24. Lewin SN, Kemel Y, Kosarin J, Hansen J, Robson ME, Offit K, et al. Utility of ovarian cancer screening in women with BRCA mutations. *J Clin Oncol* 2008;26Suppl:abstr 5531.
25. Jarboe EA, Pizer ES, Miron A, Monte N, Mutter GL, Crum CP. Evidence for a latent precursor (p53 signature) that may precede serous endometrial intraepithelial carcinoma. *Mod Pathol* 2009;22:345-50.
26. Saleemuddin A, Folkins AK, Garrett L, Garber J, Muto MG, Crum CP, et al. Risk factors for a serous cancer precursor ("p53 signature") in women with inherited BRCA mutations. *Gynecol Oncol* 2008;111:226-32.