

Expression of Receptors for Luteinizing Hormone-Releasing Hormone (LH-RH) in Prostate Cancers following Therapy with LH-RH Agonists

Stephen V. Liu¹, Andrew V. Schally⁴, Debra Hawes², Shigang Xiong¹, Laden Fazli⁵, Martin Gleave⁵, Jie Cai³, Susan Groshen³, Frank Brands², Juergen Engel⁶, and Jacek Pinski¹

Abstract

Purpose: In addition to their expression on pituitary cells, receptors for luteinizing hormone-releasing hormone (LH-RH) are found on most prostate cancer cells. These tumoral LH-RH receptors mediate the direct cytotoxic effects of LH-RH analogs and are potential therapeutic targets. Although pituitary LH-RH receptors are downregulated following prolonged exposure to LH-RH agonists, there is no evidence that tumoral receptors behave in a similar manner. To better characterize expression of tumoral LH-RH receptors, specimens of prostate cancer from various cohorts of patients were analyzed.

Experimental Design: Surgical specimens were obtained from untreated patients with prostate cancer and from patients with metastatic castration-resistant prostate cancer previously treated with bilateral orchiectomy. To address the possibility of receptor downregulation, two additional cohorts of patients who had been previously treated with LH-RH agonists were included. One group received neoadjuvant therapy prior to prostatectomy, and the other group was treated for metastatic disease with LH-RH agonists and, at progression, required palliative resection of the prostate. Lymph node metastases from previously untreated patients were subjected to similar analysis.

Results: Expression of LH-RH receptors was found in most specimens. The relative expression of LH-RH receptor mRNA in untreated patients was greater in patients whose tumor had received a Gleason score <8.

Conclusions: LH-RH receptor expression persisted despite prolonged exposure to LH-RH agonists. These findings support the concept of targeting cytotoxic LH-RH analogs to prostatic LH-RH receptors, using these receptors to gain entry into cancer cells to deliver a hybridized cytotoxic moiety for the treatment of prostate cancer. *Clin Cancer Res*; 16(18); 4675–80. ©2010 AACR.

Prostate cancer is the most common malignancy in men aside from skin cancer and is the second leading cause of cancer-related death (1); thus, prostate cancer creates a substantial public health burden. For patients with advanced prostate cancer, the cornerstone of therapy is androgen ablation through hormonal manipulation (2), either surgical, with bilateral orchiectomy, or medical, with the use of luteinizing hormone-releasing hormone (LH-RH) agonists. The two approaches are clinically equivalent,

and LH-RH agonists have become standard first-line agents in the treatment of advanced prostate cancer. LH-RH agonists mediate their effects through the downregulation of LH-RH receptors in the pituitary gland, leading to an inhibition of the pituitary-gonadal axis and a decrease in androgen synthesis (3). LH-RH receptors are also expressed directly on the plasma membranes of prostate cancer cells (4) where they have been shown to mediate direct inhibitory effects (5).

Androgen ablation therapy is effective, but its benefits are transient, lasting a median of 24 months. Once patients develop castration-resistant prostate cancer (CRPC), there are few therapeutic options. Chemotherapy has only recently been shown to improve survival of these patients (6, 7). There is a great need for additional treatment options. Given the advanced median age of patients with CRPC and the comorbidities that often exist in this population, agents that selectively target tumor cells are urgently required. The development of targeted therapy has stalled in the search for a viable therapeutic target. One such candidate is the LH-RH receptor, which is highly expressed on prostate cancer cells and only minimally

Authors' Affiliations: ¹Division of Cancer Medicine and Blood Diseases, Departments of ²Pathology and ³Preventative Medicine, Norris Comprehensive Cancer Center, University of Southern California, Los Angeles, California; ⁴Department of Pathology and Medicine, Division of Hematology/Oncology, Sylvester Comprehensive Cancer Center, Veterans Affairs Medical Center, University of Miami, Miami, Florida; ⁵Department of Urologic Sciences, The Vancouver Prostate Centre, University of British Columbia, Vancouver, BC, Canada; and ⁶Aeterna Zentaris, Inc., Frankfurt, Germany

Corresponding Author: Jacek Pinski, USC Norris Comprehensive Cancer Center, 1441 Eastlake Avenue #3440, Los Angeles, CA 90033. Phone: 323-865-3900; Fax: 323-865-0061; E-mail: pinski_j@ccnt.usc.edu.

doi: 10.1158/1078-0432.CCR-10-1113

©2010 American Association for Cancer Research.

Translational Relevance

The expression of receptors for luteinizing hormone-releasing hormone (LH-RH) on prostate cancer cells is well described. The behavior of these receptors, particularly following prolonged exposure to LH-RH agonists, is unclear. Pituitary receptors are down-regulated in response to LH-RH agonist therapy. Our data show that tumoral LH-RH receptor expression persists despite extended LH-RH agonist treatment. These findings form the basis for the use of cytotoxic LH-RH analogs in advanced prostate cancer. These agents combine an LH-RH agonist with a cytotoxic moiety and exploit LH-RH receptor expression to deliver the cytotoxic agent. One such agent, AN-152, is being studied in women with gynecologic cancers. Our data show persistent LH-RH receptor expression in prostate cancer specimens and support the concept of using cytotoxic LH-RH analogs in the treatment of advanced prostate cancer.

found on normal tissues (8). Although reported expression profiles are encouraging, most existing studies dealt with previously untreated, castration-sensitive prostate cancer specimens. Based on the current treatment algorithms, patients in need of nonhormonal therapy will have already progressed to CRPC. LH-RH receptor expression in CRPC has also been documented but only following surgical castration and antiandrogen therapy (9). The effect of medical castration with LH-RH agonists on LH-RH receptor expression has not yet been defined. The use of LH-RH agonists results in the downregulation of pituitary LH-RH receptors, and a similar response by tumoral LH-RH receptors could abolish their utility as a therapeutic target in this setting. As a result, there is a need to characterize the expression of tumoral LH-RH receptors following prolonged exposure to LH-RH agonists. In addition, there are little data regarding expression of LH-RH receptors on metastases of prostate cancer. The biology of the metastatic cells can be quite distinct from that of the primary tumor, reflecting the changes required for metastatic potential. Persistent expression of LH-RH receptors on metastatic cells would further support their role as a therapeutic target.

The purpose of this study was to characterize LH-RH receptor expression in prostate cancer specimens, particularly following prolonged exposure to LH-RH agonists. We also describe LH-RH receptor expression in prostate cancer lymph node metastases. Receptor expression was characterized in prostate cancer specimens using immunohistochemistry. Surgical specimens were obtained from patients previously untreated and from patients surgically or medically castrated. These separate cohorts mimic several common clinical scenarios, and these studies will further clarify the expression profile of LH-RH receptors in prostate cancer patients. These findings will also assess the

potential of tumoral LH-RH receptors as novel targets for cytotoxic LH-RH analogs that can exploit these receptors to deliver hybridized cytotoxic moieties.

Materials and Methods

Prostate cancer specimens

Prostate cancer tissue was obtained from three cohorts of patients. The untreated cohort was composed of specimens from 47 hormone-naïve patients who underwent curative radical prostatectomy. The neoadjuvant cohort consisted of specimens from 61 patients treated on an institutional protocol with neoadjuvant LH-RH agonist therapy prior to curative radical prostatectomy. The duration of therapy varied, with 15 patients receiving <3 months of therapy, 23 patients receiving 3 to 6 months of therapy, and 23 patients receiving >6 months of therapy. The CRPC cohort consisted of 22 patients with metastatic CRPC who had undergone palliative resection of the prostate for obstructive symptoms. Of these patients, hormonal therapy was surgical castration in 15 patients and medical castration with an LH-RH agonist in 7 patients. In the patients who had undergone surgical castration, a median of 17 months and up to 79 months passed from time of surgical castration to the development of CRPC. In the patients who had undergone medical castration with a LH-RH agonist, a median of 11 months and up to 23 months of therapy had been administered prior to the development of CRPC. Lymph node metastases were obtained from 10 patients who had undergone radical prostatectomy with no prior treatment for their prostate cancer.

Immunohistochemistry

Expression of LH-RH receptors on archived prostate cancer specimens was determined using immunohistochemistry. Immunohistochemical staining was conducted using the Ventana autostainer model Discover XT (Ventana Medical Systems) with an enzyme-labeled biotin streptavidin system and solvent-resistant 3,3'-diaminobenzidine map kit. LH-RH receptor expression was analyzed using a commercially available primary antibody, mouse anti-human GnRHR (1:200; Genescript). All sections were reviewed by one of two pathologists who were blinded to clinical information, and the intensity of staining was graded from 0 to 3. The highest staining intensity among three cores was used to classify each tumor. The same scoring system was applied to all specimens. Tumor cells were identified based on morphology using conventional light microscopy.

Laser capture microdissection

Laser capture microdissection was done with laser scissors with a PixCell II System (ARCTURUS) according to the manufacturer's instructions. Briefly, laser capture microdissection parameters included a laser power of 80 mW, laser pulse duration of 5.0 ms, and laser spot size of 30 μm in diameter. The IR laser was pulsed over cells of interest on deparaffinized H&E sections (10 μm), and

approximately 3,000 epithelial cells were collected for each group.

Quantification of LH-RH receptor mRNA

LH-RH receptor mRNA levels were quantified from microdissected prostate cancer cells from patients who had not received systemic therapy. The quantitative measurement of target mRNA was done using a real-time PCR system (Applied Biosystems 7500) according to the manufacturer's instructions. PCR amplifications were carried out with the SYBR Green PCR core reagent (Applied Biosystems) in a total volume of 10 μ L, with 1 μ L of the reverse transcription products. RNA quantification of LH-RH receptor was assayed with the sense primer, 5'-gcaaatgcaagcaaaaga-3' and antisense, 5'-atcttctcctccctga-3'. Each gene under each condition was amplified in triplicate. Analysis was carried out using the Applied Biosystems' software program, and the relative expression level was standardized with the expression of 18S as a reference, 5'-ggagaggagcctgagaaac-3' (forward) and 5'-tcggagtggttaattgc-3' (reverse). Results were plotted as the mean \pm SD from three experiments.

Statistics

Results were reported as means \pm SD of at least three experiments. Student's *t*-test was used for statistical analysis, and the differences between two means with a *P* value <0.05 were considered significant.

Results

LH-RH receptor expression in prostate cancer specimens

LH-RH receptor expression was characterized by immunohistochemistry on tumor specimens from several cohorts of patients (Fig. 1). The specimens were obtained from 47 men with previously untreated prostate cancer who underwent prostatectomy. Using immunohistochemistry, LH-RH receptor expression was detected in 95.7% of tested samples, with moderate to strong intensity staining noted in 65.9% (Fig. 2A). Limited exposure to LH-RH agonist therapy had no significant effect on receptor expression, as noted in specimens from patients who received neoadjuvant LH-RH agonist therapy. These 61 samples were obtained from patients treated with LH-RH agonists prior to radical prostatectomy, and LH-RH receptor expression was noted in 98.4% of these samples, with moderate to strong intensity staining in 68.9% (Fig. 2B). In tissue specimens obtained from men with metastatic, CRPC, LH-RH receptor expression was consistently detected. Of the 15 men treated initially with surgical castration, all samples expressed the LH-RH receptor and 80% showed moderate to strong intensity (Fig. 2C). Similarly, in the 7 patients treated with LH-RH agonists long term (for a median of 11 months and up to 23 months), all samples showed LH-RH receptor expression and 85.7% had moderate to strong expression by immunohisto-

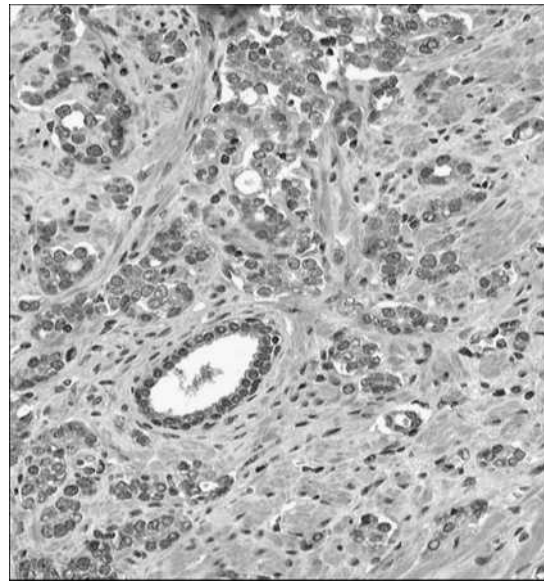


Fig. 1. Immunohistochemistry using monoclonal mouse antibodies targeting LH-RH receptor. LH-RH receptor is detected in the cytoplasm of prostate cancer cells with decreased immunoreactivity in the benign epithelium.

chemistry (Fig. 2D). There was no statistically significant difference between the various cohorts (*P* = 0.58).

LH-RH receptor mRNA expression correlates with Gleason score

LH-RH receptor mRNA was quantified using real-time PCR from microdissected prostate cancer cells from untreated patients. The relative expression of mRNA for the LH-RH receptor was greater in patients whose tumor had received a Gleason score ≤ 7 as compared with those >7 (Fig. 3). The low Gleason group had a median mRNA level of 12,052.3 compared with 6,570.7 (*P* = 0.0058) in the high Gleason group. Both sets were standardized with the expression of 18S.

LH-RH receptor expression in lymph node metastases of prostate cancer

Samples from men with previously untreated prostate cancer involving regional lymph nodes were subjected to LH-RH receptor analysis. Lymph nodes from 10 patients were obtained, and all 10 expressed LH-RH receptors with moderate to strong intensity (Fig. 4). When tissue from the primary tumor was available for comparison, LH-RH receptor expression in the lymph node metastases was as strong as or stronger than the expression in the primary tumor.

Discussion

The evolving paradigm of personalized medicine and targeted cancer therapy has had significant clinical impact

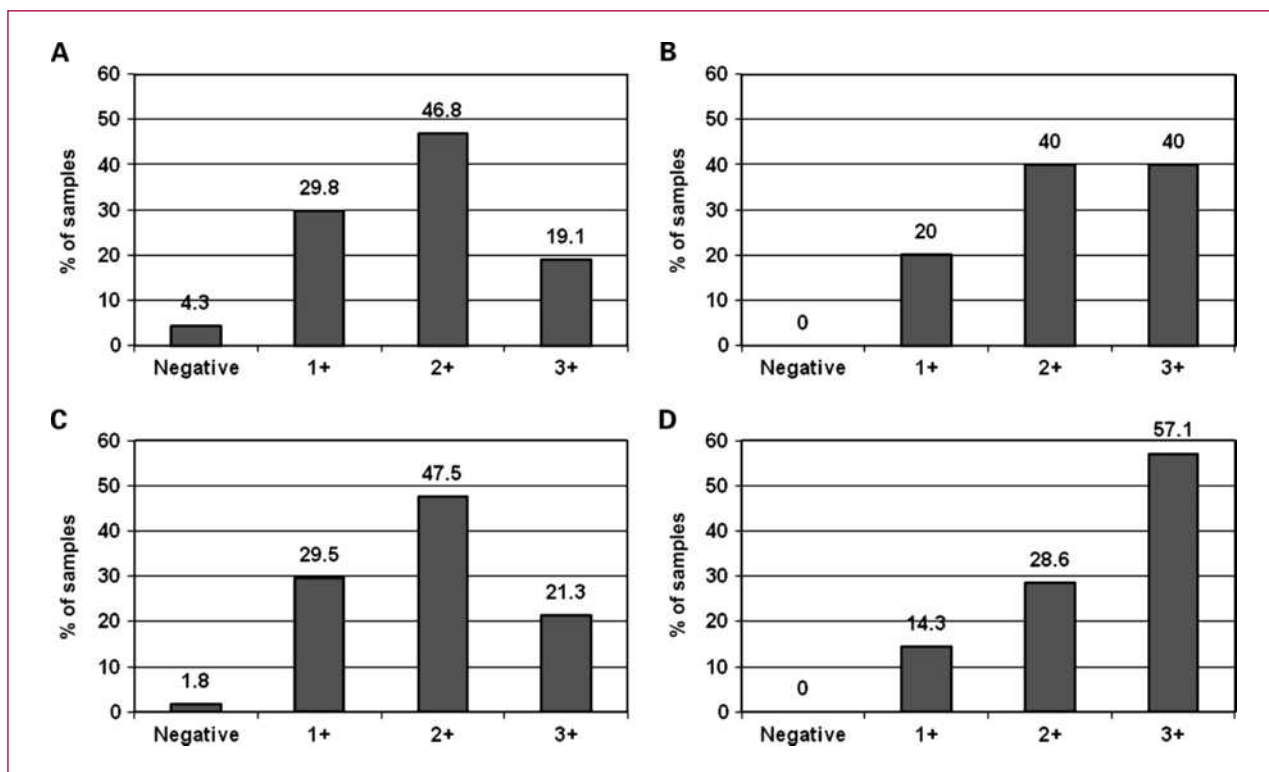


Fig. 2. LH-RH receptor expression as detected by immunohistochemistry in four separate patient cohorts. Y-axis, percentage of the cohort showing each level of expression on the X-axis: Negative, no staining; 1+, weak intensity staining; 2+, moderate intensity staining; 3+, strong intensity staining. In all cohorts, LH-RH receptor was expressed with high prevalence and the majority of samples showed moderate to strong intensity staining. A, specimens obtained from 47 patients with localized prostate cancer that had received no systemic therapy prior to surgical resection. B, specimens obtained from 61 patients with localized prostate cancer treated with neoadjuvant LH-RH agonist therapy prior to surgical resection. C, specimens obtained from 15 patients with metastatic CRPC treated with orchiectomy prior to palliative surgical resection. D, specimens obtained from 7 patients with metastatic CRPC treated with LH-RH agonist therapy prior to palliative surgical resection.

on medical oncology, although the treatment of prostate cancer has not derived much benefit from this strategy. This is a clear unmet need, given the prevalence of prostate cancer and the advanced age of most affected patients. Development of new therapeutic agents has been stalled by the lack of a viable therapeutic target on the plasma membrane of prostate cancer cells. A potential therapeutic target is the LH-RH receptor. Recent studies have shown that LH-RH receptors are expressed on a variety of human cancer cells, including ovarian (10), endometrial (11), pancreatic (12), rectal (13), renal (14), bladder (15), and breast cancer cells (16). Several groups have also shown LH-RH receptor expression with fairly high prevalence in prostate cancer cells. In treatment-naïve specimens, the presence of these receptors has been documented using reverse transcriptase-PCR (17), ligand binding assays (18), and immunohistochemistry (19). Their strong expression on prostate cancer cells relative to normal tissue makes the LH-RH receptor an attractive candidate for targeted therapy, but the expression profile of these receptors needs to be clearly defined, particularly in the castration-resistant phenotype following prolonged exposure to LH-RH agonists.

The current treatment algorithm for advanced prostate cancer relies heavily on LH-RH agonists, and it is well established that their use results in downregulation of pituitary LH-RH receptors. The effect of these agents on

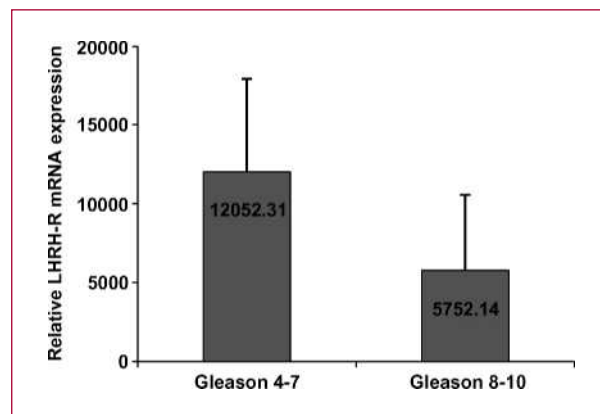


Fig. 3. LH-RH receptor (LHRH-R) mRNA evaluated with quantitative real-time PCR from tumors with Gleason ≤ 7 and from tumors with Gleason > 7 . Tumors with lower Gleason scores had higher LH-RH receptor mRNA levels than those with higher scores.

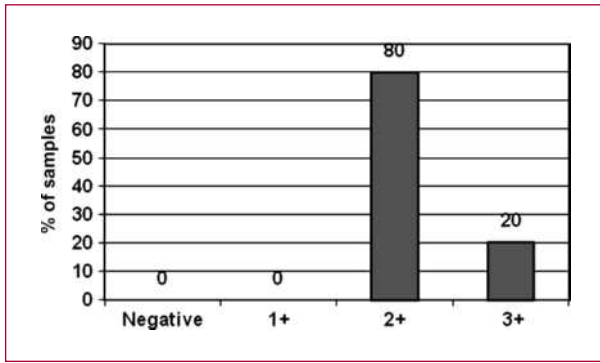


Fig. 4. LH-RH receptor expression as detected by immunohistochemistry in prostate cancer lymph node metastases. All lymph node samples showed moderate to strong intensity staining.

tumoral LH-RH receptors has not previously been described. Straub et al. analyzed LH-RH receptor expression in men with CRPC following surgical castration and anti-androgen therapy (9). LH-RH receptor mRNA was detected in 16 of the 18 samples (88.9%), suggesting persistent LH-RH receptor expression in CRPC. This does not, however, address the question of receptor downregulation, as shown for the pituitary LH-RH receptors. For the proper clinical advancement, tumoral LH-RH receptor expression following prolonged LH-RH agonist therapy must be characterized. One challenge is to obtain appropriate tissue for analysis, as biopsy and resection are not typically done in patients with CRPC after LH-RH agonist therapy. One important exception is palliative resection for obstructive symptoms, and we analyzed 22 such specimens. All samples displayed some degree of LH-RH receptor expression, including the specimens from 7 patients treated with LH-RH agonists. These findings were consistent with LH-RH expression patterns in a separate, unique cohort. This group of 61 patients was treated with neoadjuvant LH-RH agonists prior to curative resection. In this setting, LH-RH receptors were noted in most of the specimens. Together, the data indicate that LH-RH receptors are not downregulated following exposure to LH-RH agonists.

Additional studies revealed LH-RH receptor expression in metastases of prostate cancer. An early study noted LH-RH receptor gene mRNA in only a quarter (25.9%)

of lymph node metastases of prostate cancer (20). This low number may reflect the study's criteria of metastasis, which included expression of prostate specific antigen (PSA) mRNA without histopathologic confirmation. In addition, RT-PCR was done using RNA obtained from lymph nodes and not specifically from tumor cells. Our suspicion was that LH-RH receptor expression was prevalent in prostate cancer metastases, perhaps indicating a role in tumor growth or survival. In immunohistochemical analysis of 10 lymph node metastases, all samples showed moderate to strong expression of LH-RH receptors.

The precise role of LH-RH receptors in prostate cancer is not fully understood. Their presence on several, very different malignancies might suggest an important role in carcinogenesis, but these data do not speculate on the function of these receptors. In addition, the correlation between LH-RH receptor mRNA and Gleason score is hypothesis generating and supports a functional role for these receptors. The precise function of the LH-RH receptor is unclear, but its presence alone has provided the rationale for the design and synthesis of cytotoxic LH-RH conjugates consisting of analogs of LH-RH as carrier molecules linked to cytotoxic agents (21). These targeted agents do not rely on the function of the LH-RH receptor. They exploit the presence of LH-RH receptors on the plasma membranes of various tumors and, through internalization, introduce the cytotoxic molecule. Several compounds have been developed and have shown significant antitumor effect (22). A targeted cytotoxic analog of LH-RH containing doxorubicin conjugated to [D-Lys] (6) LH-RH is now available and has been used clinically in women with gynecologic cancers expressing LH-RH receptors (23). Our findings support the concept of targeting a therapy based on cytotoxic LH-RH analogs to LH-RH receptors on prostate cancers, even after prolonged LH-RH agonist therapy.

Disclosure of Potential Conflicts of Interest

J. Pinski: commercial research grant, Centocor; honoraria from speakers bureau, Sanofi-Aventis; ownership interest, OncoNatural-Solutions; consultant/advisory board, Sanofi-Aventis; expert testimony.

Received 04/28/2010; revised 07/15/2010; accepted 07/16/2010; published OnlineFirst 09/07/2010.

References

- American Cancer Society. Cancer facts and figures 2008. Atlanta: American Cancer Society; 2008.
- Loblaw DA, Virgo KS, Nam R, et al. Initial hormonal management of androgen-sensitive metastatic, recurrent, or progressive prostate cancer: 2007 update of an American Society of Clinical Oncology practice guideline. *J Clin Oncol* 2007;25:1596-605.
- Pinski J, Lamharzi N, Halmos G, et al. Chronic administration of the luteinizing hormone-releasing hormone (LH-RH) antagonist cetrorelix decreases gonadotrope responsiveness and pituitary LH-RH receptor messenger ribonucleic acid levels in rats. *Endocrinology* 1996; 137:3430-6.
- Lamharzi N, Halmos G, Armatas P, Schally AV. Expression of mRNA for luteinizing hormone-releasing hormone receptors and epidermal growth factor receptors in human cancer cell lines. *Int J Oncol* 1998; 12:671-5.
- Jungwirth A, Pinski J, Galvan G, et al. Inhibition of growth of androgen-independent DU-145 prostate cancer *in vivo* by luteinizing hormone-releasing hormone antagonist Cetrorelix and bombesin antagonists RC-3940-II and RC-3950-II. *Eur J Cancer* 1997;33: 1141-8.
- Tannock IF, de Wit R, Berry WR, et al. Docetaxel plus prednisone or mitoxantrone plus prednisone for advanced prostate cancer. *N Engl J Med* 2004;351:1502-12.
- Petrylak DP, Tangen CM, Hussain MH, et al. Docetaxel and estramustine compared with mitoxantrone and prednisone for advanced refractory prostate cancer. *N Engl J Med* 2004;351:1513-20.

8. Nagy A, Schally AV. Targeting of cytotoxic luteinizing hormone-releasing hormone analogs to breast, ovarian, endometrial, and prostate cancers. *Biol Reprod* 2005;73:851–9.
9. Straub B, Muller M, Krause H, et al. Increased incidence of luteinizing hormone-releasing hormone receptor gene messenger RNA expression in hormone refractory human prostate cancers. *Clin Cancer Res* 2001;7:2340–3.
10. Volker P, Grundker C, Schmidt O, Schulz KD, Emons G. Expression of receptors for luteinizing hormone-releasing hormone in human ovarian and endometrial cancers: frequency, autoregulation, and correlation with direct antiproliferative activity of luteinizing hormone-releasing hormone analogs. *Am J Obstet Gynecol* 2002;186:171–9.
11. Imai A, Ohno T, Iida K, Fuseya T, Furui T, Tamaya T. Presence of gonadotropin-releasing hormone receptor and its messenger ribonucleic acid in endometrial carcinoma and endometrium. *Gynecol Oncol* 1994;55:144–8.
12. Friess H, Buchler M, Kiesel L, Kruger M, Beger HG. LH-RH receptors in the human pancreas. Basis for anti-hormonal treatment in ductal carcinoma of the pancreas. *Int J Pancreatol* 1991;10:151–9.
13. Ben-Yehudah A, Lorberboum-Galski H. Targeted cancer therapy with gonadotropin-releasing hormone chimeric proteins. *Expert Rev Anticancer Ther* 2004;4:151–61.
14. Sion-Vardi N, Kaneti J, Segal-Abramson T, Giat J, Levy J, Sharoni Y. Gonadotropin-releasing hormone specific binding sites in normal and malignant renal tissue. *J Urol* 1992;148:1568–70.
15. Bahk JY, Kim MO, Park MS, et al. Gonadotropin-releasing hormone (GnRH) and GnRH receptor in bladder cancer epithelia and GnRH effect on bladder cancer cell proliferation. *Urol Int* 2008;80:431–8.
16. Baumann KH, Kiesel L, Kaufmann M, Bastert G, Runnebaum B. Characterization of binding sites for a GnRH-agonist (buserelin) in human breast cancer biopsies and their distribution in relation to tumor parameters. *Breast Cancer Res Treat* 1993;25:37–46.
17. Straub B, Muller M, Krause H, Schrader M, Miller K. Real-time quantitative reverse transcriptase-polymerase chain reaction for luteinizing hormone-releasing hormone receptor gene mRNA expression in human prostate cancer. *Urology* 2003;62:172–6.
18. Halmos G, Arencibia JM, Schally AV, Davis R, Bostwick DG. High incidence of receptors for luteinizing hormone-releasing hormone (LHRH) and LHRH receptor gene expression in human prostate cancers. *J Urol* 2000;163:623–9.
19. Szabo J, Vegh A, Racz G, Szende B. Immunohistochemical demonstration of gonadotropin-releasing hormone receptors in prostate carcinoma. *Urol Oncol* 2005;23:399–401.
20. Straub B, Muller M, Krause H, Schrader M, Goessl C, Miller K. Receptor gene messenger RNA expression in metastatic lesions of prostate cancer. *J Urology* 2002;168:1212–4.
21. Schally AV, Nagy A. Chemotherapy targeted to cancers through tumoral hormone receptors. *Trends Endocrinol Metab* 2004;15:300–10.
22. Pinski J, Schally AV, Yano T, et al. Inhibition of growth of experimental prostate cancer in rats by LH-RH analogs linked to cytotoxic radicals. *Prostate* 1993;23:165–78.
23. Emons G, Sindermann H, Engel J, Schally AV, Grundker C. Luteinizing hormone-releasing hormone receptor-targeted chemotherapy using AN-152. *Neuroendocrinology* 2009;90:15–8.