

A Case of Congenital Afibrinogenemia

By P. B. FERNANDO AND B. D. DHARMA SENA

THE FOLLOWING is a report of a case of congenital afibrinogenemia in a patient aged 22 years, who developed an apparently spontaneous hemoperitoneum at the age of 20 years when he came under investigation.

D. N. D., male, 20 years, was admitted on October 26, 1954, to the casualty surgical ward of the General Hospital, Colombo, with severe abdominal pain of two days' duration. Two days earlier he experienced a colicky, cramp-like abdominal pain which started in the left loin and spread over the entire abdomen. There was no trauma to the abdomen. The pain increased in intensity, and he vomited twice, the vomitus consisting of the meal taken earlier but there was no blood. He had two motions; there was no blood in the stools either. On the 25th, the pain was so severe that he was unconscious for about two hours. In the meantime his abdomen became progressively distended, and on the 26th he entered the General Hospital.

Personal History: Bachelor. Typist. Takes a well balanced diet. *Past History:* The patient was born at full term, and he gave a history of five bleeding episodes which were as follows: (1) At the age of thirteen days, bleeding started from the navel as the umbilical cord dropped off, and continued for five days in spite of sutures, bandages and local applications. (2) At the age of 5 years he bled for one day from an injury over the right cheek when bleeding was arrested by an application of crushed leaves. (3) At the 7th year he bled for one day from an injury to the forehead caused by a fall. (4) At the age of 15 years a boy struck him with a stone on the head and he bled for three days from the wound. (5) For the last 2 months preceding the present bleeding episode the patient had bled on several occasions from a carious tooth, whenever he used a toothpick; each bleeding bout lasted for about 2 hours.

He has had no spontaneous bleeding from the gums or subcutaneous hematoma. There was no history of hemoptysis, hematemesis, melena and hematuria, or pain and swelling in the joints. The bleeding episodes were always due to trauma, and were not accompanied or preceded by fever or taking of drugs. There was also no history of any allergic manifestation, purpuric rash or ecchymoses. *Family History:* The parents are first cousins and had nine children five of whom are alive. Mother is 48 years of age and does not give any history of abnormal bleeding. The father is 58 years old. In 1944 a jak fruit fell on his head and he lost consciousness for about half an hour. Three months later, he bled about half a cupful of blood from his nose spontaneously; this recurred two weeks later.

The first child, a male, 24 years, is in good health. The second was a miscarriage at the third month. The third, a male, at the age of 16 years in 1946, was struck over his right eye with a cricket ball, and was unconscious for about two hours. Two weeks later he developed severe headache which persisted; at the end of about a month the left side of the body became paralyzed rapidly. After admission to the hospital he lost consciousness and died. At the postmortem the cause of death was given as "bleeding into the brain." No further details are available.

The fourth child is the patient. The fifth, a male, 18 years, is normal. The sixth, a male, died at the age of 7 years of congenital heart disease. The seventh, a female, 14 years, is normal. The eighth, a male, died at the age of 3 years due to toxemia of worms. The ninth, a female, 9 years, is in good health.

Condition on Examination: On admission the patient was collapsed and the pulse was imperceptible. The heart rate was rapid and the lungs were clear. The abdomen was distended and held rigid. It was tender in the right iliac fossa. There was peristalsis.

An intravenous drip was set up with glucose saline followed by Periston and blood. On the 27th there was improvement in the general condition, the pulse ranging from 100-120

From the Department of Medicine, University of Ceylon.

Submitted July 30, 1956; accepted for publication Oct. 12, 1956.

per minute and of fair volume. The abdomen was still rigid and showed evidence of fluid in the peritoneal cavity. There was peristalsis. A further intravenous infusion of glucose saline and Amigen was given.

As the general condition was better, on the 28th a laparotomy was performed through a right paramedian supraumbilical incision. The peritoneal cavity was found to contain about two pints of blood. There was no site to be detected from where the bleeding could have taken place. The liver, spleen, kidneys and the gastrointestinal tract appeared normal. The wound was closed with drainage.

The blood count done on this day was: Hb.% 60. 8.5 Gm. per 100 cc. R.b.c. 3,210,000/cu.mm. Platelets 130,000/cu.mm. Bleeding Time: 3 minutes. Clotting Time: over 10 min. (not observed beyond).

On the following day (i.e., the 29th), though there was improvement in the general condition, the dressings were soaked with blood. A provisional diagnosis of hemophilia was made on account of the prolonged clotting time and the patient was treated with repeated blood transfusions. Still blood continued to ooze from the wound soaking the dressings at first in considerable quantities, but later it became progressively less till it completely stopped on November 19, 22 days after the operation. On November 22 the patient was transferred to the medical ward for further investigation.

The findings of the full blood investigation on December 1 were:

Hb.%—65. 9.3 Gm. per 100 cc.	Reticulocytes—0.1%
R.b.c.—3,680,000/cu.mm.	Av. Size of Red Cell—7.3/u
W.b.c.—9,000/cu.mm.	Blood Picture—Normal.
D.c.—P.37%, L.59%, E.4%.	Platelets—146,000/c.mm.
Packed Cell Volume: 35.1%	M.C.H: 28.8 $\gamma\gamma$
M. C. V.: 97.5 c/u	M.C.H.C.: 29.6%
Colour Index: 0.8	Bleeding Time: 4 min.
Icterus Index: 4	Clotting Time: over 30 min. (not observed beyond)
	One-Stage Prothrombin Time: over 2 min. (control 24 sec.)

Van den Bergh Reaction: Direct & Indirect—Negative.

Takata Ara Reaction: Negative.

Plasma Proteins: Albumin = 3.17 Gm. %
 Globulin = 2.92 Gm. %
 Fibrinogen = Nil Gm. %

—————
 Total = 6.09 Gm. %

Hess's Capillary Resistance Test: No petechiae.

Further investigation. It was observed that the blood did not clot in the test tube even after four days suggesting the condition was that of afibrinogenemia. Hence the plasma proteins were estimated again on 7/12/54 as Albumin = 3.72 Gm. per cent; Globulin = 2.67 Gm. per cent; Fibrinogen = Nil; Total = 6.39 Gm. per cent.

The electrophoretic pattern of the proteins in the patient's plasma was similar to that of normal serum suggesting absence of fibrinogen in the patient's plasma. Addition of Russel's Viper Venom (Stypven) or Topical Thrombin (Roche) did not clot the blood. But addition of fibrinogen, prepared by the method recommended by Jaques¹ corrected both the clotting and one-stage prothrombin times. The erythrocyte sedimentation was 2 mm. in the 1st hour and 5 mm. in the 2nd hour. All these tests confirmed the total absence of fibrinogen.

In order to find out whether any deficiencies of antihemophilic globulin, Christmas factor, factors V and VII were present, the thromboplastin generation test was performed. To test for antihemophilic globulin and factor V, thrombo-

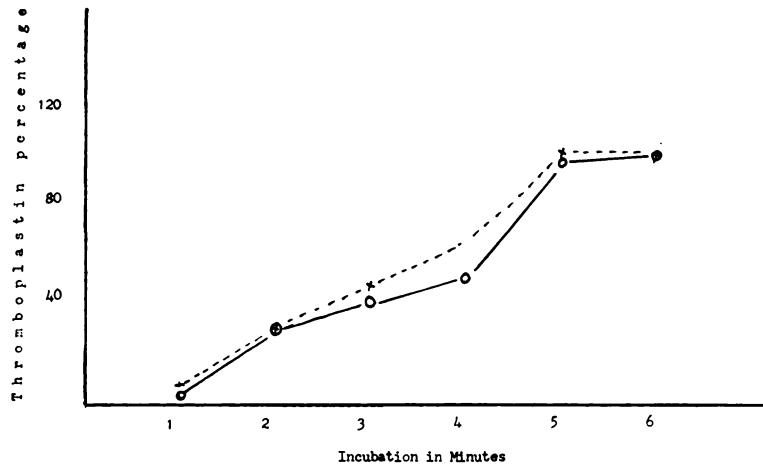


FIG. 1.—Thromboplastin generation test. X-----X = Patient's plasma + normal alumina plasma + normal platelets; O——O = patient's plasma + normal serum + normal platelets.

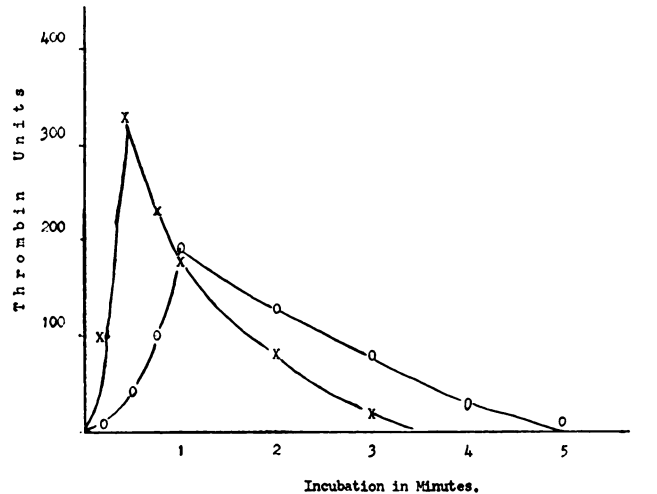


FIG. 2.—Two-stage prothrombin estimation. X——X = Prothrombin content in normal plasma; O——O = prothrombin content in patient's plasma.

plastin was generated using normal platelets, patient's plasma and normal serum, and the amount of thromboplastin generated was estimated at one minute intervals. This was repeated, using normal platelets, patient's plasma and normal plasma adsorbed with aluminum hydroxide. But both curves (fig. 1) showing the amount of thromboplastin generated were of the normal pattern confirming the presence of adequate amounts of antihemophilic globulin, Christmas factor, factors V and VII.

To determine the amount of the prothrombin present, the two-stage prothrombin estimation was done (fig. 2). The curves covered equal areas representing equal amounts of prothrombin in both patient's and normal plasma.

There was no evidence of a circulating anticoagulant as the clotting and the one-stage prothrombin times of normal plasma were not prolonged by the addition of the patient's plasma.

To find out the cause of the absence of fibrinogen, the possibility of a circulating fibrinolysin was investigated. Normal plasma was added to patient's plasma and the mixture was incubated for 24 hours. But there was no reduction of the amount of fibrinogen in the normal plasma.

The prostate gland was normal and the serum acid phosphatase was 1.40 K.A. Units. There was no clinical or laboratorial evidence of liver dysfunction. The family members were examined with regard to their plasma fibrinogen level. The following are the findings:

Father	Fibrinogen Level	0.20 Gm.%
Mother	Fibrinogen Level	0.29 Gm.%
1st Brother	Fibrinogen Level	0.50 Gm.%
2d Brother	Fibrinogen Level	0.25 Gm.%
1st Sister	Fibrinogen Level	0.30 Gm.%
2d Sister	Fibrinogen Level	0.20 Gm.%

COMMENTS

It has been shown that the mechanism of blood coagulation is more complicated than is suggested by the original theory of Morawitz and that a number of factors besides the original prothrombin, thrombokinase, calcium and fibrinogen are involved.² These discoveries, however, have not affected the dominant role of fibrinogen, for the essential process of blood coagulation is the conversion of fibrinogen to fibrin. In the absence of fibrinogen blood cannot clot, however perfect the other mechanisms may be. Temporary deficiency of fibrinogen causing severe hemorrhage may result from toxic or neoplastic interference with the production of fibrinogen, from a circulating fibrinolysin as in metastatic carcinoma of the prostate, from excessive utilization as in such complications of pregnancy as abruptio placentae, amniotic fluid embolism and intrauterine death and retention of fetus from Rhesus incompatibility.^{3, 4}

Complete and permanent absence of fibrinogen is found only as a congenital abnormality. The first case of congenital afibrinogenemia was reported by Rabe and Saloman in 1920; since then 21 other cases have been reported in the literature.^{5, 6} A case in a subject of mixed oriental extraction has been reported by de Silva and Thanabalasunderam.⁷

This rare condition affects both males and females, but males are more frequently affected; 16 of the 23 cases occurred in males. In every case reported the bleeding tendency made its appearance in early life. Our patient first started bleeding on the thirteenth day of life. Consanguinity of parents or grandparents has been noted in nine cases, including ours, and the occurrence of a hemorrhagic diathesis has been reported in the relatives of seven cases. In this case too, one brother died of cerebral hemorrhage following trauma and the father has had two attacks of spontaneous epistaxis. The latter's fibrinogen level on estimation was 0.20 per cent. Another interesting fact is that one of the brothers succumbed to congenital heart disease.

Bleeding time has shown wide variation in the reported cases; our patient had a bleeding time of four minutes. Similarly intermittent thrombocytopenia has been observed in some cases though the platelets were within the normal range in our case. Hess's positive pressure capillary resistance test was negative in all except in one.⁸ But Henderson et al.³ report decreased capillary resistance by employing Scarborough's negative pressure technic. Erythrocyte sedimentation rate has been low in all cases in which it was carried out. This is to be expected as sedimentation depends on the fibrinogen content of the blood. The one-stage prothrombin time has been done only in three patients and it was prolonged in all. In our case too it was prolonged. But the prothrombin content itself was normal as shown by the two-stage prothrombin estimation. Factors entering into the first phase of coagulation, viz., factor V and factor VII, antihemophilic globulin and Christmas factor were also normal as determined by the thromboplastin generation test.

With regard to the genetic basis of this case the following are of significance. The parents were not examples of afibrinogenemia. They were shown to have fibrinogen in the blood. Of the eight children born four are of good health and were also shown to have fibrinogen in their blood. Of the three who died, the causes of death were congenital heart disease, toxemia of worms and bleeding following trauma. It would appear therefore that two out of the eight children were examples of afibrinogenemia. This would suggest that the transmission of the disease is through the recessive genes in both parents and that both parents are heterozygous.

These patients have a poor prognosis. Six patients have died in infancy or childhood, all due to excessive bleeding from trauma. Spontaneous bleeding is unusual, although the hemorrhage that brought our patient to hospital was apparently spontaneous. The oldest reported patient was 22 years. Our patient is now in his 22nd year and is leading an active life. Although blood transfusion undoubtedly saved his life on this occasion, he had survived several episodes of bleeding without blood transfusion. Apparently the vascular mechanisms concerned in hemostasis are as important for preservation of life as the coagulation of blood.

Treatment of this condition consists of replacement transfusion with fibrinogen or blood combined with antishock therapy such as saline infusion, bed rest and sedation.

SUMMARY

1. A case of congenital afibrinogenemia of a Sinhalese boy of 22 years is reported.
2. The main features of the reported cases are reviewed.
3. The principal features of this case are total absence of fibrinogen in the blood, complete non-coagulability of blood, history of several episodes of hemorrhage dating from infancy, low erythrocyte sedimentation rate, consanguinity of the parents and the occurrence of spontaneous hemoperitoneum from which he recovered after operation.
4. Treatment consists of blood or fibrinogen transfusion.

SUMMARIO IN INTERLINGUA

1. Es reportate un caso de afibrinogenemia congenite in un masculino cingalese de 22 annos de etate.
2. Es presentate un revista del principal aspectos de previemente reportate casos.
3. Le principal aspectos del presente caso es absentia total de fibrinogeno in le sanguine, complete noncoagulabilitate del sanguine, historia de plure episodios de hemorrhagia a partir del prime infantia, basse valores del sedimentation erythrocytic, consanguineitate del parentes, e occurrentia de hemoperitoneo spontanee con restablimento postoperatori.
4. Le tractamento consiste in transfusiones de sanguine o fibrinogeno.

ACKNOWLEDGMENTS

We wish to thank Dr. A. S. Rajasingham, F.R.C.S. (Eng.) for transferring the patient under our care, and Dr. T. W. Wickremanayake for doing the electrophoretic analysis of the blood.

REFERENCES

- ¹ JAKES, L. B.: The reducing properties of fibrinogen. *Biochem. J.* **37**: 344, 1943.
- ² STEFANINI, M.: Basic mechanisms of hemostasis. *Bull. N. Y. Acad. of Med.* **30**: 239, 1954.
- ³ HENDERSON, J. L., DONALDSON, G. M. M. AND SCARBOROUGH, H.: Congenital afibrinogenemia: report of a case with review of literature. *Quart. J. Med.* **14**: 101, 1945.
- ⁴ BARNETT, VIVIEN H. AND CUSSEN, C. A.: Acquired afibrinogenemia complicating pregnancy. *Brit. M. J.* **2**: 676, 1954.
- ⁵ PRICHARD, R. W. AND VANN, R. L.: Congenital afibrinogenemia: report on a child without fibrinogen and review of literature. *Am. J. Dis. Child.* **88**: 703, 1954.
- ⁶ LEWIS, J. H., AND FERGUSON, J. H.: Afibrinogenemia: report of a case. *Am. J. Dis. Child.* **88**: 711, 1954.
- ⁷ DE SILVA, C. C. AND THANABALASUNDERAM, R. S.: Congenital Afibrinogenemia. *Brit. M. J.* **2**: 86, 1951.
- ⁸ MACFARLANE, R. G.: Boy with no fibrinogen. *Lancet* **234**: 309, 1938.