

# Severe Neurotoxicity following 5-Fluorouracil-based Chemotherapy in a Patient with Dihydropyrimidine Dehydrogenase Deficiency<sup>1</sup>

Chris H. Takimoto,<sup>2</sup> Zhi-Hong Lu,  
Ruiwen Zhang, Michael D. Liang,  
Lydia V. Larson, Louis R. Cantilena, Jr.,  
Jean L. Grem, Carmen J. Allegra,  
Robert B. Diasio, and Edward Chu

National Cancer Institute-Navy Medical Oncology Branch, National Cancer Institute, National Institutes of Health, Bethesda, Maryland 20889-5105 [C. H. T., M. D. L., L. V. L., J. L. G., C. J. A., E. C.]; Department of Pharmacology and Toxicology, University of Alabama at Birmingham, Birmingham, Alabama 35294-8240 [Z.-H. L., R. Z., R. B. D.]; and Division of Clinical Pharmacology, Uniformed Services University of the Health Sciences, Bethesda, Maryland 20814-4799 [L. R. C.]

## ABSTRACT

Patients with decreased dihydropyrimidine dehydrogenase (DPD) activity are at increased risk for experiencing serious adverse reactions following 5-fluorouracil (5-FU)-based chemotherapy. Symptoms include severe and potentially life-threatening gastrointestinal toxicity, myelosuppression, and neurological toxicity. In the present study, we describe a 50-year-old Caucasian man who developed severe encephalopathy during his second cycle of 5-FU chemotherapy. The patient remained in a comatose state for 4 days but then showed dramatic improvement in his neurological status following continuous i.v. infusion of thymidine at 8 g/m<sup>2</sup>/day. Laboratory studies revealed the patient to be severely DPD deficient, as demonstrated by DPD enzyme activity from peripheral blood mononuclear cells being below the lower limit of the 95th percentile of a control population and by Western immunoblot analysis showing undetectable levels of DPD protein. Additional studies revealed a significant defect in pyrimidine catabolism with a 3.3- and 365-fold increase in the levels of uracil in plasma and urine, respectively, compared to normal subjects. Family studies suggest that the inheritance pattern of this syndrome is complex and most consistent with an autosomal recessive trait. This study demonstrates that cancer patients with DPD deficiency are at increased risk for developing severe neurological toxicity secondary to 5-FU chemotherapy, and that infusional thymidine should be considered as a potential rescue agent against this particular host toxicity.

## INTRODUCTION

Patients with an inherited deficiency of DPD<sup>3</sup> (EC 1.3.1.2), the rate-limiting enzyme responsible for the catabolism of 5-FU, are at increased risk for experiencing severe adverse reactions to fluoropyrimidine-based chemotherapy (1). Several studies (1-6) have characterized patients with undetectable DPD activity in their PBM cells who were initially identified by their inability to tolerate standard doses of 5-FU-based chemotherapy. In patients deficient in DPD, decreased 5-FU clearance has been observed, resulting in enhanced drug exposure and increased host toxicity. Since affected individuals may otherwise be in good health, the first indication of the presence of this inborn error of metabolism usually follows an unexpectedly severe reaction to 5-FU-based chemotherapy. Careful testing of families of DPD-deficient patients has revealed an autosomal recessive pattern of inheritance (1-3). Although the exact frequency of this pharmacogenetic syndrome remains unknown, preliminary population-based studies suggest that the complete absence of DPD activity is relatively rare (4-6). However, it is now recognized that even partial enzyme deficiency may also result in severe 5-FU toxicity (2, 3). Two leading groups (4-6) have estimated that as high as 3% of adult cancer patients may have significantly decreased DPD activity. Given their impaired ability to catabolize 5-FU, these patients are at particular risk for developing severe adverse reactions to 5-FU-based chemotherapy. Therefore, additional clinical studies are needed to characterize the various clinical manifestations of this pharmacogenetic syndrome. In addition, widespread population-based studies including cancer patients are now in progress to determine the true incidence of DPD deficiency as well as to establish the relationship between the level of DPD activity and 5-FU toxicity (4, 5).

Administration of standard doses of 5-FU to DPD-deficient patients has resulted in severe, potentially life-threatening symptoms such as mucositis and myelosuppression as well as neurological toxicity, a relatively less common side effect. The most commonly described neurological syndrome associated with fluoropyrimidine therapy has been cerebellar ataxia (7); however, a slowly reversible encephalopathic syndrome, characterized by the onset over several weeks of cognitive dysfunction, confusion, and somnolence with demyelinating changes on computed tomography and MRI has also been observed (1, 8, 9). Cessation of 5-FU chemotherapy has usually resulted in the gradual resolution of such neurological abnormalities over a period of weeks to months. To date, however, therapeutic approaches to prevent and/or overcome the host toxic effects of

Received 10/6/95; revised 11/16/95; accepted 11/20/95.

<sup>1</sup> This study was supported in part by USPHS/NIH Grant CA-64214 (to R. B. D.) and U. S. Army Grant DAMD 17-94-J-4115 (to Z.-H. L.).

<sup>2</sup> To whom requests for reprints should be addressed, at NCI-Navy Medical Oncology Branch, National Naval Medical Center, 8901 Wisconsin Avenue, Building 8, Room 5101, Bethesda, MD 20889-5105. Phone: (301) 496-0901; Fax: (301) 496-0047.

<sup>3</sup> The abbreviations used are: DPD, dihydropyrimidine dehydrogenase; PBM, peripheral blood mononuclear; 5-FU, 5-fluorouracil; CT, computed tomographic; MRI, magnetic resonance imaging; NCI, National Cancer Institute; HPLC, high-performance liquid chromatography.

5-FU have met with little success. This report describes the unusually rapid onset of severe encephalopathy in a patient with profound DPD deficiency following treatment with 5-FU-based chemotherapy. The systemic administration of continuous i.v. thymidine was associated with rapid reversal of symptoms and full return of his neurological status to normal.

## MATERIALS AND METHODS

**Patient.** A 50-year-old Caucasian man of Norwegian ancestry with recurrent metastatic hepatocellular carcinoma, fibrolamellar variant, was referred to the NCI in January 1994 for experimental chemotherapy. He had been disease-free for 9 years following resection of his primary liver tumor in 1983, which involved the entire left lobe and the anterior segment of his right lobe. In 1993, he developed recurrent disease confined to the chest pleura for which he received six cycles of chemotherapy with Tomudex (ZD1694), an antifolate inhibitor of thymidylate synthase. Treatment was stopped because of disease progression. Three months later, in January 1994, he was enrolled on a NCI protocol studying the combination of paclitaxel, 5-FU, and calcium leucovorin.

Pretreatment evaluation revealed a well-nourished appearing man (height, 175 cm; weight, 85 kg) with normal liver function tests except for mildly elevated liver transaminases with an aspartate aminotransferase of 134 units/dl (normal, <35 units/dl) and an alanine aminotransferase of 240 units/dl (normal, <56 units/dl). Chest, abdomen, and brain CT scans revealed only pleural-based disease in the thorax, with no evidence of liver or brain metastases. He was treated with 175 mg/m<sup>2</sup> paclitaxel given i.v. over 3 h on day 1 followed by 4 days of daily i.v. 500 mg/m<sup>2</sup> calcium leucovorin and 370 mg/m<sup>2</sup> bolus 5-FU on days 2 through 5. On the eighth day of cycle 1, he was admitted to a local hospital with complaints of diarrhea (NCI toxicity scale, grade 2), nausea and vomiting (grade 2), dehydration, and confusion, being oriented only to person but not to place or time. Diagnostic evaluation revealed a normal brain CT scan and normal blood chemistries, with the exception of persistently elevated serum transaminases with an aspartate aminotransferase of 73 units/dl and an alanine aminotransferase of 206 units/dl. Given concern for a possible adverse drug reaction, his medications, which included a benzodiazepine sedative, acetaminophen/codeine, ondansetron, and diphenoxylate HCl/atropine sulfate, were all stopped. p.o. lactulose was also administered for the presumptive diagnosis of hepatic encephalopathy. During this time period, there were no symptoms of stomatitis and only transient, mild myelosuppression with grade 1 neutropenia. His mental status gradually improved back to baseline over the ensuing week, and he was discharged to home on hospital day 7. Three days later, he developed a left lower extremity deep venous thrombosis which required heparin followed by coumadin anticoagulation.

Seven weeks after his initial cycle of chemotherapy, he returned for a second cycle receiving paclitaxel at a reduced dose of 135 mg/m<sup>2</sup> and the same doses of 5-FU and leucovorin. On the morning of his fourth day of treatment, he presented to the Medical Oncology Outpatient Clinic complaining of nausea (grade 1) and mild confusion; he was oriented to person and place but not to the current date. His medications included

coumadin, metoclopramide, and lactulose. Upon admission to the hospital, he underwent CT and MRI scans of the brain which revealed no mass lesions and no evidence of demyelination. A lumbar puncture revealed 4 WBC cells and 31 RBC cells, a mildly elevated cerebrospinal fluid protein of 50 mg/dl (normal, <40 mg/dl), and cerebrospinal fluid cultures revealed no evidence of infection. Blood chemistries demonstrated only persistently elevated liver transaminases and an elevated prothrombin time at a level consistent with therapeutic coumadin anticoagulation. Within 4–6 h after hospital admission, he became increasingly obtunded with no spontaneous movements other than withdrawal to painful stimuli. An electroencephalogram demonstrated triphasic changes consistent with a metabolic encephalopathy. On hospital day 3, following a grand mal seizure, he was started on phenytoin, intubated for airway protection, and transferred to the intensive care unit. Despite these precautions, he developed an aspiration pneumonia, requiring antibiotic therapy.

On hospital day 4, he remained severely obtunded, withdrawing only to noxious stimuli. A continuous i.v. infusion of thymidine at 8 g/m<sup>2</sup>/day for 3 days was started in an attempt to "rescue" against the potential effects of 5-FU toxicity. Compassionate use of experimental i.v. thymidine was provided by the Investigational Drug Branch, Cancer Therapy Evaluation Program (Division of Cancer Treatment, NCI, Bethesda, MD). Twelve h after the start of the thymidine infusion, his mental status dramatically improved, and he began to respond appropriately to verbal stimuli by hand squeezing on command. Thirty-six h after starting the thymidine infusion, he was completely alert and oriented to person, place, and time. Over the next 3 days, he continued to improve, with complete return of his mental status to normal, and he was discharged on hospital day 12. Nineteen months since this episode, he is alive and well despite persistent metastatic disease.

**Materials.** 5-FU was purchased from Sigma Chemical Co. (St. Louis, MO). [<sup>3</sup>H]5-FU (25 Ci/mmol) was obtained from New England Nuclear Corp. (Boston, MA). Acrylamide and prestained molecular weight markers were purchased from Bio-Rad (Richmond, CA). Alkaline phosphatase-labeled goat anti-rabbit antibody, nitro blue tetrazolium, and 5-bromo-4-chloro-3-indolyl phosphate toluidine salt were obtained from Southern Biotechnology (Birmingham, AL). All other solvents and reagents were of the highest grade available. Buffer A used in both sample preparation and enzyme assay contained 35 mM potassium phosphate (pH 7.4), 2.5 mM magnesium chloride, and 10 mM 2-mercaptoethanol.

**Determination of DPD Activity in PBM Cells.** PBM-DPD activity was quantitated using methods previously described (3). In brief, blood samples (25 ml) were collected in heparinized tubes and then loaded onto a centrifuge tube containing 15 ml Histopaque (Sigma). After centrifugation at 500 × g for 30 min at 25°C, the PBM cell fraction was carefully removed and washed three times with PBS. Contaminating RBCs were hypotonically lysed, and PBM cells were stored at –70°C until further analysis. PBM cells were suspended in and washed with buffer A, then placed in an ice bath and lysed by sonication (three times for 10 s with a 30-s interval between sonication). After centrifugation at 14,000 × g for 15 min at 4°C, the supernatant was removed and subsequently used in the

Table 1 DPD activity in PBM cells and uracil levels in plasma and urine

Parameters	Patient	Control
PBM-DPD (nmol/min/mg)	0.037 ± 0.01 <sup>a</sup>	0.163 <sup>b</sup> (0.189 ± 0.064 <sup>c</sup> )
Plasma uracil (nmol/ml)	1.09	0.33 ± 0.05 (n = 5) <sup>d</sup>
Urinary uracil (nmol/ml)	911.4	<2.5 (n = 10) <sup>d</sup>

<sup>a</sup> Mean DPD activity from three separate determinations.

<sup>b</sup> Control sample performed under the same conditions as the patient's sample.

<sup>c</sup> Mean DPD activity obtained from a population-based study (n = 123) by Lu *et al.* (3).

<sup>d</sup> Values obtained from a population-based study (Z.-H. Lu *et al.*, unpublished data).

enzyme assay. The amount of protein in the lysate supernatant was determined according to the method of Bradford (10).

A radioassay was used to determine DPD activity (3). Separation of 5-FU and its catabolites was performed by reverse-phase HPLC using a Hewlett-Packard 1050 HPLC system equipped with a spectrophotometric detector and chromatographic terminal (HP 3396 Series II Integrator) as previously described (3, 11). The affected patient (proband) and his family members were tested on at least two separate occasions. As shown in previous studies, the radioassay was sensitive and accurate in determination of DPD activity in PBM cells (3).

**Western Immunoblot Analysis.** The primary antibody used in this study was the purified rabbit polyclonal antibody against human liver DPD, and Western immunoblot analysis was performed as previously described (12).

**HPLC Analysis of Uracil in Plasma and Urine.** The concentration of uracil in plasma and urine was determined by a modification of the methods as previously described (13).

## RESULTS AND DISCUSSION

In this report, we describe a patient who developed an unusually severe neurotoxic reaction to 5-FU-based chemotherapy. Following three separate determinations over a 19-month period, the mean DPD activity in the PBM cells of the patient was shown to be 0.037 nmol/min/mg (Table 1), which is well below the 95th percentile of DPD activity in a normal population (3). His DPD activity is also significantly lower than the mean value in unselected cancer patients (0.222 nmol/min/mg) as recently reported by Etienne *et al.* (6). Therefore, it is appropriate to classify this patient as having profound DPD deficiency. Using an affinity-purified antihuman DPD polyclonal antibody, Western immunoblot analysis revealed virtually undetectable DPD protein levels in the patient's PBM cells when compared to the level observed in control PBM samples (Fig. 1). These findings demonstrate a strong correlation between the level of DPD enzyme activity and DPD protein expression. As evidence for this deficiency in DPD being associated with a defect in pyrimidine catabolism, there was a 3.3- and 365-fold increased concentration of uracil in the patient's plasma and urine, respectively, when compared to levels measured in a control population (Table 1). Although 5-FU pharmacokinetics was not monitored in this patient, there was no detectable circulating 5-FU in the patient's plasma 24 h following his last dose of drug using a sensitive gas chromatographic

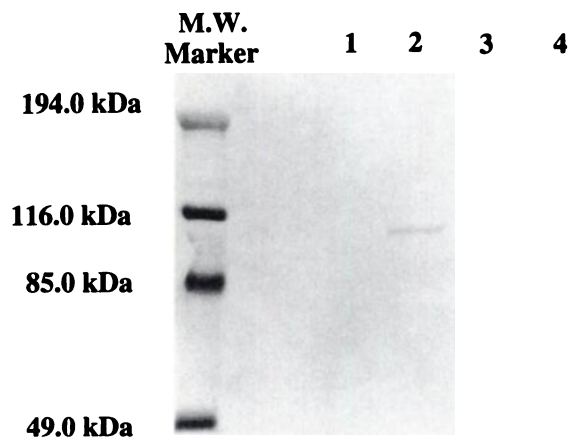


Fig. 1 Western immunoblot analysis of PBM cell DPD. Lanes 1 and 2, 100  $\mu$ g total cellular protein. Lanes 3 and 4, 200  $\mu$ g total cellular protein. All proteins were resolved on a 7% SDS-polyacrylamide gel, and staining of the Western blot was performed as described in "Materials and Methods." Proteins were from patient PBM cells (Lanes 1 and 3) and control PBM cells (Lanes 2 and 4).

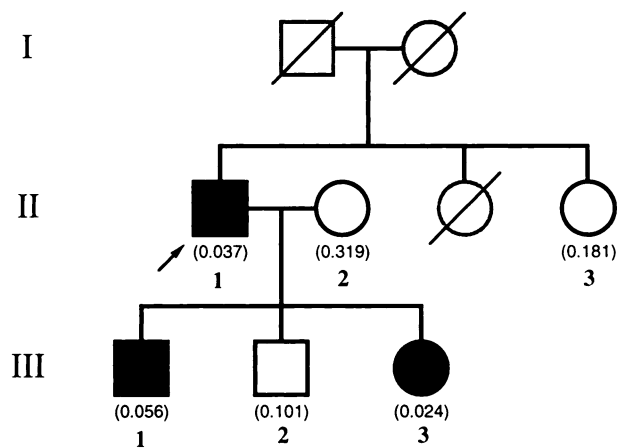


Fig. 2 Pedigree of the patient and his family members showing inheritance of a defect in DPD activity. Parentheses, DPD activity (nmol/min/mg) of each family member tested. Arrow, the patient;  $\emptyset$  and  $\square$ , deceased family members who were not tested.  $\circ$  and  $\square$ , control levels of DPD activity;  $\bullet$  and  $\blacksquare$ , partial to severe deficiency of DPD activity. I, II, and III indicate first, second, and third generation family members, respectively.

mass spectrometric assay (lower limit of sensitivity, 0.5 ng/ml; data not shown; Ref. 14).

We have also been able to test for the level of DPD activity in the patient's immediate family members. As seen in Fig. 2, one of the patient's sons had very low DPD activity (0.056 nmol/min/mg), whereas the DPD activity of a second son fell within the low normal range and in the lower 68th percentile of a normal population (0.101 nmol/min/mg). The patient's daughter had an extremely low level of DPD activity (0.024 nmol/min/mg) which is below the 95th percentile of a normal population. Of note, the DPD activity in the PBM cells of both the

patient's wife (0.319 nmol/min/mg) and his sister (0.181 nmol/min/mg) were within the normal range. Although the number of family members tested in this study is small, these results demonstrate a complex pattern in inheritance and suggest that the phenotype of this syndrome is inherited as an autosomal recessive pattern (Fig. 2). Previous studies have suggested that DPD deficiency is inherited as an autosomal recessive pattern (1, 2). Clearly, additional studies to include additional families with this pharmacogenetic syndrome along with their genotypic characterization are required to more precisely elucidate the inheritance pattern.

In addition to receiving 5-FU and leucovorin, the patient also received paclitaxel as part of his chemotherapy regimen. Although paclitaxel therapy has been associated with peripheral neurological toxicity, to our knowledge, there have not been any documented reports of encephalopathy following paclitaxel administration. In addition, measurement of the patient's plasma levels for paclitaxel during his first cycle of therapy did not reveal any gross abnormalities in his pharmacokinetic profile (data not shown). However, it remains to be determined whether paclitaxel therapy may alter 5-FU pharmacokinetics and/or pharmacodynamics and, in so doing, predispose patients receiving this drug combination to increased 5-FU toxicity. Additional studies are required to determine whether paclitaxel or one of its metabolites may, in some manner, directly affect pyrimidine catabolism.

In contrast to previously reported cases of 5-FU neurotoxicity associated with DPD deficiency (1–3, 9, 15, 16), our patient is unique with regard to the rapid onset and severity of his neurological symptoms which progressed to a comatose state within 72 h into his second cycle of 5-FU-based chemotherapy. His neurological toxicity was principally manifested in the form of a metabolic encephalopathy without the more typical finding of cerebellar ataxia. In addition, both CT and MRI scans of the brain were normal, with no evidence of cortical demyelination nor any other intracerebral process. Unlike previous reports where neurotoxicity was associated with either severe myelosuppression or stomatitis and/or diarrhea (1–3, 9, 15, 16), the patient under study experienced only mild gastrointestinal and bone marrow toxicities ( $\leq$  grade 2). Moreover, his neurological function recovered relatively rapidly over the course of several days; in particular, following the systemic administration of infusional thymidine.

Previous attempts to intervene and acutely treat the severe 5-FU-associated toxicities in DPD-deficient patients have been largely unsuccessful. Hemodialysis of a patient with DPD deficiency failed to lower the elevated 5-FU levels primarily due to the rapid rebound in plasma drug levels (17). As a rescue maneuver, charcoal hemoperfusion was able to successfully lower elevated 5-FU levels by nearly 10-fold; however, the toxic effects of 5-FU still resulted in a fatal outcome (17). Although administration of uridine has been used to abrogate some of the severe toxicities associated with 5-FU (18), uridine rescue therapy did not alter the progressively fatal clinical course for any DPD-deficient patient in whom it was attempted (17).

For the patient presented herein, there was rapid recovery of neurological function following the administration of infusional thymidine. Thymidine infusions have been used previously in patients with severe 5-FU or methotrexate toxicity to

rescue against the inhibition of thymidylate synthase and to prevent the DNA-damaging effects of these two antimetabolites (19). Although the direct effect of this therapeutic intervention on the patient's dramatic clinical improvement cannot be directly proven, the temporal relationship certainly suggests a causal association. To date, the etiology of 5-FU neurotoxicity remains poorly characterized. Earlier investigators theorized that the conversion of 5-FU to fluoro- $\beta$ -alanine and the potentially neurotoxic metabolites fluorocitrate and fluoroacetate might be responsible for 5-FU-associated cerebellar toxicity (20). The development of neurotoxicity in DPD-deficient patients with an obvious defect in pyrimidine catabolism and an inability to generate these potentially toxic metabolites argues strongly against their direct involvement. Diasio *et al.* (1) have suggested that 5-FU-associated neurological toxicity may be related to effects on RNA metabolism, since inhibition of DNA and thymidine synthesis mediated by 5-FU metabolites may be less important in the central nervous system where neuronal cells are not actively dividing. However, the apparently successful rescue of profound neurotoxicity with infusional thymidine in this one patient suggests that a DNA-directed or thymidylate synthase-based mechanism may mediate fluoropyrimidine-induced neurological toxicity. Finally, in considering the appropriate time of administration of thymidine rescue in patients who develop serious 5-FU neurotoxicity, it should be noted that thymidine can potentially interfere with 5-FU clearance and further prolong drug half-life (13). A previous pharmacokinetic study by Diasio *et al.* (1) demonstrated that unusually high levels of 5-FU were still detectable in the plasma of a patient with DPD deficiency for at least 8 h following a test dose of 5-FU. Given these observations, institution of thymidine infusion immediately following 5-FU administration should be avoided. Since this case represents the first time that thymidine infusion has been successfully used to rescue against the host neurotoxic effects of 5-FU, precise guidelines for when it should be started are not presently available and await further studies. However, based on our experience with this one patient, it would appear that infusion of thymidine rescue can be safely instituted at least 12–24 h following 5-FU administration.

This report describes a patient with severe DPD deficiency who experienced severe, reversible encephalopathy following two cycles of 5-FU-based chemotherapy. This case is unique not only for the acute onset of neurological toxicity but also for the rapid improvement in his neurological condition following the systemic administration of infusional thymidine. Given our experience with this case, early recognition of even mild neurological symptoms during the initial cycles of 5-FU-based chemotherapy should raise the suspicion of DPD deficiency. Since the incidence of partial to severe DPD deficiency may be as high as 3% in the general population of cancer patients, oncologists administering 5-FU-based chemotherapy need to be aware of the potential risk of severe neurological toxicity in these patients. Finally, infusional thymidine should be considered as a therapeutic option to be used in patients who manifest serious neurological toxicity secondary to 5-FU chemotherapy.

## ACKNOWLEDGMENTS

We thank Jieming Yan for his technical assistance, Janet Edds for her editorial assistance in the preparation of the manuscript, and the patient and his family for their kind support of this study.

## REFERENCES

1. Diasio, R. B., Beavers, T. L., and Carpenter, J. T. Familial deficiency of dihydropyrimidine dehydrogenase. *J. Clin. Invest.*, *81*: 47–51, 1988.
2. Harris, B. E., Carpenter, J. T., and Diasio, R. B. Severe 5-fluorouracil toxicity secondary to dihydropyrimidine dehydrogenase deficiency: a potentially more common pharmacogenetic syndrome. *Cancer (Phila.)*, *68*: 499–501, 1991.
3. Lu, Z., Zhang, R., and Diasio, R. B. Dihydropyrimidine dehydrogenase activity in human peripheral blood mononuclear cells and liver: population characteristics, newly identified deficient patients and clinical implication in 5-fluorouracil chemotherapy. *Cancer Res.*, *53*: 5433–5438, 1993.
4. Diasio, R. B. Genetic polymorphism of dihydropyrimidine dehydrogenase: Implications for 5-fluorouracil metabolism and toxicity. *Proc. Am. Assoc. Cancer Res.*, *35*: 688, 1994.
5. Diasio, R. B., and Lu, Z-H. Dihydropyrimidine dehydrogenase activity and fluorouracil chemotherapy. *J. Clin. Oncol.*, *12*: 2239–2242, 1994.
6. Etienne, M. C., Lagrange, J. L., Dassonville, O., Fleming, R., Thyss, A., Renée, N., Schneider, M., Demard, F., and Milano, G. Population study of dihydropyrimidine dehydrogenase in cancer patients. *J. Clin. Oncol.*, *12*: 2248–2253, 1994.
7. Grem, J. L. 5-Fluoropyrimidines. In: B. A. Chabner and D. L. Longo (eds.), *Cancer Chemotherapy and Biotherapy: Principles and Practice*, Second Edition, pp. 149–211. Philadelphia: Lippincott-Raven, 1996.
8. Lynch, H. T., Droszcz, C. P., Albano, W. A., and Lynch, J. F. Organic brain syndrome secondary to 5-fluorouracil toxicity. *Dis. Colon Rectum*, *24*: 130–131, 1981.
9. Fassas, A. B. T., Gattani, A. M., and Morgello, S. Cerebral demyelination with 5 fluorouracil and levamisole. *Cancer Invest.*, *12*: 379–383, 1994.
10. Bradford, M. A. Rapid sensitive method for the quantitation of microgram quantities of protein utilizing the principle of protein-dye binding. *Anal. Biochem.*, *72*: 258–264, 1976.
11. Sommadossi, J. P., Gewirtz, D. A., Diasio, R. B., Aubert, C., Cano, J. P., and Goldman, I. D. Rapid catabolism of 5-fluorouracil in freshly isolated hepatocytes as analyzed by high performance liquid chromatography. *J. Biol. Chem.*, *257*: 8171–8176, 1982.
12. Lu, Z-H., Zhang, R., and Diasio, R. B. Purification and characterization of dihydropyrimidine dehydrogenase from human liver. *J. Biol. Chem.*, *267*: 17102–17109, 1992.
13. Au, J. L., Rustum, Y. M., Ledesma, E. J., Mittelman, A., and Creaven, P. J. Clinical pharmacological studies of concurrent infusion of 5-fluorouracil and thymidine in treatment of colorectal carcinomas. *Cancer Res.*, *42*: 2930–2937, 1982.
14. Anderson, L. W., Parker, R. J., Collins, J. M., Ahlgren, J. D., Wilkinson, D., Strong, J. M. Gas chromatographic-mass spectrometric method for routine monitoring of 5-fluorouracil in plasma of patients receiving low-level protracted infusions. *J. Chromatog.*, *581*: 195–201, 1992.
15. Amin, G., Shahinian, H., Miller, D., Vukelja, S., Zhang, R., Lu, Z., Diasio, R. B. Severe neurotoxicity following 5-fluorouracil (FUra) chemotherapy in patients with dihydropyrimidine dehydrogenase (DPD) deficiency. *Proc. Am. Soc. Clin. Oncol.*, *14*: 169, 1995.
16. Tuchman, M., Stoekeler, J. S., Kiang, D. T., O'Dea, R. F., Ramnaraine, M. L., and Mirkin, B. L. Familial pyrimidinemia and pyriminuria associated with severe fluorouracil toxicity. *N. Engl. J. Med.*, *313*: 245–249, 1985.
17. Fleming, R. A., Milano, G. A., Gaspard, M. H., Bargnoux, P. J., Thyss, A., Plagne, R., Renée, N., Schneider, M., and Demard, F. Dihydropyrimidine dehydrogenase activity in cancer patients. *Eur. J. Cancer*, *29A*: 740–744, 1993.
18. Van Groeningen, C. J., Peters, G. J., and Pinedo, H. M. Reversal of 5-fluorouracil-induced toxicity by oral administration of uridine. *Ann. Oncol.*, *4*: 317–320, 1993.
19. Grem, J. L., King, S. A., Sorensen, J. M., and Christian, M. C. Clinical use of thymidine as a rescue agent from methotrexate toxicity. *Invest. New Drugs*, *9*: 281–290, 1991.
20. Koenig, H., and Patel, A. Biochemical basis for fluorouracil neurotoxicity: the role of Krebs cycle inhibition by fluoroacetate. *Arch. Neurol.*, *23*: 155–160, 1970.