

Löffler's Endomyocardial Fibrosis With Eosinophilia in Association With Acute Lymphoblastic Leukemia

By P. M. Blatt, G. Rothstein, H. L. Miller, and W. J. Cathey

The association of eosinophilia and Löffler's endomyocardial fibrosis with acute lymphoblastic leukemia in a 9-yr-old boy is reported. During the illness, there were three leukemic relapses, each preceded by eosinophilia which subsided upon induc-

tion of remission. It is suggested that the eosinophilia in this case was not "eosinophilic leukemia," but more likely a non-neoplastic response to an antigenic stimulus from the leukemic process.

THE TERM eosinophilic leukemia has been applied broadly to a group of disorders associated with circulating eosinophilia,¹ and the association of this syndrome with cardiomegaly, congestive failure, and Löffler's endomyocardial fibrosis is now well recognized.^{2,3} Opinion has not been uniform that this syndrome is indeed a form of leukemia. In fact, there has been constant controversy and confusion over this issue since "eosinophilic leukemia" was first described 60 yr ago.⁴

The purpose of this report is to describe a boy with typical acute lymphoblastic leukemia and associated eosinophilia and endomyocardial fibrosis. Because the leukemia was of lymphoid origin and because eosinophilia preceded each leukemic relapse, it is suggested that the eosinophilia was reactive and not neoplastic.

CASE HISTORY

Onset of Disease

This 9-yr-old boy was in good health until April 1969, at which time he developed fever and diffuse abdominal pain. The physical findings included sternal tenderness, three firm movable cervical lymph nodes (1.5 × 1.5 cm), raised erythematous skin lesions over the inner thighs and buttocks, and a spleen which was palpable 2 cm below the costal margin. The volume of packed red cells (VPRC) was 43.5 ml/100 ml. The total leukocyte count was 17,300/cu mm with an eosinophil count of 2076/cu mm (Fig. 1). The platelet count was 149,000/cu mm.

The eosinophils in the blood usually contained a bilobed nucleus. There were frequent cytoplasmic vacuoles and large refractile eosinophilic granules. The cells did not contain alkaline phosphatase or chloroacetate esterase, and the peroxidase activity was cyanide resistant.⁵ Electron-microscopic examination revealed typical eosinophil granules. The remainder of the leukocytes consisted of normal neutrophils, lymphocytes, and monocytes. No blast cells, promyelocytes, or myelocytes were present. The bone marrow was hypercellular with 60% eosinophils and 15% lymphoblasts. The blast cells were peroxidase negative and were "block positive" with the periodic acid-Schiff (PAS) stain. Chromosomal studies revealed extra chromosomes in groups C and G. A cervical lymph node was infiltrated with blasts and only an occasional eosinophil. A skin biopsy showed perivascular lymphoid cells and infiltration of the dermis by eosinophils.

From the Departments of Medicine and Pathology, University of Utah College of Medicine, Salt Lake City, Utah 84132.

Submitted January 7, 1974; accepted April 18, 1974.

Supported by NIH Research Grant AM-04495 and NIH Graduate Training Grant 2A-5098.

Dr. Rothstein is an Investigator of the Howard Hughes Medical Institute.

Address for reprint requests: G. Rothstein, M.D., University Hospital, 50 N. Medical Dr., Salt Lake City, Utah 84132.

© 1974 by Grune & Stratton, Inc.

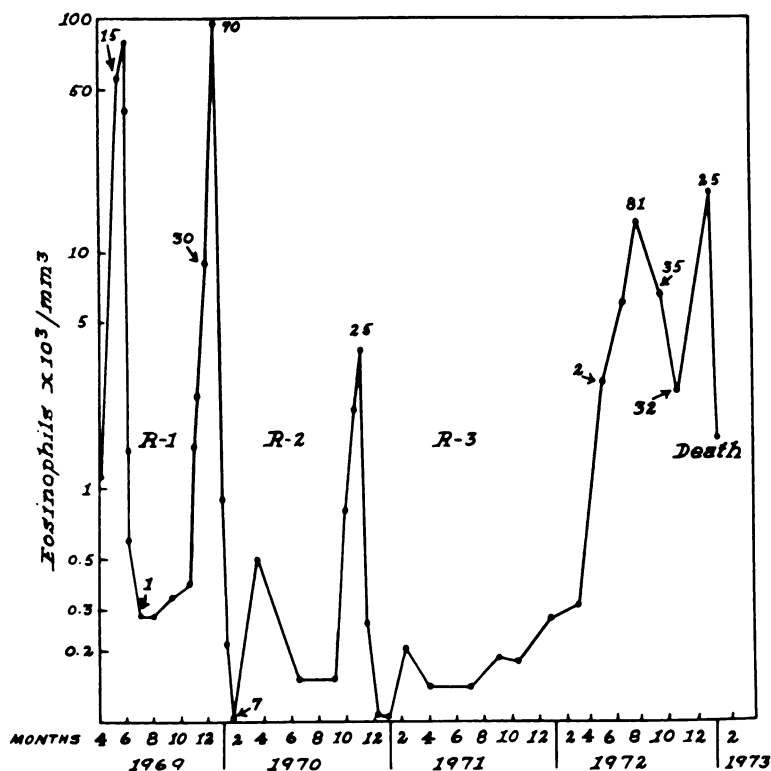


Fig. 1. Circulating eosinophils during the course of the disease. The numbers refer to the percentage of bone marrow lymphoblasts at the time indicated by the arrow. R refers to the first, second, and third drug-induced remissions. A logarithmic scale has been used on the ordinate.

On June 2 the patient was critically ill with high fever, severe abdominal pain, nausea, vomiting, arthralgia, congestive heart failure, and mental confusion. New physical findings included tachycardia (110-120/min), a II/VI systolic ejection murmur along the left sternal border, and bilateral extensor plantar reflexes. The VPRC was 32 ml/100 ml; eosinophils, 80,000/cu mm; platelets 165,000/cu mm. No blasts, promyelocytes, or myelocytes were seen in the blood. The chest film now revealed small bilateral pleural effusions and cardiomegaly. Left axis deviation with right bundle branch block was found in the electrocardiogram, consistent with a diagnosis of Löffler's endomyocarditis.⁶ Spinal fluid and brain scan were normal. An electroencephalogram was consistent with a metabolic encephalopathy.

A diagnosis of acute lymphoblastic leukemia was made, and therapy with corticosteroids (initially 100 mg hydrocortisone intravenously every 6 hr, then 80 mg prednisone/day orally) was begun on June 4, 1969. By June 9, the eosinophil count had decreased to 590/cu mm. Complete clinical and hematologic remission of the leukemia ensued, and all physical abnormalities reverted to normal except for the systolic murmur and exertional tachycardia. Prednisone was discontinued on October 21.

First Relapse

On November 21, 1969 the eosinophil count had increased to 8960/cu mm, and the bone marrow contained 30% lymphoblasts. By December 15 the skin lesions reappeared, the eosinophil count reached 96,000/cu mm, 560 lymphoblasts/cu mm were present in the blood, and the bone marrow contained 70% lymphoblasts. A second complete hematologic remission was induced with

prednisone and vincristine and maintained with 12.5 mg of methotrexate orally twice weekly. During the remission the eosinophil count was less than 215/cu mm.

Second Relapse

In October 1970 the eosinophil count increased to 3168/cu mm, skin lesions reappeared, and leukemic relapse was apparent in the blood and marrow. A third complete clinical and hematologic remission was induced with prednisone and vincristine and maintained with 6-mercaptopurine, 75 mg/day. Coincident with the remission, the eosinophils again returned to normal.

Third Relapse

On May 12, 1972 the eosinophil count had increased to 2700/cu mm. At this time the bone marrow contained 1.6% lymphoblasts and 10% eosinophils. By July 21, 1972 the eosinophils were 6200/cu mm, the bone marrow contained 81% lymphoblasts and 10% eosinophils, and the skin rash reappeared.

In spite of various treatment programs including (1) prednisone and vincristine, (2) daunomycin and prednisone, (3) cytosine arabinoside and thioguanine, and (4) cyclophosphamide, a remission could not be induced, and eosinophilia persisted. The course was complicated by *Pneumocystis carinii* pneumonia which was treated successfully with pentamidine. Other features were CNS leukemia, recurrent upper gastrointestinal tract bleeding secondary to stress ulcers, high fever (104°F), migratory thrombophlebitis, congestive heart failure, and persistent tachycardia. During a period of pancytopenia, mucous membrane ulcerations, and gastrointestinal bleeding, the patient died on January 11, 1973, 46 mo after the onset of the illness.

AUTOPSY

The bone marrow was hypocellular, edematous, and diffusely hemorrhagic. The cell population comprised a few immature myeloid cells, as well as blastlike lymphocytoid cells. The lymph nodes were moderately enlarged and contained plasma cells, lymphocytoid cells similar to those found in the bone marrow, and proliferating sinus reticular cells. The spleen weighed 150 g, and the red pulp contained atypical lymphocytoid cells, plasma cells, and large numbers of eosinophils. The liver weighed 1450 g and except for a mild portal infiltration with lymphocytes was microscopically normal. There was diffuse pneumonitis consisting of interstitial and alveolar accumulations of large pigmented phagocytic cells, swollen desquamated alveolar lining cells, eosinophils, and lymphocytes, the latter being particularly prominent around small blood vessels. Some alveolar spaces contained cell debris enmeshed in fibrin. No pneumocystis organisms were found. The heart weighed 210 g. The lateral and apical left ventricular endocardium was distorted and thickened by confluent plaques of pale fibrous tissue. Small mural thrombi filled some of the intertrabecular spaces. The underlying myocardium was focally fibrotic and thinned. The coronary arteries were grossly normal. Microscopically there was a complex lesion comprising fresh and healing zones of hemorrhagic infarctlike necrosis, irregular scars, and fresh and organizing thrombi in veins and endocardial recesses. The lesions lay largely within the inner third of the myocardium. Eosinophils were present but not in large numbers. A section taken from the area of the S-A node showed similar changes. Necrotizing lesions were found in the mucosae of the ileum and colon. Sections of brain showed a mild infiltration of the arachnoid with atypical lymphocytoid cells resembling those present in bone marrow.

DISCUSSION

The presence of a syndrome consisting of eosinophilia, cardiac and pulmonary disease, transient neurologic abnormalities, and hepatosplenomegaly raises the question as to whether the eosinophilia is of neoplastic (eosinophilic leukemia) or of nonneoplastic origin (reactive eosinophilia).

In the present report a hypereosinophilic syndrome occurred in conjunction with acute leukemia, but the blast cell origin and temporal course suggest a non-neoplastic origin of the eosinophils.

The Leukemic Cell Line

Based upon currently accepted concepts of cell phylogeny, the eosinophil is derived from the myeloblast and not the lymphoblast.⁷ In the present report, the leukemic blast cells had the following characteristics: (1) morphologic appearance of lymphoblasts on Romanowsky stain and (2) PAS positivity. Furthermore, the age of the patient and the response of the leukemia to chemotherapy were most characteristic of lymphoblastic leukemia. These features confirm the diagnosis of lymphoblastic leukemia. Thus, it seems reasonable to argue that the patient's lymphoblastic leukemia cells were not the precursors of the eosinophils.

The Temporal Course

In the present case, eosinophilia preceded each of three relapses of leukemia (Fig. 1). Then, when remission was induced, the eosinophilia disappeared. This course is consistent with the hypothesis that the leukemic blasts may somehow have stimulated a reactive eosinophilia of non-neoplastic origin. Basten and Beeson⁸ have studied the eosinophilia in rats in response to *Trichinella spiralis* nematodes. They were able to show that thoracic duct lymphocytes from these sensitized rats produced a humoral eosinophilia-inducing factor.⁹⁻¹¹ An attractive hypothesis is that in certain patients with leukemia, such as the one described in this report, a leukemic antigen may stimulate thymus-dependent lymphocytes to produce an eosinophilia-inducing factor analogous to that shown in the studies of Basten and Beeson. The resultant eosinophilia would be of non-neoplastic origin.

Evidence in support of a non-neoplastic origin for eosinophilia in association with lymphoblastic leukemia has also been reported by Spitzer and Garson.¹² In two cases of lymphoblastic leukemia and eosinophilia, cytogenetic evidence suggested that the eosinophilia was reactive and not a part of the leukemic process. Furthermore, in one case, eosinophilia heralded leukemic relapse, as in the present report.

From the present case and those of Spitzer and Garson, it can be seen that in acute lymphoblastic leukemia, a "leukemoid" non-neoplastic eosinophilia may mimic an eosinophilic leukemia. Indeed other authors have challenged the very existence of eosinophilic leukemia.^{13,14} Hardy and Anderson¹³ have proposed that simple infiltration of eosinophils into nonhemeric tissues is not a reliable sign of neoplasia, as this occurs in obviously non-neoplastic eosinophilias. They also point out that even when eosinophilia was found in chronic myelocytic leukemia, the presence of a Philadelphia chromosome was not clear

evidence of autonomous (neoplastic) eosinophil production. Other authors¹ have accepted persistent eosinophilia, eosinophil immaturity, eosinophil infiltration into nonhemic tissues, and the presence of a Philadelphia chromosome¹⁵ as sufficient evidence for the existence of eosinophilic leukemia as a disease entity. Thus, it can be seen that the concept of eosinophilic leukemia is still a matter of controversy. Perhaps neoplastic eosinophilia does not depend upon humoral factors, but reactive eosinophilia does. If so, a readily available assay for the eosinophilia-inducing factor of Basten and Beeson could be used to resolve the question of eosinophilic leukemia as a disease.

REFERENCES

1. Benvenisti DS, Ultmann JE: Eosinophilic leukemia. Report of five cases and review of literature. *Ann Intern Med* 71:731, 1969
2. Roberts WC, Buja LM, Ferrans VJ: Löffler's fibroplastic parietal endocarditis, eosinophilic leukemia, and Davies' endomyocardial fibrosis: the same disease at different stages? *Pathol Microbiol* 35:90, 1970
3. Roberts WC, Liegler DG, Carbone PP: Endomyocardial disease and eosinophilia: a clinical and pathologic spectrum. *Am J Med* 46:28, 1969
4. Stillman RG: A case of myeloid leukemia with predominance of eosinophil cells. *M Rec* 81:594, 1912
5. Yam LT, Li CY, Necheles TF, Katayama I: Pseudoeosinophilia, eosinophilic endocarditis, and eosinophilic leukemia. *Am J Med* 53:193, 1972
6. Raizner AE, Silverman ME, Waters WC: Conduction disturbances and pacemaker failure in Löffler's endomyocarditis. *Am J Med* 53:343, 1972
7. Wintrobe MM: *Clinical Hematology* (ed 6). Philadelphia, Lea & Febiger, 1967
8. Basten A, Boyer MH, Beeson PB: Mechanism of eosinophilia. I. Factors affecting the eosinophil response of rats to *Trichinella spiralis*. *J Exp Med* 131:1271, 1970
9. Basten A, Beeson PB: Mechanism of eosinophilia. II. Role of the lymphocyte. *J Exp Med* 131:1288, 1970
10. Boyer MH, Basten A, Beeson PB: Mechanism of eosinophilia by agents known to modify the immune response. *Blood* 36:458, 1970
11. Walls RS, Baston A, Leuchars E, Davies AJS: Mechanisms for eosinophilic and neutrophilic leukocytosis. *Br Med J* 3:157, 1971
12. Spitzer G, Garson OM: Lymphoblastic leukemia with marked eosinophilia: A report of two cases. *Blood* 42:377, 1973
13. Hardy WR, Anderson RE: The hyper-eosinophilic syndromes. *Ann Intern Med* 68:1220, 1968
14. Odeberg B: Eosinophilic leukemia and disseminated eosinophilic collagen disease: a disease entity? *Acta Med Scand* 177:129, 1965
15. Gruenwald H, Kiossoglou KA, Mitus W, Dameshek W: Philadelphia chromosome in eosinophilic leukemia. *Am J Med* 39:1003, 1965