

Early B-Cell Differentiation in Merkel Cell Carcinomas: Clues to Cellular Ancestry

Axel zur Hausen¹, Dorit Rennspiess¹, Veronique Winnepeninckx¹, Ernst-Jan Speel¹, and Anna Kordelia Kurz²

Abstract

Merkel cell carcinoma (MCC) is a highly malignant neuroendocrine nonmelanoma skin cancer, which is associated with the Merkel cell polyoma virus (MCPyV). Recently, expression of the terminal deoxynucleotidyl transferase (TdT) and the paired box gene 5 (PAX 5) has been consistently reported in the majority of MCCs. We tested 21 MCCs for the expression of MCPyV, TdT, PAX5, IgG, IgM, IgA, kappa, and lambda by immunohistochemistry and assessed IgH and Igk rearrangement in all 21 MCCs. All of the MCCs revealed specific expression of PAX5 and 72.8% of the MCCs expressed TdT. In addition, most of the MCCs revealed specific expression of one or more Ig subclasses and kappa or lambda. One MCC did reveal monoclonal IgH and Igk rearrangement next to two other MCCs showing Igk rearrangement. As coexpression of TdT and PAX5 under physiologic circumstances is restricted to pro/pre- and pre-B cells we propose, on the basis of our results, that the cell of origin of MCCs is a pro/pre- or pre-B cell rather than the postmitotic Merkel cells. MCPyV infection and transformation of pro-/pre-B cells are likely to induce the expression of simple cytokeratins as has been shown for SV40 in other nonepithelial cells. This model of cellular ancestry of MCCs might impact therapy and possibly helps to understand why approximately 20% of MCCs are MCPyV-negative. *Cancer Res*; 73(16); 4982–7. ©2013 AACR.

Introduction

Merkel cell carcinoma (MCC) is a highly malignant non-melanoma skin cancer characterized by the expression of neuroendocrine markers, that is, CD56, chromogranin A, and synaptophysin and a typical dot-like perinuclear expression of cytokeratin 20 (CK20; ref. 1). MCC occurs mainly in elderly or immunosuppressed patients and its clinical prognosis is very poor (1). The recent finding of the merkel cell polyomavirus (MCPyV) in MCCs has substantially contributed to the understanding of the etiopathogenesis of this malignancy (2). Since 2008, MCPyV DNA has been detected in approximately 80% of more than 1000 MCCs yet tested. MCPyV has been shown to be integrated in the MCC genomes by diverse molecular techniques (2–6).

MCC was first introduced by Toker in 1972 as a trabecular carcinoma of the skin (7). Dense core granules were identified in 3 MCCs, which was confirmed by subsequent immunohistochemical studies testing neuroendocrine and simple epithelium markers (8–13). On the basis of the similarity of the expression patterns, MCC is considered to be most closely

related to merkel cells, which are located at the epidermal dermal junction and are supposed to function as nociceptive receptors of the skin. However, serious doubts on this theory have been postulated—also based on histomorphologic growth patterns—and an alternative proposal suggesting a role for a pluripotent stem cell in the dermis as cells of origin of MCCs still remains to be proven (14).

In the past years, evidence is accumulating that MCCs express early B-cell lineage markers (15–22). For example, specific expression of terminal deoxynucleotidyl transferase (TdT) as assessed by immunohistochemistry, which normally is restricted to thymocytes and precursors of lymphocytes in the bone marrow, has been reported in 72.5% (95 of 131) of MCCs (15–19). In addition, a number of studies have reported immunostaining of the B-cell-specific activating protein (BSAP; syn: PAX5) in 83.6% (102 of 122) of MCCs (16, 19–22). Coexpression of TdT and BSAP under physiologic circumstances is restricted to pro/pre-B cells and pre-B cells. Pre-B cells exhibit immunoglobulins and in addition rearrangement of the IgH and Igk locus. Here, we examined 21 MCCs for the expression of TdT, PAX 5 (BSAP), IgG, IgM, IgA, kappa, and lambda by immunohistochemistry. In addition, clonal rearrangement of the IgH and Igk locus was tested in all MCCs to find further evidence for our assumption that MCCs possibly derive from pro/pre- or pre-B cells.

Materials and Methods

Patients and tissues

Formalin-fixed and paraffin-embedded (FFPE) tissues of resection specimens of 21 MCCs were included

Authors' Affiliations: ¹Department of Pathology, GROW-School for Oncology and Developmental Biology, Maastricht University Medical Centre, Maastricht, The Netherlands; and ²Department of Internal Medicine IV, University Hospital Aachen, Aachen, Germany

Corresponding Author: Axel zur Hausen, Department of Pathology, Maastricht University Medical Center, P. Debyelaan 25, P.O. Box 5800, Maastricht 6202 AZ, The Netherlands. Phone: 31-433874634; Fax: 31-433876613; E-mail: axel.zurhausen@mumc.nl

doi: 10.1158/0008-5472.CAN-13-0616

©2013 American Association for Cancer Research.

Downloaded from <http://aacrjournals.org/cancerres/article-pdf/73/16/4982/2868659/4982.pdf> by guest on 14 December 2024

in this study. All respective tumors had been excised for diagnostic and therapeutic reasons. Eighteen specimens were obtained from the Maastricht Pathology Tissue Collection. All use of tissue and patient data was in agreement with the Dutch Code of Conduct for Observational Research with Personal Data (2004) and Tissue (2001, www.fmwv.nl). Three MCCs were collected at the Institute of Pathology, University Hospital Freiburg, Freiburg, Germany, which had been previously tested for the presence of MCPyV (23).

MCC diagnoses were previously defined by histology and immunohistochemistry for CK20, CD56, synaptophysin, and chromogranin A in routine diagnostic. The histology of all MCCs included in this study has been reviewed by 2 expert dermatopathologists (V. Winnepenninckx and A. zur Hausen). The patient group consisted of 9 men (age: range, 63–93 years; mean, 78.3 years) and 12 women (age: range, 60–93 years; mean, 76.2 years). Only MCC tissues were included in this study of patients with no history of other hematologic oncologic disease. Further details of clinicopathologic parameters are included in Table 1. Serial sections of all specimens were used for hematoxylin and eosin (H&E) staining, immunohistochemistry, and DNA isolation.

Immunohistochemistry

The following antibodies and dilutions were used in this study: anti-MCPyV (clone: CM2B4) dilution 1:50, Santa Cruz, Inc.; anti-TdT "Ready to use Antibody"; anti-PAX5 (clone: DAK-Pax5), "Ready to use Antibody"; anti-IgA dilution 1:20,000; anti-IgG dilution 1:20,000; anti-IgM dilution 1:2,000; anti-kappa dilution 1:40,000; anti-lambda dilution 1:40,000, all DAKO. All immunohistochemical stainings were conducted on a Dako Autostainer Link 48 using the EnVision FLEX Visualization Kit K8008 DAKO according to standard diagnostic routine protocols and manufacturers' instructions.

DNA extraction and immunoglobulin light chain restriction

First, an H&E stain of the selected specimens was reviewed (V. Winnepenninckx and A. zur Hausen). Five 10 µm-thick consecutive sections were cut from each paraffin block of formalin-fixed tissue and, if needed, microdissection was conducted. After deparaffinization, the tissues were lysed by proteinase K overnight until complete tissue lysis, and DNA was extracted using QUIAmp mini kit (Qiagen) or Maxwell 16 FFPE Plus LEV DNA isolation kit (AS1135), Promega. Purified DNA was measured in a spectrophotometer (Nano-drop, 2000;

Table 1. Clinicopathologic, immunohistochemical, and molecular pathology data of 21 MCCs

	Pat ID	Gender	Age, y	Histology	Immunohistochemistry								Molecular pathology		
					MCPyV	TdT	PAX 5 (BSAP)		IgA	IgG	IgM	Ig-kappa	Ig-lambda	SCS ladder	IgH
TDT > PAX5	1-7	M	63	Int.	+	+++	+	20%	50%	<5%	-	50%	y	p	p
	2-9	M	86	Int.	+++	+++	+	-	5%	-	-	15%	n	n.i.	n.i.
	3-14	F	93	Int.	+++	+++	++	30%	30%	-	40%	90%	y	p	p
TDT = PAX5	4-20	F	75	Int.	+++	+	+	50%	10%	-	20%	20%	y	p	p
	5-13	M	69	Int.	+++	++	++	<5%	-	-	-	-	y	p	p
	6-8	M	84	s.c.	-	+++	+++	-	-	-	-	-	y	p	p
	7-23	F	66	Int.	+++	+++	+++	-	-	-	-	-	y	p	p
	8-26	F	83	Int.	+++	+++	+++	30%	-	-	-	-	y	p	p
TDT < PAX5	9-10	F	65	Int.	+	-	+	-	-	5%	-	-	y	p	p
	10-25	F	91	Int.	+++	-	+	-	-	-	-	-	y	p	p
	11-17	F	74	Int.	+++	+	++	10%	80%	-	30%	80%	y	n.i.	p
	12-21	F	76	Int.	+++	+	++	30%	-	-	-	5%	y	p	p
	13-6	F	85	s.c.	+++	+	++	-	-	-	-	-	y	p	p
	14-2	M	92	s.c.	-	-	++	-	-	-	-	-	y	p	p
	15-18	M	93	Int.	-	-	+++	-	-	-	-	-	y	n.i.	n.i.
	16-27	F	76	Int.	++	-	+++	60%	<5%	<5%	<5%	<5%	n	n.i.	n.i.
	18-15	F	60	Int.	+	+	+++	<5%	<5%	20%	20%	>10%	y	p	m
	17-5	M	73	Int.	++	+	+++	-	15%	-	-	10%	n	n.i.	n.i.
	19-16	F	70	Int.	+++	+	+++	-	-	30%	30%	80%	y	p	p
20-38	M	74	Int.	+++	+	+++	-	60%	-	-	>50%	y	m	m*	
21-11	M	71	Int.	+++	++	+++	+++	100%	50%	30%	80%	y	p	m	

NOTE: Expression of Igs and kappa and lambda is given as percentage tumor cells expressing respective Igs or kappa and lambda. Abbreviations: -, negative; +, weak expression; ++, moderate expression; +++, strong expression. Abbreviations: BSAP, B-cell-specific activating protein; F, female; int., intermediate; M, male; m, monoclonal; m*, vk/intron k deleting element; n, not sufficient DNA quality; n.i., not informative; p, polyclonal; s.c., small cell; PAX5, paired box gene 5; SCS ladder, specimen control size ladder indicating whether DNA quality is sufficient in order to interpret results; y, sufficient DNA quality.

Downloaded from http://aacrjournals.org/cancerres/article-pdf/73/16/4982/2868659/4982.pdf by guest on 14 December 2024

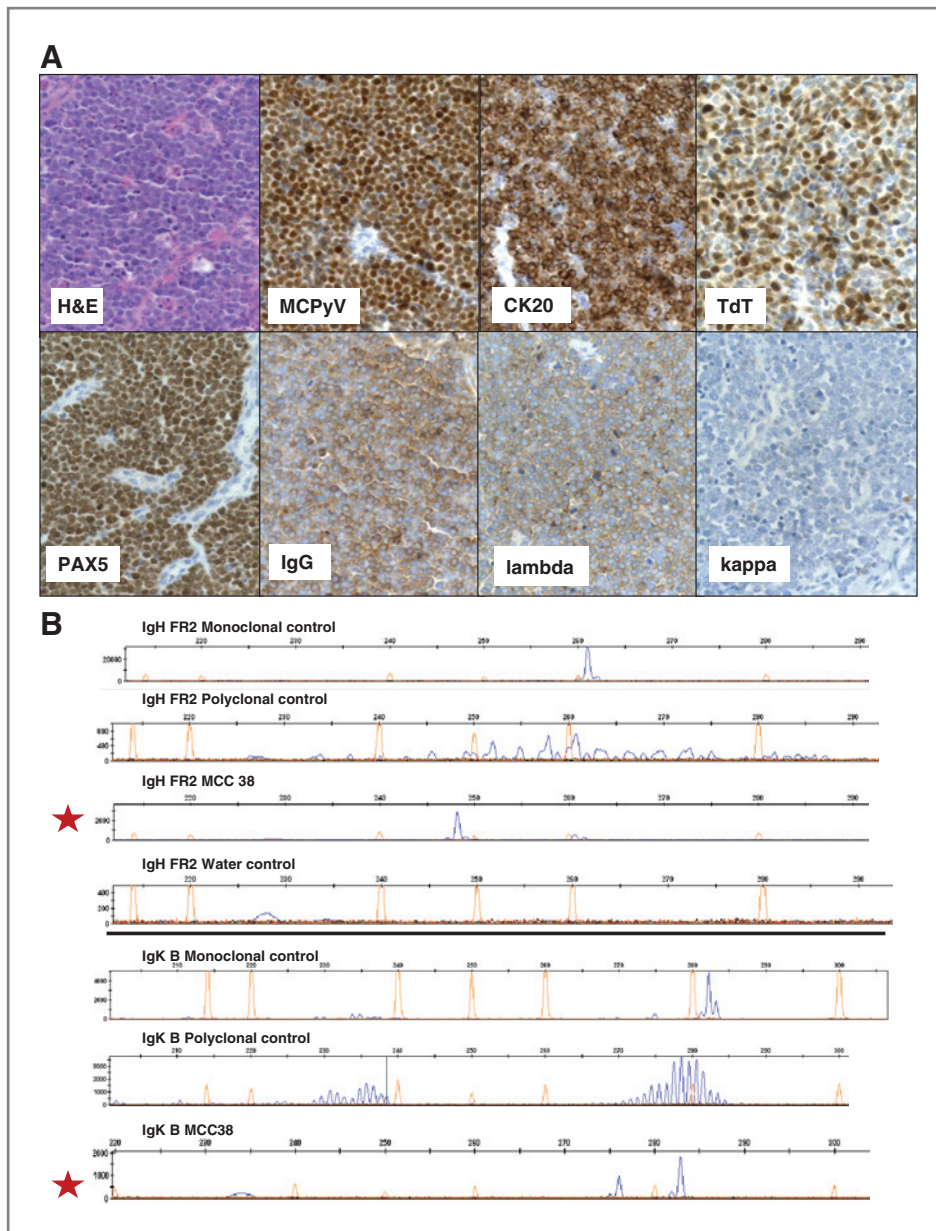


Figure 1. Histomorphology, immunohistochemistry, and IgH and Igk rearrangement of MCC 38. A, H&E showing an intermediate type of MCC; MCPyV, merkel cell polyomavirus as determined by CM2B4 antibody directed against LTag of MCPyV; CK20, cytokeratin 20 showing the typical perinuclear dot-like expression pattern as reported in MCCs; specific nuclear TdT expression; specific nuclear PAX5 expression in all MCC cells; specific membranous IgG and kappa expression in contrast to no expression of lambda according to the vk/intron k-deleting element as tested by Igk rearrangement (Table 1). B, assessment of IgH FR2 (top) and Igk B (bottom) rearrangements reveals B-cell clonality in MCC 38 (see also Table 1) as compared with the respective monoclonal and polyclonal controls. The red stars indicate the MCC38 either in IgH FR2 or in Igk B.

Thermo Scientific) and directly used for PCR. Detection of clonal immunoglobulin gene recombinations was conducted according to an established and validated protocol (24) in a routine diagnostic setting in the nationally accredited diagnostic molecular pathology laboratory of the Department of Pathology, Maastricht University Medical Center, Maastricht, the Netherlands.

Results

MCPyV, PAX5, and TdT expression in MCCs

The presence of MCPyV was assessed by the expression of the large T antigen (LTag) as tested by immunohistochemistry. Eighteen MCCs (85.7%) were tested positive for LTag expression. Of the 21 MCCs, 13 revealed very strong nuclear expression of the LTag, 2 moderate nuclear expression, and 3 weak

nuclear expression (Fig. 1; Table 1). In these MCPyV-positive cases, LTag expression was homogeneous and found in all tumor cells. Three MCCs were completely negative for LTag expression.

Specific nuclear expression of PAX5 was seen in all MCCs, of which 10 MCCs revealed strong PAX5 expression, 6 moderate, and 5 weak (Table 1).

Specific nuclear TdT expression was detected in 16 MCCs (76.2%), of which 6 were strongly, 2 moderately, and 8 weakly expressing TdT. Five MCCs were completely negative for TdT expression. Although no correlation was observed between PAX5, TdT, and LTag expression it is of interest that when PAX5 expression was high, TdT expression was low, and vice versa. MCCs could be grouped according to TdT and PAX5 expression (see Table 1): TdT high, PAX5 low expression, and

TdT expression equally to PAX5 expression. In addition, the third and also largest group of MCCs showed a lower TdT expression than PAX5 expression.

Expression of immunoglobulins and kappa and lambda in MCCs

Testing 21 MCCs for the expression of Igs by immunohistochemistry revealed that almost all MCCs did show Ig expression of one or more Ig subclasses to variable extent (Fig. 1A). In detail, 10 (47.6%) MCCs were expressing IgA, 10 (47.6%) MCCs were expressing IgG, 5 (23.8%) MCCs were tested positive for IgM expression to a varying degree. In addition, 7 (33.3%) MCCs revealed kappa and 12 (57.1%) MCCs revealed lambda expression. Expression was membranous or cytoplasmic and only strong expression intensity was scored as positive. The percentage of tumor cells expressing Ig or kappa or lambda did show marked diversity among the MCCs. Details are summarized in Table 1. Noteworthy, all of the MCPyV-negative MCC ($n = 3$) did not show expression of Ig or kappa or lambda.

Molecular testing of IgH and Igk rearrangement in MCCs

According to the specimen control size, ladder 18 of the 21 MCCs revealed sufficient DNA quality to proceed with molecular testing (Table 1). Analysis of IgH and Igk rearrangements in MCCs according to van Dongen and colleagues (24) identified a monoclonal IgH locus rearrangement combined with a monoclonal Igk rearrangement in one case (case no. 38–20, see Fig. 1B, Table 1). Furthermore, light chain restriction was found in 2 additional cases (case no. 15–18 and 21–11; Table 1). All MCCs revealing molecular rearrangements were restricted to the group of MCCs with low TdT and high PAX5 expression.

Discussion

At present, profound doubts are challenging the concept that the postmitotic merkel cells are the cells of origin of MCCs, which had been proposed in the early 1980s (8–13, 25, 26). The recently discovered MCPyV has been shown to play an important role in the etiopathogenesis of the majority of MCCs. Of interest, MCPyV cannot be detected in non-neoplastic merkel cells adjacent to MCPyV-positive MCCs (26). On the basis of MCC mouse models, it has been speculated that the cell of origin of MCC derives from epidermal stem cells or other primitive totipotent stem cells (reviewed in refs. 25, 26).

However, none of the previous reports on the cellular origin of MCCs took into account that in a significant number of MCCs, TdT and PAX5 are expressed consistently, that is, in 72.5% and 83.6% of cases, respectively. Here, we assessed TdT and PAX5 expression in 21 MCCs and indeed were able to confirm these previous results. Specific nuclear expression of TdT was found in 16 of 21 MCCs (76.2%) and all of the 21 MCCs revealed specific nuclear PAX5 expression. Under physiologic conditions, coexpression of TdT and PAX5 is restricted to pro/pre- and pre-B cells. In addition to TdT and PAX5 expression, pro/pre- and pre-B cells are characterized by the expression of immunoglobulins (Igs) and VJH clonal rearrangements.

Taken together, the obtained data on TdT and PAX5 expression in MCCs might either reflect an epiphenomenon in the course of malignant transformation or be of meaningful sig-

nificance possibly pointing to the cellular ancestry of MCC. To assess further pro/pre- and pre-B cells differentiation in MCCs, we examined the expression of immunoglobulins (IgA, IgG, and IgM), kappa and lambda and in addition B-cell clonality in MCC tissues.

Indeed, we were able to show strong expression of immunoglobulins or kappa/lambda in a significant number of MCCs. Only strong membranous or cytoplasmic Ig and/or kappa/lambda staining of the MCC cells were considered as positive expression. Although this is the first report to show Ig expression by immunohistochemistry in FFPE tissues of MCCs, it is not the first report on Igs and kappa/lambda expression in MCCs on the transcriptional level. Recent cDNA microarray analyses have shown that the expression of certain Igs is strongly upregulated. Comparing the transcriptional expression profiles of MCC cell lines versus that of cell lines of small cell lung cancer, Van Gele and colleagues have shown a 100-fold increase in membrane-bound and secreted immunoglobulin gamma heavy chain in MCC cells (27). In addition, Paulson and colleagues identified transcriptional expression of the IgJ polypeptide and Ig kappa constant as genes most highly upregulated in good prognosis tumors (28). Thus, the immunohistochemical expression data of Ig and kappa/lambda are in line with previous observations on the transcriptional level.

Although only a minority of the MCCs in this study did show B-cell clonality, the finding of B-cell clonality in 3 MCCs (14.3%) strongly points to pro/pre- or pre B-cells as the cells of origin of MCCs.

B-lymphocyte development is a timely regulated specific process controlled by protein products of functionally rearranged Ig heavy (H) and light (L) chain genes. This process of Ig rearrangement begins in pro-B cells at the IgH locus (29).

On the basis of our results, we propose that pro/pre- or pre-B cells, which either or not have yet started the process of Ig rearrangement turn into a tumor cell as the starting point of MCCs (Fig. 2). Although other transforming events may be considered, MCPyV is the main suspect to transform pro/pre- and pre-B cells. More than 80% of MCCs harbor the recently discovered Merkel cell polyomavirus in its integrated form and in addition reveal oncogenic mutations in the LTA of MCPyV. It is likely that MCPyV transformation leads to spontaneous loss of cytokeratin and neuroendocrine marker gene expression control and thus the expression of simple cytokeratins and neuroendocrine markers is induced in pro/pre- and pre-B cells. At least, the induction of cytokeratin expression in cytokeratin-negative cells upon infection with another polyomavirus, that is, SV40, has been shown previously (30). Phylogenetically, MCPyV is closely related to SV40 and thus shares the same set of transformation relevant genes. Moreover, it has been shown that, for example, JC polyomaviruses preferentially infect stem cells or progenitor cells (reviewed in ref. 25). The finding of Ig and kappa and lambda expression in MCCs on the protein level, as has been described in 2 previous independent cDNA microarray studies on the transcriptional level strongly support our model. Clonal IgH and Igk rearrangement in MCCs as found in our study in addition highly substantiates our model. The relative low number of 3 MCCs revealing B-cell clonality might indicate that the transforming event, that is,

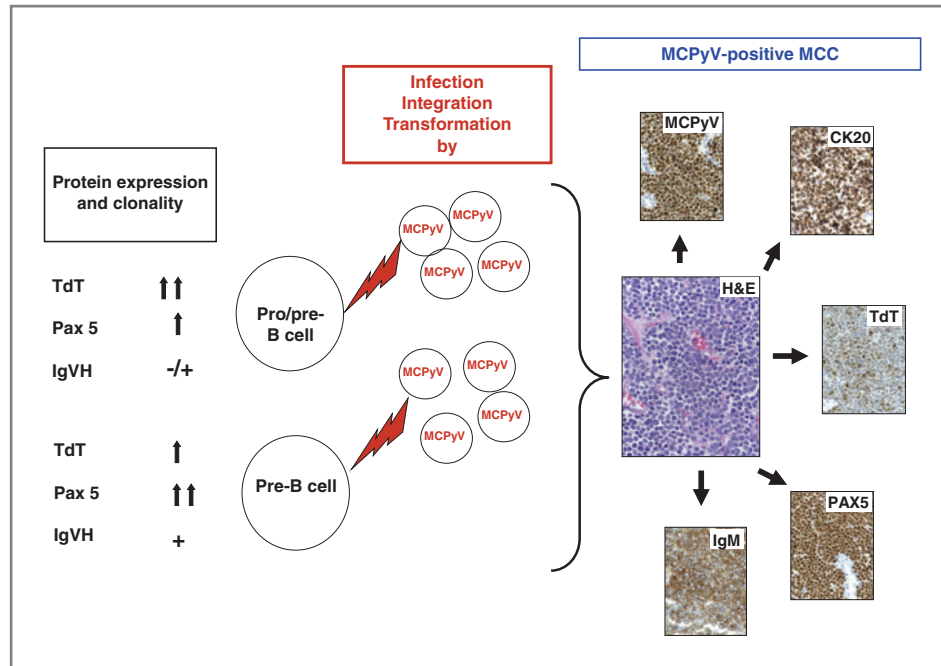


Figure 2. Proposed model of cellular ancestry and etiopathogenesis of MCCs. MCPyV infects, integrates, and transforms pro/pre- or pre-B cells inducing the expression of simple cytokeratins, that is, cytokeratin 20 (CK20) according to the previously reported induction of cytokeratins by SV40 in nonepithelial cells (30). The level of TdT and PAX 5 expression in the MCCs is likely to reflect the state of B-cell maturity (pro/pre- or pre-B cell) at the time point of MCPyV-infection. Right, the histology and immunohistochemistry of MCC 11 (Table 1). Double arrows in the left panel indicate strong expression, one arrow moderate expression.

MCPyV infection, of pro/pre- or pre- B cells occurs before the start of Ig rearrangement. The fact that all MCCs carrying IgH or Igk rearrangements are in the group of MCCs with lower TdT than PAX5 expression also supports our hypothesis. In addition, the striking histologic similarity of pro/pre- and pre-B cells and the intermediate type of MCCs further supports this hypothesis. The proposed model can also help to understand why there are MCPyV-positive and MCPyV-negative MCCs and why most MCCs reveal a lymphoma-like growth pattern in the skin and only a very small minority of MCCs being connected to the epidermis. MCCs are almost always hematologically disseminated at the time of diagnosis. Identifying pro/pre- or pre-B cells as the cellular ancestors of MCCs is also expected to impact current treatment regimens of MCCs, which is of major significance in the context of the very poor prognosis for patients with MCCs after primary MCC diagnosis. Next to this, it might also influence the current understanding of the

cellular ancestry of other neuroendocrine cancers such as small cell lung cancer in which to a lesser extent TdT and PAX5 expression has been observed (18, 19).

Disclosure of Potential Conflicts of Interest

No potential conflicts of interest were disclosed.

Authors' Contributions

Conception and design: A. zur Hausen, A.K. Kurz

Development of methodology: D. Rennspiess, E.-J.M. Speel

Acquisition of data (provided animals, acquired and managed patients, provided facilities, etc.): D. Rennspiess

Analysis and interpretation of data (e.g., statistical analysis, biostatistics, computational analysis): A. zur Hausen, D. Rennspiess, E.-J.M. Speel

Writing, review, and/or revision of the manuscript: A. zur Hausen, V. Winnepenninckx, E.-J.M. Speel, A.K. Kurz

Study supervision: A. zur Hausen

Received February 27, 2013; accepted March 29, 2013; published OnlineFirst April 10, 2013.

References

- Swann MH, Yoon J. Merkel cell carcinoma. *Semin Oncol* 2007;34:51–6.
- Feng H, Shuda M, Chang Y, Moore PS. Clonal integration of a polyomavirus in human Merkel cell carcinoma. *Science* 2008;319:1096–100.
- Sastre-Garau X, Peter M, Avril MF, Laude H, Couturier J, Rozenberg F, et al. Merkel cell carcinoma of the skin: pathological and molecular evidence for a causative role of MCV in oncogenesis. *J Pathol* 2009;218:48–56.
- Laude HC, Jonchère B, Maubec E, Carlotti A, Marinho E, Couturaud B, et al. Distinct merkel cell polyomavirus molecular features in tumour and non tumour specimens from patients with merkel cell carcinoma. *PLOS Pathog* 2010;6:e1001076.
- Hagg AM, Speel EJ, Pantulu ND, Pallasch C, Kurz AK, Kvasnicka HM, et al. Fluorescence in situ hybridization confirms the presence of Merkel cell polyomavirus in chronic lymphocytic leukemia cells. *Blood* 2011;117:5776–7.
- Duncavage EJ, Magrini V, Becker N, Armstrong JR, Demeter RT, Wylie T, et al. Hybrid capture and next-generation sequencing identify viral integration sites from formalin-fixed, paraffin-embedded tissue. *J Mol Diagn* 2011;13:325–33.
- Toker C. Trabecular carcinoma of the skin. *Arch Dermatol* 1972;105:107–10.
- Tang CK, Toker C. Trabecular carcinoma of the skin: an ultrastructural study. *Cancer* 1978;42:2311–21.
- Warner TF, Uno H, Hafez GR, Burgess J, Bolles C, Lloyd RV, et al. Merkel cells and Merkel cell tumors. Ultrastructure, immunocytochemistry and review of the literature. *Cancer* 1983;52:238–45.
- Wilson BS, Lloyd RV. Detection of chromogranin in neuroendocrine cells with a monoclonal antibody. *Am J Pathol* 1984;115:458–68.

11. Hartschuh W, Weihe E, Egner U. Chromogranin A in the mammalian Merkel cell: cellular and subcellular distribution. *J Invest Dermatol* 1989;93:641–8.
12. Moll R, Osborn M, Hartschuh W, Moll I, Mahrle G, Weber K. Variability of expression and arrangement of cytokeratin and neurofilaments in cutaneous neuroendocrine carcinomas (Merkel cell tumors): immunocytochemical and biochemical analysis of twelve cases. *Ultrastruct Pathol* 1986;10:473–95.
13. Moll R, Löwe A, Laufer J, Franke WW. Cytokeratin 20 in human carcinomas. A new histodiagnostic marker detected by monoclonal antibodies. *Am J Pathol* 1992;140:427–47.
14. McCardle TW, Sondak VK, Zager J, Messina JL. Merkel cell carcinoma: pathologic findings and prognostic factors. *Curr Probl Cancer* 2010;34:47–64.
15. Sur M, AlArdati H, Ross C, Alowami S. TdT expression in Merkel cell carcinoma: potential diagnostic pitfall with blastic hematological malignancies and expanded immunohistochemical analysis. *Mod Pathol* 2007;20:1113–20.
16. Buresh CJ, Oliyai BR, Miller RT. Reactivity with TdT in Merkel cell carcinoma: a potential diagnostic pitfall. *Am J Clin Pathol* 2008;129:894–8.
17. Bhatia K, Goedert JJ, Modali R, Preiss L, Ayers LW. Merkel cell carcinoma subgroups by Merkel cell polyomavirus DNA relative abundance and oncogene expression. *Int J Cancer* 2010;126:2240–6.
18. Sidiropoulos M, Hanna W, Raphael SJ, Ghorab Z. Expression of TdT in Merkel cell carcinoma and small cell lung carcinoma. *Am J Clin Pathol* 2011;135:831–8.
19. Kolhe R, Reid MD, Lee JR, Cohen C, Ramalingam P. Immunohistochemical expression of PAX5 and TdT by Merkel cell carcinoma and pulmonary small cell carcinoma: a potential diagnostic pitfall but useful discriminatory marker. *Int J Clin Exp Pathol* 2013;6:142–7.
20. Dong HY, Liu W, Cohen P, Mahle CE, Zhang W. B-cell specific activation protein encoded by the PAX-5 gene is commonly expressed in merkel cell carcinoma and small cell carcinomas. *Am J Surg Pathol* 2005;29:687–92.
21. Mhawech-Fauceglia P, Saxena R, Zhang S, Terracciano L, Sauter G, Chadhuri A, et al. Pax-5 immunoexpression in various types of benign and malignant tumours: a high-throughput tissue microarray analysis. *J Clin Pathol* 2007;60:709–14.
22. Agostinelli C, Sabattini E, Gjørret JO, Righi S, Rossi M, Mancini M, et al. Characterization of a new monoclonal antibody against PAX5/BASP in 1525 paraffin-embedded human and animal tissue samples. *Appl Immunohistochem Mol Morphol* 2010;18:561–72.
23. Kasseem A, Schöpflin A, Diaz C, Weyers W, Stickeler E, Werner M, et al. Frequent detection of Merkel cell polyomavirus in human Merkel cell carcinomas and identification of a unique deletion in the VP1 gene. *Cancer Res* 2008;68:5009–13.
24. Langerak AW, Groenen PJ, Brüggemann M, Beldjord K, Bellan C, Bonello L, et al. EuroClonality/BIMED-2 guidelines for interpretation and reporting of Ig/TCR clonality testing in suspected lymphoproliferations. *Leukemia* 2012;26:2159–71.
25. Calder KB, Smoller BR. New insights into merkel cell carcinoma. *Adv Anat Pathol* 2010;17:155–61.
26. Tilling T, Moll I. Which are the cells of origin in merkel cell carcinoma? *J Skin Cancer* 2012;2012:680410.
27. Van Gele M, Boyle GM, Cook AL, Vandesompele J, Boonefaes T, Rottiers P, et al. Gene-expression profiling reveals distinct expression patterns for Classic versus Variant Merkel cell phenotypes and new classifier genes to distinguish Merkel cell from small-cell lung carcinoma. *Oncogene* 2004;23:2732–42.
28. Paulson KG, Iyer JG, Tegeder AR, Thibodeau R, Schelter J, Koba S, et al. Transcriptome-wide studies of merkel cell carcinoma and validation of intratumoral CD8+ lymphocyte invasion as an independent predictor of survival. *J Clin Oncol* 2011;29:1539–46.
29. Lutz J, Heideman MR, Roth E, van den Berk P, Müller W, Raman C, et al. Pro-B cells sense productive immunoglobulin heavy chain rearrangement irrespective of polypeptide production. *Proc Natl Acad Sci U S A* 2011;108:10644–9.
30. Knapp AC, Franke WW. Spontaneous losses of control of cytokeratin gene expression in transformed, non-epithelial human cells occurring at different levels of regulation. *Cell* 1989;59:67–79.