

Acquired Storage Pool Disease in Platelets During Disseminated Intravascular Coagulation

By F. I. Pareti, A. Capitanio, and P. M. Mannucci

A patient with clinical and laboratory evidence of disseminated intravascular coagulation associated with deep-vein thrombosis and pulmonary embolism developed a qualitative platelet abnormality characterized by a defective release reaction. Second-phase aggregation induced by ADP and adrenaline was impaired, and reduced collagen-induced aggregation was accompanied by defective release of ADP and ATP. The decrease in total platelet ATP and ADP, the high ATP:ADP ratio in the presence of normal amounts

of metabolic adenine nucleotides, and the low content of serotonin associated with abnormal uptake and metabolism of the exogenous amine suggested that the defective platelet function was due to lack of the platelet organelles in which serotonin and nonmetabolic adenine nucleotides are normally stored. Acquired storage pool disease is likely to be related to exposure of circulating platelets to aggregating agents, with their degranulation occurring during disseminated intravascular coagulation.

DURING DISSEMINATED INTRAVASCULAR COAGULATION (DIC), circulating platelets are exposed to inducers of aggregation (such as thrombin and plasmin) which may trigger a release reaction in vivo. We report a case in which this situation is likely to have led to the development of an acquired defect of platelet function resembling storage pool disease. The latter is a congenital abnormality characterized by a defective platelet release reaction due to lack of the cytoplasmic organelles in which 5-hydroxytryptamine (5HT) and non-metabolic adenine nucleotides are stored.¹⁻³

MATERIALS AND METHODS

Aggregation in platelet-rich plasma (PRP), measurement of total and released ATP and ADP, determination of radioactive nucleotides, assay of 5HT and ¹⁴C-5HT uptake were carried out as previously described by Pareti et al.⁴ Prothrombin time, kaolin-partial thromboplastin time, thrombin time, fibrinogen assay, fibrinogen degradation products (FDP), and platelet counts were performed as described by Denson.⁵

CASE REPORT

F.R. (age 51, male) developed clinical signs of deep vein thrombosis (DVT) of the right leg 10 days after cholecystectomy. During surgery, blood loss had not been excessive, nor was there any history of easy bruising or prolonged bleeding after dental extraction or minor surgery. DVT was first treated at home with bed rest and elevation of the leg. Three days after the onset of symptoms, the patient was admitted to hospital because he developed sudden chest pain, acute breathlessness, hemoptysis, hypotension, and cyanosis. The chest x-ray showed a peripheral opacity in the lower lobe of the left lung; the electrocardiogram showed sinus tachycardia, a q wave and inverted T wave in lead III, and T wave inversion in the right precordial leads. There were also signs of a hemorrhagic tendency, characterized by gastrointestinal bleeding, generalized purpura, epistaxis, and prolonged oozing from venipuncture

From the Hemophilia and Thrombosis Center Angelo Bianchi Bonomi, International Training Center of the World Federation of Hemophilia, University of Milano, Milan Italy.

Submitted March 18, 1976; accepted June 2, 1976.

Address for reprint requests: F.I. Pareti, M.D., Via Pace, 15, 20122 Milano, Italy.

© 1976 by Grune & Stratton, Inc.

sites. Laboratory investigation showed a hemoglobin level of 10.1 g/dl, WBC 11.6×10^9 /liter, and platelet count 120×10^9 /liter. Prothrombin time was prolonged to 29 sec (normal values 14-16 sec); kaolin-partial thromboplastin time was 56 sec (normal values: 40-50 sec), thrombin time 25 sec (normal values: 14-17 sec) and plasma fibrinogen 0.9 g/liter. The coagulation studies and the measurement of increased levels of serum FDP ($64 \mu\text{g}/\text{ml}$) led to a diagnosis of disseminated intravascular coagulation. After sampling additional blood for platelet studies, treatment was begun with intravenous heparin, given at a loading dose of 10,000 I.U. followed by the continuous infusion of 1200 I.U./hr. During the next few hours, cardiopulmonary conditions deteriorated, and the patient died. Postmortem investigation revealed a fresh thrombus extending from the calf into the right iliofemoral vein and complete embolic occlusion of the lower lobar artery of the left lung.

RESULTS

Platelet Aggregation and Release (Fig. 1)

The patient showed a normal first phase of aggregation induced by ADP and adrenaline; second-phase aggregation was absent at concentrations of the aggregating agents ($10 \mu\text{M}$) which gave irreversible aggregation in normal PRP. Collagen-induced aggregation was sharply decreased.

Release of ATP and ADP, induced by collagen during aggregation, was 3.1% and 10.5% of the total ATP and ADP in the patient's PRP; in PRP from a normal control tested under the same conditions, it was 25.4% and 43.1%, respectively.

Adenine Nucleotides and 5HT Content

Table 1 shows that the total ATP, ADP, and 5HT content of the patient's PRP was very low, and that the decrease was of similar magnitude to that measured in another patient congenitally affected by a platelet qualitative defect

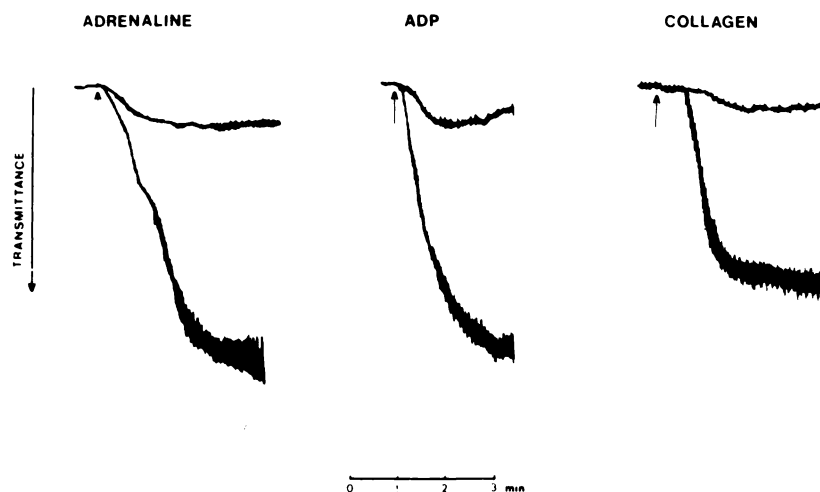


Fig. 1. Examples of platelet aggregation induced by adrenaline ($10 \mu\text{M}$), ADP ($3 \mu\text{M}$), and collagen ($10 \mu\text{l}$ of standard acid-soluble collagen per milliliter PRP). In each case, the lower of the two superimposed traces is from a normal control and the upper trace is from the DIC patient. Platelet aggregation in patient's and normal PRP was carried out at the same platelet concentration (140×10^9 /liter).

Table 1. Platelet 5HT, ATP, and ADP Content

Subjects	5HT	ATP	ADP	ATP:ADP Ratio
DIC patient	0.07	5.18	1.87	2.77
SPD patient	0.04	4.87	0.86	5.66
Controls (n = 12)	0.30 ± 0.10	6.92 ± 0.39	3.87 ± 0.52	1.79 (1.62 – 1.95)*

Values are expressed as nmoles/10⁸ platelets (± SD).

*Ninety-five per cent confidence limits of the ratio calculated by the method of Goldstein.¹²

with the features of storage pool disease. Similarly, the ATP:ADP ratio was higher than normal.

¹⁴C-5HT Uptake

The uptake of radioactive 5HT was much lower in the patient's platelets than in normal platelets, and was similar to that of the patient with storage pool disease. When incubation of PRP with ¹⁴C-5HT was continued up to 5 hr, radioactivity was retained within normal platelets during the incubation period, whereas it was progressively lost into the plasma when the patient's and SPD platelets were investigated (Fig. 2).

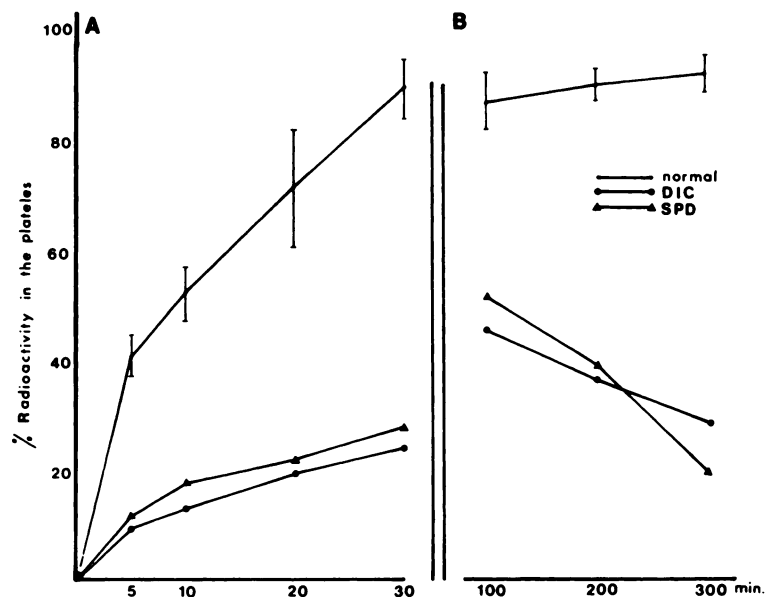


Fig. 2. Uptake of 5HT by normal, SPD patient, and DIC patient PRP. (A) Experiments in which the uptake was followed for 30 min. ¹⁴C-5HT (0.5 μM) was incubated with citrated PRP at 37°C. Platelet counts were adjusted to 100 × 10⁹/liter by dilution with autologous PPP. (B) Experiments in which PRP was incubated for up to 300 min with ¹⁴C-5HT (1 μM). Platelet counts in PRP were (× 10⁹/liter): DIC patient, 140; SPD patient, 485; controls ranged from 340 to 418. The results show the difference between the plasma radioactivity expressed as a percentage of the total. Bars represent ± 1 SD.

Table 2. Breakdown of Radioactive ATP During Exposure of PRP to Collagen

Subjects	Resting		Collagen	
	Per Cent ATP	Per Cent IMP + IN + Hx	Per Cent ATP	Per Cent IMP + IN + Hx
DIC patient	74.5	9.9	70.8	12.1
SPD patient	75.9	8.1	64.4	17.3
Controls (n = 5)	76.0 ± 2.3	8.8 ± 0.9	63.0 ± 1.8	14.7 ± 1.8

Results are given as radioactivity in the indicated spots expressed as percentage of the total recovered radioactivity in all of the ultraviolet absorbing spots on each chromatogram (\pm SD).

Metabolically Active Nucleotides

Incubation of PRP with ^{14}C -adenine results in the labeling of nucleotides of the metabolic pool, whereas those of the nonmetabolic pool stored in cytoplasmic organelles are not labeled.⁶ Table 2 shows that under resting conditions radioactive ATP and its metabolic products were present in normal amounts in the patient's platelets, and that ATP degradation and IMP-hypoxanthine formation (characteristic of the induction of the platelet release reaction by collagen⁷) were less extensive than in the normal PRP. This finding suggested that the patient's platelets were refractory to the metabolic action of the aggregating agent.

DISCUSSION

Platelets from a patient with postoperative DVT and pulmonary embolism accompanied by clinical and laboratory evidence of DIC showed a qualitative platelet abnormality characterized by a defective release reaction. The negative family history, lack of bleeding complications after surgery, and the concomitant appearance of the abnormality with DIC strongly suggested its acquired nature. The decrease in the total ATP and ADP and the high ATP:ADP ratio in the presence of normal amounts of metabolic adenine nucleotides suggested that the low levels of total ATP and ADP were related to the defect of the nonmetabolic pool. These findings, as well as the low platelet content of 5HT accompanied by abnormal uptake and metabolism of the exogenous amine, indicated that abnormal platelet function was due to lack of the platelet organelles where 5HT and nonmetabolic adenine nucleotides are stored together. The defects observed were strikingly similar to those described in the congenital abnormality of platelet function referred to as storage pool disease, and to the findings of Zahavi and Marder⁸ in a patient with systemic collagen disorder and platelet autoantibodies, and of Cowan et al.⁹ in leukemia.

In our patient, exposure of circulating platelets during DIC to release inducers, such as thrombin and plasmin, appeared to be the most likely pathogenic mechanism. It has been shown by Reimers et al.^{10,11} in animal experiments that a partial release or complete degranulation of platelets induced by thrombin did not necessarily lead to the immediate removal of these platelets from the circulation, and that their hemostatic effectiveness was impaired. The present observations suggested that this situation may occur in humans, and that a platelet qualitative defect may be an additional factor contributing to the development of bleeding in the DIC syndrome.

ACKNOWLEDGMENT

We thank Luisa Mannucci and Veena Chantarangkul for expert technical assistance.

REFERENCES

1. Holmsen H, Weiss HJ: Hereditary defect in the platelet release reaction caused by a deficiency in the storage pool of platelet adenine nucleotides. *Br J Haematol* 19:643, 1970
2. Hardisty RM, Mills DCB, Ketsa-Ard K: The platelet defect associated with albinism. *Br J Haematol* 23:279, 1972
3. White JG, Edson JR, Desnick SJ, Witkop CJ: Studies of platelets in a variant of the Hermansky-Pudlak syndrome. *Am J Pathol* 63:319, 1971
4. Pareti FI, Day HJ, Mills DCB: Nucleotide and serotonin metabolism in platelets with defective secondary aggregation. *Blood* 44:789, 1974
5. Denson KWE, in Biggs R (ed): *Human Blood Coagulation, Haemostasis and Thrombosis*, Oxford, Blackwell, 1972, p 602
6. Holmsen H: Collagen-induced release of adenosine diphosphate from blood platelets incubated with radioactive phosphate in vitro. *Scand J Clin Lab Invest* 17:239, 1965
7. Ireland DM: Effect of thrombin on the radioactive nucleotides of human washed platelets. *Biochem J* 105:857, 1967
8. Zahavi J, Marder VS: Acquired "storage pool disease" of platelets associated with circulating platelet antibodies. *Am J Med* 56:883, 1974
9. Cowan OH, Graham RC, Baunach D: The platelet defect in leukemia: Platelet ultrastructure, adenine nucleotide metabolism and the release reaction. *J Clin Invest* 56:188, 1975
10. Reimers HJ, Packham MA, Kinlough-Rathbone RL, Mustard JF: Effect of repeated treatment of rabbit platelets with low concentrations of thrombin on their function, metabolism and survival. *Br J Haematol* 25:675, 1975
11. Reimers HJ, Kinlough-Rathbone RL, Cazenave JP, Senyi AF, Hirsh J, Packham MA, Mustard JF: In vitro and in vivo functions of thrombin-treated platelets. *Thromb Haemostasis* 35:151, 1976
12. Goldstein A: *Biostatistics*. New York, Macmillan, 1964