

Prospective Assessment of Discontinuation and Reinitiation of Erlotinib or Gefitinib in Patients with Acquired Resistance to Erlotinib or Gefitinib Followed by the Addition of Everolimus

Gregory J. Riely,¹ Mark G. Kris,¹ Binsheng Zhao,^{2,5} Tim Akhurst,³ Daniel T. Milton,¹ Erin Moore,¹ Leslie Tyson,¹ William Pao,^{1,4} Naiyer A. Rizvi,¹ Lawrence H. Schwartz,² and Vincent A. Miller¹

Abstract Purpose: Ten percent of U.S. patients with non–small cell lung cancer experience partial radiographic responses to erlotinib or gefitinib. Despite initial regressions, these patients develop acquired resistance to erlotinib or gefitinib. In these patients, we sought to assess changes in tumor metabolism and size after stopping and restarting erlotinib or gefitinib and to determine the effect of adding everolimus.

Experimental Design: Patients with non–small cell lung cancer and acquired resistance to erlotinib or gefitinib were eligible. Patients had 18-fluoro-2-deoxy-D-glucose-positron emission tomography/computed tomography and computed tomography scans at baseline, 3 weeks after stopping erlotinib or gefitinib, and 3 weeks after restarting erlotinib or gefitinib. Three weeks after restarting erlotinib or gefitinib, everolimus was added to treatment.

Results: Ten patients completed all four planned studies. Three weeks after stopping erlotinib or gefitinib, there was a median 18% increase in SUV_{max} and 9% increase in tumor diameter. Three weeks after restarting erlotinib or gefitinib, there was a median 4% decrease in SUV_{max} and 1% decrease in tumor diameter. No partial responses (0 of 10; 95% confidence interval, 0–31%) were seen with the addition of everolimus to erlotinib or gefitinib.

Conclusions: In patients who develop acquired resistance, stopping erlotinib or gefitinib results in symptomatic progression, increase in SUV_{max}, and increase in tumor size. Symptoms improve and SUV_{max} decreases after restarting erlotinib or gefitinib, suggesting that some tumor cells remain sensitive to epidermal growth factor receptor blockade. No responses were observed with combined everolimus and erlotinib or gefitinib. We recommend a randomized trial to assess the value of continuing erlotinib or gefitinib after development of acquired resistance.

Treatment with the epidermal growth factor receptor (EGFR) tyrosine kinase inhibitors (TKI) erlotinib and gefitinib has led to prompt and dramatic radiographic and clinical improvement in selected patients with metastatic non–small cell lung cancer (NSCLC; refs. 1–3). These patients are more likely to have minimal smoking history, be of Asian ethnicity, and have

adenocarcinoma histology (2, 4, 5). Retrospective molecular analysis of tumors from patients who were treated with EGFR TKI identified an association between somatic mutations in *EGFR* and response to gefitinib or erlotinib (6–8). Preliminary data from prospective trials treating only patients with *EGFR* mutations have found response rates of 65% to 82% (9–13). This association between response to treatment and *EGFR* mutations is thought to represent, along with chronic myelogenous leukemia and gastrointestinal stromal tumor, an example of “oncogene addiction” (14).

Because it is likely that some tumor cells remain sensitive to imatinib or trastuzumab, patients with gastrointestinal stromal tumor and *HER2*-amplified breast cancer are routinely continued on these agents after disease progression is documented radiographically. Anecdotally, patients with gastrointestinal stromal tumor and objective evidence of disease progression have reported an acute exacerbation or appearance of symptoms after the withdrawal of imatinib. Investigators have explored the computed tomography (CT) and positron emission tomography (PET) consequences of withdrawal of imatinib in patients with gastrointestinal stromal tumor, noting a “flare” in tumor metabolism after stopping imatinib (15). Similarly, women with *HER2*-amplified breast cancer often continue treatment with trastuzumab despite

Authors' Affiliations: ¹Thoracic Oncology Service, Division of Solid Tumor Oncology, Department of Medicine, ²Department of Radiology, ³Department of Nuclear Medicine, ⁴Human Oncology Pathogenesis Program, and ⁵Department of Medical Physics, Memorial Sloan-Kettering Cancer Center and Weill Medical College of Cornell University, New York, New York
Received 3/7/07; revised 5/1/07; accepted 6/22/07.

Grant support: Steps for Breath and The Society of Memorial Sloan-Kettering, National Cancer Institute grants 5T32CA009207 and 5P01CA005826, and Novartis Pharmaceuticals.

The costs of publication of this article were defrayed in part by the payment of page charges. This article must therefore be hereby marked *advertisement* in accordance with 18 U.S.C. Section 1734 solely to indicate this fact.

Note: Presented in part at the 42nd Annual Meeting of the American Society of Clinical Oncology, Atlanta, Georgia.

Requests for reprints: Gregory J. Riely, Memorial Hospital, 1275 York Avenue, New York, NY 10021. Phone: 212-639-7617; Fax: 212-794-4357; E-mail: rielyg@mskcc.org.

©2007 American Association for Cancer Research.
doi:10.1158/1078-0432.CCR-07-0560

progressive disease. No prospective trials have been done to investigate the role of continued trastuzumab after development of acquired resistance.

Patients with NSCLC who initially respond to erlotinib or gefitinib therapy develop progressive disease after a median of 12 to 13 months (16, 17). After patients develop acquired resistance, as defined by an initial radiographic response to treatment with erlotinib or gefitinib followed by progressive disease while still on erlotinib or gefitinib, a significant proportion of tumors (~50%) can be shown to harbor an acquired *EGFR* T790M mutation, in addition to the drug-sensitizing mutations (L858R or exon 19 deletion; refs. 18–22). *In vitro*, this T790M mutation confers resistance to treatment with erlotinib and gefitinib, suggesting that these tumors continue to require signaling through EGFR. However, in patients with acquired resistance, tumor cells bearing *EGFR* T790M represent a minority of cells, and as such, some proportion of the tumor may remain responsive to erlotinib or gefitinib (21, 23). Based in part on our anecdotal observations of more rapid progression of disease after discontinuation of erlotinib or gefitinib in patients who had initially responded to treatment, we hypothesized that, in patients with acquired resistance to erlotinib or gefitinib, continued treatment with erlotinib or gefitinib may be of value as well.

In addition to the use of “nontargeted” cytotoxic chemotherapies, targeted approaches hold promise for treatment of patients with acquired resistance to erlotinib or gefitinib. Several multitargeted kinase inhibitors that inhibit EGFR and other HER family kinases (i.e., HER2) are beginning to be explored (HKI-272, BIBW 2992; refs. 24, 25). Geldanamycin derivatives have also been shown to have *in vitro* activity against cell lines with *EGFR* T790M mutations (26, 27). Inhibitors of signaling molecules downstream of EGFR could block signals that escape EGFR inhibition.

Everolimus (RAD001, Novartis) is an inhibitor of mammalian target of rapamycin (mTOR), which is being explored for the treatment of NSCLC as a single agent and in combination. Because mTOR is a downstream effector of EGFR, inhibition of this pathway is a reasonable target in patients who seem to continue to depend on EGFR signaling. Previously, we explored combinations of gefitinib and everolimus and established that, in combination with 250 mg/d gefitinib, the maximum tolerated dose of everolimus is 5 mg/d (28). Pharmacokinetic data indicated that coadministration of everolimus and gefitinib did not alter the steady-state serum concentrations of either drug.

We sought to prospectively examine two hypotheses in a population of patients with acquired resistance to erlotinib or gefitinib. We hypothesized that discontinuation of erlotinib or gefitinib in patients with acquired resistance to EGFR TKI would lead to increase in size and metabolic activity of tumors and that reintroduction of erlotinib or gefitinib would lead to decreased size and metabolic activity of tumors. Further, we hypothesized that the addition of everolimus to erlotinib or gefitinib in these patients would overcome acquired resistance.

Materials and Methods

Patients. All patients had metastatic NSCLC and were treated with gefitinib or erlotinib monotherapy for more than 6 months. Patients

had acquired resistance to erlotinib or gefitinib as defined by a prior radiographic response to treatment with gefitinib or erlotinib or, in cases where radiographs were not available to document prior response, documentation of either an *EGFR* exon 19 deletion or an *EGFR* L858R mutation and treatment with erlotinib or gefitinib for at least 6 months. *EGFR* mutational analysis was done as described previously (29). All patients had radiographically documented progressive disease [Response Evaluation Criteria in Solid Tumors (RECIST)] during continued treatment with gefitinib or erlotinib. All patients had measurable indicator lesions, Karnofsky performance status $\geq 70\%$, and adequate hematologic (WBC $>3,000/\mu\text{L}$, hemoglobin >9.0 g/dL, platelets $>100,000/\mu\text{L}$), renal (creatinine <2), and hepatic function (total bilirubin $<1.5\times$ upper limit of normal, aspartate aminotransferase $<2.5\times$ upper limit of normal). The protocol and informed consent documents were reviewed and approved by the Institutional Review Board of Memorial Sloan-Kettering Cancer Center.

Discontinuation and reinitiation of erlotinib or gefitinib. At the time of study entry, following baseline whole-body 18-fluoro-2-deoxy-D-glucose (FDG)-PET/CT and chest CT, patients discontinued treatment with erlotinib or gefitinib (Fig. 1). After 3 weeks without receiving erlotinib or gefitinib, PET/CT and CT scans were repeated. Patients then resumed treatment with gefitinib or erlotinib at the same dose and with the same drug each patient was receiving before study entry. Following 3 weeks of continuous treatment with gefitinib or erlotinib, PET/CT and CT scans were repeated.

Treatment with everolimus. Three weeks after resuming erlotinib or gefitinib, 5 mg/d orally everolimus (RAD001, Novartis), was added. After 3 weeks of combined treatment with gefitinib or erlotinib and everolimus, patients had physical exam, toxicity evaluation, complete blood count, blood chemistry including lipid panel, PET/CT, and CT. CT scan was also done after 8 weeks of combined treatment and then every 8 weeks. History, physical exam, and laboratory evaluation were repeated every 4 weeks.

PET/CT scan methodology. PET/CT scans were done on a GE Discovery combined high-resolution PET and high-resolution CT. After being instructed to fast for at least 4 h before the PET/CT scan, patients were injected with 10 to 20 mCi of [^{18}F]FDG. PET/CT scan images were obtained 20 to 60 min following injection of [^{18}F]FDG. All images were iteratively reconstructed using postemission transmission attenuation-corrected data sets. Region-of-interest analysis tools shipped with the scanner were used to calculate the maximal [^{18}F]FDG concentration within the primary tumor mass. SUV_{max} values were obtained by correcting for the injected dose and the patient's weight (30). SUV_{max} refers to the FDG-avid lesion with the highest standardized uptake value (SUV) on the baseline scan. Subsequent measurements are based on the changes in the SUV_{max} of that lesion.

CT scan methodology. All CT scans were obtained using a thin-section CT imaging protocol on a dedicated GE LightSpeed 16. Target lesions in each patient were selected by a radiologist (L.H.S.). Tumor diameters were determined using standard criteria (RECIST). Tumor volumes were determined by a computer segmentation algorithm. After

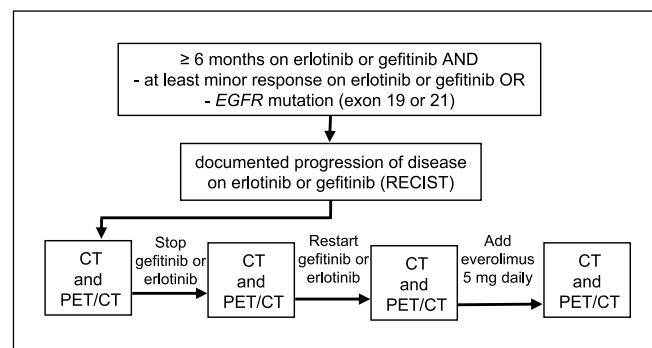


Fig. 1. Protocol schema.

manual determination of a lesion region of interest, the algorithm automatically separated the lesion volume from its surrounding tissues, including lung parenchyma, blood vessels, or chest wall (31–33). Manual correction of segmentation was required at times if a lesion was connected to the mediastinum.

Biostatistics. The primary end point of the protocol was to explore changes in tumor size and metabolic activity of NSCLC as assessed by serial PET/CT scans after EGFR TKI withdrawal, after EGFR TKI reintroduction, and after receiving combination therapy with EGFR TKI and everolimus. A secondary end point was to determine the overall response rate after the addition of everolimus to gefitinib or erlotinib. The planned sample size was 10 evaluable patients. The sample size of 10 patients was chosen to allow description of changes observed in an adequate number of patients. For the assessment of the efficacy of everolimus in combination with gefitinib or erlotinib, this corresponds to the first stage of an optimal two-stage design wherein a response rate (p_0) of 5% is tested against a response rate (p_1) of 20%, with α of 0.05 and power of 0.8. If no responses were observed in the first 10 patients, then accrual would be discontinued. Patients were considered evaluable for protocol end points if the first four CT and PET/CT scans were completed. Time to progression and overall survival for treatment with everolimus were determined from the date of first treatment with everolimus until documented progression of disease (time to progression) or death (overall survival). Median values were determined using Kaplan-Meier survival curves. All toxicities were reported using National Cancer Institute Common Terminology Criteria for Adverse Events v3.0.

Results

Baseline characteristics. The baseline characteristics of the 13 patients who signed informed consent for this protocol are described in Table 1. *EGFR* mutations were present in all patients for whom adequate tissue was available (8 of 13). In a biopsy obtained at the time of development of acquired resistance to gefitinib, one patient had an *EGFR* T790M mutation in addition to *EGFR* L858R (18). Three patients did

not complete the four CT and PET/CT scans required to be evaluable for the primary study end points. One died of liver failure caused by progressive hepatic metastases 4 weeks after stopping gefitinib. One developed increasing back pain 2 weeks after discontinuing gefitinib. The third was taken off study due to cough and dyspnea 3 weeks after restarting erlotinib but before the addition of everolimus.

Clinical findings after discontinuation and reinitiation of gefitinib or erlotinib. Thirteen patients enrolled and, after baseline imaging, discontinued treatment with erlotinib or gefitinib (Fig. 1). For each patient, symptoms that emerged after discontinuing and reinitiating gefitinib or erlotinib are described in Table 2. Seven of 10 patients had an increase in symptoms after discontinuing erlotinib or gefitinib. All 7 had improvement or stabilization of symptoms after restarting gefitinib or erlotinib.

Imaging findings after discontinuation and reinitiation of gefitinib or erlotinib. The changes in diameter and volume of indicator lesions observed after discontinuing and restarting gefitinib and erlotinib are depicted in Fig. 2A and C, respectively. Changes in SUV_{max} are depicted in Fig. 2B. After discontinuation of gefitinib or erlotinib, tumor diameters (RECIST) increased in 8 of 10 patients, whereas tumor volume increased in 9 of 10 patients. Two patients had increase in tumor diameter >20% and three patients had increase in tumor volume >73% (equivalent to an increase in tumor diameter of 20%). After discontinuation of erlotinib or gefitinib, the SUV_{max} of the most FDG-avid lesion increased by $\geq 25\%$ (the European Organization for Research and Treatment of Cancer guideline for progressive metabolic disease) in 5 of 10 patients.

Three weeks after restarting erlotinib or gefitinib, 7 of 10 patients had either no growth or reduction in the diameter of indicator lesions, 8 of 10 patients had a reduction in tumor volume, and 6 of 10 had a >15% decrease in SUV_{max} [European Organization for Research and Treatment of Cancer–defined partial metabolic response (34)] of the lesion with the highest SUV_{max} . Median, mean, and range of size changes and change in SUV_{max} of indicator lesions are presented in Table 3.

Response to combined treatment with everolimus plus gefitinib or erlotinib. No patient (0 of 10, 0%; 95% confidence interval, 0–32%) had a confirmed partial response after combined treatment with 5 mg/d everolimus plus gefitinib or erlotinib (Fig. 3). FDG-PET and CT scans (to determine tumor diameter and tumor volume) were obtained 3 weeks after adding everolimus. At this time point, 5 of 10 patients had a decrease in SUV_{max} of >15%, with a median reduction in SUV_{max} of 18% (mean reduction, 11%; range, -39% to +82%; Table 3). Median time to progression after treatment with everolimus in combination with erlotinib or gefitinib was 3 months. With a median follow-up of 7 months, the median overall survival has not been reached.

Toxicity of combined treatment with everolimus and gefitinib or erlotinib. No patients died within 30 days of receiving combined everolimus plus gefitinib or erlotinib. Most patients experienced fatigue (four patients with grade 1, three with grade 2, and one with grade 3). Treatment-emergent oral ulcerations were seen (one patient with grade 1, two with grade 2, and one with grade 3). Three patients had grade 2 rash. Three patients had grade 1 epistaxis. Diarrhea was seen in two patients (one patient with grade 1 and one patient with grade 3). Grade 1 dyspnea and nausea were seen in one patient each. The most

Table 1. Baseline characteristics of patients enrolled (13 patients)

Characteristic	Number
Age, median (range)	56 (42-81)
Women	11
Histology	
Adenocarcinoma	11
NSCLC	2
Smoking history	
Never smokers	7
≤ 15 pack-y	4
>15 pack-y	2
Time from diagnosis of metastatic disease (mo)	
Median (range)	20 (8-91)
Previous treatment	
Erlotinib	6
Gefitinib	7
Time on erlotinib or gefitinib (mo)	
Median (range)	16 (8-79)
EGFR	
L858R*	2
Exon 19 deletion	6
Not available	5

*On biopsy material obtained after treatment with gefitinib, one patient had both L858R and T790M.

Table 2. Clinical course of individual patients

Patient	After stopping erlotinib or gefitinib	After resuming erlotinib or gefitinib
1	No change	No change
2	Increased cough	Cough stable
3	Seizure, increase in size of brain mets	Brain mets stable
4	No change	No change
5	Increased cough	Cough stable
6	Increased pleural effusion	Improved*
7	No change	No change
8	Cough/fever	Resolution
9	Increased pain	Pain stabilized
10	Increased cough, hemoptysis	Improved cough and hemoptysis
11 [†]	Liver failure	Death
12 [†]	Pain/weakness	No change
13 [†]	Increased fatigue/weakness	Increased pain

*Required drainage of pleural effusion before resumption of gefitinib.

[†]Came off study before completing the first four CT and PET/CT scans.

common grade 3 treatment-emergent toxicities were fatigue, oral mucosal ulcerations, and diarrhea. There were no grade 4 toxicities. Two patients had dose reduction for intolerable grade 2 oral ulcerations.

Discussion

This prospective study of 10 patients who have previously responded to erlotinib or gefitinib suggests that these patients continue to benefit from treatment with erlotinib or gefitinib despite documented progression of disease by RECIST. When patients with acquired resistance to erlotinib or gefitinib discontinue EGFR TKI treatment, the majority of patients had a worsening in lung cancer symptoms, an increase in tumor size, and an increase in tumor FDG uptake. Just 3 weeks after resuming the EGFR TKI, the majority of patients had stabilization or improvement in symptoms, a decrease in tumor size, and reduction in tumor FDG uptake. Finally, we also show that the addition of everolimus (an inhibitor of mTOR) failed to shrink tumors further in this clinical setting.

We chose to examine the changes in radiographic characteristics and symptoms 3 weeks after discontinuing treatment and 3 weeks after reinitiation of EGFR TKI treatment. Three weeks allowed adequate time for clearance of drug (more than five half-lives for gefitinib or erlotinib) and achievement of a new steady state. Radiographic or symptomatic improvements with gefitinib or erlotinib have been shown to commonly occur within a 3-week period (1).

Alterations in lung cancer-related symptoms experienced by patients in this trial were evident just 3 weeks after changing treatments. Although striking, the symptomatic disease progression noted after discontinuation of erlotinib or gefitinib (Table 2) should be interpreted with caution. To be eligible for this trial, patients had to have evidence of progressive disease determined by RECIST, suggesting that patients may have had symptomatic progression even if they remained on treatment with EGFR TKI during that time. However, stabilization or

improvement in symptoms observed after resumption of erlotinib or gefitinib was noted by all patients who had symptomatic progression. A potential limitation of these data is that patients were not randomly assigned to treatment or placebo. In fact, given that the distinct toxicities of erlotinib and gefitinib had been experienced by all patients previously, it is likely they would recognize the symptoms of EGFR TKI retreatment even if a placebo control arm were present. It is possible that some of these symptom reports were related to patients' expectations related to the withdrawal and resumption of treatment. The subjective nature of patient symptoms requires correlation with objective radiographic data.

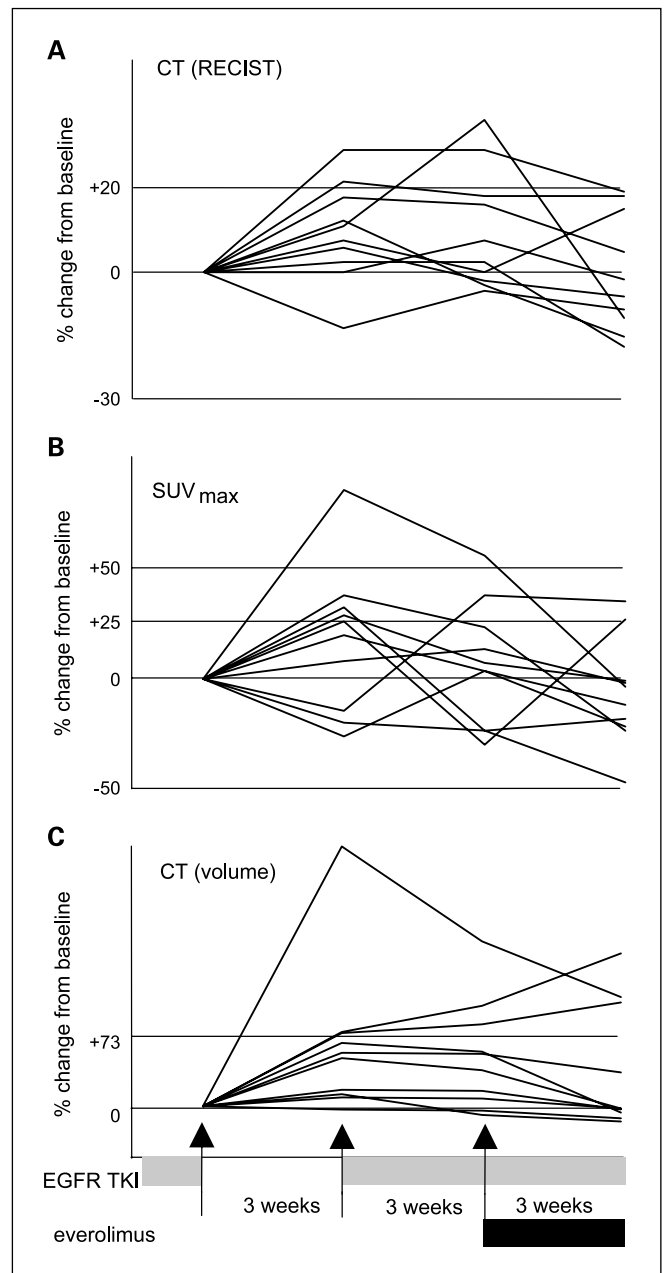


Fig. 2. Imaging changes for individual patients after stopping and restarting erlotinib or gefitinib followed by the addition of everolimus. *A*, CT unidimensional (RECIST) measurements. *B*, FDG-PET SUV_{max} . *C*, CT volume measurements.

Table 3. Changes in tumor on CT and FDG-PET

	After stopping gefitinib or erlotinib	After restarting gefitinib or erlotinib	3 wks after adding everolimus
Median change in tumor diameter	+9%	-1%	-8%
Mean change in tumor diameter	+9%	1%	-9%
Range in change in tumor diameter	-13% to +29%	-14% to +23%	-34% to +15%
Median change in tumor volume	+50%	-1%	-11%
Mean change in tumor volume	+61%	-4%	-10%
Range in change in tumor volume	-4% to +260%	-27% to 15%	-40% to +26%
Median change in SUV _{max}	+18%	-4%	-18%
Mean change in SUV _{max}	+23%	-11%	-11%
Range in change in SUV _{max}	-17% to +87%	-45% to +62%	-39% to +82%

Radiographic evidence of tumor progression after withdrawal of erlotinib or gefitinib followed by improvement or stabilization after restarting gefitinib or erlotinib was noted in a majority of the patients. Because all patients had evidence of disease progression before study entry, the increase in tumor volume and tumor diameters seen after discontinuing erlotinib or gefitinib may have been due to continued progressive disease. The subsequent stabilization of tumor size, and in some cases tumor shrinkage, seen after resumption of EGFR TKI was noteworthy. Patients in this study resumed treatment with the same drug (erlotinib or gefitinib) at the same dose they had received before discontinuation of treatment. Other investigators have reported responses to erlotinib or gefitinib after patients have shown either primary or acquired resistance to the other EGFR TKI (35, 36). Others have reported patients who have resistance to one EGFR TKI have resistance to both erlotinib and gefitinib (37).

To our knowledge, this is the first published report of FDG-PET assessment of patients with NSCLC treated with gefitinib, erlotinib, or everolimus. FDG-PET assessment of changes in tumors is complicated by many factors, which may limit the interpretation and generalizability of the data. FDG avidity as measured by PET scan is altered by tumor growth, cellular proliferation, and, importantly, glucose metabolism. Some changes in FDG-PET scan observed in this report may be a result of changes in glucose metabolism without significant change in tumor growth. Both gefitinib and everolimus are known to alter glucose transport in cell lines independent of changes in proliferation or induction of cell death (38, 39). Interpretation of FDG-PET data is also hindered by the absence of established guidelines for reporting of PET scan results (similar to RECIST). Although the European Organization for Research and Treatment of Cancer and the National Cancer Institute have produced guidelines, they are preliminary and fail to address several issues for result reporting (such as how multiple lesions should be treated; refs. 34, 40). Despite several known confounding factors (41), FDG-PET SUV_{max} correlated with patient symptoms and tumor size determined by CT, suggesting that it is a useful objective measure in this group of patients.

These data suggest that erlotinib or gefitinib should not be discontinued in patients who have previously responded to treatment with erlotinib or gefitinib. No randomized trials of continued treatment with erlotinib or gefitinib versus placebo have been done in this unique patient population. In *HER2*-amplified breast cancer, trastuzumab is generally continued

after development of progressive disease (42). No randomized trials have been done to determine whether this is more effective than discontinuing trastuzumab, partially due to a significant limitation imposed by the 3-week half-life of trastuzumab. Retrospective reviews on this issue have provided conflicting results (42–44).

Several groups are currently testing agents to treat patients with acquired resistance to erlotinib or gefitinib. Our results suggest that, because patients seem to be benefiting from continued treatment with erlotinib or gefitinib, when designing such trials, the time off erlotinib or gefitinib should be minimized.

We observed no significant antitumor activity after the addition of everolimus to gefitinib or erlotinib in these 10 patients with acquired resistance to gefitinib or erlotinib. Although there was some decrease in SUV_{max} and tumor size at 3 weeks after addition of everolimus (Table 3), no RECIST-defined partial responses were seen and there was an increase in toxicity with the addition of everolimus. Absence of response in this small sample does not rule out a response rate as high as 27%. The absence of efficacy of everolimus in this setting may have occurred for a variety of reasons. There are several downstream effectors of EGFR (signal transducers and activators of transcription, RAS, mitogen-activated protein kinase, and other pathways) in addition to mTOR, raising the possibility that other molecules may be more important than mTOR in continued signaling through EGFR. Alternatively, treatment with everolimus may also lead to up-regulation of some upstream signaling molecules (i.e., Akt) due to loss of feedback

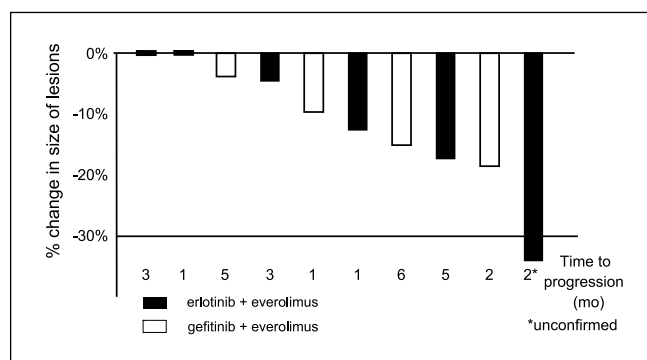


Fig. 3. Waterfall plot for patients treated with everolimus and gefitinib or erlotinib. Columns, maximum decrease in the size of the indicator lesion while on the combination.

inhibition (45). We examined a relatively small number of patients, raising the possibility that, either due to chance or varying mechanisms of acquired resistance, efficacy was not seen. We have previously reported phase I data examining the combination of gefitinib and everolimus, showing the tolerability of this combination and the lack of pharmacokinetic interaction in a few unselected patients (28). The data presented here support the tolerability of the combination with erlotinib or gefitinib in the setting of acquired resistance but failed to reveal any dramatic efficacy in this patient population.

The data provided here suggest several further trials. A randomized trial comparing continued treatment with gefitinib or erlotinib to discontinuation of erlotinib or gefitinib at the time of development of acquired resistance is one consideration. Such a trial could be incorporated with the assessment of a novel agent or conventional chemotherapy in this clinical setting. Further trials to identify agents with activity in patients with acquired resistance to erlotinib or gefitinib are critical for these patients with lung cancer driven by this unique mechanism.

References

- Kris MG, Natale RB, Herbst RS, et al. Efficacy of gefitinib, an inhibitor of the epidermal growth factor receptor tyrosine kinase, in symptomatic patients with non-small cell lung cancer: a randomized trial. *JAMA* 2003;290:2149–58.
- Fukuoka M, Yano S, Giaccone G, et al. Multi-institutional randomized phase II trial of gefitinib for previously treated patients with advanced non-small-cell lung cancer (The IDEAL 1 Trial). *J Clin Oncol* 2003;21:2237–46.
- Perez-Soler R, Chachoua A, Hammond LA, et al. Determinants of tumor response and survival with erlotinib in patients with non-small-cell lung cancer. *J Clin Oncol* 2004;22:3238–47.
- Miller VA, Johnson DH, Krug LM, et al. Pilot trial of the epidermal growth factor receptor tyrosine kinase inhibitor gefitinib plus carboplatin and paclitaxel in patients with stage IIIB or IV non-small-cell lung cancer. *J Clin Oncol* 2003;21:2094–100.
- Miller VA, Kris MG, Shah N, et al. Bronchioloalveolar pathologic subtype and smoking history predict sensitivity to gefitinib in advanced non-small-cell lung cancer. *J Clin Oncol* 2004;22:1103–9.
- Lynch TJ, Bell DW, Sordella R, et al. Activating mutations in the epidermal growth factor receptor underlying responsiveness of non-small-cell lung cancer to gefitinib. *N Engl J Med* 2004;350:2129–39.
- Paez JG, Janne PA, Lee JC, et al. EGFR mutations in lung cancer: correlation with clinical response to gefitinib therapy. *Science* 2004;304:1497–500.
- Pao W, Miller VA. Epidermal growth factor receptor mutations, small-molecule kinase inhibitors, and non-small-cell lung cancer: current knowledge and future directions. *J Clin Oncol* 2005;23:2556–68.
- Inoue A, Suzuki T, Fukuhara T, et al. Prospective phase II study of gefitinib for chemotherapy-naïve patients with advanced non-small-cell lung cancer with epidermal growth factor receptor gene mutations. *J Clin Oncol* 2006;24:3340–6.
- Paz-Ares L, Sanchez JM, Garcia-Velasco A, et al. A prospective phase II trial of erlotinib in advanced non-small cell lung cancer (NSCLC) patients (p) with mutations in the tyrosine kinase domain of the epidermal growth factor receptor (EGFR). *J Clin Oncol* 2006;24:7020.
- Morikawa A, Inoue A, Suzuki T, et al. Prospective analysis of the epidermal growth factor receptor gene mutations in non-small cell lung cancer in Japan. *J Clin Oncol* 2006;24:7077.
- Sunaga N, Yanagitani N, Kaira K, et al. Phase II study of the efficacy of gefitinib in patients with non-small cell lung cancer with the EGFR mutations. *J Clin Oncol* 2006;24:7183.
- Sutani A, Nagai Y, Udagawa K, et al. Phase II study of gefitinib for non-small cell lung cancer (NSCLC) patients with epidermal growth factor receptor (EGFR) gene mutations detected by PNA-LNA PCR clamp. *J Clin Oncol* 2006;24:7076.
- Weinstein IB. Cancer. Addiction to oncogenes—the Achilles heel of cancer. *Science* 2002;297:63–4.
- Van Oosterom AT, Dumez H, Desai J, et al. Combination signal transduction inhibition: a phase I/II trial of the oral mTOR inhibitor everolimus (E, RAD001) and imatinib mesylate (IM) in patients (pts) with gastrointestinal stromal tumor (GIST) refractory to IM. *J Clin Oncol* 2004;22:3002.
- Riely GJ, Pao W, Pham D, et al. Clinical course of patients with non-small cell lung cancer and epidermal growth factor receptor exon 19 and exon 21 mutations treated with gefitinib or erlotinib. *Clin Cancer Res* 2006;12:839–44.
- Jackman DM, Yeap BY, Sequist LV, et al. Exon 19 deletion mutations of epidermal growth factor receptor are associated with prolonged survival in non-small cell lung cancer patients treated with gefitinib or erlotinib. *Clin Cancer Res* 2006;12:3908–14.
- Balak MN, Gong Y, Riely GJ, et al. Novel D761Y and common secondary T790M mutations in EGFR-mutant lung adenocarcinomas with acquired resistance to kinase inhibitors. *Clin Cancer Res* 2006;12:6494–501.
- Pao W, Miller VA, Politi KA, et al. Acquired resistance of lung adenocarcinomas to gefitinib or erlotinib is associated with a second mutation in the EGFR kinase domain. *PLoS Med* 2005;2:1–11.
- Kobayashi S, Boggon TJ, Dayaram T, et al. EGFR mutation and resistance of non-small-cell lung cancer to gefitinib. *N Engl J Med* 2005;352:786–92.
- Kwak EL, Sordella R, Bell DW, et al. Irreversible inhibitors of the EGF receptor may circumvent acquired resistance to gefitinib. *Proc Natl Acad Sci U S A* 2005;102:7665–70.
- Kosaka T, Yatabe Y, Endoh H, et al. Analysis of epidermal growth factor receptor gene mutation in patients with non-small cell lung cancer and acquired resistance to gefitinib. *Clin Cancer Res* 2006;12:5764–9.
- Engelman JA, Mukohara T, Zejnullahu K, et al. Allelic dilution obscures detection of a biologically significant resistance mutation in EGFR-amplified lung cancer. *J Clin Invest* 2006;116:2695–706.
- Wong KK, Fracasso PM, Bukowski RM, et al. HKI-272, an irreversible pan erbB receptor tyrosine kinase inhibitor: preliminary phase 1 results in patients with solid tumors. *J Clin Oncol* 2006;24:3018.
- Shaw H, Plummer R, Vidal L, et al. A phase I dose escalation study of BIBW 2992, an irreversible dual EGFR/HER2 receptor tyrosine kinase inhibitor, in patients with advanced solid tumours. *J Clin Oncol* 2006;24:3027.
- Shimamura T, Lowell AM, Engelman JA, Shapiro GI. Epidermal growth factor receptors harboring kinase domain mutations associate with the heat shock protein 90 chaperone and are destabilized following exposure to geldanamycins. *Cancer Res* 2005;65:6401–8.
- Yang S, Qu S, Perez-Torres M, et al. Association with HSP90 inhibits Cbl-mediated down-regulation of mutant epidermal growth factor receptors. *Cancer Res* 2006;66:6990–7.
- Milton DT, Kris M, Azzoli CG, et al. Phase I/II trial of gefitinib and RAD001 (everolimus) in patients (pts) with advanced non-small cell lung cancer (NSCLC). *J Clin Oncol* 2005;23:7104.
- Pan Q, Pao W, Ladanyi M. Rapid polymerase chain reaction-based detection of epidermal growth factor receptor gene mutations in lung adenocarcinomas. *J Mol Diagn* 2005;7:396–403.
- Meirelles GS, Kijewski P, Akhurst T. Correlation of PET/CT standardized uptake value measurements between dedicated workstations and a PACS-integrated workstation system. *J Digit Imaging*. In press 2007.
- Zhao B, Yankelevitz D, Reeves A, Henschke C. Two-dimensional multi-criterion segmentation of pulmonary nodules on helical CT images. *Med Phys* 1999;26:889–95.
- Zhao B, Reeves AP, Yankelevitz D, Henschke C. Three-dimensional multi-criterion automatic segmentation of pulmonary nodules of helical CT images. *Optical Engineering* 1999;38:1340–7.
- Zhao B, Schwartz LH, Moskowitz CS, Ginsberg M, Rizvi N, Kris MG. Lung cancer: computerized quantification of tumor response—initial results. *Radiology* 2006;241:892–8.
- Young H, Baum R, Cremerius U, et al. Measurement of clinical and subclinical tumour response using [¹⁸F]-fluorodeoxyglucose and positron emission tomography: review and 1999 EORTC recommendations. European Organization for Research and Treatment of Cancer (EORTC) PET Study Group. *Eur J Cancer* 1999;35:1773–82.
- Choong NW, Dietrich S, Seiwert TY, et al. Gefitinib response of erlotinib-refractory lung cancer involving meninges—role of EGFR mutation. *Nat Clin Pract Oncol* 2006;3:50–7.
- Garfield DH. Modern treatment of lung cancer: case 2. Response to erlotinib after failure of gefitinib in a patient with advanced non-small-cell lung carcinoma. *J Clin Oncol* 2005;23:7738–40.
- Viswanathan A, Pillot G, Govindan R. Lack of response to erlotinib after progression on gefitinib in patients with advanced non-small cell lung cancer. *Lung Cancer* 2005;50:417–8.
- Majumder PK, Sellers WR. Akt-regulated pathways in prostate cancer. *Oncogene* 2005;24:7465–74.
- Su H, Bodenstern C, Dumont RA, et al. Monitoring tumor glucose utilization by positron emission tomography for the prediction of treatment response to epidermal growth factor receptor kinase inhibitors. *Clin Cancer Res* 2006;12:5659–67.
- Shankar LK, Hoffman JM, Bacharach S, et al. Consensus recommendations for the use of ¹⁸F-FDG PET as an indicator of therapeutic response in patients in National Cancer Institute Trials. *J Nucl Med* 2006;47:1059–66.
- Keyes JW, Jr. SUV: standard uptake or silly useless value? *J Nucl Med* 1995;36:1836–9.
- Gelmon KA, Mackey J, Verma S, et al. Use of trastuzumab beyond disease progression: observations from a retrospective review of case histories. *Clin Breast Cancer* 2004;5:52–8.
- Montemurro F, Valabrega G, Aglietta M. Trastuzumab-based combination therapy for breast cancer. *Expert Opin Pharmacother* 2004;5:81–96.
- Tripathy D, Slamon DJ, Cobleigh M, et al. Safety of treatment of metastatic breast cancer with trastuzumab beyond disease progression. *J Clin Oncol* 2004;22:1063–70.
- O'Reilly KE, Rojo F, She QB, et al. mTOR inhibition induces upstream receptor tyrosine kinase signaling and activates Akt. *Cancer Res* 2006;66:1500–8.