

## Autologous Ectopic Grafting of Cryopreserved Testicular Tissue Preserves the Fertility of Prepubescent Monkeys That Receive Sterilizing Cytotoxic Therapy

Kirsi Jahnukainen<sup>1,2,5</sup>, Jens Ehmcke<sup>1,6,7</sup>, Mirja Nurmio<sup>3,4</sup>, and Stefan Schlatt<sup>1,6</sup>

### Abstract

Boys faced with future sterility as a result of the need of a sterilizing cancer therapy might avoid this fate by engraftment of cryopreserved immature testicular tissue after therapy is completed. Efforts to address this important survivorship issue have been encouraged by reports of the long-term survival and proliferation of human spermatogonia after xenotransplant of cryopreserved immature testicular tissue into immunocompromised murine hosts. However, spermatogenic arrest at the pachytene spermatocyte stage that occurs in this situation has been associated with a failure in sperm production. In this study, we used a prepubescent simian model to address the possibility that testicular tissue engraftment is insufficiently supported in the model to allow suitable maturation of germ cells. Briefly, we carried out autologous orthotopic grafting of cryopreserved testicular tissue from four prepubescent monkeys and one pubescent rhesus monkey after testicular irradiation and castration of the host animal. Five months after implantation of scrotal grafts, we determined that 3% to 7% of the autografts could be recovered with spermatogenesis proceeding through spermatozoa formation in 13% to 17% of the seminiferous tubules formed in the grafts. In contrast, Sertoli cell-only tubules were detected in parallel xenografts transplanted into immunocompromised mice. Our results show that cryopreservation of testicular tissue from prepubescent primates can maintain the fully functional capacity of spermatogonia to produce sperm, but that host conditions are critical for spermatogenic maturation. Furthermore, our results establish an initial perspective on the quantity of cryopreserved material needed to ensure success in preserving fertility through testicular tissue grafts. *Cancer Res*; 72(20); 5174–8. ©2012 AACR.

### Introduction

Prepubertal boys facing a sterilizing cancer therapy cannot benefit from sperm banking. A potential alternative strategy for preserving their fertility involves cryopreservation of immature testicular tissue (1–3). Studies with nonhuman primates have revealed that fresh prepubertal testicular tissue survives well when xenografted into nude mice, and is able to differentiate to full spermatogenesis (4, 5). The testicular tissue can be removed from the grafting site, and sperm can be retrieved from the tissue. Xenogenic rhesus sperm generated in host

mice have shown to be fertilization competent, allowing *in vitro* embryo development (4). This is contrary to adult testicular tissue that undergoes almost complete degeneration after grafting (6, 7).

Successful long-term survival and proliferation of human spermatogonia has been reported after xenografting of cryopreserved immature testicular tissue (8–10). However, these studies have failed to confirm the preservation of the functionality of spermatogonial stem cells in the cryopreserved tissues. Spermatogenic arrest at the pachytene spermatocyte stage occurred in cryopreserved testicular tissue for both humans and rhesus monkeys after xenotransplantation into an immunodeficient murine host (1, 9). Maximal preservation of spermatogonial stem cells in functional testicular tissue and an adequate transplantation or xenografting procedure are key factors to guarantee success of future fertility preservation approaches using testicular tissue transplantation and xenografting. In the terms of fertility preservation, all previous grafting strategies may be considered unsuccessful.

The reasons why the outcome after grafting of cryopreserved human and monkey xenografts has been poor, so far, remain unknown. It is possible that the cryopreservation protocols were not optimal and that the xenografting is leading to incomplete germ cell maturation due to differences between host and donor gonadotropic hormones (11), local testosterone levels within xenografts, or incompatibilities between the

**Authors' Affiliations:** <sup>1</sup>Department of Cell Biology and Physiology, Center for Research in Reproductive Physiology, University of Pittsburgh School of Medicine, Pittsburgh, Pennsylvania; <sup>2</sup>Department of Women's and Children's Health, Pediatric Endocrinology Unit, Karolinska Institutet and University Hospital, Stockholm, Sweden; Departments of <sup>3</sup>Physiology and <sup>4</sup>Pediatrics, University of Turku, Turku, Finland; <sup>5</sup>Children's Hospital, University of Helsinki and Helsinki University Central Hospital, Helsinki, Finland; <sup>6</sup>University Hospital of Münster, Centre of Reproductive Medicine and Andrology, Institute of Reproductive and Regenerative Biology; and <sup>7</sup>Central Animal Facility of the Faculty of Medicine, University of Münster, Münster, Germany

**Corresponding Author:** Stefan Schlatt, Centre of Reproductive Medicine and Andrology, Institute of Reproductive and Regenerative Biology, University of Münster, Domagkstraße 11, 48149 Münster. Phone: 49-251-835-6099; Fax: 49-251-835-4800; E-mail: Stefan.Schlatt@ukmuenster.de

doi: 10.1158/0008-5472.CAN-12-1317

©2012 American Association for Cancer Research.

primate germ cells and the murine-supporting Sertoli cells (4, 12). Many, thus far, unexplored factors may affect success of germ differentiation in xenografted primate testis tissues. The effects of cold and warm ischemia before the reestablishment of blood supply to the grafts may also have relevant impact and to be explored would have required short-term studies. Warm ischemia may well depend on the site of grafting due to different degrees of vascularization at various grafting sites.

To evaluate if autologous grafting might serve as a fertility preservation method after testicular irradiation and (hemi) castration, ectopic autologous grafting of cryopreserved testicular tissues from prepubertal and pubertal rhesus monkeys was used. Spermatogenic differentiation in autologous grafts was compared with that in xenografts in immunodeficient mouse host.

## Materials and Methods

### Animals

Five male rhesus monkeys aged 30 to 49 months (*Macaca mulatta*) from the University of Pittsburgh Plum Boro primate facility (Pittsburgh, PA) were used for the study. All animal experiments were approved by and carried out under the guidance of the Institutional Animal Care and Use Committee of the University of Pittsburgh School of Medicine. This study is a continuation of an irradiation study reported earlier (3).

### Testicular biopsy and graft cryopreservation

One of the testes in each animal was biopsied under general anesthesia using isoflurane. In one monkey (#3199), unilateral orchidectomy was carried out. At the time of tissue collection, the testicular tissue from donor monkeys #3199, #3082, #3213, and #3117 consisted of seminiferous cords with preleptotene spermatocytes as the most advanced germ cell type and donor monkey #3212 showed full spermatogenesis as described earlier (3). The collected testicular tissue was dissected into small fragments (~1 mm<sup>3</sup>). Altogether, 140 tissue fragments from monkey #3199; 10 fragments from monkeys #3082, #3212, and #3213; and 5 fragments from monkey #3117 were cryopreserved for tissue grafting experiment. Tissue fragments were kept in Dulbecco's Modified Eagle's Medium high glucose (4 g/L) containing 10% fetal calf serum, nonessential amino acids, and antibiotics on ice. Dimethylsulfoxide (DMSO) was added dropwise to the suspension to a final concentration of 1.4 mol/L. The tissue fragments were then transferred into cryovials and submitted to a slow-freezing protocol (1).

Six weeks later, in March 2006, testicular irradiation was carried out at the University of Pittsburgh Medical Center Presbyterian Hospital. The animals were castrated in March and April 2008, except monkey #3117, which was castrated in October 2008.

### Autologous grafting

In June 2008, the testicular grafts were thawed in 37°C water bath for 2 minutes and were washed in fresh ice-cold medium. By using cancer implant G13 needle (Popper Precision Instruments), 5 testicular fragments were placed subcutaneously into the left side of the scrotum, and 5 under the skin on the left

shoulder for monkeys #3082, #3212, and #3213. In monkey #3199, 30 testicular fragments were placed into the left side of the scrotum and 30 into the right side. Also 30 grafts each were placed subcutaneously on the shoulder and left arm. In monkey #3117, 5 grafts were placed subcutaneously on the left shoulder only. Five months later, in October 2008, monkeys were fully anesthetized again, and the grafts were dissected from under the skin and fixed in Bouins solution overnight.

### Xenografting

Three adult (10–15 weeks old) immunodeficient male nude mice (CrI:Nu/Nu-nuBR; Charles River Laboratories) were used as recipients. Mice were castrated and 6 testicular fragments from monkey #3199 were placed in each mouse under the dorsal skin on either side of the dorsal midline by using cancer implant G13 needle (Popper Precision Instruments). Five months later, the mice were anesthetized and killed by exsanguination. The back skin was removed and grafts were dissected from the skin and fixed in Bouins solution.

### Histology

The grafts were fixed for 18 to 24 hours and, washed and stored in 70% ethanol, and embedded in paraffin for serial sectioning at 4 µm throughout the entire graft. Tissue sections were stained with periodic acid-Schiff's reagent and Gill's hematoxylin and examined under the light microscope. Graft survival was defined by light microscopic observation of seminiferous tubules with Sertoli cells in the retrieved graft. The serial section showing best tissue survival was selected for analysis. The tubular diameter, fertility index (FI; percentage proportion of tubules containing spermatogonia), spermatogenic repopulation index (percentage proportion of tubules containing B-spermatogonia or more advanced germ cell types), most advanced germ cell type, and percentage of tubules with the most advanced germ cell type were recorded in 50 tubular cross sections selected for analysis by random systematic sampling. All cross sections of seminiferous tubules were analyzed from smaller grafts, which did not contain 50 tubular cross sections. The identification of type A dark (Ad) and A pale (Ap) spermatogonia followed the scheme of Clermont and Leblond (13). The light microscopic determinations were conducted by one observer (K. Jahnukainen).

## Results

### Graft survival

Five months after autologous grafting, 5% (8/155) of the cryopreserved grafts were recovered. No difference in graft survival was detected between different grafting sites. Altogether, 7% grafts (5/75) from scrotal, 4% (2/50) from shoulder, and 3% (1/30) from arm contained active testicular tissue. Survival of xenografts in the back skin of immunodeficient mice was 6% (1/18) for the same time period.

### Histologic evaluation of spermatogenic recovery

Five months after autologous grafting in the scrotum, 2 of 5 recovered grafts showed fully matured spermatogenesis (Fig.

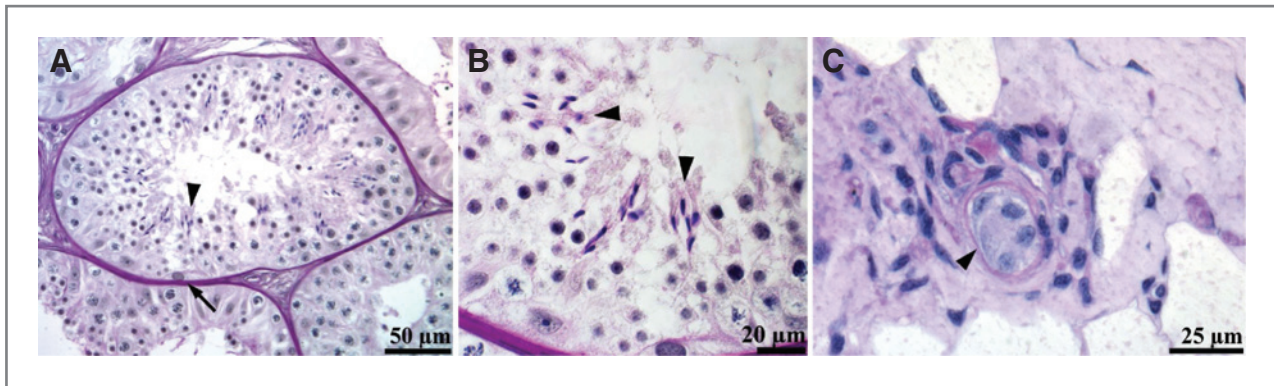


Figure 1. Representative light micrographs of monkey (#3199) testicular grafts 5 months after subcutaneous grafting. A, testicular autograft grafted ectopically under scrotal skin shows a seminiferous tubule with a fully maturing spermatogenesis (arrowhead) and an Ad spermatogonia (arrow). B, high-power micrograph showing spermatozoa with mature acrosome cap and fully formed tail. C, testicular xenograft grafted under back skin of immunodeficient mouse shows no germ cells. Sertoli cell-only tubule (arrowhead) is surrounded by tissue macrophages.

1A and B). The 3 other scrotal autologous grafts had round spermatids and pachytene spermatocytes as the most advanced germ cell stages. Each graft that was recovered from other locations than from scrotal skin showed some germ cell maturation. However, maturation in these grafts did not reach beyond pachytene spermatocyte stage. The surviving xenograft that was recovered from immunodeficient mouse showed Sertoli cell-only (SCO) pattern and no germ cells. Table 1 summarizes the basic morphometric data of the recovered grafts.

In all autologous grafts, a morphologically normal interstitium with blood vessels, macrophages, peritubular, and Leydig

cells was detected (Fig. 1A). The recovered xenograft showed interstitial infiltration with macrophages (Fig. 1C).

**Discussion**

The present results provide first unequivocal evidence that cryopreservation of prepubertal primate testicular tissue maintains the functional capacity of spermatogonia and testicular tissue to produce sperm after grafting. Spermatogenesis up to level of spermatozoa was detected in the cryopreserved grafts autologously grafted into scrotal skin of the rhesus monkey. Testicular tissue that produced sperm was cryopreserved at the time when the donor has still been prepubertal

**Table 1.** Survival and basic morphometric data of monkey testicular grafts according to type and side of grafting

Most advanced germ-cell type in cryopreserved grafts	Type of grafting	Site of grafting	No. of grafts used	No. of grafts recovered (%)	No. of serial sections screened	No. of cross-sections analyzed	Tubular diameter (µm)	Spermatogenetic repopulation		Most advanced germ-cell type	Proportion of tubules with most advanced germ-cell type (%)
								FI (%)	index (%)		
Prepubertals											
#3199 Preleptotene Spc	Auto	Scrotum	60	4 (7%)	14	30	170	43	43	Sperm	13
					42	30	168	50	70	Sperm	17
					41	35	153	43	63	Round Sptd	14
	Auto	Shoulder	30	2 (7%)	10	50	121	6	4	Pachytene Spc	4
					12	50	132	34	26	Pachytene Spc	12
Auto	Arm	30	1 (3%)	30	50	114	26	20	Pachytene Spc	12	
Xeno	Back	18	1 (6%)	1	4	29	0	0	SCO	100%	
#3082 Preleptotene Spc	Auto	Scrotum	5	1 (20%)	23	50	99	2	6	Pachytene Spc	6
	Auto	Shoulder	5	0							
#3213 B-Spg	Auto	Scrotum	5	0							
	Auto	Shoulder	5	0							
#3117 B-Spg	Auto	Shoulder	5	0							
Pubertals											
#3212 Sperm	Auto	Scrotum	5	0							
	Auto	Shoulder	5	0							

Abbreviations: FI, fertility index; SCO, Sertoli cell only; Spc, spermatocytes; Spg, spermatogonia; Sptd, spermatides; sperm, spermatozoa.

Downloaded from http://aacrjournals.org/cancerres/article-pdf/72/20/5174/2674065/5174.pdf by guest on 03 November 2024

(3). Grafting was carried out 2 years later when the donor was adult, but sterile, because of the effects of testicular irradiation and bilateral castration. Transferring our experimental scenario into a clinical setting, 2 subcutaneous testicular grafts containing seminiferous tubules with spermatozoa would have easily enabled assisted reproductive technology specialists to obtain sperm by testicular sperm extraction and to conduct intracellular sperm injection. Therefore, our study reveals a proof-of-principle for fertility preservation via grafting of testicular tissue in a sterile patient.

A major factor that guaranteed successful outcome by autologous grafting was the large number of cryopreserved grafts available in monkey #3199. Survival of the grafted tissue was low (3%–7%) independent of the site where the grafts were placed. Only the removal of one entire testis by hemicastriation provided sufficient material to collect sperm. Altogether, 110 testicular fragments were cryopreserved from this single prepubertal testis. From the other 5 donors, small biopsies (20–40 mg of tissue) were collected and only 5 to 10 tissue fragments were cryopreserved. One of these donors had surviving testicular grafts but these did not contain fully matured sperm. No grafts were recovered from the donor that had shown initiation of puberty and spermatogenesis before the cryopreservation of grafts (3). Present observations are in accordance with a previous autologous grafting experiment with marmoset using a low number of autologous grafts (14). None of the 7 cryopreserved grafts retransplanted in each marmoset were recovered after a 10-month period. A large amount of testicular tissue is therefore a critical factor to guarantee success of future fertility preservation with testicular tissue transplantation.

In this study, spermatogenic maturation beyond meiosis was seen only when ectopic autologous grafting was carried out into the scrotum. This was observed in all 3 grafts with good germ cell survival (FI, 43%–50%). Two other scrotal grafts with lower spermatogonial survival (FI, 2%–6%) had germ cell development up to the pachytene spermatocyte stage. All subcutaneous grafts from other locations showed some degree of spermatogenic recovery but did not develop beyond meiosis. This was despite good survival of spermatogonia (FI, 26%–44%). Our observations are in accordance with the previous autologous grafting study where grafting under the back skin was shown to contribute to spermatogenetic arrest but grafting into the scrotum allowed maturation (14). As previously hypothesized hyperthermia in back skin may be one of the factors responsible for the detected spermatogenic arrest. In this study, no autologous graft with Sertoli cell-only pattern was recovered and in most of the grafts, the spermatogenetic repopulation index was high (20%–70%). Thus, a significant part of surviving grafts showed potential to support spermatogenesis and more SCO tubules would most probably be repopulated with increased grafting time. Our results reveal that cryopreserved autografts survive with an all or nothing pattern. The loss of grafts seems to be the only limiting factor for fertility preservation procedures.

Further studies are needed to explore the reasons for graft disappearance that could be related to the cryopreservation protocol, the ectopic grafting site, graft rejection, or inflammation-like responses eventually induced by ischemia-induced

death of cells in the grafts. Cryopreservation of testicular tissue requires adequate penetration of cryoprotectants through the seminiferous tubular membranes and barriers. A slow-cooling protocol using DMSO supplemented with sucrose and human serum albumin enabled survival of human xenografts in a short-term study (15). Improved survival of primate autografts will require further research on optimal protein support and concentrations of cryoprotectants in freezing solution as well as methods for adequate thawing, comparable to studies with ovarian tissue (16, 17). New grafting techniques that promote a fast and efficient graft revascularization will also be required. Orthotopic transplantation into an intratesticular location offers potentially intensive circulation and hormonal support to the testicular grafts (18). Also, other well-vascularized grafting locations such as muscle or kidney capsule could be selected to decrease posttransplantation anoxia as shown in the studies with ovarian grafts (19). It is also possible that host or gonadal grafts will be treated with hormones, growth factors, or biologic substances (such as vascular endothelial growth factor) to enhance graft vascularization (20).

Cryopreserved testicular grafts from rhesus monkey (#3199) showed very poor survival as xenograft. Only Sertoli cell-only tubules were detected in 1 surviving graft out of 18. The observed graft survival rate of 6% in immunocompromised mice is low compared with 73% previously reported using similar testicular material, freezing program, cryopreservation media, and follow-up time (1). Interstitial infiltration of macrophages was detected suggesting that the host immunoreaction may have affected graft survival and caused death of germ cells. Macrophage activation in the nude mice must be regarded as a factor that potentially affects the probability of spermatogenesis in primate testicular grafts. Macrophage activation can potentially be avoided by using more immunocompromised severe combined immunodeficient mice in future studies. In the present experimental setting, xenografting presented inferior potential for fertility preservation for this particular sterilized donor.

In conclusion, we were able to provide the proof-of-principle that cryopreserved primate spermatogonial stem cells and prepubertal testicular tissue have full functional capacity to mature to sperm after grafting. Optimal transplantation conditions were shown to be critical for maturation capacity. In this study, this was provided by autologous grafting of cryopreserved tissue into the scrotum. The observations provide valuable evidence that spermatogenic arrest reported previously in human testicular tissue (8–10) might be more associated to the xenografting method used than to the lack of spermatogenetic potential in the cryopreserved human tissue. We expect that an improvement of grafting strategies will open scenarios for clinical use of testicular tissue transplantation (1, 21, 22). The most promising approach will most probably involve autologous grafting of immature testicular tissue, stored before gonadotoxic therapy for nonmalignant pathologies or cautiously nonhematologic and nonmetastasizing cancers (1, 21, 22). For the other patients, testicular samples should be cryobanked after careful counseling.

## Disclosure of Potential Conflicts of Interest

No potential conflicts of interest were disclosed.

## Authors' Contributions

**Conception and design:** K. Jahnukainen, S. Schlatt

**Development of methodology:** K. Jahnukainen, J. Ehmcke, S. Schlatt

**Acquisition of data (provided animals, acquired and managed patients, provided facilities, etc.):** K. Jahnukainen, J. Ehmcke, S. Schlatt

**Analysis and interpretation of data (e.g., statistical analysis, biostatistics, computational analysis):** K. Jahnukainen, J. Ehmcke, M. Nurmio, S. Schlatt

**Writing, review, and/or revision of the manuscript:** K. Jahnukainen, J. Ehmcke, S. Schlatt

**Administrative, technical, or material support (i.e., reporting or organizing data, constructing databases):** K. Jahnukainen, S. Schlatt

**Study supervision:** S. Schlatt

## Acknowledgments

The nonhuman primate work was supported by Core B of the Center for Research in Reproductive Physiology at the University of Pittsburgh, includ-

ing the skilful animal handling of Mike Cicco and Rachel Roslund. The authors thank Taija Leinonen and Jutta Salzig for skilful technical assistance.

## Grant Support

This study was supported by NIH grants (1RO1 01050617-01; 2U54HD008610, project 1), the German Federal Ministry of Education and Research (Grant no. 01GN 0809), the Swedish Barncancerfonden, the Finnish Cancer Society, the Helsingin Sanomat Centennial Foundation, the Finnish Pediatric Research Foundation, Paulo Foundation, the Nona and Kullervo Väre Foundation, the Lance Armstrong Foundation, and Academy of Finland.

The costs of publication of this article were defrayed in part by the payment of page charges. This article must therefore be hereby marked *advertisement* in accordance with 18 U.S.C. Section 1734 solely to indicate this fact.

Received April 12, 2012; revised June 16, 2012; accepted July 22, 2012; published OnlineFirst August 17, 2012.

## References

- Jahnukainen K, Ehmcke J, Hergenrother SD, Schlatt S. Effect of cold storage and cryopreservation of immature non-human primate testicular tissue on spermatogonial stem cell potential in xenografts. *Hum Reprod* 2007;22:1060-7.
- Wyns C, Curaba M, Vanabelle B, Van Langendonck A, Donnez J. Options for fertility preservation in prepubertal boys. *Hum Reprod Update* 2010;16:312-28.
- Jahnukainen K, Ehmcke J, Quader MA, Saiful Huq M, Epperly MW, Hergenrother S, et al. Testicular recovery after irradiation differs in prepubertal and pubertal non-human primates, and can be enhanced by autologous germ cell transplantation. *Hum Reprod* 2011;26:1945-54.
- Honaramooz A, Li M-W, Penedo CT, Meyers S, Dobrinski I. Accelerated maturation of primate testis by xenografting into mice. *Biol Reprod* 2004;70:1500-3.
- Rathi R, Honaramooz A, Zeng W, Turner R, Dobrinski I. Germ cell development in equine testis tissue xenografted into mice. *Reproduction* 2006;131:1091-8.
- Schlatt S, Honaramooz A, Ehmcke J, Goebell PJ, Rübber H, Dhir R, et al. Limited survival of adult human testicular tissue as ectopic xenograft. *Hum Reprod* 2006;21:384-9.
- Geens M, De Block G, Goossens E, Frederickx V, Van Steirteghem A, Tournaye H. Spermatogonial survival after grafting human testicular tissue to immunodeficient mice. *Hum Reprod* 2006;21:390-6.
- Wyns C, Curaba M, Martinez-Madrid B, Van Langendonck A, Wese F-X, Donnez J. Spermatogonial survival after cryopreservation and short-term orthotopic immature human cryptorchid testicular tissue grafting to immunodeficient mice. *Hum Reprod* 2007;22:1603-11.
- Wyns C, Van Langendonck A, Wese F-X, Donnez J, Curaba M. Long-term spermatogonial survival in cryopreserved and xenografted immature human testicular tissue. *Hum Reprod* 2008;23:2402-14.
- Goossens E, Geens M, De Block G, Tournaye H. Spermatogonial survival in long-term human prepubertal xenografts. *Fertil Steril* 2008;90:2019-22.
- Bousfield GR, Butnev VY, Gotschall RR, Baker VL, Moore WT. Structural features of mammalian gonadotropins. *Mol Cell Endocrinol* 1996;125:3-19.
- Wistuba J, Mundry M, Luetjens CM, Schlatt S. Cografting of hamster (*Phodopus sungorus*) and marmoset (*Callithrix jacchus*) testicular tissues into nude mice does not overcome blockade of early spermatogenic differentiation in primate grafts. *Biol Reprod* 2004;71:2087-91.
- Clermont Y, Leblond CP. Differentiation and renewal of spermatogonia in the monkey, *Macaca rhesus*. *Am J Anat* 1959;104:237-73.
- Luetjens CM, Stukenborg JB, Nieschlag E, Simoni M, Wistuba J. Complete spermatogenesis in orthotopic but not in ectopic transplants of autologously grafted marmoset testicular tissue. *Endocrinology* 2008;149:1736-47.
- Wyns C, Curaba M, Martinez-Madrid B, Van Langendonck A, François-Xavier W, Donnez J. Spermatogonial survival after cryopreservation and short-term orthotopic immature human cryptorchid testicular tissue grafting to immunodeficient mice. *Hum Reprod* 2007;22:1603-11.
- Hreinsson J, Zhang P, Swahn ML, Hultenby K, Hovatta O. Cryopreservation of follicles in human ovarian cortical tissue. Comparison of serum and human serum albumin in the cryoprotectant solutions. *Hum Reprod* 2003;18:2420-28.
- Fabbri R, Pasquinielli G, Keane D, Magnani V, Paradisi R, Venturoli S. Optimization of protocols for human ovarian tissue cryopreservation with sucrose, 1,2-propanediol, and human serum. *Reprod Biomed Online* 2010;21:819-28.
- Van Saen D, Goossens E, De Block G, Tournaye H. Regeneration of spermatogenesis by grafting testicular tissue or injecting testicular cells into the testes of sterile mice: a comparative study. *Fertil Steril* 2009;91:2264-72.
- Soleimani R, Heytens E, Van den Broecke R, Rottiers I, Dhont M, Cuvelier CA, et al. Xenotransplantation of cryopreserved human ovarian tissue into murine back muscle. *Hum Reprod* 2010;25:1458-70.
- Friedman O, Orvieto R, Fisch B, Felz C, Freud E, Ben-Haroush A, et al. Possible improvements in human ovarian grafting by various host and graft treatments. *Hum Reprod* 2012;27:474-82.
- Jahnukainen K, Ehmcke J, Söder O, Schlatt S. Clinical potential and putative risks of fertility preservation in children utilizing gonadal tissue or germline stem cells. *Pediatr Res* 2006;59:40R-47R.
- Jahnukainen K, Ehmcke J, Hou M, Schlatt S. Testicular function and fertility preservation in male cancer patients. *Best Pract Res Clin Endocrinol Metab* 2011;25:287-302.