

CAR T-Cell Therapies in Glioblastoma: A First Look

Denis Migliorini¹, Pierre-Yves Dietrich², Roger Stupp³, Gerald P. Linette¹, Avery D. Posey Jr¹, and Carl H. June¹



Abstract

Glioblastoma is an aggressive malignancy with a poor prognosis. The current standard of care for newly diagnosed glioblastoma patients includes surgery to the extent, temozolomide combined with radiotherapy, and alternating electric fields therapy. After recurrence, there is no standard therapy and survival is less than 9 months. Recurrent glioblastoma offers a unique opportunity to investigate new treatment approaches in a malignancy known for remarkable genetic heterogeneity, an immunosuppressive microenvironment, and a partially permissive anatomic blood–brain barrier.

Results from three first-in-man chimeric antigen receptor (CAR) T-cell trials targeting IL13R α 2, Her2/CMV, and EGFRvIII have recently been reported. Each one of these trials addresses important questions, such as T-cell trafficking to CNS, engraftment and persistence, tumor microenvironment remodeling, and monitoring of glioma response to CAR T cells. Objective radiologic responses have been reported. Here, we discuss and summarize the results of these trials and suggest opportunities for the field. *Clin Cancer Res*; 24(3); 535–40. ©2017 AACR.

Introduction

Modest progress has been made in the treatment of glioblastoma over the past decade. The current standard of care for newly diagnosed glioblastoma multiforme (GBM) patients established in 2005 remains the backbone of treatment: tumor resection to the extent safely feasible, followed by radiotherapy with concomitant temozolomide chemotherapy (1, 2) and subsequent maintenance treatment. The main goals of surgery are to establish a definitive diagnosis and to alleviate symptoms from compression/increased intracranial pressure. As gliomas are diffusely infiltrative tumors with failure both at the margin of initial tumor resection and also at distant structures within the brain, additional adjuvant therapy with concomitant chemoradiotherapy is indicated. Recently, the combination of alternating electrical fields and maintenance temozolomide chemotherapy has demonstrated an improved progression-free and overall survival in a randomized prospective phase III trial (3). These tumor-treating fields (TTField) have low intensity and are applied through multiple transducer patches directly to the scalp at intermediate frequency of 100 to 300 kHz. Despite all these treatments and efforts, glioblastoma almost invariably recurs. At recurrence, there is no accepted standard of care, and treatment recommendations vary from patient to patient and include repeat surgery or reirradiation in case of monofocal relapse, second-line systemic therapies, such as antiangiogenic

drugs (bevacizumab), alkylating agents (CCNU), and platinum salts (4, 5) or experimental protocols, including locoregional injection of replicating viruses, novel chemotherapy agents, EGFR-targeting compounds, or immunotherapy protocols. Nevertheless, numerous phase III trials have failed to prolong survival in both newly diagnosed or recurrent GBM, for example, bevacizumab, cediranib, cilengitide, nimotuzumab, rindopimut, and most recently nivolumab. New treatments and alternative strategies are urgently needed.

Cancer Immunotherapy: CAR T Cells Are Different

Chimeric antigen receptor (CAR) T cells provide a new strategy to bypass the defective immune system and counter the various obstacles imposed by the blood–brain barrier and tumor microenvironment (TME) associated with GBM. T-cell engineering allows the construction of an autologous cell product harboring a high-affinity single-chain fragment variable (scFv) specific for a target of interest, fused to domains necessary for full activation and costimulation (6, 7). The principal advantage of this new class of therapy is the potent antitumor effector mechanisms mediated by the granzyme/perforin lytic pathway coupled to the specificity of the scFv.

Adoptive T-cell transfer using anti-CD19 CAR T cells has led to remarkable clinical activity in hematologic malignancies (8–10) and FDA approval for pediatric acute lymphoblastic leukemia has been granted recently and appears imminent for various disease indications. CAR T-cell therapy in the context of brain tumors is promising for several reasons. First, identification of highly restricted target antigens expressed on glioblastoma provides the starting point for development of CAR T-cell therapy. Second, recent progress in delineating the human glioma TME provides a deeper understanding of the resistance mechanisms involved in immunosuppression and evasion by the immune system. Glioma is a good example of how specific improvements in trafficking, persistence, and resistance to the immunosuppressive factors related to the TME

¹Center for Cellular Immunotherapies and Parker Institute for Cancer Immunotherapy, Perelman School of Medicine, University of Pennsylvania, Philadelphia, Pennsylvania. ²Department of Oncology, Geneva University Hospital, Geneva, Switzerland. ³Robert H. Lurie Comprehensive Cancer Center, Northwestern University Feinberg School of Medicine, Chicago, Illinois.

Corresponding Author: Gerald P. Linette, University of Pennsylvania, 3400 Civic Center Boulevard, South Pav 8-102, Philadelphia, PA 19104. Phone: 215-573-7032; Fax: 215-349-8550; E-mail: glinette@upenn.edu

doi: 10.1158/1078-0432.CCR-17-2871

©2017 American Association for Cancer Research.

Table 1. Population/schedule/administration differences

		City of Hope	Baylor College	University of Pennsylvania/UCSF
Patient population	NCT	NCT02208362	NCT01109095	NCT02209376
	Patients	1 (adult)	17 (ped. and adult)	10 (adult)
Molecular profile		MGMT non met., IDH1 WT	Not known	All MGMT non met.
Construct	Target	IL13R α 2 (E13Y neopeptide) assessed by IHC	Her2 (FRP5 exodomain) assessed by IHC, CMV pp65 antigen	Humanized EGFRvIII (neopeptide) assessed by RNA-based NGS
	Costimulatory molecules	4-1BBz	CD28z	4-1BBz
	Vector	Lentivirus	Retrovirus	Lentivirus
Protocol/schedule	Number of infusions	Multiple	Multiple	1
	Dose	2 to 5e6	1 to 100e6 cell/m ²	175 to 500e6 cells
	Route	ICV then IVT	IV	IV
Toxicity	Tox	No DLT, no CRS	No DLT, No cardiac tox., no CRS	No DLT, no skin or mucosal or lung, no CRS, 3 non-CAR-related neurologic events
Efficacy	Radiologic responses	Yes	Yes 1PR, 7SD	No 9SD, 1PD
	Expansion	Yes, 1 d (assessed in CSF)	No expansion	Yes (assessed by flow and qPCR in blood)
	Persistence	7 d (CSF)	12 mo in 6 pat. (blood tests by qPCR)	14 d max 2 mo (at low level) (blood, qPCR, flow)
	T-cell repertoire expansion	Yes	Not known	Yes
	Antigen loss	Yes	No	Yes (IHC in 5/7 reoperated pat.)
	Brain trafficking	Not known	Not known	Yes, max 2 mo after infusion

will be especially critical for success. Thus, translational research investments combining the preclinical optimization of CAR constructs with innovative engineering strategies to circumvent immunosuppression are imperative in addition to evaluating the standard variables related to routes of administration, persistence, and cell trafficking to central nervous system (CNS) and dose schedules. These questions have been addressed in three phase I trials recently reported by investigators from the City of Hope (Duarte, CA; ref. 11), Baylor College of Medicine (Houston, TX; ref. 12), and the University of Pennsylvania (Philadelphia, PA)/UCSF (San Francisco, CA; Table 1; ref. 13).

Current Clinical Experience in Glioma

Various CART-cell constructs and routes of administration are currently under investigation. We summarize here the results of three recent reports.

IL13R α 2 CAR T

Brown and colleagues reported the case of a 50-year-old man with recurrent multifocal *IDH1* wild-type, *MGMT* non-methylated GBM (11). The patient had failed standard therapy, including surgery, chemoradiotherapy, TTFIELDS, as well as salvage investigational treatment with FGFR tyrosine kinase inhibitor and had undergone repeat surgery with resection of 3 lesions before enrolling in the CAR T-cell trial. The patient was enrolled on the CAR T-cell study targeting the IL13R α 2 cell surface receptor using CAR T cells expressing an IL13 E13Y mutein, selected for enhanced binding to IL13R α 2. Targeted genomic analysis was performed using the primary tumor and recurrent resected lesions and showed similar mutational profiles with no acquisition of additional novel driver mutations at the time of recurrence; in addition, heterogeneous IL13R α 2 expression with low H-score (+1) was documented. Enriched central memory CD8⁺ T cells (T_{cm}) were lentiviral transduced with a CAR comprised of an IL13R-specific cytokine ectodomain, mutated IgG4-Fc linker, transmembrane domain, 4-1BB costimulatory endodomain, and CD3zeta endodomain construct (Fig. 1). The same group previously

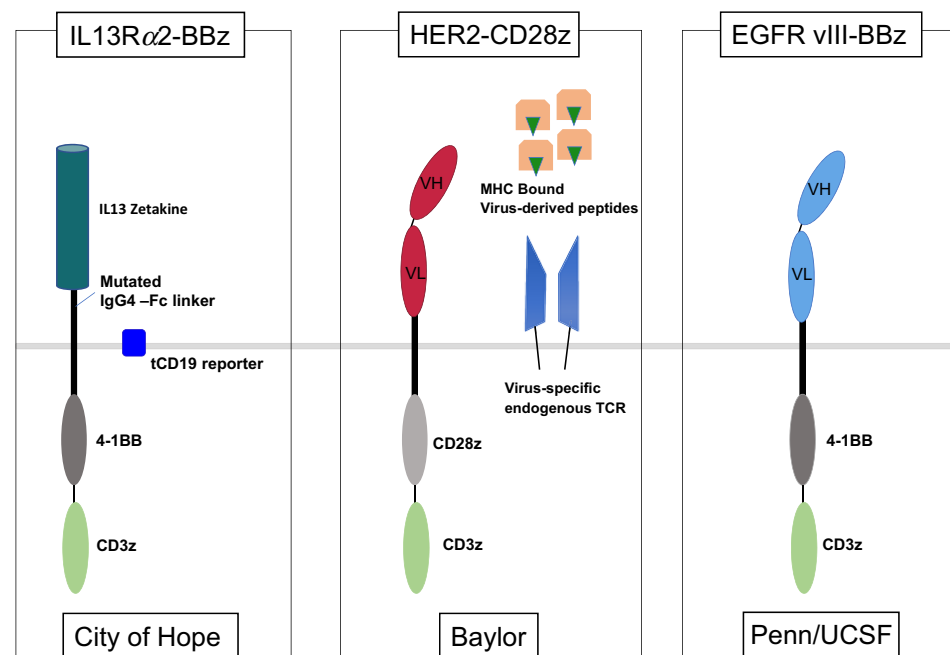
reported the results of a first-generation construct and intracavitary delivery showing objective radiologic responses in 2 of 3 GBM patients and significant decrease in IL13R α 2 expression after therapy (14).

Six intracavitary infusions of CAR T cells were administered through a Rickham catheter device weekly. The initial cell dose (cell product #1: 74% CD4⁺, 64% CAR⁺) was 2×10^6 CAR⁺ T cells, while cycles 2 to 6 were each 10×10^6 CAR⁺ T cells. Progressive disease was observed distant to the injection site cavity, including the appearance of several new spinal metastases. The investigators then switched to intraventricular administration of 10×10^6 CAR⁺ T cells weekly after a new Rickham catheter was placed and 10 additional cycles were administered. The dexamethasone was gradually tapered, and after the 11th cycle, marked tumor regression of all lesions was documented. The infusions were stopped and repeat imaging 5 weeks later confirmed ongoing regression of all intracranial and spinal tumors. The CAR T-cell infusions via the intraventricular route were resumed using the second cell product (90% CD4⁺, 81% CAR⁺) and four additional cycles (10×10^6 CAR T cells per cycle) were administered. The patient had been successfully weaned off dexamethasone at the time of the cycle #16 infusion with resumption of normal daily activities. Unfortunately, recurrent disease at 4 new anatomic sites within the CNS were noted radiographically soon thereafter. Surgical resection of the right frontal recurrent lesion confirmed glioblastoma with minimal or absent expression of the target IL13R α 2.

Clinical benefit was significant as assessed by several objective measures, including 7.5-month duration of response, ability to discontinue corticosteroids, and complete response by RANO criteria with MRI and Fluoro-deoxy-glucose PET (FDG-PET). Cytokine profiling in cerebrospinal fluid (CSF) showed increases in cytokines (CXCL10, CCR2) after each infusion. Interestingly, neither circulating CAR T cells nor stimulatory cytokines were detected in peripheral blood; however, cytopathologic analysis of CSF showed normal reactive lymphocytes and modest percentages of CAR T cells.

The investigators made several new and important observations. First, the route of delivery appeared decisive with complete

Figure 1.
Chimeric antigen receptor constructs.



regression of multiple intracranial and spinal tumors after intraventricular rather than intracavitary administration. Cells and effect appears confined to the CNS with no detection of CAR⁺ T cells or elevated cytokines in the peripheral blood. Second, glioma with heterogeneous target expression exhibited marked response with eventual relapse consistent with tumor editing and growth of antigen loss variants. The use of Tcm-enriched cell product is supported by impressive preclinical data (15); however, in the context of glioblastoma treatment, more evidence is required before any efficacy claims in favor of Tcm over bulk T cells can be postulated.

HER2/CMV CAR T

Ahmed and colleagues reported on 10 adult and 7 pediatric heavily pretreated patients with recurrent HER2⁺ GBM treated with HER2-specific CAR T cells (12).

The construct is a second-generation CAR encoding FRP5 (anti-Her2) scFv, CD28 endodomain, and CD3zeta endodomain (Fig. 1). Polyclonal virus-specific T cells (VST) were selected through native T-cell receptor (TCR) priming by APCs presenting CMV, ADV, and EBV peptides and underwent 4 rounds of stimulation prior to CAR transduction. The mean transduction efficiency was 39% (range, 18%–67%). The main subset was Tcm cells, and the CAR product was tested in cytotoxicity assays against HER2⁺ U373 GBM cell line as a test for antigen specificity. CAR T-cell infusions were delivered intravenously and 3 patients per dose level were treated, starting at 1×10^6 cells/m² to 100×10^6 cells/m². Six additional doses were given at 6- to 12-week intervals if a response was observed. The patients were not lymphopenic at the time of first administration, and no serious adverse events were reported. However, the CAR T cells did not expand in circulation but persisted at low levels for 12 months in 6 patients as assessed by qPCR. Clinical outcome was assessed with a brain MRI at 6 weeks, and radiologic response was recorded in 1 patient. For the entire study cohort, the median PFS was 3.5 months and the median OS was 11.1 months.

The authors conclude that (i) repeated administration of the HER2-specific CAR T cells was safe with no dose-limiting toxicity. This finding is notable as the FRP5 scFv is distinct from the HER2 scFv construct employed in a previous trial that was associated with significant cardiopulmonary toxicity (16); (ii) peripheral intravenous infusion resulted in CAR T-cell persistence (albeit without apparent T-cell expansion) despite the fact that most patients were CMV seropositive. This observation, at first glance, is disappointing, as many were optimistic that VSTs could serve as a useful platform to provide adequate TCR/costimulation to promote T-cell expansion for solid tumors; (iii) clinical activity was seen including one objective radiographic response and 5 patients with durable disease stabilization for >24 months after treatment with CAR T-cell therapy.

EGFRvIII CAR T

O'Rourke and colleagues reported 10 patients with recurrent GBM (9 with multifocal disease) treated with CAR T-cell therapy targeting EGFRvIII, which is characterized by deletion of exons 2 through 7 with insertion of a glycine residue at the junction between exon 1 and 8 of EGFR (13). Seven of 10 patients underwent craniotomy either at progression after CAR T-cell therapy or a later time point, which provided biopsy material for histopathologic and molecular analysis.

The construct was a second-generation CAR with a humanized scFv against EGFRvIII in a lentivirus encoding 4-1BB costimulation, and CD3z activation (Fig. 1); the median transduction efficiency of bulk CD3⁺ T cells was 20% (range, 5%–26%). A single CAR T-cell dose (range, 1.75 – 5×10^8 cells) administered by intravenous infusion was provided. Brain MRI was performed 4 weeks after infusion. No objective radiographic responses were seen; however, one patient had stable disease that persisted for >18 months and remains alive with no additional treatment.

The study investigators made several important findings. First, a single dose of the EGFRvIII-specific CAR T cells was safe with no

dose-limiting toxicity. As demonstrated previously in animal studies and confirmed in the report, there was no cross-reactivity to wild-type EGFR and, thus, no apparent cutaneous toxicity. Second, peripheral intravenous infusion resulted in CAR T-cell expansion peaking 3 to 10 days postinfusion in all subjects. One issue was the limited persistence, as no CAR T cells could be identified by flow cytometry in peripheral blood samples after day 30 postinfusion. Third, surgical biopsies provided information related to CAR T-cell trafficking and immune-mediated alterations of the glioma TME. Of the 7 patients that underwent postinfusion resection, biopsies showed that 4 patients had detectable CAR T cells in tumor tissue as determined by *in situ* RNA hybridization assay, and interestingly, this was accompanied by a marked infiltration of non-CAR-infiltrating T cells, albeit at various time points. Curiously, the 2 patients (#216, #217) with the highest levels of immune-mediated changes as reflected by CD8⁺ T-cell and CAR T-cell infiltration and resulting in high PD-L1 expression remain alive. Patient #209, who is also alive, had no discernible CAR T cells in the resection specimen obtained at day 120 postinfusion. Finally, evidence of target (EGFRvIII) tumor cell elimination was found based on diminished expression of EGFRvIII positive cells within the resection specimen.

Discussion and Early Lessons Learned

Safety

These three trials have demonstrated safety. Neither serious AEs nor cytokine release syndrome were observed.

The limited space in the human skull makes any inflammation occurring in the brain potentially catastrophic (17) and renders adoptive T-cell therapy for brain tumors more challenging than for tumors in other parts of the body. In an effort to allow the use of corticosteroids, which hamper the antitumor immune response, without crippling the CAR T-cell effect, inducible systems desensitizing CAR T cells to steroids or approaches to gene-edit the glucocorticoid receptor (18) could enable control of local endogenous inflammation and still allow CART cells to attack the tumor. Other strategies include the use of anti-IL6 antibody as used by O'Rourke and colleagues as well as the use of bevacizumab to reduce peritumoral edema (6).

Engraftment and trafficking

A major challenge to the treatment of glioma with engineered T cells is the difficulty of determining the efficiency of engraftment and trafficking of cells to the tumor. Under ideal conditions with direct intratumoral injection of CAR T cells, the infused cells can be imaged at low levels by incorporating reporter genes into the CAR T cells (19). The route of administration appears to be important, and intraventricular delivery appears highly promising. The only confirmed radiographic complete response was reported by Brown and colleagues, although the one patient presented was selected as the best responder from a larger cohort in a phase I trial. The intraventricular route enables trafficking of CAR T cells to multiple tumor sites in the CNS, as well as circulating tumor cells (20) and bypasses the requirements for VLA-4 expression and CXCR10, which influence T-cell homing from blood to the CNS (21).

The EGFRvIII trial was informative as CAR T cells administered by a single intravenous infusion were found in tumor samples resected in all 4 patients that underwent early repeat

craniotomy on days 6 to 13 post infusion. Comparative studies would be most informative comparing intraventricular versus intratumoral versus peripheral intravenous routes of administration, alone and in combination.

Persistence

In hematologic malignancies, host lymphodepletion with chemotherapy enhances CAR T-cell proliferation and persistence (6). The three studies in recurrent GBM did not use a preconditioning regimen; however, patients were likely somewhat lymphopenic as they all received corticosteroids and chemoradiation at study initiation. Limited persistence of CAR T cells *in vivo* suggests that preconditioning with nonmyeloablative chemotherapy might be necessary or at least needs to be investigated in the context of glioblastoma. The NCI (Rockville, MD) currently has a clinical trial (NCT 01454596) with EGFRvIII targeting CAR T cells for GBM, whereby the patients undergo 5 days of fludarabine (30 mg/m²) and cyclophosphamide (60 mg/m²) chemotherapy before T-cell infusion and IL2 after infusion. The construct is a third-generation CAR with 4-1BB- and CD28 costimulation, unlike the second generation as used in the three trials presented here; nevertheless, the results of the NCI trial will assess the impact of a preconditioning regimen on the persistence of CAR T cells in GBM.

Another issue that should be addressed is the "vein to vein" interval, defined as the time from initiation of T-cell manufacturing to CAR T-cell infusion. The *ex vivo* manufacturing and release process currently takes approximately 4 weeks, an interval too long for many patients with recurrent GBM, a rapidly growing and fatal disease. One opportunity for clinical investigation would be to include CAR T-cell therapy immediately after completion of 6 weeks of standard chemoradiotherapy. The common lymphopenia associated with chemoradiotherapy may allow for an ideal therapeutic window for CAR T-cell therapy earlier in the disease course in the setting of minimal residual disease (22).

Tumor editing

Elimination of target antigen-positive glioma cells was documented in both the case report on the IL13R α 2-treated patient and the EGFRvIII CAR T-cell-treated patients that were biopsied after treatment. This finding represents strong evidence of tumor editing due to recognition and elimination by CART cells supporting the mechanisms of action and validation of each target. Observations related to radiographic response and durable disease stabilization provide evidence, albeit indirect, for target validation for Her2 antigen after CAR T-cell therapy.

Checkpoint therapies targeting the PD-1/PD-L1 axis should be considered along with CAR T cells. O'Rourke and colleagues demonstrated the conversion of "cold" tumors into "hot" tumors in some of the patients on the trial in that there were increased T cells in postinfusion samples compared with baseline biopsy samples and an increase in TCR diversity in tumors after CAR T-cell treatment beyond the TCRs present in the infusion product. This suggests recruitment of endogenous, nonmodified T cells. It is unclear whether these recruited T cells exhibit antiglioma properties, but given the recent report of preclinical activity with anti-PD-1 and anti-PD-L1 antibodies in glioma (23), there is a strong rationale to combine checkpoint inhibition with EGFRvIII CAR T cells to sustain activity of the CAR T cells and, possibly, to promote epitope spreading. This combination therapy has been

shown to increase antitumor responses in DLBCL after CD19 CAR T-cell therapy and pembrolizumab infusion (24).

Finally, antigen escape and tumor heterogeneity are two major issues in the context of malignant glioma. Future studies targeting multiple antigens to prevent antigen escape and increase tumor killing should evaluate bi- and trisppecific CAR T cells (25, 26). Additional antigens for targeting glioma include glioma-initiating cell markers, such as CD133, and erythropoietin-producing hepatocellular carcinoma A2 (EphA2; refs. 27, 28).

Conclusions

Modest T-cell persistence/trafficking and adaptive immune resistance along with the other immunosuppressive constituents of the TME have been identified as major obstacles for evaluating CAR T-cell therapy for recurrent glioblastoma. Despite the many variables and differences, each study provided valuable insights that will guide clinicians when designing future studies. Investigators have come to the realization that tumor editing is a desirable consequence of effective therapeutic intervention and, thus, selection of multiple targets is an essential first step in creating combinatorial therapy with curative potential. In this regard, each target chosen (IL13R α 2, HER2, and EGFRvIII) by the respective groups has been preliminarily validated, and each warrants further study. Our hope is that future trials with CAR

T-cell therapy will target multiple antigens in each patient in an attempt to address tumor antigen heterogeneity in recurrent glioblastoma.

Disclosure of Potential Conflicts of Interest

A.D. Posey reports receiving commercial research grants from Tmunity. C.H. June reports receiving commercial research grants from Novartis and is an inventor of intellectual property licensed by the University of Pennsylvania to Novartis. No potential conflicts of interest were disclosed by the other authors.

Authors' Contributions

Conception and design: D. Migliorini, R. Stupp, G.P. Linette, A.D. Posey
Development of methodology: D. Migliorini, G.P. Linette
Acquisition of data (provided animals, acquired and managed patients, provided facilities, etc.): G.P. Linette
Analysis and interpretation of data (e.g., statistical analysis, biostatistics, computational analysis): D. Migliorini, G.P. Linette
Writing, review, and/or revision of the manuscript: D. Migliorini, P.-Y. Dietrich, R. Stupp, G.P. Linette, A.D. Posey, C.H. June
Administrative, technical, or material support (i.e., reporting or organizing data, constructing databases): G.P. Linette
Study supervision: G.P. Linette, A.D. Posey

Received September 29, 2017; revised November 8, 2017; accepted November 16, 2017; published OnlineFirst November 20, 2017.

References

- Stupp R, Mason WP, van den Bent MJ, Weller M, Fisher B, Taphoorn MJ, et al. Radiotherapy plus concomitant and adjuvant temozolomide for glioblastoma. *N Engl J Med* 2005;352:987–96.
- Stupp R, Hegi ME, Mason WP, van den Bent MJ, Taphoorn MJ, Janzer RC, et al. Effects of radiotherapy with concomitant and adjuvant temozolomide versus radiotherapy alone on survival in glioblastoma in a randomised phase III study: 5-year analysis of the EORTC-NCIC trial. *Lancet Oncol* 2009;10:459–66.
- Stupp R, Taillibert S, Kanner AA, Kesari S, Steinberg DM, Toms SA, et al. Maintenance therapy with tumor-treating fields plus temozolomide vs. temozolomide alone for glioblastoma: a randomized clinical trial. *JAMA* 2015;314:2535–43.
- Seystahl K, Wick W, Weller M. Therapeutic options in recurrent glioblastoma—An update. *Crit Rev Oncol Hematol* 2016;99:389–408.
- Friedman HS, Prados MD, Wen PY, Mikkelsen T, Schiff D, Abrey LE, et al. Bevacizumab alone and in combination with irinotecan in recurrent glioblastoma. *J Clin Oncol* 2009;27:4733–40.
- Fesnak AD, June CH, Levine BL. Engineered T cells: the promise and challenges of cancer immunotherapy. *Nat Rev Cancer* 2016;16:566–81.
- Lim WA, June CH. The principles of engineering immune cells to treat cancer. *Cell* 2017;168:724–40.
- Porter DL, Levine BL, Kalos M, Bagg A, June CH. Chimeric antigen receptor-modified T cells in chronic lymphoid leukemia. *N Engl J Med* 2011;365:725–33.
- Maude SL, Frey N, Shaw PA, Aplenc R, Barrett DM, Bunin NJ, et al. Chimeric antigen receptor T cells for sustained remissions in leukemia. *N Engl J Med* 2014;371:1507–17.
- Grupp SA, Kalos M, Barrett D, Aplenc R, Porter DL, Rheingold SR, et al. Chimeric antigen receptor-modified T cells for acute lymphoid leukemia. *N Engl J Med* 2013;368:1509–18.
- Brown CE, Alizadeh D, Starr R, Weng L, Wagner JR, Naranjo A, et al. Regression of glioblastoma after chimeric antigen receptor T-cell therapy. *N Engl J Med* 2016;375:2561–9.
- Ahmed N, Brawley V, Hegde M, Bielamowicz K, Kalra M, Landi D, et al. HER2-specific chimeric antigen receptor-modified virus-specific T cells for progressive glioblastoma: a phase 1 dose-escalation trial. *JAMA Oncol* 2017;3:1094–101.
- O'Rourke DM, Nasrallah MP, Desai A, Melenhorst JJ, Mansfield K, Morrissette JJD, et al. A single dose of peripherally infused EGFRvIII-directed CAR T cells mediates antigen loss and induces adaptive resistance in patients with recurrent glioblastoma. *Sci Transl Med* 2017;9:pii:eaag0984.
- Brown CE, Badie B, Barish ME, Weng L, Ostberg JR, Chang WC, et al. Bioactivity and safety of IL13R α 2-redireceted chimeric antigen receptor CD8+ T cells in patients with recurrent glioblastoma. *Clin Cancer Res* 2015;21:4062–72.
- Wang X, Berger C, Wong CW, Forman SJ, Riddell SR, Jensen MC. Engraftment of human central memory-derived effector CD8+ T cells in immunodeficient mice. *Blood* 2011;117:1888–98.
- Morgan RA, Yang JC, Kitano M, Dudley ME, Laurencot CM, Rosenberg SA. Case report of a serious adverse event following the administration of T cells transduced with a chimeric antigen receptor recognizing ERBB2. *Mol Ther* 2010;18:843–51.
- Morgan RA, Chinnsamy N, Abate-Daga D, Gros A, Robbins PF, Zheng Z, et al. Cancer regression and neurological toxicity following anti-MAGE-A3 TCR gene therapy. *J Immunother* 2013;36:133–51.
- Menger L, Gouble A, Marzolini MA, Pachnio A, Bergerhoff K, Henry JY, et al. TALEN-mediated genetic inactivation of the glucocorticoid receptor in cytomegalovirus-specific T cells. *Blood* 2015;126:2781–9.
- Keu KV, Witney TH, Yaghoubi S, Rosenberg J, Kurien A, Magnusson R, et al. Reporter gene imaging of targeted T cell immunotherapy in recurrent glioma. *Sci Transl Med* 2017;9:pii:eaag2196.
- Pentsova EI, Shah RH, Tang J, Boire A, You D, Briggs S, et al. Evaluating cancer of the central nervous system through next-generation sequencing of cerebrospinal fluid. *J Clin Oncol* 2016;34:2404–15.
- Calzascia T, Masson F, Di Bernardino-Besson W, Contassot E, Wilmette R, Aurrand-Lions M, et al. Homing phenotypes of tumor-specific CD8 T cells are predetermined at the tumor site by crosspresenting APCs. *Immunity* 2005;22:175–84.
- Campian JL, Ye X, Gladstone DE, Ambady P, Nirschl TR, Borrello I, et al. Pre-radiation lymphocyte harvesting and post-radiation reinfusion in patients with newly diagnosed high grade gliomas. *J Neurooncol* 2015;124:307–16.

23. Antonios JP, Soto H, Everson RC, Orpilla J, Moughon D, Shin N, et al. PD-1 blockade enhances the vaccination-induced immune response in glioma. *JCI Insight* 2016;1:e87059.
24. Chong EA, Melenhorst JJ, Lacey SF, Ambrose DE, Gonzalez V, Levine BL, et al. PD-1 blockade modulates chimeric antigen receptor (CAR)-modified T cells: refueling the CAR. *Blood* 2017;129:1039-41.
25. Hegde M, Mukherjee M, Grada Z, Pignata A, Landi D, Navai SA, et al. Tandem CAR T cells targeting HER2 and IL-13Ra2 mitigate tumor antigen escape. *J Clin Invest* 2016;126:3036-52.
26. Bielamowicz K, Fousek K, Byrd TT, Samaha H, Mukherjee M, Aware N, et al. Trivalent CAR T-cells overcome interpatient antigenic variability in glioblastoma. *Neuro Oncol* 2017 Sep 16. [Epub ahead of print].
27. Chow KK, Naik S, Kakarla S, Brawley VS, Shaffer DR, Yi Z, et al. T cells redirected to EphA2 for the immunotherapy of glioblastoma. *Mol Ther* 2013;21:629-37.
28. Zhu X, Prasad S, Gaedicke S, Hettich M, Firat E, Niedermann G. Patient-derived glioblastoma stem cells are killed by CD133-specific CAR T cells but induce the T cell aging marker CD57. *Oncotarget* 2015;6:171-84.