

Treatment of Life-threatening Hemorrhage Due to Acquired Factor VIII Inhibitor

By Tomás Pintado, Howard F. Taswell, and E. J. Walter Bowie

An otherwise healthy elderly man developed massive, life-threatening, sublingual bleeding associated with an idiopathic factor VIII inhibitor. The patient was treated with cyclophosphamide, steroids, factor VIII concentrates, and repeated plasmapheresis (including three times with NCI-IBM blood-cell separator). Rapid clinical and laboratory improvement occurred, with complete disappearance of the in-

hibitor. The patient has remained well, without evidence of an inhibitor, for 8 mo. The possible role of each of the therapeutic measures in the disappearance of the inhibitor and the possible pathogenetic mechanism of this disorder are discussed. A high mortality rate and a striking incidence of sublingual hematoma have been observed in cases in the literature.

THE DEVELOPMENT OF anti-factor VIII antibodies (inhibitors)* is an ominous complication in 5%–20% of patients with hemophilia A.²⁻⁴ Inhibitors also can appear in nonhemophilic persons, mostly in young women during their first year postpartum or in patients with various disorders with autoimmune characteristics such as rheumatoid arthritis, systemic lupus erythematosus, regional enteritis, or pemphigus. They are occasionally associated with drug reactions, in particular with penicillin.⁵ Finally, they might arise in an otherwise healthy person without underlying disease; this happens most often in elderly persons of either sex.

The development of an anti-factor VIII inhibitor in a nonhemophilic patient is usually associated with a protracted course and often with a fatal hemorrhage. Therapy of this serious condition has included factor VIII concentrates (both homologous and heterologous), conventional plasmapheresis, and corticosteroids, with little or no success.

The use of immunosuppressants (6-mercaptopurine, azathioprine, cyclophosphamide) has also been advocated in the treatment of factor VIII inhibitors in both hemophiliacs and nonhemophiliacs. The results of initial trials with daily administration of 6-mercaptopurine or azathioprine were encouraging for the nonhemophilic group,^{2,6-8} although relapse often occurred on withdrawal of the drug.^{6,8} In 1971, Green⁹ reported successful treatment of a nonhemophilic by the use of large doses of factor VIII and a single large dose of cyclophosphamide. The patient remained well without evidence of recurrence.

We report a case of idiopathic, acquired, factor VIII inhibitor with life-threatening bleeding successfully treated by means of plasmapheresis, factor VIII concentrates, a single large dose of cyclophosphamide, and steroids. Plas-

*Throughout this report, the term inhibitor will be used because it is now well accepted that most, if not all, factor VIII inhibitors are indeed antibodies.¹

From the Mayo Clinic and Mayo Foundation, Rochester, Minn. 55901.

Submitted December 18, 1974, accepted April 10, 1975.

Address for reprint requests: Dr. Howard F. Taswell, Mayo Clinic, 200 First Street SW, Rochester, Minn. 55901.

© 1975 by Grune & Stratton, Inc.

mapheresis, initially performed by conventional methods, was subsequently more efficiently achieved by means of the continuous-flow centrifuge blood-cell separator developed jointly by the IBM Corporation and the National Cancer Institute.¹⁰

CASE REPORT

A 77-yr-old white man was admitted on Dec. 28, 1973, because of massive ecchymoses of the left flank, arm, and leg. He had been well until approximately 2½ mo before admission, when he had undergone an operation for a right carpal tunnel syndrome (at another institution). The pathologic diagnosis was "slight chronic nonspecific synovitis." There was no history, symptoms, or physical findings of an underlying rheumatic disorder. There had been excessive bleeding from the wound during the postoperative period; since that time he had suffered multiple extensive ecchymoses and had required transfusions. He had no personal or family history of unusual bleeding.

Findings on Admission

Results of physical examination were unremarkable except for the huge hematomas of the left flank, arm, and leg, with severe limitation of motion.

The initial laboratory data included: hemoglobin, 7.5 g/dl; bleeding time (Duke and Ivy), normal; platelets, 780,000 cu mm; plasma clot time, 194 sec (normal, 70-90 sec); prothrombin time, 20 sec (normal, 17-19 sec); thrombin time, normal; partial thromboplastin time (PTT), 207 sec (normal, 45-60 sec), and factor VIII, < 1%. Coagulation studies showed the presence of a factor VIII inhibitor (see below).

Multiple tests and examinations to detect an underlying rheumatic, collagen, vascular, or malignant disorder were negative, including rheumatoid factor, antinuclear antibody, LE preparation, Coombs' test, liver function studies, and roentgenologic examination of the gastrointestinal and renal organs.

Clinical Course

On the morning of December 30, 36 hr after admission, the patient complained of a feeling of imminent death; a rapidly enlarging sublingual hematoma was causing difficulty with speaking and breathing. The PTT was 185 sec, and the factor VIII level was < 1%. A conventional 4-U plasmapheresis removed 1400 ml of plasma; 6750 U of factor VIII concentrate (Humafac) was infused, and then 1500 mg of cyclophosphamide was administered intravenously. Prednisone therapy, 60 mg/day, was started.

On December 31, the patient felt better and could speak more clearly. Plasmapheresis (1400 ml) was repeated, and 3750 U of factor VIII concentrate was given.

By January 2, the sublingual hematoma had resolved, but a large hemarthrosis had developed in the right shoulder. Factor VIII level was < 1%. Plasmapheresis (1400 ml) was repeated, and 3750 U of factor VIII concentrate was given. On January 4, PTT was 148 sec and factor VIII level still was < 1% in spite of an additional 3750 U of factor VIII concentrate given on January 3. At this point, because of persisting low factor VIII levels and recurrent hematomas, it was elected to perform more intensive plasmapheresis using the blood-cell separator; 6000 ml of plasma was removed and replaced with 4400 ml of fresh-frozen plasma and an additional 3750 U of factor VIII concentrate. One hour after this procedure, the factor VIII level was 25%; 24 hr later, on January 5, the PTT was 123 sec, and the factor VIII level was 8%.

The PTT remained moderately prolonged (between 105 and 125 sec) during the following 3 days. No further bleeding occurred until January 7 when pain and swelling of the right shoulder recurred associated with tachycardia; the PTT was 109 sec. On the following morning, when the factor VIII level was 25%, another 6000 ml of plasma was removed by plasmapheresis with the blood-cell separator. After 3750 U of factor VIII concentrate was infused, the factor VIII level increased to 225%. Twenty-four hours later, the factor VIII level was 41%. On January 11, a third plasmapheresis was performed removing 6000 ml of plasma, which was replaced with 4400 ml of fresh frozen plasma and an additional 3750 U of factor VIII concentrate. The level of factor VIII rose to 200%. No further bleeding occurred, and factor VIII levels remained at 50% or more from this point on. No further treatment was required. The patient was dismissed on January 22,

3 wk after admission, completely recovered and with normal coagulation values. At the time of this report, 8 mo later, the patient remains well, and there is no laboratory evidence of a factor VIII inhibitor.

MATERIALS AND METHODS

The tests of hemostasis were performed as previously described.¹¹

The factor VIII activity of the samples was measured by a one-stage partial thromboplastin assay according to the method of Bowie et al.¹¹ One unit of factor VIII was defined as that activity present in 1 ml of pooled normal plasma.

Factor VIII inhibitor was titrated by the method of Roberts et al.¹² Serial dilutions of the patient's plasma (with buffered saline) and normal plasma were mixed in equal volumes, the mixture was incubated for 60 min at 37°C, and a PTT determination was performed at the end of this period. The inhibitor titer was taken as the greatest dilution that prolonged the PTT by 30 sec over the control time. The control time was determined by diluting normal plasma 1 : 1 with buffered saline and determining the PTT after 60 min of incubation at 37°C.

RESULTS

Figure 1 shows the factor VIII and PTT values at various times in relation to the therapy. Despite the initial treatment with conventional plasmapheresis and factor VIII concentrate on repeated occasions during the first 5 days, the factor

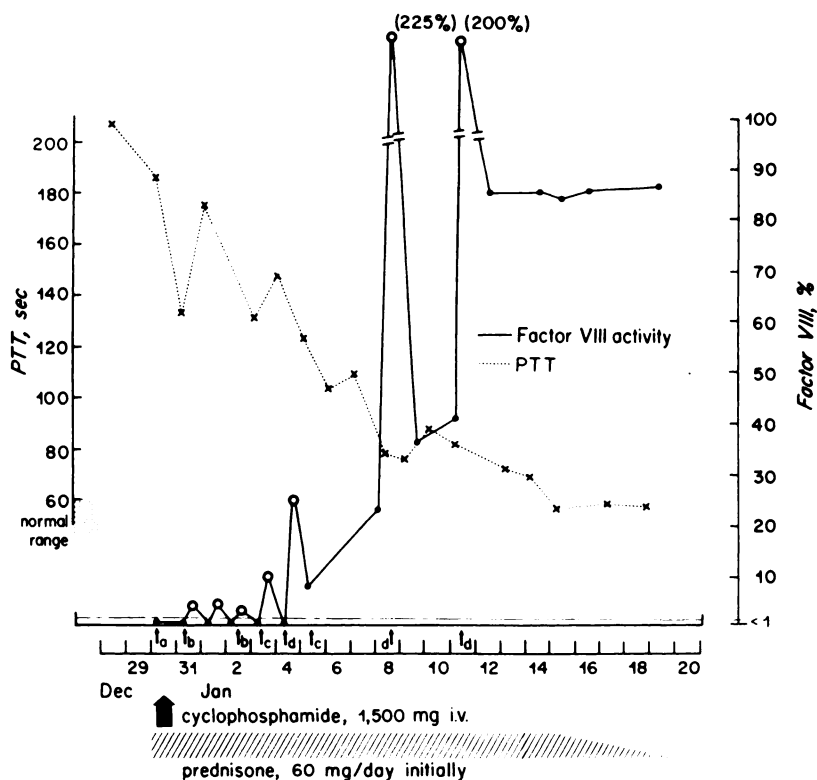


Fig. 1. PTT and factor VIII (open circles, at 3 min after concentrate given; solid circles, at 6-12 hr after) values during hospital course. Additional treatment: (a) conventional plasmapheresis (1400 ml) and 6750 U of factor VIII concentrate; (b) conventional plasmapheresis (1400 ml) and 3750 U of factor VIII concentrate; (c) 3750 U of factor VIII concentrate; (d) blood-cell separator plasmapheresis (6000 ml), 4400 ml of fresh-frozen plasma, and 3750 U of factor VIII concentrate.

VIII level was still $< 1\%$ when measured 6 hr or more after the procedure. These laboratory findings paralleled a clinical course in which recurrence of bleeding followed temporary improvement related to the therapeutic maneuver.

The inhibitor titer (1:4) was of the same order of magnitude on January 2, after the repeated conventional plasmapheresis and factor VIII concentrate therapy, as it was 3 wk before admission to this hospital. The factor VIII level at 6 or more hr after the therapeutic procedure became measurable (8%) for the first time after massive plasmapheresis with the blood-cell separator on January 4. A similar beneficial effect followed the same procedure on January 8.

DISCUSSION

The presence of an acquired factor VIII inhibitor in a nonhemophilic constitutes a serious disease for which there has been no satisfactory treatment until recently. Spontaneous disappearance of the antibody is not uncommon in cases in which the inhibitor is associated with an underlying disorder, once the underlying disease is under control. This fact is illustrated by the case of Ellis et al.¹³ (recovery in 6 wk after bowel resection for regional enteritis) and by perhaps as many as half or more of the cases associated with an allergic reaction to penicillin, in which complete recovery may take place within 2 or 3 wk after cessation of the drug administration.⁵ When the factor VIII inhibitor appears during the postpartum period, about half of the patients recover completely, but this event may take place as late as 11 yr after the initial episode and usually not less than 6 mo.⁴

With the idiopathic variety of factor VIII inhibitors, spontaneous remission is not the rule and, when it does occur, may be years after the disease first appears. None of the 12 cases of idiopathic factor VIII inhibitor compiled by Sise et al.¹⁴ showed complete spontaneous recovery during the period of follow-up. In only three of the 13 cases reported by Shulman and Hirschman¹⁵ was there complete remission (at 3 mo, 7 mo, and 2½ yr), but the clinical data are lacking in this report, and one of these patients apparently had mild rheumatoid arthritis. In the two cases of idiopathic factor VIII inhibitor reported by Margolius et al.¹⁶ inhibitor persisted for at least 1 yr and probably also was present at the time of last follow-up at 4 yr in one case; in the other case there was a mild inhibitor effect appearing after an accident, with very mild bleeding (requiring no treatment), disappearing spontaneously at 6 mo. A patient studied by Hougie¹⁷ had a severe stormy course and no remission in 3 yr. Horowitz and Fujimoto¹⁸ reported two cases: one probably was associated with penicillin reaction, and there was spontaneous recovery in 8 mo; in the other, presumably idiopathic, the patient died of complications after 6 mo without remission.

When it became universally accepted that most, if not all, of the factor VIII inhibitors are antibodies,¹ immunotherapy seemed an attractive way to treat these disorders.^{2,6-8} Green⁹ expanded the concept to the use of specific immune suppression by treating one patient with a single large dose of cyclophosphamide and a large antigenic load (human factor VIII concentrate); complete remission occurred in this patient who had not responded previously to more conventional immunosuppressant therapy.

Several therapeutic maneuvers were used in the present case. The rapid development of an asphyxiating sublingual hematoma prompted the use of plasmapheresis and large doses of factor VIII concentrates as the only means of quickly controlling the bleeding. Concomitantly, a single large dose of cyclophosphamide was administered. Several days after the initial therapy, there was still evidence of persistence of the inhibitor and recurrent bleeding; at this point, massive plasmapheresis with a blood-cell separator achieved a rapid removal of the inhibitor and prompt recovery. Although Edson et al.¹⁹ successfully used a blood-cell separator to plasmapherese a hemophiliac patient with a subdural hematoma as a means of preparing for surgical drainage, we are not aware of this procedure having been reported as a primary means of treatment of a patient with an idiopathic factor VIII inhibitor.

Two different phenomena are involved in the recovery from a bleeding diathesis due to a factor VIII inhibitor. One is cessation of the factor VIII antibody production, that is, abrogation of the ongoing immune response. The other is the disappearance of the antibody already formed. Although immunologic characterization of the inhibitor was not done in this case, practically all the cases have been due to an IgG antibody.¹ Thus, a half-life of 3 wk can be expected. Whereas a complete recovery from factor VIII inhibitor disease requires only cessation of the immune response with eventual disappearance of the antibody, a recovery as rapid as in our patient must also be associated with the rapid clearance of the antibody already formed. Thus, there are two possible explanations for the prompt recovery of this patient.

Spontaneous remission of the immune response, without therapy, may have occurred at the time of or shortly after admission to the hospital. The severe bleeding diathesis present at this point would have been due to the formed antibody, and the subsequent rapid disappearance of the inhibitor would have resulted from aggressive plasmapheresis. In view of the infrequency of spontaneous recovery and of the time sequence of this event in other cases, this hypothesis seems unlikely. In fact, our case may represent the shortest time of complete recovery (3 mo from the time of initial bleeding symptoms to complete disappearance of the inhibitor) from idiopathic (acquired) factor VIII inhibitor. Repeated conventional plasmapheresis alone, even up to 30 500-ml units of blood per wk for 3 wk, has failed in the management of these patients.¹⁵

Alternatively, cessation of the immune process and antibody formation could have been the result of the simultaneous use of an antigenic load and immunosuppressive therapy (cyclophosphamide) as advocated by Green.⁹ Parenthetically, in this approach, presumably human factor VIII should be used, rather than heterologous (bovine or porcine) factor VIII, if specific immune suppression is to be achieved. Again, immunosuppression alone cannot account for the rapid clearance of the inhibitor achieved in this case. Massive plasmapheresis was deemed necessary in view of the severity and recurrence of bleeding associated with the persistent unmeasurably low levels of factor VIII during the first 7 days of hospitalization. In contrast to Green's case,⁹ in which a single initial 1500-mg dose of cyclophosphamide was followed by two additional 500-mg doses at 4 and 6 wk, no additional cytotoxic agent was given in our case.

It is unlikely that the steroid therapy had a direct effect on the suppression of the immune response. In carefully reviewing the data of the published cases of acquired factor VIII inhibitors in nonhemophiliacs, we were not impressed with the therapeutic effects of steroids. Whereas a transient decrease in the inhibitor titer was not infrequent, there seldom, if ever, was a complete and rapid remission. Corticosteroids may be of some benefit in those cases in which the inhibitor is associated with an underlying disorder such as collagen disease. In the idiopathic type, none of the 32 cases selected from the series of Sise et al.,¹⁴ Shulman and Hirschman,¹⁵ Horowitz and Fujimoto¹⁸ (case 2), Hougie,¹⁷ Rizza et al.,⁸ and Margolius et al.¹⁶ responded to steroids.

Activated prothrombin concentrate has been used successfully to treat patients with inhibitors of factor VIII.^{20,21} This therapy was not used in our patient because of his favorable response to other types of treatment.

There were nine deaths in the combined group of 32 cases, during a period of follow-up that often was short. Therefore, in reported cases the mortality is at least 30%, emphasizing the severity of this disorder, although inhibitors have been described in some patients with systemic lupus erythematosus who have had less severe or no bleeding.¹⁶ The frequency and severity of sublingual hematomas and of bleeding into the soft tissues of the neck, which pose an immediate threat of suffocation, are noteworthy. This complication has been noted by Bidwell²² and Hougie.³

It was present in our case, in Green's case,⁹ in one of the cases of Robboy and co-workers,⁷ in Masure's case,²³ and in one of the three cases of Rizza et al.,⁸ and it caused death in Knyvett's²⁴ and Henderson's²⁵ cases. This complication developed in two of the three cases of Sherman et al.,⁶ with a fatal outcome in one. This complication may arise at one time or another in as many as 40% of these patients during the course of their disease.

In the few cases of idiopathic acquired factor VIII inhibitor in which there has been remission, the patients seem to have remained well, and the inhibitor has not reappeared in a follow-up of as long as 4 yr, as in the case of Green⁹ (personal communication). Most of these patients had received some form of immunosuppressant therapy.^{6,7,9} This situation is in contrast to that of hemophilia, in which immunosuppressant therapy has met with failure or only partial and transient decrease in factor VIII inhibitor titers.²⁶

We think that a combination of specific immune suppression and intensive plasmapheresis may be the best form of treatment in patients with acquired idiopathic factor VIII inhibitors and life-threatening bleeding. Specific immune suppression appears to be effective in the abrogation of factor VIII inhibitor formation. If this form of immune paralysis is to be attempted, human rather than heterologous (porcine or bovine) factor VIII must be used. In this situation, and faced with a possible fatal hemorrhage, one can only resort to large doses of human factor VIII concentrate and to the removal of large amounts of the inhibitor. This is particularly true if the inhibitor titer is high. We call attention to the great potential of massive plasmapheresis with a blood-cell separator in the treatment of this situation.

REFERENCES

1. Hoyer LW: Immunologic properties of antihemophilic factor. *Prog Hematol* 8:191-221, 1973
2. Bidwell E: Acquired inhibitors of coagulants. *Annu Rev Med* 20:63-74, 1969
3. Hougie C: Circulating anticoagulants, in Poller L (ed): *Recent Advances in Blood Coagulation*. Boston, Little, Brown, 1969, p 197
4. Feinstein DI, Rapaport SI: Acquired inhibitors of blood coagulation. *Prog Hemostasis Thromb* 1:75-95, 1972
5. Green D: Spontaneous inhibitors of Factor VIII. *Br J Haematol* 15:57-75, 1968
6. Sherman LA, Goldstein MA, Sise HS: Circulating anticoagulants (antifactor VIII) treated with immunosuppressive drugs. *Thromb Diath Haemorrh* 21:249-258, 1969
7. Robboy SJ, Lewis EJ, Schur PH, Colman RW: Circulating anticoagulants to Factor VIII: Immunochemical studies and clinical response to Factor VIII concentrates. *Am J Med* 49:742-752, 1970
8. Rizza CR, Edgumbe JOP, Pitney WR, Child JA: The treatment of patients having spontaneously occurring antibodies to antihemophilic factor (Factor VIII). *Thromb Diath Haemorrh* 28:120-128, 1972
9. Green D: Suppression of an antibody to Factor VIII by a combination of Factor VIII and cyclophosphamide. *Blood* 37:381-387, 1971
10. Freireich EJ, Judson G, Levin RH: Separation and collection of leukocytes. *Cancer Res* 25:1516-1520, 1965
11. Bowie EJW, Thompson JH Jr, Didisheim P, Owen CA Jr: *Mayo Clinic Laboratory Manual of Hemostasis*. Philadelphia, Saunders, 1971
12. Roberts HR, Scales MB, Madison JT, Webster WP, Penick GD: A clinical and experimental study of acquired inhibitors to Factor VIII. *Blood* 26:805-818, 1965
13. Ellis H, Handley DA, Taylor KB: Surgery in a patient with an acquired circulating anticoagulant. *Lancet* 1:1167-1170, 1959
14. Sise HS, Gauthier J, Desforges J, Becker R: Spontaneous circulating anticoagulant (antifactor VIII): case report and review of the literature. *Am J Med* 32:964-975, 1962
15. Shulman NR, Hirschman RJ: Factor VIII inhibitors in non-hemophiliacs, in Brinkhous KM (ed): *Hemophilia and New Hemorrhagic States*. Chapel Hill, Univ North Carolina Pr, 1970, p 169
16. Margolius A Jr, Jackson DP, Ratnoff OD: Circulating anticoagulants: a study of 40 cases and review of the literature. *Medicine (Baltimore)* 40:145-202, 1961
17. Hougie C: Studies on an acquired anticoagulant directed against Factor VIII. *J Lab Clin Med* 70:384-392, 1967
18. Horowitz HI, Fujimoto MM: Acquired hemophilia due to a circulating anticoagulant: report of two cases, with review of the literature. *Am J Med* 33:501-509, 1962
19. Edson JR, McArthur JR, McCullough JJ: Successful treatment of subdural hematoma in a hemophiliac with an anti-factor VIII antibody. *Third Congress of the International Society on Thrombosis and Haemostasis*, Washington D.C., August 22-26, 1972, p 86
20. Abildgaard CF, Britton M, Roberts R: Prothrombin complex concentrate (Konyne) for patients with Factor VIII inhibitors. *Blood* 44:933, 1974
21. Kurczynski EM, Penner JA: Activated prothrombin concentrate for patients with Factor VIII inhibitors. *N Engl J Med* 291:164-167, 1974
22. Bidwell E: Immunological aspects of haemophilia, in Biggs R, Macfarlane RG (eds): *Treatment of Haemophilia and Other Coagulation Disorders*. Oxford, Blackwell Scientific Publications, 1966, p 93
23. Masure R: Pseudo-hémophilie féminine acquise due à la présence d'un inhibiteur du facteur antihémophilique A. *Rev Belge Pathol Med Exp* 24:23-37, 1955
24. Knyvett AF: Haemorrhagic disease due to a circulating anticoagulant, with report of a case. *Australas Ann Med* 1:84-87, 1952
25. Henderson WMR: Treatment with cortisone of haemorrhagic disease due to a circulating anticoagulant. *Br Med J* 1:764-767, 1959
26. Hruby MA, Schulman I: Failure of combined Factor VIII and cyclophosphamide to suppress antibody to Factor VIII in hemophilia. *Blood* 42:919-923, 1973