
Traumatically acquired color vision defect

Rockefeller S. L. Young, Gerald A. Fishman, and Felix Chen

A 24-year-old man acquired a color vision defect shortly after an accident in which he struck the back of his head. Results of the Farnsworth-Munsell 100-hue test showed that the patient had poor color discrimination in both eyes. His color matches on the Nagel anomaloscope suggested a red/green disturbance. Results from increment threshold testing demonstrated an absence of the blue mechanism. Results of field sensitivity measurements confirmed that foveal vision was mediated by the red or green mechanism. This case showed both similarities and differences to previously reported cases of acquired color vision defects secondary to cortical trauma.

Key words: acquired color vision defect, Stile's mechanisms, cerebral lesion

Several types of color vision abnormalities can occur in humans. The least frequently reported are those secondary to damage of the occipital cortex. We saw a patient who acquired a color vision disturbance subsequent to head trauma. The patient had no prosopagnosia or visual field losses that have been previously associated with color disturbances of cortical origin,^{1, 2} nor did he show any abnormalities of the retina or optic nerve.

Case history

A 24-year-old railroad engineer was involved in a motorcycle accident. He was not wearing a helmet, and the back of his head struck the pavement. Approximately 1 week later, the patient noticed that red and green traffic signals appeared similar. Automobile brake lights looked distinctly darker than normal and appeared more brown or

gray than red. Two weeks after the accident, the patient was again examined. Visual acuity and skull x-rays were normal. Because of his abnormality on the Ishihara pseudoisochromatic plates, however, the patient was referred to us.

At the time of the psychophysical testing, visual acuity was found to be 20/20 in the right eye with a -1.5 sphere and 20/20 in the left eye with a -1.25 sphere. External examination and slit-lamp examination of the anterior chamber, lens, and vitreous were unremarkable. Applanation tensions were normal. Fundus examination showed no abnormalities of the discs, foveas, or retinal vessels. Visual field testing on the Goldmann perimeter showed normal peripheral boundaries with no evidence of scotomata to the 4-e-II test target. Specifically, there was no evidence of an altitudinal field defect. A review of the patient's past medical history showed that he had correctly identified all plates on the Ishihara color test as part of a pre-employment physical examination for the Chicago Transit Authority in 1975.

Methods and procedures

The Ishihara (38 plates, 1954) and the Farnsworth-Munsell 100-hue color discrimination tests were administered monocularly and under illumination from a Macbeth easel lamp. Color matches were assessed on the Nagel anomaloscope. The experimenter randomly set the red/green ratio (top field) and then required the patient to adjust the brightness of the yellow (bottom field) to

From the Department of Ophthalmology, University of Illinois Eye and Ear Infirmary, Chicago.

Supported in part by training grant EY 703802, Core Grant 1P30EY01792 from the National Eye Institute, National Institutes of Health, Bethesda, Md., and by a Manpower Award Grant from the Research to Prevent Blindness, Inc.

Submitted for publication March 12, 1979.

Reprint requests: R. S. L. Young, Illinois Eye and Ear Infirmary, 1855 W. Taylor, Chicago, Ill. 60612.

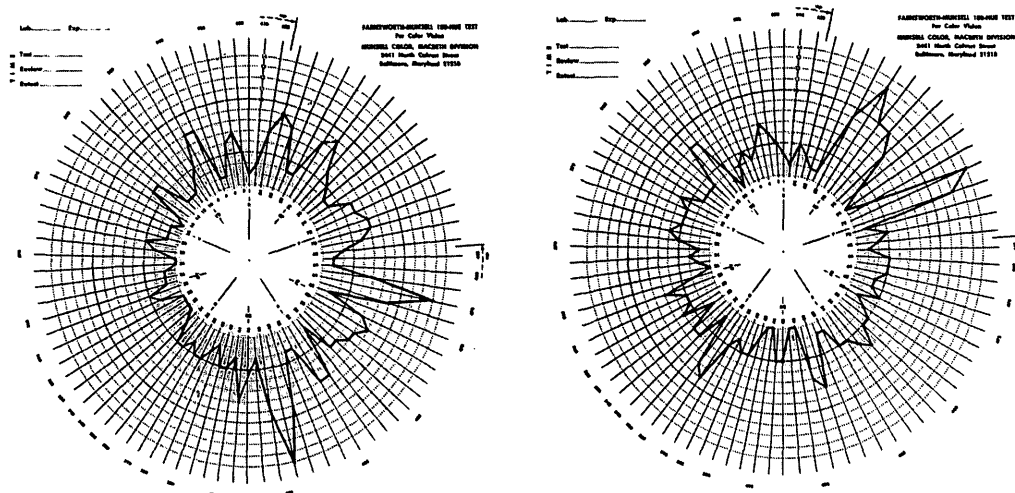


Fig. 1. Plot of patient's error scores on the Farnsworth-Munsell 100-hue test. Left and right plots correspond to patient's left and right eyes, respectively.

achieve a match. The patient was allowed as much time as needed.

Two-color increment thresholds were assessed on a three-channel Maxwellian view apparatus. The test field was a 200 msec flash of 0.85° subtense superimposed on a foveally fixated steady 8.5° disc. A red pinpoint source served as a fixation in the dark, and crosshairs on the background field served for fixation in bright light conditions. A biteboard was used to ensure accurate head and eye positioning. Prior to each session, the patient underwent dark adaptation for at least 10 min. Then the patient adapted to each background field condition for at least 1 min before making several threshold determinations. The thresholds were determined by a method of adjustment whereby the subject adjusted the test flash flux until it either "just disappeared" or "just appeared." The average of the two points was taken as his detection threshold.

In the field sensitivity experiment, either a 476 or 640 nm test flash was used. Prior to the experiment, the test flash was adjusted to 10 times the absolute threshold. The patient was required to raise the background flux slowly until the test flash just disappeared and just reappeared, a procedure similar to that described by Boynton et al.³ The reciprocal of the mean background determination was taken as the field sensitivity. These measurements were repeated for different field wavelengths and replicated a number of times.

Results

The patient identified the demonstration plate (i.e., the first plate) but was unable to identify the figures in most of the other Ishihara plates. On the diagnostic plates, he missed the figures that protan observers typically fail to identify. The results were identical in both eyes.

On the Farnsworth-Munsell 100-hue test, the patient scored 268 and 258 errors (left and right eyes, respectively). As shown in Fig. 1, the pattern of errors in either eye does not appear to show the characteristic protan-, deutan-, or tritan-type axis.⁴

The patient had difficulty in matching colors on the Nagel anomaloscope. But when encouraged, the patient could find a match for the different red/green setting tested (Fig. 2). A comparison with the mean color matches of five congenital protanopes and 11 deuteranopes illustrates how different the patient's settings were from those of congenital dichromats (or from extreme anomalous trichromats). Note that a straight line drawn through the match settings of any dichromat should pass near the normal trichromat's match (i.e., about 40,15). As shown by the dash line in the figure, the matches of this

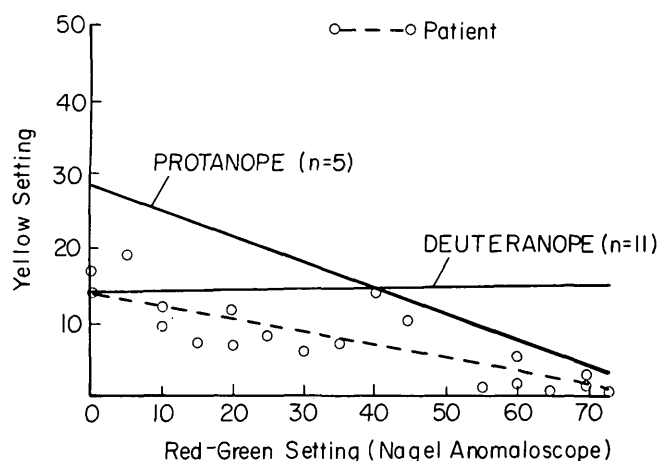


Fig. 2. Patient's color-matching settings on the Nagel anomaloscope. Solid lines illustrate the average color matches of five congenital protanopes and 11 congenital deuteranopes.

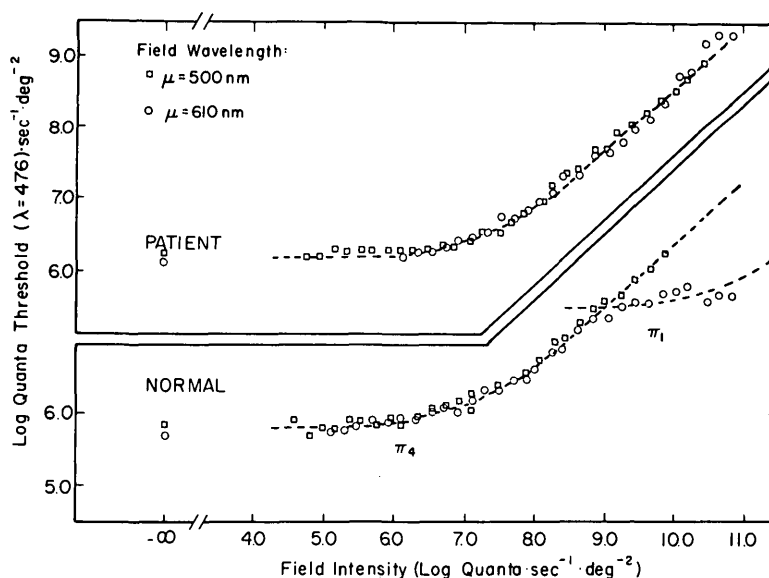


Fig. 3. Top, patients increment thresholds to a 476 nm test flash on a 500 or 610 nm background. Bottom, normal observer's increment thresholds obtained under comparable conditions. Dashes illustrate isolated cone thresholds as interpreted by Stiles.⁵

patient did not fulfill this requirement. His matches were perhaps better described by a nonlinear curve. It is also interesting that the patient's yellow settings appeared to decrease as the red/green setting was increased. This trend was consistent with the patient's subjective impression that "red objects now appear to be darker."

The results shown in Fig. 3 are the pa-

tient's increment thresholds to a 476 nm test flash on a 500 or 610 nm background. For comparison, the thresholds of a normal observer obtained under comparable conditions are also presented. For the normal observer, the 476 nm increment thresholds on successively brighter 500 nm background fields follow a monotonically increasing curve. On a 610 nm field, however, a discontinuity in the

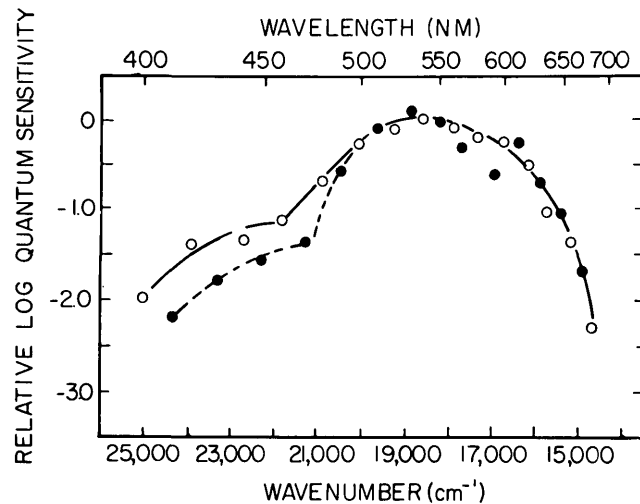


Fig. 4. Patient's relative field sensitivity assessed by a 476 nm (open circles) or by a 640 nm (closed circles) test flash. The relative differences between the 476 and 640 conditions are correctly shown in this figure. The data have not been shifted relative to one another.

curve appears near the threshold value of $7.3 \log \text{ quanta} \cdot \text{sec}^{-1} \cdot \text{deg}^{-2}$. In accordance with the interpretation of Stiles,⁵ the lower branch of the increment threshold curve for normal observers represents the green cone mechanism, whereas the upper branch represents the blue cone mechanism. Stiles⁵ reported that the mean ± 1 S.D. (for 20 observers) absolute threshold flux for the green mechanism was $5.85 \pm 0.29 \log \text{ quanta} \cdot \text{sec}^{-1} \cdot \text{deg}^{-2}$ and for the blue mechanism was 6.96 ± 0.35 .

The results of the patient's performance on this test are shown in Fig. 3. The incremental thresholds on the 500 nm field did not differ appreciably from the normal. However, on the 610 nm field there appeared to be no evidence of a blue mechanism branch. Because all of Stiles' 20 observers and all 11 normal observers tested so far in our laboratory revealed the blue mechanism branch, its absence in this patient must be regarded as highly unusual if he were normal. These results were replicated on the second day of testing, to ensure that they were not produced by chance nor by error on the part of the experiment.

The spectral sensitivity of the mechanism underlying the detection of the 476 nm flash was assessed by field sensitivity measure-

ments (Fig. 4). Clearly, these results show that the red or green—not the blue—cone mechanism mediated his ability to detect the 476 nm flashes. To differentiate between the red or green mechanism, the patient's field sensitivity to a 640 nm test flash was also assessed. The results for the 640 nm flash did not differ much from those for the 476 nm flash condition over red/green field wavelength conditions. For field wavelengths less than about 470 nm, it was clear that a difference existed, thereby indicating that more than one mechanism mediated his detection of the test flash.

Discussion

As shown by the results of the color discrimination tests, the patient has abnormally poor color discrimination. Color matches on the Nagel anomaloscope suggest a red/green disturbance. Results from the two-color increment threshold test reveal the absence of the blue mechanism. Results of the field sensitivity test confirm that his foveal vision is mediated by red, green, or both cone systems (although it is difficult to decide among these possibilities). Differences between the 476 and 640 nm field sensitivity curves, however, clearly rule out the possibility that the patient is a monochrome monochromat. In

short, our results indicate that the patient has some form of an incomplete color blindness.

The simplest explanation for this abnormality is that the patient acquired the color vision disturbance from trauma to his visual cortex. Three years prior to the accident the patient was color normal. He had no prior history of any visual disorder. It was shortly after the accident that the patient became aware of his problem. The pattern of his test results (errors on the Farnsworth-Munsell 100-hue test; red/green range on the Nagel anomaloscope; and loss of the blue cone mechanism) is consistent with the major perceptual findings in other patients with acquired cortical defects.^{1, 2, 6}

The absence of the blue mechanism on the increment threshold test rules out the possibility that the patient was simply malingering or that he has a congenital color vision trait. The patient had no knowledge of the instrument's calibration nor of the expected performance of an observer whose blue mechanism is missing. It is therefore very unlikely that the patient could totally disregard the sensations from his blue system and then be able to raise the test flux so precisely as to mimic the green (or red) mechanism. It is also unlikely that the patient has one of the congenital color deficiency traits. Patients with the protan or deutan traits do not exhibit an absence of the blue mechanism, and those with the tritan trait do not exhibit a red/green color disturbance.

Dysfunctions of the blue mechanism with or without red/green color disturbances are frequently associated with retinal diseases and disorders of the macula.^{7, 8} However, our clinical examination of the patient's fundi did not show any abnormalities. In addition, the patient had no other visual complaints other than the color disturbances. Interestingly, this patient did not exhibit the gross visual field loss that had been found in nearly all of the cases with a cerebral lesion reviewed by Meadows.¹ The patient denied (and also did not demonstrate) having any difficulty rec-

ognizing familiar faces or places, another symptom associated with color disturbance due to a cerebral lesion. So, does this abnormality stem from a cortical defect?

In the absence of objective brain scans, we can only speculate that the patient's abnormality arises from partial destruction of the chromatic mechanism. This is why he has a color disturbance and why brightness perception (and associated visual functions) is preserved. Accordingly, the apparent loss of his blue mechanism can be explained in terms of the residual achromatic mechanism. Brightness perception is probably mediated mainly by the red and green—not by the blue—cone mechanism.⁹

We are grateful to Drs. Siler and Peck of the Chicago Transit Authority for their cooperation. Morton F. Goldberg, M.D., and Maxine Gere provided valuable comments on the manuscript. Leticia Zemaitis and Victoria Vasquez provided technical assistance in the preparation of this paper.

REFERENCES

1. Meadows JC: Disturbed perception of colours associated with localized cerebral lesion. *Brain* 97:615, 1974.
2. Pearlman AL, Birch J, and Meadows JC: Cerebral color blindness: an acquired defect in hue discrimination. *Ann Neurol* 5:253, 1979.
3. Boynton RM, Das S, and Gardiner J: Interaction between photopic visual mechanisms revealed by mixing conditioning fields. *J Opt Soc Am* 56:1775, 1966.
4. Farnsworth D: The Farnsworth-Munsell 100-hue and dichotomous tests for color vision. *J Opt Soc Am* 33:568, 1963.
5. Stiles WS: Separation of the "blue" and "green" mechanisms of foveal vision by measurements of increment thresholds. *Proc R Soc Lond (Biol)* 133:418, 1946.
6. Birch J: A case of acquired tritanopia. *Mod Probl Ophthalmol* 17:325, 1976.
7. Pearlman JT, Owen WC, Brounley DW, and Sheppard JJ: Cone dystrophy with dominant inheritance. *Am J Ophthalmol* 77:293, 1974.
8. Sandberg MA and Berson EL: Blue and green cone mechanisms in retinitis pigmentosa. *INVEST OPHTHALMOL VISUAL SCI* 16:149, 1977.
9. Whittle P: The brightness of coloured flashes on backgrounds of various colours and luminances. *Vision Res* 13:621, 1973.