

# Phase I Trial of Intravenous Oncolytic Vaccinia Virus (GL-ONC1) with Cisplatin and Radiotherapy in Patients with Locoregionally Advanced Head and Neck Carcinoma



Loren K. Mell<sup>1</sup>, Kevin T. Brumund<sup>2</sup>, Gregory A. Daniels<sup>3</sup>, Sunil J. Advani<sup>1</sup>, Kaveh Zakeri<sup>1</sup>, Mary E. Wright<sup>1</sup>, Sara-Jane Onyeama<sup>1</sup>, Robert A. Weisman<sup>2</sup>, Parag R. Sanghvi<sup>1</sup>, Peter J. Martin<sup>4</sup>, and Aladar A. Szalay<sup>1</sup>

## Abstract

**Purpose:** Preclinical models have shown that the effectiveness of GL-ONC1, a modified oncolytic vaccinia virus, is enhanced by radiation and chemotherapy. The purpose of this study was to determine the safety of GL-ONC1 when delivered intravenously with chemoradiotherapy to patients with primary, nonmetastatic head and neck cancer.

**Experimental Design:** Patients with locoregionally advanced unresected, nonmetastatic carcinoma of the head/neck, excluding stage III–IVA p16-positive oropharyngeal cancers, were treated with escalating doses and cycles of intravenous GL-ONC1, along with radiotherapy and chemotherapy. The primary aims were to define the MTD and dose-limiting toxicities, and to recommend a dose for phase II trials.

**Results:** Between May 2012 and December 2014, 19 patients were enrolled. The most frequent adverse reactions included grade

1–2 rigors, fever, fatigue, and rash. Grade 3 adverse reactions included hypotension, mucositis, nausea, and vomiting. In 2 patients, the rash was confirmed as viral in origin by fluorescence imaging and viral plaque assay. In 4 patients, viral presence in tumor was confirmed on midtreatment biopsy by quantitative PCR. In 1 patient, live virus was confirmed in a tongue tumor 7 days after receiving the first dose of virus. The MTD was not reached. With median follow-up of 30 months, 1-year (2-year) progression-free survival and overall survival were 74.4% (64.1%) and 84.6% (69.2%), respectively.

**Conclusions:** Delivery of GL-ONC1 is safe and feasible in patients with locoregionally advanced head/neck cancer undergoing standard chemoradiotherapy. A phase II study is warranted to further investigate this novel treatment strategy. *Clin Cancer Res*; 23(19): 5696–702. ©2017 AACR.

## Introduction

Squamous cell head and neck cancer is a major cause of morbidity and mortality, affecting over 40,000 patients per year in the United States. For patients with locoregionally advanced disease, multimodality therapy with chemotherapy and radiotherapy improves organ preservation and survival, although long-term disease-free survival is often below 50% (1–5). Patients with tumors negative for human papillomavirus (HPV) have particu-

larly worse outcomes, with 3-year overall survival less than 60% (6). Therefore, novel treatment strategies in conjunction with standard therapy are needed to improve disease control and survival.

Oncolytic viruses represent a promising gene therapy strategy to treat cancer. Vaccinia is a virus in the poxvirus family that has been used as a vaccine for smallpox and has also been found to have independent oncolytic activity. Because of its long history of use in humans and favorable safety profile, vaccinia may be more desirable than other classes of oncolytic viruses. Previous preclinical and early clinical studies of recombinant poxviruses have shown safety and potential efficacy of this treatment approach (7–9).

GL-ONC1 is a genetically engineered oncolytic vaccinia virus (VACV) developed as a novel class of immunotherapeutic agent for cancer therapy (7, 10–12). Preclinical studies of GL-ONC1 have demonstrated independent oncolytic efficacy in a wide range of tumor types in both *in vitro* and *in vivo* models (11–16). The cytotoxic effect of GL-ONC1 is also enhanced when combined with radiation or chemotherapy. In preclinical studies (17), the addition of radiation or chemotherapy to GL-ONC1 resulted in enhanced cell kill and increased viral replication in irradiated tumors (17–22). In particular, viral infection increases the S-phase and sub-G<sub>1</sub> cells and induces apoptosis via activated caspase-3/7 (19). Furthermore, it has been shown that the combination of

<sup>1</sup>Center for Translational Radiation Medicine and Imaging, Department of Radiation Medicine and Applied Sciences, University of California San Diego, La Jolla, California. <sup>2</sup>Department of Surgery, Division of Otolaryngology-Head and Neck Surgery, University of California San Diego, La Jolla, California. <sup>3</sup>Center for Personalized Cancer Therapy, and Division of Hematology and Oncology, UCSD Moores Cancer Center, La Jolla, California. <sup>4</sup>Department of Otolaryngology, Kaiser Permanente, San Diego, California.

**Note:** Prior presentation: This study was presented at the 2015 Annual American Society for Clinical Oncology Meeting (ASCO; Chicago, IL).

**Corresponding Author:** Loren K. Mell, Department of Radiation Medicine and Applied Sciences, University of California San Diego, 3855 Health Sciences Drive, MC0843, La Jolla, CA 92093. Phone: 858-246-0471; Fax: 858-822-5568; E-mail: lmell@ucsd.edu

**doi:** 10.1158/1078-0432.CCR-16-3232

©2017 American Association for Cancer Research.

### Translational Relevance

Oncolytic viruses are a novel treatment strategy for improving disease control and survival in cancer patients. This is the first prospective clinical trial of intravenous viral therapy with standard chemoradiation for definitive treatment of locally advanced head and neck cancer. A novel aspect of this study is that viral therapy was delivered as an intravenous infusion, which simplifies the delivery of virus compared with intratumoral injections. Administration of GL-ONC1 was well tolerated and feasible with favorable results compared with historical controls. This study adds to the growing evidence supporting the use of oncolytic viruses to treat malignancies.

radiation with genetically modified vaccinia increases cytotoxicity and apoptosis due to attenuation of the JNK pathway and ERK MAPK phosphorylation in BRAF-mutant melanoma cells (20). These studies support the hypothesis that the oncolytic effects of vaccinia could be enhanced in the presence of chemoradiotherapy.

GL-ONC1 has been clinically tested as a single agent for systemic or regional delivery but has never been tested in combination with concurrent chemotherapy or radiotherapy. The purpose of this phase I study was to determine the MTD and safety of GL-ONC1 when delivered intravenously with concurrent chemoradiotherapy to patients with primary, nonmetastatic head and neck cancer.

## Materials and Methods

### Study design and patient population

This study was a single-institution phase I dose escalation clinical trial of GL-ONC1 in patients receiving concurrent chemoradiotherapy for locoregionally advanced head and neck cancer. The primary endpoint was to determine the MTD of GL-ONC1 and the dose-limiting toxicities (DLT). Secondary endpoints included the susceptibility of tumor to viral infection in cell culture, tumor tissue analysis for the presence of virus after GL-ONC1 administration using qPCR and/or viral plaque assay (VPA), and to analyze therapeutic outcomes, including tumor response, progression-free survival (PFS), and overall survival (OS).

Patients were eligible for enrollment if they had newly diagnosed, biopsy-proven, unresected stage III-IVB primary head and neck carcinoma, excluding p16-positive stage III-IVA (AJCC 7th edition) oropharyngeal cancer. Patients with p16-positive non-oropharyngeal cancer or stage IVB oropharyngeal cancer (p16 positive or p16 negative) were eligible. All patients were treated with definitive intent, not postoperatively. All patients with primaries of the salivary gland, paranasal sinus, and oral cavity had unresectable disease based on skull base or base of tongue involvement. Patients were required to be 18 years or older and have an Eastern Cooperative Oncology Group (ECOG) performance status  $\leq 2$ . Laboratory requirements for enrollment included absolute neutrophil count  $\geq 1,800$  cells/mm<sup>3</sup>; platelets  $\geq 100,000$  cells/mm<sup>3</sup>; hemoglobin  $\geq 8.0$  g/dL; bilirubin  $\leq 1.5$  mg/dL; liver enzymes  $\leq$  twice the upper limit of normal; serum creatinine  $\leq 1.5$  mg/dL; and international normalized ratio  $< 1.5$ .

Patients were ineligible if they had evidence of metastatic disease, any prior anticancer treatments (e.g., chemotherapy,

radiation, or surgery), or any active immunosuppressive systemic infection, including HIV, AIDS, and hepatitis B or C. In addition, patients were excluded if they were on immunosuppressive therapy or had immune disorders, such as autoimmune disease, including clinically significant dermatologic disorders (e.g., eczema or psoriasis). Prior splenectomy, previous organ transplantation, and prior gene therapy or virus treatments were also grounds for exclusion.

The study was sponsored by Genelux and was registered at ClinicalTrials.gov (NCT01584284). It was conducted in accordance with recognized ethical guidelines (Declaration of Helsinki) and was approved by the University of California San Diego Institutional Review Board. Written informed consent was obtained for all patients.

### Treatment details

Patients received GL-ONC1 as an intravenous infusion with concurrent chemotherapy and radiation. The dose of GL-ONC1 was escalated in each cohort as follows: GL-ONC1 was administered as a single treatment on day 3 in cohort 1 at  $3 \times 10^8$  plaque-forming units (pfu); cohort 2 at  $1 \times 10^9$  pfu, and cohort 3 at  $3 \times 10^9$  pfu. In cohort 4, GL-ONC1 was administered at the same dose as cohort 3 ( $3 \times 10^9$  pfu) on days 3 and 8. The number of GL-ONC1 treatments was increased to 4 doses in cohort 5 (days 3, 8, 15, and 22) at the same dose level as cohorts 3 and 4.

Intensity-modulated radiotherapy was delivered with a prescription dose of 70 Gy to gross tumor in 33 to 35 fractions daily with 5 fractions per week. Additional high risk and standard risk clinical treatment volumes received doses of 59 to 66 Gy and 50 to 54 Gy, respectively. Concurrent chemotherapy consisted of cisplatin dosed at 100 mg/m<sup>2</sup> given on days 1, 22, and 43. Repeat head and neck CT was obtained during weeks 3 to 5 of treatment to reoptimize the radiation treatment plan in response to tumor changes or weight loss. Dose modifications and indications for holding cycles of cisplatin included neutropenia, thrombocytopenia, poor renal function, and grade 3 or higher nausea, neurotoxicity, or mucositis.

### Safety and DLT

The safety profile of GL-ONC1 was assessed by the type, frequency, and severity of adverse events (AE) and serious adverse events (SAE). Changes in laboratory values, immunogenicity, and physical examination were also incorporated into the safety evaluation. DLT was defined as grade  $\geq 4$  toxicity or grade  $\geq 3$  mucositis or skin reaction in the radiation field persisting  $> 6$  weeks after completion of therapy. All AEs and SAEs were graded using the Common Terminology Criteria for Adverse Events (CTCAE) Version 4.0. AEs and SAEs were assessed weekly during treatment and at posttreatment follow-up visits at weeks 11, 15, and 23. Toxicity results are presented without regard to whether they were felt to be attributable to the experimental therapy. For assessment of viral shedding, patients had VPA titer testing from oral swab and urine samples within 1 to 2 weeks following administration of the GL-ONC1 virus. After the study phase, patients were followed per routine standards of care. Long-term follow up for PFS and OS continued for 3 years.

### Antitumor and efficacy assessments

Within 4 weeks before beginning therapy, a diagnostic CT, MRI, or PET/CT of the tumor was obtained. Posttreatment diagnostic

CT scans of the neck and chest were obtained at week 15, and diagnostic PET/CT was obtained at week 23.

### Translational analyses

In patients with accessible tumors who consented for an additional biopsy, tissue was obtained for cell culture sensitivity to GL-ONC1 and other vaccinia virus within 4 weeks prior to beginning treatment. In addition, a tumor biopsy was obtained from consenting patients during weeks 2 or 3 of therapy after receipt of the GL-ONC1 virus to measure the presence of virus using qPCR and/or VPA.

To assess the sensitivity of tumor tissue to GL-ONC1 infection, baseline biopsy tissue was infected *ex vivo* with vaccinia virus strain GLV-1h68. GLV-1h68 is the laboratory strain of GL-ONC1 and contains three expression cassettes encoding for the biomarker genes for a *Renilla* luciferase-GFP fusion protein,  $\beta$ -galactosidase and  $\beta$ -glucuronidase, respectively, which are expressed upon successful replication of the virus (13). Briefly, tumor tissue was weighed, cut into smaller pieces of 1 mm<sup>3</sup> or less, transferred to cell culture inserts in culture plates containing DMEM supplemented with 2% FBS and 1% antibiotics-antimycotics (Invitrogen Corporation), and infected with  $1 \times 10^5$  pfu/mg tissue of GLV-1h68. Culture media were replaced after 2 hours and plates incubated at 37°C and 5% CO<sub>2</sub> for 72 hours. Tumor tissue was then evaluated for GFP expression, harvested, and analyzed by standard plaque assay on CV-1 cells (ATCC #CCL 70) to determine viral titer. In addition, the supernatant was tested for *Escherichia coli* (*E. coli*)  $\beta$ -glucuronidase activity according to the published method (19). Briefly, supernatant was serially diluted and incubated with 4-methylumbelliferyl  $\beta$ -D-glucuronidase (MUGlcU) substrate in Costar 384-well plates (Corning Life Sciences) for 1 hour at 37°C. Fluorescence was read at an excitation wavelength of 365 nm and emission wavelength of 455 nm using a Spectra Max M5 (Molecular Devices).  $\beta$ -Glucuronidase activity was calculated using an *E. coli*  $\beta$ -glucuronidase standard with defined enzymatic activity and reported as pg/mg tissue.

To determine the presence of viral DNA in tumor tissue samples, DNA was isolated using the QIAGEN DNeasy Tissue Kit (Qiagen). DNA was analyzed with Real-time qPCR Kit (Genelux proprietary, custom-made with A21L-specific primers by MicroCoat Biotechnologie GmbH) for the detection of vaccinia virus A21L gene using a LightCycler instrument (Roche Diagnostics GmbH). Data were reported as copies/mg tissue. Live virus was analyzed on the basis of standard VPA.

Urine, oral swabs, and lesion or rash swabs were evaluated by VPA to determine the extent of viral shedding posttreatment with GL-ONC1. Briefly, urine and swab samples were diluted in culture media and used to infect CV-1 cells (ATCC #CCL 70) by standard viral plaque assay to determine the viral load in the shedding samples.

### Statistical analyses

A 3 + 3 design was employed with cohorts of 3 to 6 patients enrolled at each dose level until the MTD was reached or the study concluded. The final sample size was dependent on observed toxicities. Statistical analysis of tumor response and time-to-event analyses was conducted in R. Time-to-event outcomes were estimated using the Kaplan–Meier method.

**Table 1.** Patient and tumor characteristics

	<b>Subjects = 19</b>
Age in years, mean (range)	56.0 (23–77)
Gender, n (%)	
Male	18 (94.7)
Female	1 (5.3)
Race, n (%)	
Caucasian	16 (84.2)
Black	2 (10.5)
Other	1 (5.3)
ECOG <sup>a</sup> performance status, n (%)	
0	8 (42.1)
1	10 (52.6)
2	1 (5.3)
Stage, n (%)	
Stage IVA	14 (73.7)
Stage IVB	5 (26.3)
Tumor site	
Oral cavity	2
Oropharynx	4
Salivary gland	1
Paranasal sinus	1
Nasopharynx	1
Hypopharynx	3
Supraglottis	3
Glottis	1
Carcinoma of unknown primary	3
p16 positive, n (%)	5 (26.3)

<sup>a</sup>As published in Am J Clin Oncol: Oken MM, Creech RH, Tormey DC, Horton J, Davis TE, McFadden ET, Carbone PP: Toxicity and response criteria of the Eastern Cooperative Oncology Group. Am J Clin Oncol 1982;5:649–55.

## Results

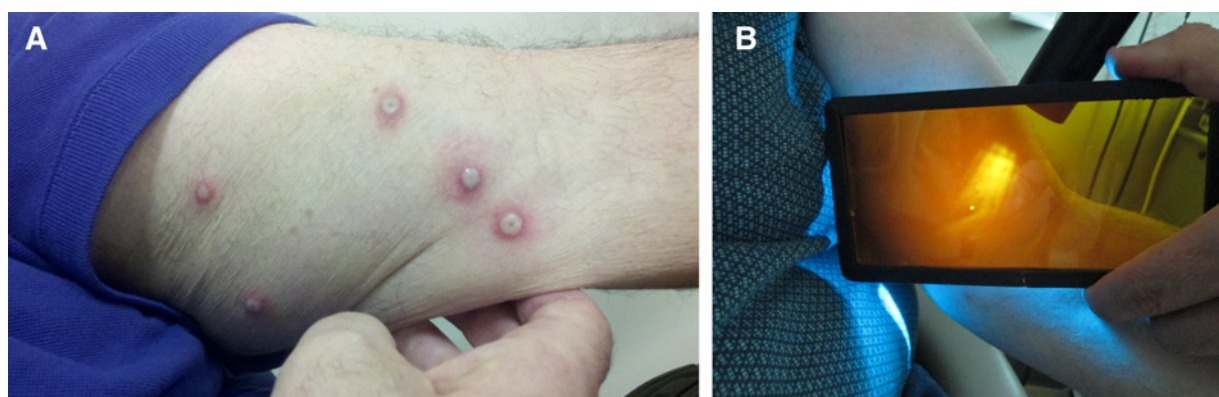
### Study sample

Between May 2012 and December 2014, 24 patients were consented, and 19 eligible stage IV patients were enrolled in the study. The reasons for screen failures included ECOG performance status of 3 ( $n = 1$ ), p16-positive oropharynx cancer ( $n = 1$ ), metastatic disease at presentation ( $n = 1$ ), infection ( $n = 1$ ), and noncompliance with screening laboratories ( $n = 1$ ). The mean age of the cohort was 56.0 years. The majority of patients were male, Caucasian, with good baseline performance status (ECOG 0 or 1), and had p16-negative, stage IVA tumors (Table 1).

### Safety and toxicity

This section includes safety data reported up to the date of manuscript submission. The most commonly reported adverse reactions considered related to GL-ONC1 were rigors, pyrexia, fatigue, hypotension, nausea, vomiting, and rash and pox-like lesions (Fig. 1A and B). Fluorescence imaging and VPA were used to confirm the viral origin of rash in 2 patients. Other common toxicities considered related to standard therapy were mucositis, dysphagia, thrombocytopenia, and radiation dermatitis (Table 2). There were no grade 4 acute toxicities considered related to GL-ONC1 (Table 2). One diabetic patient developed grade 4 hypoglycemia. The median treatment duration was 50 days (range, 42–66). One patient received 32 of 33 planned fractions; all others completed the entire course.

The MTD of GLONC-1 was not reached in this trial. One patient in cohort 4 experienced a myocardial infarction, which, according to the protocol at the time of the event, was considered a DLT, although this event was considered unlikely related to the



**Figure 1.**

**A,** Transient pox-like rash confirming systemic viral delivery. **B,** Transient rash confirmed as viral in origin by VPA and fluorescence imaging.

experimental therapy. Per protocol requirements, the sample size was expanded in this cohort to 6 patients. DLTs were not reported in cohort 5 where patients received 4 weekly bolus intravenous infusions of GL-ONC1 at  $3 \times 10^9$  pfu concurrently with chemoradiation treatment.

Fifteen patients received 3 cycles of cisplatin, and 4 patients received 2 cycles of cisplatin. There was no correlation between cycles of cisplatin and increasing dose of GL-ONC1. One patient each in cohorts 1, 2, 3, and 4 received two cycles of cisplatin. All patients in cohort 5 tolerated 3 cycles of cisplatin. Reasons for held cycles of cisplatin included poor renal function, neutropenia, and nausea/emesis.

#### Viral shedding and replication

The analysis of urine and oral swabs showed no viral shedding in any patients 1 to 2 days postinfusion of GL-ONC1. Skin rashes were found positive for virus by standard plaque assay in 2 patients, one of which was found to be GFP positive. Viral infection of tumor tissue was confirmed through qPCR of viral DNA or by viral plaque assay in 5 patients. In 4 patients, viral presence in tumor was confirmed on midtreatment biopsy by qPCR for A21L gene (Table 3). However, it should be noted that recovery of viral DNA (in the absence of evidence of the virus being replication competent) is not sufficient to conclude that the virus is biologically active.

**Table 2.** Most frequently reported AEs (regardless of attribution to GL-ONC1)

Event	Grade				Total/AE	% of sample
	1	2	3	4		
Rigors <sup>a</sup>	2	11	0	0	13	68
Pyrexia <sup>a</sup>	5	5	0	0	10	53
Fatigue <sup>a</sup>	8	9	0	0	17	89
Hypotension <sup>a</sup>	3	2	2	0	7	37
Nausea <sup>a</sup>	8	7	2	0	17	89
Vomiting <sup>a</sup>	4	2	2	0	8	42
Rash <sup>a</sup>	6	1	0	0	7	37
Chills <sup>a</sup>	4	0	0	0	4	21
Flushing	4	0	0	0	4	21
Mucositis	0	7	11	0	18	95
Dysphagia	2	8	6	0	16	84
Thrombocytopenia	1	5	1	1	8	42
Radiation dermatitis	10	9	0	0	19	100

<sup>a</sup>Expected toxicity for GL-ONC1.

In addition, live GL-ONC1 virus ( $2.9 \times 10^3$  pfu) was detected in a swab of a tumor lesion on the tongue of one patient in cohort 5 7 days after receiving the first dose of virus. Tumor susceptibility to viral infection *ex vivo* was confirmed in 11 of 13 patients, as indicated by positive readings for VPA, GFP, or  $\beta$ -glucuronidase activity (Table 4). In 7 of 13 patients, the viral titers of the infected tumor tissues by VPA were not defined (ND). A nondefined viral titer was not indicative of tumor tissue not being susceptible to the virus infection, as some of the ND tumor tissue samples demonstrated strong positive readings for GFP and/or  $\beta$ -glucuronidase activity. The *ex vivo* viral titer was presented as the titer above the medium control, which was the titer of the same amount of virus after 3 days of incubation in the culture medium. The interference from tissue matrix can lead to a false-negative result or an underestimation of the amount of virus. GL-ONC1 replication in the tumor tissues was confirmed in 9 patients by  $\beta$ -glucuronidase assay with 4 patients not tested. The  $\beta$ -glucuronidase assay appeared to be the most sensitive and least prone to the matrix effect among the three methods in detecting active viral infection *ex vivo*.

#### Treatment outcomes

With median follow-up of 30 months, there were 7 treatment failures and 7 deaths. Of the 7 treatment failures, 3 were locoregional, 3 were distant, and 1 was both local and distant. Of the 7 deaths (all unrelated to GL-ONC1 treatment), 5 were due to progression of the head and neck cancer, 1 was due to a second primary cancer of gastrointestinal origin, and 1 was due to non-cancer causes. Posttreatment PET/CT was obtained at 4 months in 18 patients; 1 patient died 3 months posttreatment. PET/CT was negative in 11 patients, showed partial response in 4 patients, and was positive in 3 patients.

PFS estimates at 1 and 2 years were 74.4% [95% confidence interval (CI), 57.3–96.5] and 64.1% (95% CI, 46.0–89.4), respectively (Fig. 2). OS estimates at 1 and 2 years were 84.6% (95% CI, 70.0–100.0) and 69.2% (95% CI, 51.5–93.1), respectively (Fig. 3). All treatment failures and deaths occurred in the 14 patients with p16-negative tumors. The 5 patients with p16-positive tumors were all alive and free of disease with median follow-up of 36 months. PFS estimates at 1 and 2 years for patients with p16-negative tumors were 65.5% (95% CI, 45.1–95.2) and 51.8% (95% CI, 31.5–85.0), respectively. OS estimates at 1 and 2 years

**Table 3.** Viral infection of tumors confirmed by qPCR

Cohort	Dose	Patient	Tumor location	Virus treatment(s)	Time of biopsy	qPCR results (copies/mg)
2	1 × 10 <sup>9</sup> pfu	507	Oropharynx	W1 D3	W2 D5	174
3	3 × 10 <sup>9</sup> pfu	510	Hypopharynx	W1 D3	W3 D3	4
		512	Larynx	W1 D3	W3 D2	409
4	3 × 10 <sup>9</sup> pfu 2x	516	Oropharynx	W1 D3 & W2 D1	W3 D2	10

Abbreviations: D, day; W, week.

for patients with p16-negative tumors were 79.3% (95% CI, 61.0–100.0) and 58.6% (95% CI, 38.1–90.3), respectively.

## Discussion

A novel aspect of our study is that GL-ONC1 was delivered as an intravenous infusion, which allows for a less complicated systemic delivery of virus as compared with intratumoral injections. In addition, GL-ONC1 was investigated in combination with concurrent chemoradiotherapy for locally advanced head and neck cancer (i.e., against a highly toxic standard treatment backbone). We found that intravenous administration of GL-ONC1 was well tolerated in single and multiple escalating doses and was feasible in patients receiving standard chemoradiotherapy, which is consistent with the results of other clinical trials investigating oncolytic viruses (8, 9, 23, 24). The results of this trial also suggest that GL-ONC1 may be a feasible treatment option with less toxic standard treatment approaches, such as concurrent radiation alone, or as monotherapy in a neoadjuvant or adjuvant treatment setting.

Our study of GL-ONC1 adds to the growing evidence supporting the use of oncolytic viruses to treat malignancies. Oncolytic viruses have numerous potential mechanisms of direct oncolysis and immune-mediated tumor destruction. Preclinical evidence indicates that viral therapies can have a direct oncolytic effect on tumor cells. In addition, oncolytic viruses can improve tumor regression when combined with radiation and chemotherapy (19–22). Replication of viruses in tumor cells can also elicit a beneficial immune response, representing a novel avenue of oncolysis (25). Oncolytic viruses can also be engineered to stimulate antitumor immunity. Interestingly, an oncolytic HSV-1 encoding GM-CSF has demonstrated efficacy in melanoma patients (26).

Altogether, these findings argue for further investigation of oncolytic viruses in phase II and III clinical trials. Notably, our outcomes in p16-negative patients compare favorably with results from Ang and colleagues (6), despite the inclusion of nonoropharynx patients with exclusively stage IV tumors. However, our sample was quite small, precluding any meaningful conclusions regarding the efficacy of GL-ONC1 in this setting, which await testing in later phase randomized trials. Potential strategies include combining oncolytic viruses with chemoradiation for patients with HPV-negative head and neck cancer, given the aggressiveness and poor prognosis of these tumors. Viral therapy also has potential as a replacement for conventional cytotoxic chemotherapy (e.g., cisplatin) for patients with favorable tumors. Further study of oncolytic viruses is needed to improve the delivery and effectiveness of this treatment strategy.

There are several immunologic challenges and potential limitations to the use of oncolytic viruses in clinical practice. Innate immunity and complement may impede delivery of oncolytic viruses, especially with the intravenous approach (27). However, transportation by cells may also protect virus during intravenous delivery, despite the presence of neutralizing antibodies prior to infusion (28). The role of adaptive immunity in limiting the benefit of repeated administrations of virus is unknown and requires additional study. Coadministration of viruses with immunotherapies, especially complement-binding agents, may maximize the benefit of oncolytic viruses. Oncolytic viral therapy also has a unique toxicity profile, including fevers, rigors, and pox-like rash. We excluded patients in this study who had active immunosuppressive infections, were on immunosuppressive therapy, or had clinically significant autoimmune disorders. The efficacy and toxicity of viral therapies in these patients is unknown.

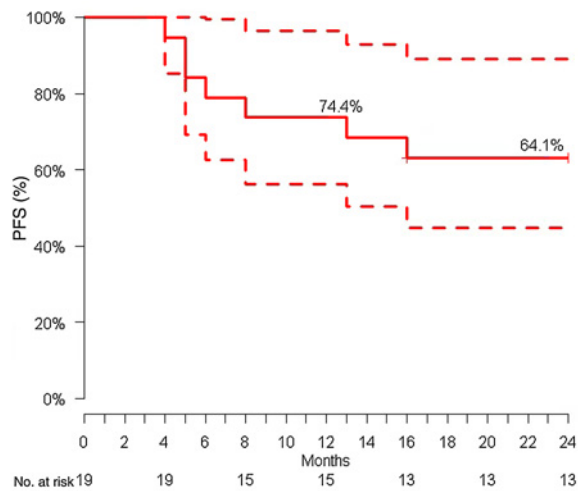
In conclusion, GL-ONC1 delivered as an intravenous infusion with concurrent radiation and chemotherapy was well tolerated in

**Table 4.** *Ex vivo* susceptibility of baseline tumor tissue biopsies to GL-ONC1 infection

Cohort	Dose	Patient	GLV-1h68 (i.e., GL-ONC1)		
			Average titer (pfu/mg)	GFP	Average β-gluc (pg/mg)
1	3 × 10 <sup>8</sup> pfu	501	1.49 × 10 <sup>4</sup>	+	ND
		502 <sup>a</sup>	ND <sup>b</sup>	+++	4.75 × 10 <sup>4</sup>
		503	9.02 × 10 <sup>3</sup>	++	ND
3	3 × 10 <sup>9</sup> pfu	510	ND	+	4.48 × 10 <sup>4</sup> ± 7.75 × 10 <sup>4</sup>
		512	ND	+	1.20 × 10 <sup>6</sup> ± 1.67 × 10 <sup>6</sup>
4	3 × 10 <sup>9</sup> pfu 2x	514 <sup>b</sup>	3.72 × 10 <sup>4</sup> ± 1.44 × 10 <sup>4</sup>	+	2.40 × 10 <sup>5</sup> ± 3.34 × 10 <sup>5</sup>
		515 <sup>a</sup>	2.56 × 10 <sup>4</sup> ± 7.71 × 10 <sup>3</sup>	+	2.02 × 10 <sup>3</sup> ± 1.31 × 10 <sup>3</sup>
		516	ND	–	8.73 × 10 <sup>3</sup> ± 7.35 × 10 <sup>2</sup>
		517 <sup>a</sup>	5.10 × 10 <sup>4</sup> ± 1.17 × 10 <sup>4</sup>	++	6.93 × 10 <sup>2</sup> ± 5.47 × 10 <sup>2</sup>
		518	3.40 × 10 <sup>4</sup> ± 5.37 × 10 <sup>3</sup>	+	3.79 × 10 <sup>4</sup> ± 2.84 × 10 <sup>4</sup>
5	3 × 10 <sup>9</sup> pfu 4x	521	ND	–	1.26 × 10 <sup>5</sup> ± 1.12 × 10 <sup>5</sup>

<sup>a</sup>Fine needle aspiration samples.

<sup>b</sup>Cells were cultured for 5 passages before the infection was performed.



**Figure 2.**  
Kaplan-Meier plot of PFS.

patients with locally advanced head and neck cancer. Viral infection of tumor tissues by intravenously delivering GL-ONC1 was confirmed by qPCR and/or VPA. Favorable results in terms of PFS and OS were observed with GL-ONC1 treatment as compared with historical data, within the limitations of a small sample size. This is the first clinical trial of intravenous viral therapy with standard concurrent chemoradiotherapy for the definitive treatment of head and neck cancer. Further investigation of this novel treatment strategy is warranted.

#### Disclosure of Potential Conflicts of Interest

L.K. Mell reports receiving commercial research grants from Merck and speakers bureau honoraria from Bristol-Myers Squibb and Pfizer, and is a consultant/advisory board member for Pfizer. No potential conflicts of interest were disclosed by the other authors.

#### Disclaimer

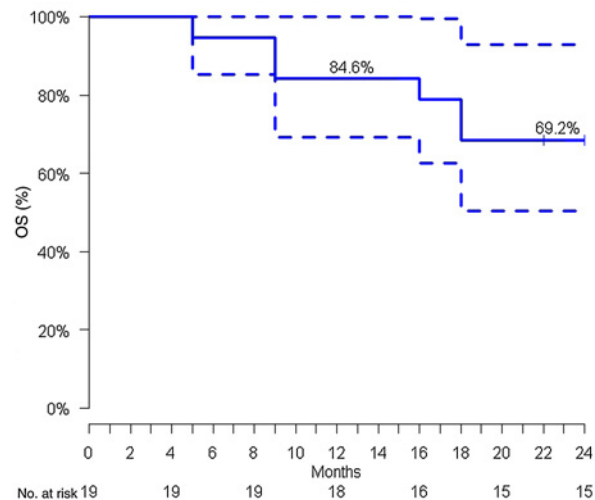
The data published here may change upon final closure of clinical database. The contents of this article are the sole responsibility of the authors and do not necessarily represent the official views of the sponsors.

#### Authors' Contributions

**Conception and design:** L.K. Mell, S.J. Advani, P.J. Martin, A.A. Szalay  
**Development of methodology:** L.K. Mell, S.-J. Onyeama, A.A. Szalay

#### References

- Bonner JA, Harari PM, Giralt J, Azarnia N, Shin DM, Cohen RB, et al. Radiotherapy plus cetuximab for squamous-cell carcinoma of the head and neck. *N Engl J Med* 2006;354:567–78.
- Posner MR, Hershock DM, Blajman CR, Mickiewicz E, Winquist E, Gorbounova V, et al. Cisplatin and fluorouracil alone or with docetaxel in head and neck cancer. *N Engl J Med* 2007;357:1705–15.
- Vermorken JB, Remenar E, van Herpen C, Gorlia T, Mesia R, Degardin M, et al. Cisplatin, fluorouracil, and docetaxel in unresectable head and neck cancer. *N Engl J Med* 2007;357:1695–704.
- Forastiere AA, Goepfert H, Maor M, Pajak TF, Weber R, Morrison W, et al. Concurrent chemotherapy and radiotherapy for organ preservation in advanced laryngeal cancer. *N Engl J Med* 2003;349:2091–8.



**Figure 3.**  
Kaplan-Meier plot of OS.

**Acquisition of data (provided animals, acquired and managed patients, provided facilities, etc.):** L.K. Mell, K.T. Brumund, G.A. Daniels, M.E. Wright, S.-J. Onyeama, R.A. Weisman, P.R. Sanghvi, P.J. Martin, A.A. Szalay  
**Analysis and interpretation of data (e.g., statistical analysis, biostatistics, computational analysis):** L.K. Mell, K. Zakeri  
**Writing, review, and/or revision of the manuscript:** L.K. Mell, K.T. Brumund, S.J. Advani, K. Zakeri, R.A. Weisman, A.A. Szalay  
**Administrative, technical, or material support (i.e., reporting or organizing data, constructing databases):** L.K. Mell, M.E. Wright, S.-J. Onyeama, A.A. Szalay  
**Study supervision:** L.K. Mell, K.T. Brumund, P.J. Martin, A.A. Szalay

#### Acknowledgments

The authors thank all staff from Genelux for their scientific input, laboratory analytic services, and clinical support for this trial.

#### Grant Support

This study was supported by Genelux Corporation.  
The costs of publication of this article were defrayed in part by the payment of page charges. This article must therefore be hereby marked *advertisement* in accordance with 18 U.S.C. Section 1734 solely to indicate this fact.

Received December 23, 2016; revised March 21, 2017; accepted June 27, 2017; published OnlineFirst July 5, 2017.

8. Gomella LG, Mastrangelo MJ, McCue PA, Maguire HC JR, Mulholland SG, Lattime EC. Phase I study of intravesical vaccinia virus as a vector for gene therapy of bladder cancer. *J Urol* 2001;166:1291–5.
9. Liu TC, Hwang T, Park BH, Bell J, Kim DH. The targeted oncolytic poxvirus JX-594 demonstrates antitumoral, antivascular, and anti-HBV activities in patients with hepatocellular carcinoma. *Mol Ther* 2008;16:1637–42.
10. Park BH, Hwang T, Liu TC, Sze DY, Kim JS, Kwon HC, et al. Use of a targeted oncolytic poxvirus, JX-594, in patients with refractory primary or metastatic liver cancer: a phase I trial. *Lancet Oncol* 2008;9:533–42.
11. Worschech A, Chen N, Yu YA, Zhang Q, Pos Z, Weibel S, et al. Systemic treatment of xenografts with vaccinia virus GLV-1h68 reveals the immunologic facet of oncolytic therapy. *BMC Genomics* 2009;10:301.
12. Zhang Q, Yu YA, Wang E, Chen N, Danner RL, Munson PJ, et al. Eradication of solid human breast tumors in nude mice with an intravenously injected light-emitting oncolytic vaccinia virus. *Cancer Res* 2007;67:10038–46.
13. Yu Z, Li S, Brader P, Chen N, Yu YA, Zhang Q, et al. Oncolytic vaccinia therapy of squamous cell carcinoma. *Mol Cancer* 2009;8:45.
14. Gentschev I, Donat U, Hofmann E, Weibel S, Adelfinger M, Raab V, et al. Regression of human prostate tumors and metastases in nude mice following treatment with the recombinant oncolytic vaccinia virus GLV-1h68. *J Biomed Biotechnol* 2010;2010:489759.
15. Yu YA, Galanis C, Woo Y, Chen N, Zhang Q, Fong Y, et al. Regression of human pancreatic tumor xenografts in mice after a single systemic injection of recombinant vaccinia virus GLV-1h68. *Mol Cancer Ther* 2009;8:141–51.
16. Lin SF, Price DL, Chen CH, Brader P, Li S, Gonzalez L, et al. Oncolytic vaccinia virotherapy of anaplastic thyroid cancer in vivo. *J Clin Endocrinol Metab* 2008;93:4403–7.
17. Advani SJ, Buckel L, Chen NG, Scanderbeg DJ, Geissinger U, Zhang Q, et al. Preferential replication of systemically delivered oncolytic vaccinia virus in focally irradiated glioma xenografts. *Clin Cancer Res* 2012;18:2579–90.
18. Buckel L, Advani SJ, Frentzen A, Zhang Q, Yu YA, Chen NG, et al. Combination of fractionated irradiation with anti-VEGF expressing vaccinia virus therapy enhances tumor control by simultaneous radiosensitization of tumor associated endothelium. *Int J Cancer* 2013;133:2989–99.
19. Mansfield D, Pencavel T, Kyula JN, Zaidi S, Roulstone V, Thway K, et al. Oncolytic vaccinia virus and radiotherapy in head and neck cancer. *Oral Oncol* 2013;49:108–18.
20. Kyula JN, Khan AA, Mansfield D, Karapanagiotou EM, McLaughlin M, Roulstone V, et al. Synergistic cytotoxicity of radiation and oncolytic Lister strain vaccinia in (V600D/E)BRAF mutant melanoma depends on JNK and TNF- $\alpha$  signaling. *Oncogene* 2014;33:1700–12.
21. Kelly KJ, Woo Y, Brader P, Yu Z, Riedl C, Lin SF, et al. Novel oncolytic agent GLV-1h68 is effective against malignant pleural mesothelioma. *Hum Gene Ther* 2008;19:774–82.
22. Frentzen A, Geissinger U, Tsoneva D, Stritzker J. Use of GLV-1h68 for vaccinia virotherapy and monitoring. *Methods Mol Biol* 2015;1317:225–37.
23. Harrington K, Hingorani M, Tanay MA, Hickey J, Bhide SA, Clarke PM, et al. Phase I/II study of oncolytic HSVGM-CSF administered in combination with radiotherapy and cisplatin in untreated stage III/IVA/IVB squamous cell cancer of the head and neck. *Clin Cancer Res* 2010;16:4005–15.
24. Harrington KJ, Karapanagiotou EM, Roulstone V, Twigger KR, White CL, Vidal L, et al. Two-stage phase I dose-escalation study of intratumoral reovirus type 3 dearing and palliative radiotherapy in patients with advanced cancers. *Clin Cancer Res* 2010;16:3067–77.
25. Jefferson A, Cadet VE, Hielscher A. The mechanisms of genetically modified vaccinia viruses for the treatment of cancer. *Crit Rev Oncol Hematol* 2015;95:407–16.
26. Andtbacka RH, Kaufman HL, Collichio F, Amatruda T, Senzer N, Chesney J, et al. Talimogene Laherparepvec improves durable response rate in patients with advanced melanoma. *J Clin Oncol* 2015;33:2780–8.
27. Evgin L, Acuna SA, Tanese de Souza C, Marguerie M, Lemay CG, Ilkow CS, et al. Complement inhibition prevents oncolytic vaccinia virus neutralization in immune humans and cynomolgus macaques. *Mol Ther* 2015;23:1066–76.
28. Adair RA, Roulstone V, Scott KJ, Morgan R, Nuovo GJ, Fuller M, et al. Cell carriage, delivery, and selective replication of an oncolytic virus in tumor in patients. *Sci Transl Med*. 2012;4:138ra77.