

Pseudotumor of Hemophilia in a Patient with PTC Deficiency

By R. SILBER AND W. R. CHRISTENSEN

ALTHOUGH the hemarthroses of hemophilia are well-known manifestations of this disease, it is not commonly realized that abnormal bleeding may also cause bone destruction in sites remote from the articulations. Such osteolytic lesions are generally accompanied by massive soft tissue swelling and usually, therefore, are called pseudotumors of hemophilia. The clinical and roentgenologic manifestations may be indistinguishable from those of malignant osteolytic tumors. A total of only 18 such cases have been recorded in the literature. This rare but serious complication is illustrated in the following case report of a patient with PTC deficiency.

CASE REPORT

L.W.: This 27-year-old white male draftsman was referred to the Salt Lake General Hospital for consultation regarding an abdominal mass. About one year prior to admission, the patient had fallen on a staircase and sustained minor trauma to the region of the right hip. Slight swelling was noted at the site of the trauma, but this subsided spontaneously over a period of about four weeks. However, three months after the accident, a painless mass appeared in the right flank. In the course of the following nine months this gradually increased in size to that of a watermelon. Numbness developed over the anterior aspect of the right thigh. No other symptoms had been noted during this period.

At the age of 3, the patient had suffered a spontaneous epistaxis which lasted 2 weeks. One year later, minor trauma to the left knee was followed by bleeding into the joint. At the age of 5, profuse bleeding was noted after dental extractions. A hemarthrosis of the right knee developed at the age of 10. Five years later, multiple blood transfusions were required for the treatment of severe epistaxis and gingival bleeding. In the course of the following 10 years, the patient had noted repeated bouts of hematuria and numerous hemarthroses. Because of this, he had sought a sedentary occupation and carefully avoided strenuous physical exercise. A grand uncle and a cousin on the maternal side were known hemophiliacs.

Physical examination revealed an obese male, who was neither pale nor icteric. The vital signs were normal. A large, bulging mass was readily apparent on the right side of the abdomen. It was firm and discrete and extended from the costal margin to the inguinal ligament as well as posteriorly into the region of the right flank. The overlying skin was not warm. No tenderness was elicited on pressure. There was no evidence of accompanying hemorrhage. The mass was readily palpable on rectal examination. Examination of the joints revealed limitation of abduction of the right hip. Physical examination was not otherwise remarkable.

From the Departments of Medicine and Radiology, University of Utah, College of Medicine, Salt Lake City, Utah.

One of the authors (R.S.) is a Trainee, National Cancer Institute, Public Health Service.

The authors acknowledge with sincere appreciation the advice and assistance of Drs. Maxwell Wintrobe, George E. Cartwright and Russell S. Jones in the preparation of this paper.

Submitted July 7, 1958; accepted for publication July 25, 1958.

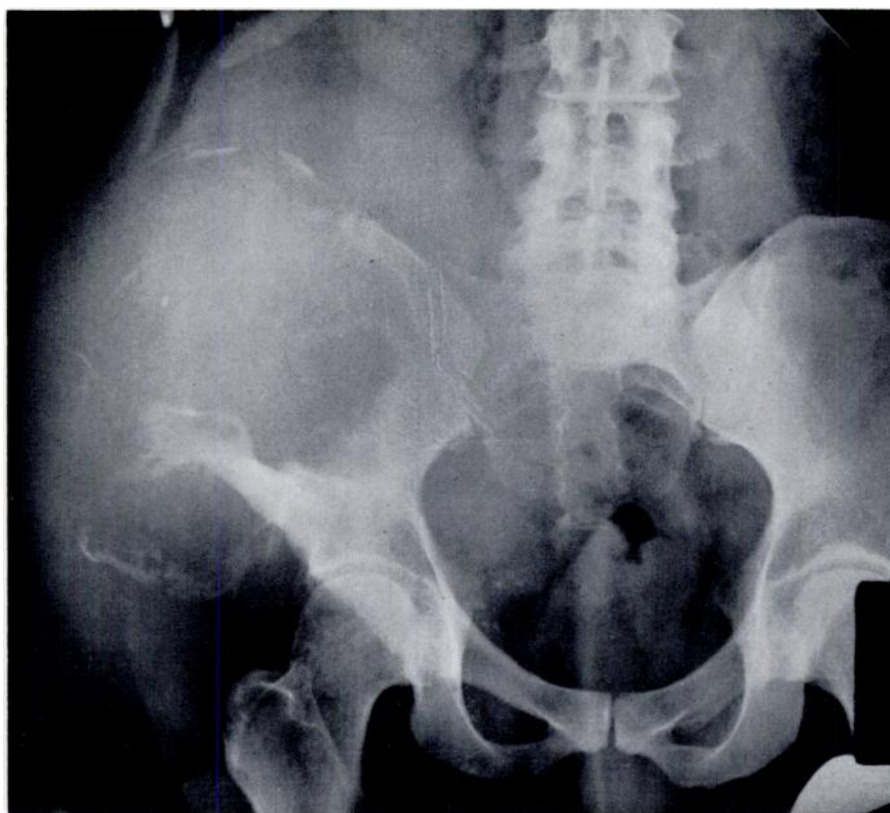

FIG. 1.—Anteroposterior film of pelvis, October 3, 1956.

The volume of packed red cells was 42 ml./100 ml. The white blood count was 7850 per cu.mm. The differential was normal. The morphology of the erythrocytes and platelets was not unusual. The platelet count (Brecher, Schneiderman and Cronkite) was 216,000 per cu.mm. The tourniquet test was negative. Clotting time (Lee-White) was 15 minutes (control, 12 minutes). Qualitative clot retraction was good after two hours. The thromboplastin generation test (Biggs and Douglas) was abnormal. The defect was localized to the patient's serum since the test became normal after the addition of normal serum. Additional studies showed that this patient's serum did not correct the coagulation defect of a patient with known PTC deficiency. The alkaline phosphatase was 5.5 Bodansky units; the serum calcium 10.8 mg. per hundred ml. and the serum phosphorus 3.5 mg. per hundred ml.

X-ray of the abdomen and hips (fig. 1) showed extensive, irregular destruction of the right ilium. Only the medial and inferior portions of this bony structure remained intact. The major portion of the crest and lateral portion of the body were no longer demonstrable. This bony defect was associated with a large, lobulated, fairly well-defined soft tissue mass which extended from the body of the ilium in all directions except posteriorly. The mass had clearly displaced discrete fragments of the ilium and induced some new, periosteal bone formation. Irregular flecks of calcification were present in its medial portion, which extended to the midline of the pelvis. Some irregular fragments of bone presumed to be remnants of the ilium were apparent within the main body of the soft tissue mass. PA film of the chest and a skeletal survey were not remarkable. It was suggested that the extensive soft tissue mass and the bone destruction had been produced either by a neoplasm, such as osteogenic sarcoma, or a large hematoma. The irregularity

of the osseous defect, periosteal new bone formation, irregular calcification at the periphery of the mass and the unusual size of the soft tissue tumor made malignancy a serious consideration. The patient was returned to his physician with the recommendation that he be hospitalized, transfused with plasma and that a needle biopsy obtained.

An ordinary surgical biopsy was attempted on October 17, 1956 in another hospital. A small, vertical incision was made immediately below the right anterior superior iliac spine. When the fascia lata was opened, approximately 1000 ml. of old blood gushed forth. The residual cavity contained a few old clots, but there was no evidence of tumor. A Penrose drain was inserted and the wound closed. Pathologic examination of the specimen obtained at surgery showed only "degenerating blood clot." No formed elements were seen. The abdominal swelling largely disappeared with evacuation of the hematoma only to regain its original size over the following week.

On December 4, 1956, the patient was again transferred to the Salt Lake General Hospital. The biopsy site remained unhealed, was infected with a hemolytic staph. aureus and continued to ooze blood. The tumor was essentially unchanged in size. In an attempt to control bleeding and prevent progression of disease, a regime of repeated, large plasma transfusions was initiated. The patient received an average of 750 ml. of plasma per day during his stay in the hospital from December to May. His anemia was controlled by numerous whole blood transfusions. The operative wound continued to drain purulent, bloody material. The abdominal and flank mass, however, slowly decreased in size. Nevertheless, the patient pursued a desultory downhill course. Despite continuous antibiotic therapy, he developed a staphylococcal septicemia in February 1957. The same organism was also cultured from a left sided pleural effusion which appeared simultaneously. Deterioration became more rapid after this complication. The patient became confused and disoriented. Cardiomegaly, dyspnea and edema appeared. These symptoms did not improve with digitalization. On May 23, the patient had several grand mal seizures and expired the following day. Despite the fatal outcome, the patient's abdominal mass had progressively decreased in size during the last four months of hospitalization. At the time of death the swelling was about 1/3 of its original size. This decrease had occurred despite the fact that the cavity in the pseudotumor had repeatedly emptied and refilled with blood.

Radiographs obtained on the day of death (fig. 2) demonstrated considerable improvement in appearance. The bulky, soft tissue mass was no longer apparent. Definite reconstitution of the ilium had taken place. The area of erosion had decreased considerably in size. The crest and lateral border of the ilium had approached a fairly normal external contour. A gross lesion was obviously still present but a striking response to therapy had occurred.

Autopsy Findings

The right iliac fossa was occupied by a poorly defined mass of bloody necrotic material measuring approximately 10 cm. in diameter. There was a large defect in the right ilium. The psoas muscle was dark brown in color and of flabby consistency. No gross pus was seen. Microscopic examination of sections taken from the wall of the hematoma revealed fibrotic changes and hemosiderin laden macrophages. Numerous sections showed no evidence of neoplasm, but various stages of new bone formation were evident. The adjoining muscle fibers were atrophic with an increase in sarcolemmal nuclei. There was polymorphonuclear leukocytic infiltration. A large hemorrhagic area was present in the right parietal lobe of the brain. Sections of brain tissue also showed areas of neuronal damage with glial proliferation and polymorphonuclear cell infiltration. Zones of myocarditis were noted on microscopic examination of the heart. Hemosiderosis was present in the liver and spleen. The left pleura was thickened and fibrotic. There was a diffuse arteritis involving all branches of the pulmonary artery, from large to small. The vessel walls were necrotic and infiltrated with macrophages and polymorphonuclear leukocytes. Sections stained with PAS showed mycelia within the inflammatory zones present in lung and brain. Unfortunately, no cultures were obtained and the exact nature of the fungus which invaded this debilitated, antibiotic-treated patient is, therefore, unknown.

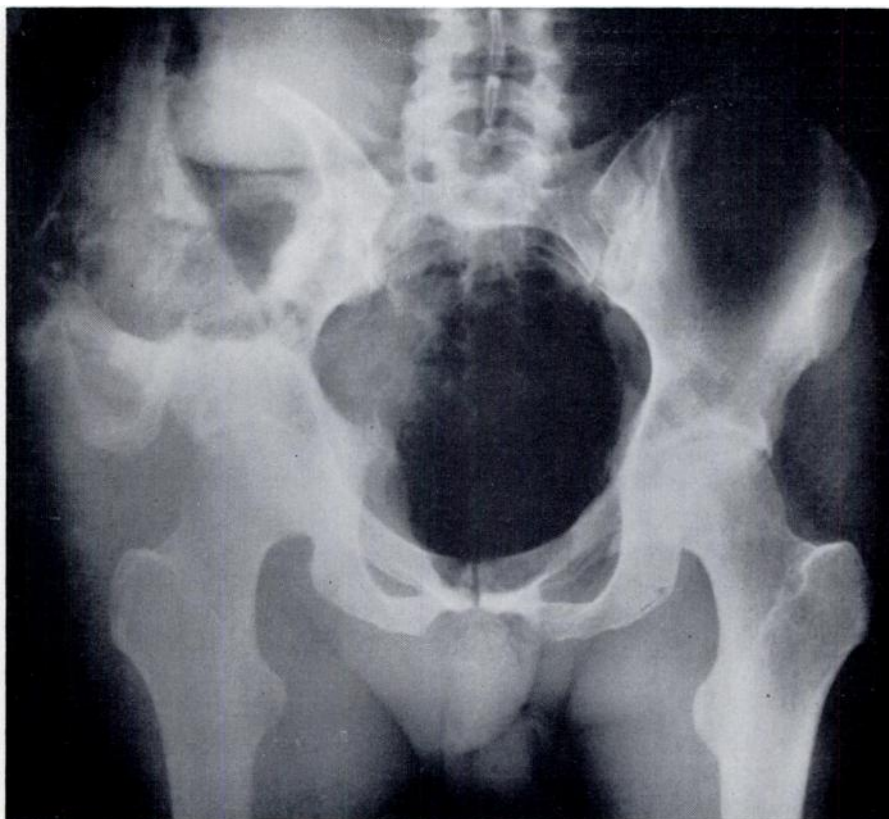


FIG. 2.—Anteroposterior film of pelvis, May 24, 1957.

DISCUSSION

The first report of hemophilic pseudotumor was presented by Starker in 1918.¹³ He described a 14-year-old hemophiliac who sought medical aid because of a large swelling in his right thigh. Slight trauma had occurred 8 months earlier. Cortical destruction and periosteal thinning of the femur were seen on x-ray and the diagnosis of sarcoma of the bone with bleeding into the tumor was entertained. The swelling was probed and 750 ml. of blood aspirated, with collapse of the tumor sac. In 4 days this refilled. The patient subsequently developed fever, became anemic and expired in 10 days. Pathologic examination revealed no evidence of neoplasm.

Since this original report, extra-articular destructive changes in bones have been reported in 18 patients with bleeding tendencies^{1,4,5,6,8-12} (table 1). These have been associated with large hematomas and pronounced swelling of the surrounding soft tissue. The names, "pseudotumor of hemophilia"⁴ or "resorption tumor of bone"¹⁰ appear to have been well accepted.

Little is known regarding the pathologic physiology of this complication of hemophilia. The exact anatomic site of the hemorrhage and the nature of the process producing bone destruction are uncertain. It is possible that the bleeding originates under the periosteum and produces erosion by pressure

from the outside; intramedullary hemorrhage might also have this effect by increasing internal pressure on the shaft. Others have suggested that the hematomas may originate through extension from old hemarthroses.⁷

In our patient the hematoma was under considerable pressure. This has also been noted in other cases.^{7,12} Larsen has produced massive necrosis of bone in dogs by infusing sterile saline into their femoral cavities and maintaining a pressure of 180 cm. of water continuously for 12 hours.⁹ It is conceivable that a similar mechanism may account for the "resorption tumor of bone." All requirements of this situation would be met in the case of continual minimal oozing into a confined sub-periosteal space or an intramedullary cavity. At present there is no evidence that the blood of patients with hemophilia possesses greater osteolytic potency than normal blood.¹²

As has been indicated, our patient's bleeding tendency was due to a PTC deficiency. This is the first reported instance of pseudotumor in this disorder. One would suspect, therefore, that the amount and duration of bleeding rather than the exact nature of the coagulation defect are the primary factors in the development of a pseudotumor.

Development of this lesion was preceded by a definite history of injury in only eight of the reported cases. The importance of trauma is questionable in that months or even years may elapse between injury and the appearance of signs and symptoms. The customary presenting complaint has been painless swelling of several months duration. The bone most frequently involved is the femur (table 1). The ulna, tibia and thumb have also been affected. The ilium has been the only flat bone involved.

The differential diagnosis of such localized osteolytic lesions which may show varying degrees of irregular margination, periosteal elevation and new bone formation include osteomyelitis, osteitis deformans, giant cell tumor, osteitis fibrosa cystica, solitary plasmacytoma, reticulum cell sarcoma, metastatic malignancy and osteogenic sarcoma. The malignancies, both primary and secondary, are clearly the most important considerations. Differentiation from osteogenic sarcoma, in particular, may be most difficult. It is apparent from the characteristics listed above that all radiologic and clinical features of an osteogenic sarcoma may be duplicated. A presumptive diagnosis of pseudotumor should probably be made in any instance where a patient with known bleeding tendencies develops a slowly growing mass. Awareness of such a possibility in hemophilia may well save the patient exploration or even amputation. Needle aspiration is a safer biopsy technic than surgical incision. However, in the presence of a hematoma in a hemophiliac patient even this presents considerable risk. The dangers of hemorrhage and infection are continually present.

Therapy, in our opinion, should be aimed at the correction or control of the underlying coagulation defect. Active bleeding must be stopped. Repeated plasma transfusions over a long period of time may be required. Fresh plasma or stored plasma may be given depending on whether the patient is AHG or PTC deficient. Roentgen therapy has been advocated in the past on the assumption that it hastens resorption of the tumor.¹⁰

TABLE 1.—*Pseudotumor of Bone*

Number of patients reported	18
Age of patients	9–55 years
Sex	Male
Affected Bone	
Femur	10 cases
Tibia	3 cases
Ilium	3 cases
Thumb	2 cases
Fatal outcome (related to pseudotumor)	7 cases
Surgical intervention (biopsy, exploration or amputation because of possibility of sarcoma)	10 cases
Duration of pseudotumor	4 months – 24 years

The mortality rate for patients with this complication is high. Seven of the 18 patients reported in the literature died of the pseudotumor or its complications. In four of the cases, surgical intervention may have contributed to the poor outcome. Progression of the untreated pseudotumor may occur over a period of years and result in serious incapacitation even if the immediate outcome is not fatal.

SUMMARY

1. A case of pseudotumor of the ilium in a PTC deficient patient is reported.
2. The natural history and treatment of this serious complication of hemophilia are reviewed.

SUMMARIO IN INTERLINGUA

1. Es reportate un caso de pseudotumor del ilium in un patiente con deficiencia de PTC.
2. Es presentate un revista del historia natural e del tractamento de iste serie complication de hemophilia.

REFERENCES

1. Becker, F.: Sarkom vortäuschende sog. Resorptionsgeschwulst bei Hämophilie. *Zentralbl. Chir.* 69:113, 1942.
2. Biggs, Rosemary and Douglas, A. S.: The thromboplastin generation test. *J. Clin. Path.* 6:23, 1953.
3. Brecher, G., Schneiderman, M. and Cronkite, E.: The Reproducibility and constancy of the platelet count. *Am. J. Clin. Path.* 23:15, 1953.
4. Echternacht, A. P.: Pseudotumor of bone. *Radiology* 41:565, 1943.
5. Firor, W. M. and Woodhall, B.: Hemophilic pseudotumor: diagnosis, pathology and surgical treatment of hemophilic lesions in the smaller bones and joints. *Bull. Johns Hopkins Hosp.* 59:237, 1936.
6. Forfota, E.: Über die Gelenk- und Knochenveränderungen bei Blutern. *Röntgenpraxis* 3:399, 1931.
7. Ghormley, R. K. and Clegg, R. S.: Bone and joint changes in hemophilia, with report of cases of so-called hemophilic pseudotumor. *J. Bone & Joint Surg.* 30-A:589, 1948.
8. Günzel, E.: Über krankhafte Veränderungen an Knochen und Gelenken bei Blutern. *Röntgenpraxis* 14:80, 1942.

9. Larsen, R. M.: Intramedullary pressure with particular reference to massive diaphyseal bone necrosis. *Ann. Surg.* 108:127, 1938.
10. Müller, J. H.: Über die Röntgentherapie von sog. Resorptionsgeschwülsten bei Hämophilie. *Strahlentherapie* 72:281, 1942.
11. Petersen, J.: A Case of osseous changes in a patient with hemophilia. *Acta radiol.* 28:323, 1947.
12. Reinecke and Wohlwill: Über Hämophilie Gelenkerkrankung. *Arch. klin. Chir.* 154:424, 1929.
13. Starker, L.: Knochenusur durch ein Hämophiles, subperiostales Hämatom. *Mitt.a.d. Grenzgeb.d.Med. u. Chir.* 31:381, 1918.
14. Walker, H. J. S. and Womack, N. A.: Pseudotumor of bone in hereditary pseudohemophilia. *Arch. Surg.* 56:329, 1948.