

## Whole-Body Low-Dose Computed Tomography and Advanced Imaging Techniques for Multiple Myeloma Bone Disease

Matthew J. Pianko<sup>1</sup>, Evangelos Terpos<sup>2</sup>, G. David Roodman<sup>3</sup>, Chaitanya R. Divgi<sup>4</sup>, Sonja Zweegman<sup>5</sup>, Jens Hillengass<sup>6,7</sup>, and Suzanne Lentzsch<sup>1,8</sup>

### Abstract

Detection of lytic bone lesions is crucial in the workup for multiple myeloma and very often dictates the decision to start treatment. Conventional radiography, despite decades of use, is often insufficient for detection of bone disease in multiple myeloma. Modern imaging techniques such as MRI, PET, and CT offer superior detection of myeloma bone disease and extramedullary manifestations of plasma cell dyscrasias. Novel whole-body low-dose computed tomography (WBLDCT) protocols allow for collection of superior image detail of the skeleton at doses of radiation similar to those used for conventional planar radiography. Several studies have shown that WBLDCT has a superior detection rate for lytic bone lesions compared with whole-body X-ray (WBXR), potentially leading to restaging and changes in therapy. MRI and PET provide imaging data important for assessing disease activity and prognostication. Because of several advantages over WBXR, WBLDCT is already the standard imaging technique for use in patients with multiple myeloma in many European institutions. However, the radiographic skeletal survey or WBXR is still the initial study of choice used to screen for myeloma bone disease in many institutions. In this review, we aim to explore the changing landscape of imaging for myeloma bone disease through use of modern imaging techniques. *Clin Cancer Res*; 20(23); 5888–97. ©2014 AACR.

### Introduction

Multiple myeloma is a plasma cell neoplasm characterized by bone marrow infiltration and excessive production of monoclonal immunoglobulin. Multiple myeloma represents 1.3% of all new cancer diagnoses and approximately 15% of all new hematologic malignancies annually in the United States (1). The osteolytic destruction of the bony skeleton in multiple myeloma distinguishes it from

precursor entities such as monoclonal gammopathy of undetermined significance (MGUS) and smoldering myeloma. The CRAB criteria (hypercalcemia, renal insufficiency, anemia, bone lesions) proposed by the International Myeloma Working Group that define symptomatic multiple myeloma requiring therapy include an imaging evaluation of the skeleton (2). Therefore, imaging that can accurately define the presence and extent of osteolytic lesions in multiple myeloma is a critical part of the initial workup, staging, and evaluation of multiple myeloma, as the presence of end-organ damage is an indication to initiate treatment. The initial imaging evaluation in patients with suspected multiple myeloma for approximately the last 40 years has been the radiographic skeletal survey (SS) or whole-body X-ray (WBXR; ref. 3). Since the 1980s, advanced imaging technologies such as CT, MRI, and PET have improved the quantity of information available to clinicians treating patients with myeloma. WBXR, the "gold standard" imaging test, has a poor detection rate that potentially delays diagnosis and therapy until late findings are present. Although it is currently not known whether early therapy would improve outcome, a delay in therapy can at least lead to clinically significant bone disease associated with complications such as hypercalcemia and fracture. Therefore, an imaging method with a high sensitivity should be used as an initial imaging test. Modern imaging techniques such as whole-body MRI and PET have been

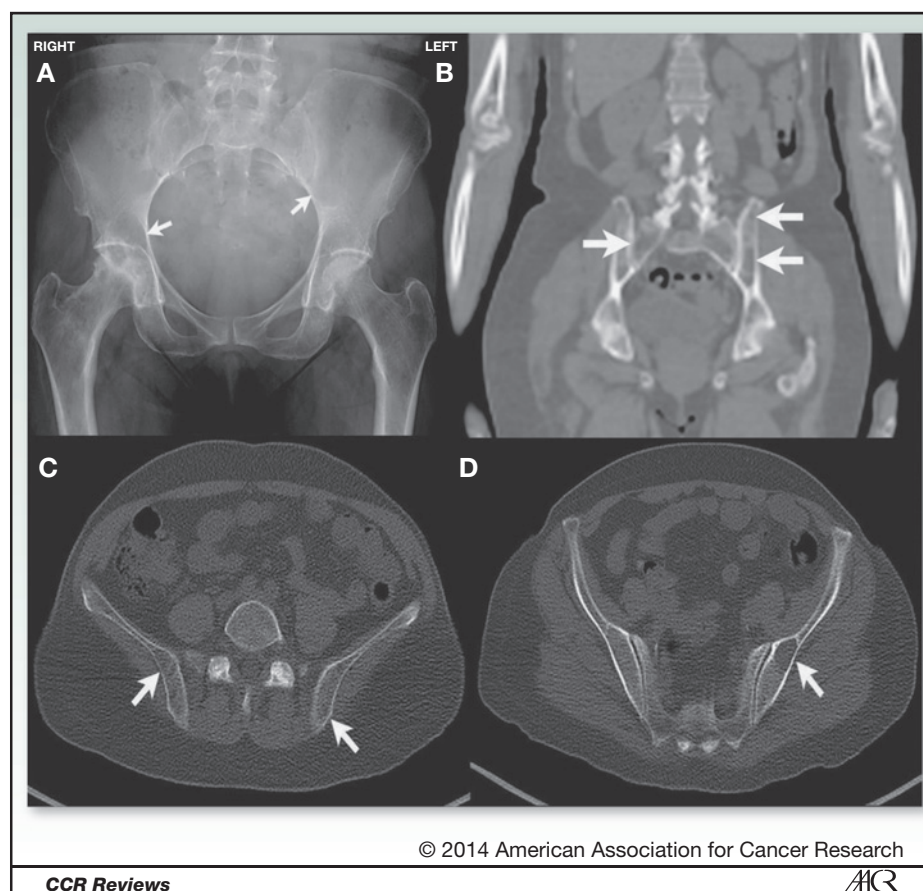
<sup>1</sup>Department of Medicine, College of Physicians and Surgeons of Columbia University, New York-Presbyterian Hospital, New York, New York. <sup>2</sup>Department of Clinical Therapeutics, University of Athens School of Medicine, Alexandra General Hospital, Athens, Greece. <sup>3</sup>Division of Hematology/Oncology, Department of Medicine, Hematopoiesis, Hematological Malignancies and Immunology Research Program, Indiana University Simon Cancer Center, Bloomington, Indiana. <sup>4</sup>Department of Radiology, College of Physicians and Surgeons of Columbia University, New York, New York. <sup>5</sup>Department of Hematology, VU University Medical Center, Amsterdam, the Netherlands. <sup>6</sup>Department of Hematology and Oncology, University Hospital Heidelberg, Heidelberg, Germany. <sup>7</sup>Department of Internal Medicine, University Hospital Heidelberg, Heidelberg, Germany. <sup>8</sup>Division of Hematology/Oncology, College of Physicians and Surgeons of Columbia University, New York, New York.

**Corresponding Author:** Suzanne Lentzsch, Division of Hematology/Oncology, College of Physicians and Surgeons of Columbia University, 161 Fort Washington Avenue, Herbert Irving Pavilion, R-953, New York, NY 10032. Phone: 646-317-4840; Fax: 212-305-3035; E-mail: sl3440@columbia.edu

doi: 10.1158/1078-0432.CCR-14-1692

©2014 American Association for Cancer Research.

**Figure 1.** A patient with multiple myeloma and subtle lucencies in the bony pelvis on WBXR that may be easily missed or mistaken for bowel loops (A). WBLDCT images (B–D) show multiple bony lytic lesions in the pelvis indicated by white arrows.



included in the Durie/Salmon PLUS staging system (3), but use of these tests can be limited by several logistical factors at many centers. In addition, the Durie/Salmon PLUS staging system has not been prospectively validated. Two comparative studies have noted only 30% to 45% concordance between the Durie/Salmon and Durie/Salmon PLUS staging systems (4, 5) reflecting the difficulties of incorporation of a new imaging technique with very high sensitivity with an old staging system. CT has a better detection rate compared with conventional radiography for lytic bone disease (5) and could change the management of patients with multiple myeloma, preventing or delaying significant morbidity and mortality related to skeletal-related events.

In this review, we aim to compare and contrast traditional and modern imaging techniques used in multiple myeloma and discuss opportunities to improve the quality of care for patients with myeloma using advanced imaging techniques.

#### Radiologic skeletal survey

Despite advantages, which include decades of experience and validation with staging systems, low cost, and wide availability, WBXR is quite limited in its technical capacity to evaluate bony structures, fractures, and osteolytic foci. Lytic lesions are only apparent on conventional

radiography when 30% to 50% of bone mineral density is already lost from cortical bone destruction (6–8). Patients with early myeloma who have very small lytic lesions may escape detection and delay treatment. Detection of focal lesions in the axial skeleton using conventional radiography is further confounded by overlying tissue and complex anatomy (Fig. 1). In the pelvis, bowel loops overlying bone may mimic lytic lesions where none exist. In addition, a diffuse pattern of cortical bone loss may not be detected by WBXR. Surgical intervention for bony disease in the spine, biopsy planning, identification of impending fracture, and investigation of suspected cord compression demands use of additional cross-sectional imaging such as CT or MRI. The consistent shortcomings of WBXR in the detection of lytic lesions can lead to pervasive understaging (9). In addition, the use of WBXR in patients with early myeloma may delay diagnosis, as bony lesions must be significant before they are detected.

In evaluating modern imaging techniques and comparing the sensitivity and specificity of these tests to that of WBXR as the current gold standard reference test, it is important to note that the lower lesion detection rate of WBXR as a reference test may suggest that newer techniques have less specificity when lesions are found (Table 1). For example, does detection of a 3- to 4-mm lytic lesion, which would not have been detected by WBXR, reflect multiple

**Table 1.** Characteristics of advanced imaging studies in multiple myeloma

Index test	Reference test	Sensitivity index test	Specificity index test	Detection rate	References
CT	WBXR	0.947–1.00	0.467–0.500	1.10–1.33	(12, 15)
MRI	WBXR	0.916 (0.883–0.940)	0.412 (0.261–0.582)	1.12–1.80	(15, 40–48)
PET-CT	WBXR	0.667–1.00	0.286–0.500	1.27–1.45	(40)
PET	WBXR	0.953 (0.369–0.999)	0.217 (0.178–0.679)	1.16–1.50	(49)
PET	CT	0.824	1.00	1.00	(50)
MRI	CT	0.800–1.00	0.782–0.789	1.15–1.25	(9)

NOTE: Studies included above were not preselected on the basis of bone disease. Detection rate is a ratio of the number of patients/regions with lesions detected by the index test divided by the number of patients/regions with lesions detected by the reference test. Adapted from Regelink et al. (10) by permission of John Wiley & Sons.

myeloma bone disease? In a statistical direct comparison, the low specificity of newer imaging techniques reflects their superior detection rates over that of WBXR, and ignores that the high number of lesions observed by newer techniques, although not biopsy proven, do likely reflect myeloma bone disease (10, 11).

### Computed tomography

CT has promising characteristics that may lead to its replacement of conventional radiography as a screening test for lytic lesions in multiple myeloma (Table 2). According to a systematic review, CT has a 4% to 33% higher detection rate of lytic lesions compared with X-ray, although in some studies, there was inferior detection of lesions in the skull and ribs, whereas others suggested better detection in those regions (Table 3; ref. 10). In 1985, Schreiman and colleagues (12) published the first study demonstrating improved detection rates of CT over WBXR. Advances in CT technology, such as development of low radiation dose protocols, have made it a useful technique for use in patients with multiple myeloma. Horger and colleagues were the first group to use the advantage of the intrinsic high contrast of bone in whole-body low-dose computed tomography (WBLDCT) to explore protocols that lower the dose of radiation necessary to image the skeletal system while preserving sensitivity and image detail (13). Following their pioneering work, use of WBLDCT in multiple myeloma has become standard of care in many European institutions. Several useful attributes have contributed to the expanding use of WBLDCT, such as rapid acquisition time (75 seconds), superior image quality without need for i.v. contrast agents due to the intrinsic contrast of bone, comparable radiation exposure to WBXR, and utility in planning for image-guided biopsy and surgical interventions.

In a prospective head-to-head study at a single center in Germany, results of WBLDCT and WBXR in 29 patients were compared. The included patients (13 female, 16 male) had DS stage I–III multiple myeloma and were of average age of 57 years (44–73). The authors presented data comparing the number and size of lesions detected, diagnostic confidence, the number and nature of lesions

seen on WBLDCT and missed on WBXR, extra osseous findings, radiation dose, and examination time. Lesions were counted, graded according to diagnostic confidence in whether or not they constituted osteolytic lesions, and categorized according to anatomic location in one of the five bony regions. The levels of confidence in 48 uncertain WBXR findings were raised by evaluation using WBLDCT (14). The most significant differences in lesion detection between the two methods by body region were in single lesions in the thoracic cage (5-fold increase), and in several lesions in the vertebral column (3.75-fold increase). Using WBLDCT, the detection of osteolytic lesions increased 7-fold in the spine. There were 97 lesions in 18 patients that were exclusively identified by WBLDCT and only 11 lesions noted with WBXR that were not seen on WBLDCT. In the limbs and the calvarium, more lesions were detected by WBXR. Lesions of the spine, pelvis, and thoracic skeleton were significantly more frequent ( $P \leq 0.001$ ), and diagnostic confidence was increased by WBLDCT compared with WBXR ( $P \leq 0.02$ ). A greater number of uncertain findings in WBXR ( $n = 49$ ) versus WBLDCT ( $n = 26$ ) were found in the vertebral spine and pelvis (14), which correlate with known limitations of WBXR in imaging these anatomic regions. As a consequence of these findings, therapy was changed in 18.2% of patients in the study. A representative series of images of a patient whose vertebral and pelvic lesions detected by WBLDCT are in regions of the axial skeleton poorly imaged by WBXR are presented in Fig. 2.

In another study that compared WBXR with WBLDCT, 39 patients were followed over 18 months in a prospective randomized European single-center trial with two WBLDCT protocols and were compared with WB-MRI as the index imaging test. In this study, imaging findings obtained through the use of WBLDCT lead to restaging of 18 patients (16 upstaged, 2 down-staged). Overall reader impression of stage on WBLDCT significantly correlated with WB-MRI ( $\kappa = 0.454$ ,  $P < 0.05$ ). WBLDCT detected 89.7% of myelomatous lesions compared with 69.2% of lesions detected by the WBXR when correlated with WB-MRI as the index imaging test (15). In comparison with WBXR, WBLDCT

**Table 2.** Included studies examining WBLDCT for detection of multiple myeloma bone disease

Authors	Study	Patients	N	Exam	Tube energy (kilovolt peak, kVp)	Current tube time product (milliampereseconds, mAs)	WBLDCT radiation dose (mSv)	Reference	Key findings
Gleeson et al. (15)	Prospective	Suspected multiple myeloma or known multiple myeloma	39	WBLDCT	140	14	3.3 (1.5-4.6)	WB-MRI, WBXR, bone marrow biopsy	WBLDCT correlates with WBMRI, superior detection over WBXR
Horger et al. (13)	Prospective	Proven multiple myeloma or MGUS	100	WBLDCT	120	40	4.1	None	Pioneering study determined optimal settings for WBLDCT that preserve image quality and reduce radiation exposure
Horger et al. (31)	Prospective	Proven multiple myeloma	131	WBLDCT	120	70	Not calculated	None	Response to treatment can be monitored with WBLDCT
Horger et al. BJR (51)	Prospective	Proven multiple myeloma	50	WBLDCT	120	70	7.5	None	WBLDCT shows bone marrow abnormalities that correlate with hematologic parameters
Ippolito et al. (52)	Prospective	Proven multiple myeloma	138	WBLDCT	120	40	4.2	None	WBLDCT demonstrates high detection rates of bone lesions, extraosseous findings
Kropil et al. (14)	Prospective	Proven multiple myeloma	29	WBLDCT	100	75.9 (73.5-77.8)	4.8	WBXR	Compared detection rates by region, WBLDCT superior to WBXR
Princewill et al. (16)	Retrospective	Proven multiple myeloma	51	WBLDCT	120	100	4.1 (2.2-4.9)	WBXR	Superior detection of lesions by WBLDCT in ultrasound-based referral center
Spira et al. (38)	Retrospective	confirmed MGUS	71	WBLDCT	120	70	7.2	WBXR	WBLDCT correlates with hematologic parameters during ongoing treatment
Wolf et al. (5)	Prospective	multiple myeloma, MGUS, or solitary plasmacytoma	171	WBLDCT	Not reported	90	9.4-11.3	WBXR, WB-MRI	Found only 30% correlation between Durie/Salmon and Durie/Salmon PLUS staging systems

**Table 3.** Detection rate of osteolytic bone lesion number by body region (WBLDCT vs. WBXR)

	Kropil et al. (14)				Princewill et al. (16)			
	WBLDCT (# detected)	WBXR (# detected)	Ratio of detection (WBLDCT#/ WBXR#)	P	WBLDCT (# detected)	WBXR (# detected)	Ratio of detection (WBLDCT#/ WBXR#)	P
Total skeleton	247	120	2.06	Not reported	968	248	3.90	<0.001
Skull	7	1	7.00	Not reported	94	86	1.09	0.02
Spine	69	15	4.60	<0.001	241	49	4.92	<0.001
Thoracic cage (ribs and sternum)	60	29	2.07	<0.001	222	3	74.00	<0.001
Pelvis and flat bones	61	24	2.54	<0.001	240	36	6.67	<0.001
Long bones and extremities	46	47	0.98	Not reported	171	74	2.31	<0.001

NOTE: Two studies examining number of lytic lesions by body region as detected by WBLDCT and WBXR are compared above. Study protocols differed slightly in that Kropil et al. (14) protocol examined skull only from skull base.

more accurately assessed the extent of bone destruction (9, 15), and was found to correlate more significantly with WB-MRI in the staging workup.

Princewill and colleagues conducted a recent retrospective study to evaluate WBLDCT compared with WBXR during the initial staging or restaging of patients with multiple myeloma at a U.S.-based myeloma referral center (16). In their cohort, 61% of patients with normal WBXR warranted a higher disease stage based on abnormal WBLDCT. The total quantity of lesions detected with CT was 968 versus 248 for radiographs ( $P < 0.001$ ). Nine patients (18%) had no detectable findings on either WBXR or WBLDCT, and the remaining 39 of 42 patients had more lesions on CT. On the basis of these findings, 31 cases (61%) could have resulted in higher stages at initial evaluation based on WBLDCT use rather than the WBXR (16).

In a prospective study of 117 patients of all stages of multiple myeloma, MGUS, or smoldering multiple myeloma, Wolf and colleagues compared WB-MRI and WB-CT with conventional radiography and found that both advanced imaging techniques had higher detection rates. WB-CT imaging demonstrated relevant additional findings in 33 of 52 (63%) patients (5). WB-MRI and WB-CT were each found to be superior to conventional radiography.

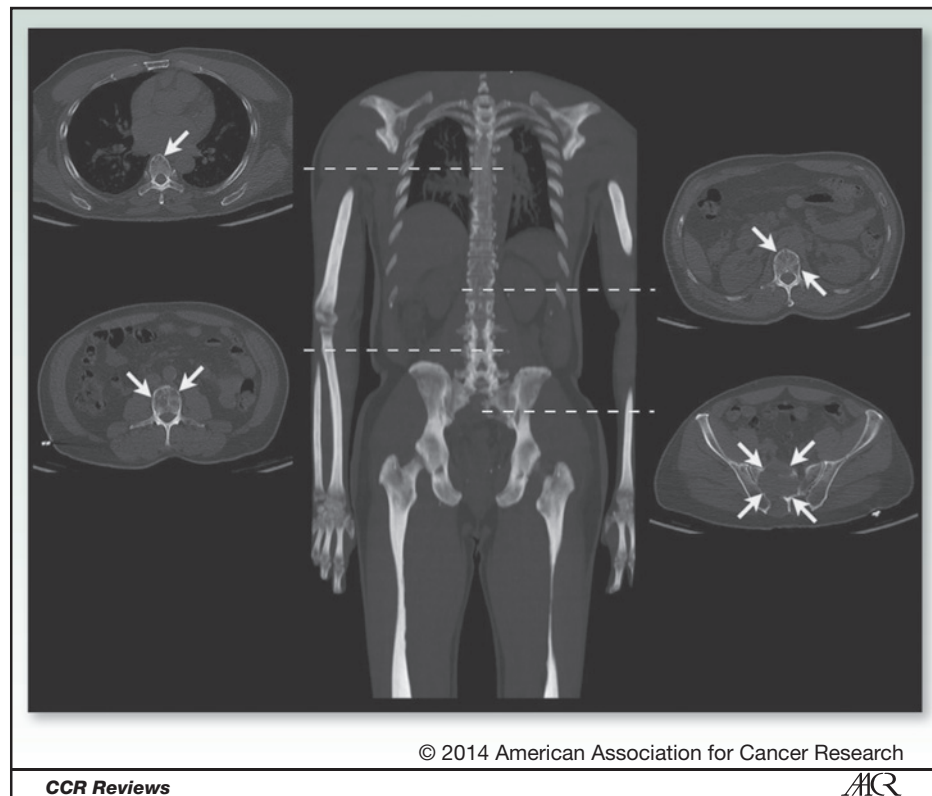
### Magnetic resonance imaging

Overall survival improves as therapeutic options expand for patients with myeloma and MRI may allow for repeat imaging and follow-up without repeat exposure to radiation. MRI can provide distinct information compared with

WBXR and CT, such as bone marrow infiltration and distinct patterns of marrow infiltrates that have been found to correlate with findings on bone marrow biopsy (17). A systematic review indicated that MRI has a superior focal lesion detection rate (as much as 82% higher) compared with WBXR (10). The higher detection rate of MRI may be due to the fact that lesions detected by MRI in bone may also reflect bone marrow infiltrates rather than frank osteolytic lesions. A main advantage of MRI cited in the literature is the improved detection of diffuse bone marrow infiltration by myeloma cells (18). MRI allows for imaging of the bone cavity content and can detect changes in marrow density and identify marrow infiltration patterns before development of any bone destruction in patients with MGUS (19, 20). Diffuse involvement of the bone marrow by multiple myeloma is better detected by WB-MRI, leading to upstaging in cases where diffuse bone loss could be misinterpreted as senile osteoporosis by WBLDCT (9). However, MRI has lower sensitivity in detecting osteolytic bone disease, which in many cases is the criterion for which patients initiate treatment for multiple myeloma (21).

Detection of lesions in the skull, clavicles, and ribs is limited by respiratory movements and by small lesions missed by MRI slices (11, 21). WB-MRI sequences use multiplanar cuts that improve detection of small bony lesions over axial MRI. MRI also detects infiltrative lesions without destruction of cancellous bone, which overestimate the prevalence of bony disease in multiple myeloma. Intravenous contrast agents are necessary for obtaining optimal MRI images but are contraindicated in patients with renal insufficiency due to the risk of nephrogenic systemic fibrosis. Routine use of contrast-enhanced MRI is often

**Figure 2.** A representative low-dose CT image set from a patient with subtle lytic lesions. Coronal maximum intensity projection and selected axial CT images of a patient show lytic lesions throughout the vertebral column as denoted by arrows present on corresponding axial images. The sacral lesion shows a sizable soft tissue component, which would likely not have been detected with conventional radiography.



precluded in a population with high incidence of renal insufficiency from cast nephropathy and hypercalcemia. In addition, prolonged acquisition time in patients with significant bony pain, high cost, presence of indwelling metal objects, and patient claustrophobia are known limitations of MRI. Although MRI is a useful imaging technique for multiple myeloma, a lack of suitable MRI scanners in some centers is a limitation to its widespread use (9).

### PET and functional imaging

Several modern imaging techniques allow for quantification of disease activity. PET allows for imaging of metabolic activity through detection of radiolabeled tracers that provide information about disease activity and can be used to follow patients for response to therapy. PET has been shown to be sensitive in detecting multiple myeloma in areas not imaged by MRI. The most significant advantage in the use of PET/CT is through detection of disease activity as it can distinguish between active and inactive disease (22). PET results correlate with clinical and hematologic parameters in patients with multiple myeloma (23), and can predict survival (24). Limitations of PET imaging include poor specificity to small lytic lesions less than 0.5 cm in size and false-positive results. False-positive results in FDG-PET for detection of multiple myeloma may result from detection of metabolically active areas of inflammation or infection, brown fat, postsurgical changes, or other malignancies (25). During follow-up examinations, PET/CT imaging can

distinguish persistent metabolically active lesions of clinical significance just after therapy (26), whereas lesions detected by MRI persist for a longer period of time (9–12 month lag) following therapy (11, 27). Novel radiotracers such as  $^{11}\text{C}$ -methionine and  $^{18}\text{F}$ -fluorodeoxy-L-thymidine have been used to image bone marrow metabolic activity and bone turnover but have not yet been brought forth for clinical use (28, 29). Hybrid techniques such as PET/MRI and PET/WBLDCT may add functional data but are also not yet in routine clinical practice. Comparison of FDG-avid lesions before and after induction therapy may predict survival in patients with multiple myeloma and suggests that serial functional disease assessments using FDG-PET/CT could alter therapy and affect survival (30).

### Imaging for surveillance and prognostication

Prognosis in multiple myeloma has been determined according to the use of WBXR and the Durie/Salmon staging system for decades. There are a number of studies evaluating FDG-PET/CT and MRI as tools to assess response to ongoing therapy, and both have recently been incorporated into the updated Durie/Salmon PLUS staging system (3). An excellent correlation has been reported between the number and pattern of lesions detected by MRI and treatment outcomes and survival (3). WBXR and CT are morphologic imaging modalities that neither provide functional information about disease response in the face of ongoing treatment nor are they very sensitive to early changes in

**Table 4.** Advantages and disadvantages of imaging techniques used for detection of multiple myeloma bone disease

Advantages	Disadvantages
<b>WBXR</b> <ul style="list-style-type: none"> <li>• Cost</li> <li>• Availability</li> <li>• Historical use/validation</li> <li>• Possible better detection of skull, limb lesions</li> </ul>	<ul style="list-style-type: none"> <li>• Poor sensitivity/low detection rate</li> <li>• Findings present only after advanced bone damage</li> <li>• Patient discomfort with repositioning, multiple films</li> <li>• Long image acquisition time</li> <li>• Limited to bony defects</li> <li>• Possible need for repeat images</li> </ul>
<b>WBLDCT</b> <ul style="list-style-type: none"> <li>• Sensitivity and specificity</li> <li>• 3D structural information for CT-guided biopsy, surgery, radiotherapy planning</li> <li>• Can depict EMD, bone marrow involvement, and lytic lesions</li> <li>• Can assess tumor burden</li> <li>• Rapid acquisition time</li> <li>• Inexpensive compared with MRI, PET</li> <li>• Comfortable for patients</li> </ul>	<ul style="list-style-type: none"> <li>• Lesions in ribs and skull may be missed</li> <li>• Unclear prognostic significance of lesion number</li> <li>• Higher radiation exposure, expense</li> </ul>
<b>PET/CT</b> <ul style="list-style-type: none"> <li>• Functional disease activity</li> <li>• Assesses disease activity before and after treatment</li> <li>• Images EMD</li> <li>• Prognostic significance pre- and posttreatment</li> <li>• Novel radioisotopes may offer additional disease-relevant information</li> </ul>	<ul style="list-style-type: none"> <li>• High cost</li> <li>• Limited availability</li> <li>• Potential confusion of infection/inflammation for disease activity</li> <li>• Poor spatial resolution &lt;5 mm</li> <li>• Low FDG-avidity of myeloma</li> </ul>
<b>MRI</b> <ul style="list-style-type: none"> <li>• No radiation exposure</li> <li>• Assesses bone marrow compartment, detects infiltration and focal bone marrow lesions</li> <li>• Superior for detection of spinal cord compression, soft tissue masses</li> <li>• Lesion number has prognostic significance</li> <li>• Images EMD</li> <li>• 3D structural information for CT-guided biopsy, surgery, radiotherapy planning</li> </ul>	<ul style="list-style-type: none"> <li>• High cost</li> <li>• Long acquisition time, claustrophobia</li> <li>• Excludes patients with indwelling metal objects</li> <li>• Contrast contraindicated in severe renal insufficiency</li> <li>• Bone infiltration may be misinterpreted as osteolytic lesion (overestimates osteolytic lesions)</li> <li>• Limited imaging field, subject to motion artifact</li> </ul>

bone marrow during treatment (3). Heterogeneous osteoporosis in a population at risk may be misinterpreted as osteolytic lesions representative of multiple myeloma (15). Conversely, WBLDCT may not detect diffuse marrow involvement with homogenous-appearing cortical bone destruction that could be mistaken for osteoporosis or osteopenia (31, 32).

In addition, data are sparse for the use of CT to prognosticate in multiple myeloma. A systematic review of 32 studies examining the role of modern imaging techniques compared with conventional imaging for patients with multiple myeloma noted multiple studies establishing the prognostic value of MRI and FDG-PET/CT (10). Use of MRI to document the number of lesions has prognostic significance in MGUS, smoldering myeloma, and multiple mye-

loma (11, 19, 33). PET/CT has the highest detection rates for extramedullary disease (EMD; ref. 34) compared with other imaging techniques, which is critical, since EMD has been found to confer a poor prognosis (24, 27, 35, 36). Only one study examined the prognostic value of lesions found on CT, and showed no correlation between the number of lesions and prognosis (30). These findings stand in contrast with studies using MRI and FDG-PET/CT, in which the number of lesions correlated with prognosis, which reflects the detection of active disease infiltration in the bone or bone marrow (37). Further studies are indicated to replicate these findings for CT.

For initial diagnosis of patients with multiple myeloma bone disease, use of an imaging test with a superior detection rate such as WBLDCT would find more lesions and

**Table 5.** Guidelines and suggestions for use of advanced imaging techniques for multiple myeloma

<b>Imaging techniques</b>	<b>Suggestions for use</b>
CT/WBLDCT	<ul style="list-style-type: none"> <li>• Consider for patients with bony pain and negative skeletal survey; higher detection rate of smaller lesions not seen on conventional radiography, especially in spine and pelvis</li> <li>• Pathologic fracture risk assessment</li> <li>• 3D imaging for CT-guided biopsy planning and radiotherapy</li> <li>• No contrast or preparation time necessary</li> <li>• Fast acquisition time ideal for patients with bony pain intolerant of longer imaging studies or procedures</li> </ul>
PET/PET-CT	<ul style="list-style-type: none"> <li>• Assesses intraosseous and extraosseous lesions for disease activity</li> <li>• Staging of nonsecretory myeloma</li> <li>• Assesses patients with purported solitary plasmacytoma for more lesions</li> <li>• Monitors metabolic response to therapy</li> </ul>
MRI	<ul style="list-style-type: none"> <li>• Superior sensitivity for imaging the bone marrow compartment</li> <li>• Indicated for patients with neurologic symptoms suggestive of spinal cord or nerve root compression</li> <li>• Staging of nonsecretory myeloma</li> <li>• Best for detection of diffuse bone marrow involvement</li> <li>• MRI of spine useful for diagnosis, follow-up after stem cell transplant, evaluation of disease activity</li> <li>• Complementary CT may be indicated to detect presence of osteolytic lesions</li> </ul>

presumably upstage patients, but definitive studies have yet to be completed defining the prognostic value of WBLDCT. WBLDCT can reliably exclude bone disease to confirm MGUS and complement laboratory monitoring (38). It remains unproven whether clinical benefit could be obtained by treating patients earlier or more aggressively based on WBLDCT findings. Nevertheless, recent data showing that early treatment of smoldering multiple myeloma leads to improved overall survival suggest that a more sensitive imaging method might help to detect lytic lesions and provide earlier treatment and thus improve survival (39).

### Conclusions and Future Perspectives

Although conventional radiography has been in use for decades in patients with multiple myeloma and remains in the guidelines for workup of multiple myeloma, there are significant limitations and drawbacks to its continued use that may be addressed by adoption of novel imaging technology in clinical practice. MRI and FDG-PET/CT have demonstrated clinical utility and prognostic value for patients with multiple myeloma, but widespread use is limited by several factors such as cost, availability, and logistics of use in patients who commonly have severe bone pain and renal insufficiency. As a modern imaging technique, WBLDCT offers superior image quality without need for contrast agents, 3D detail important for planning biopsies as well as orthopedic and radiotherapy interventions, ease of completion, and rapid acquisition time in patients who poorly tolerate lengthy imaging tests (Table 4).

Novel WBLDCT protocols offer these benefits at comparable levels of radiation exposure to conventional radiography. WBLDCT protocols can be implemented with existing CT technology, which would make it widely available as

an alternative to conventional radiography in the initial workup and continued follow-up of patients with multiple myeloma undergoing therapy. MRI and PET imaging are useful adjunctive imaging techniques that provide information about disease activity, intramedullary disease, and EMD (Table 5).

Other important unanswered questions may arise with adoption of WBLDCT. Does a patient with MGUS and a small lytic lesion in the absence of other CRAB criteria need to initiate therapy? Will the 5-mm lytic lesion minimum size threshold suggested by experts to be included in the CRAB criteria be validated as having prognostic significance in prospective studies? Does earlier initiation of treatment based on WBLDCT findings afford patients better survival or prevent onset of skeletal-related events? Future studies are warranted to address these important questions as the experience with use of WBLDCT grows. As a whole, the data supporting the superior detection rate of WBLDCT, FDG-PET, and MRI over WBXR are convincing. Further studies are warranted to explore prognosis and survival with WBLDCT as an initial screening test for bone disease in multiple myeloma in place of WBXR.

### Disclosure of Potential Conflicts of Interest

G.D. Roodman reports receiving a commercial research grant from Eli Lilly and is a consultant/advisory board member for Amgen. No potential conflicts of interest were disclosed by the other authors.

### Acknowledgments

The authors thank David K. Leung of the Columbia University PET Center for assistance with images submitted in Figs. 1 and 2 and Dr. Josien Regelink for granting permission to adapt her data for Table 1.

Received July 1, 2014; revised September 2, 2014; accepted September 22, 2014; published OnlineFirst October 7, 2014.



## References

- Siegel R, Naishadham D, Jemal A. Cancer statistics, 2013. *CA Cancer J Clin* 2013;63:11–30.
- Dimopoulos M, Terpos E, Comenzo RL, Tosi P, Beksac M, Sezer O, et al. International myeloma working group consensus statement and guidelines regarding the current role of imaging techniques in the diagnosis and monitoring of multiple myeloma. *Leukemia* 2009;23:1545–56.
- Durie BGM. The role of anatomic and functional staging in myeloma: Description of Durie/Salmon PLUS staging system. *Eur J Cancer* 2006;42:1539–43.
- Fechtner K, Hillengass J, Delorme S, Heiss C, Neben K, Goldschmidt H, et al. Staging international plasma cell disease: comparison of the Durie-Salmon and the Durie-Salmon PLUS staging systems. *Radiology* 2010;257:195–204.
- Wolf MB, Murray F, Kilk K, Hillengass J, Delorme S, Heiss C, et al. Sensitivity of whole-body CT and MRI versus projection radiography in the detection of osteolyses in patients with monoclonal plasma cell disease. *Eur J Radiol* 2014;83:1222–30.
- Edelstyn GA, Gillespie PJ, Grebbell FS. The radiological demonstration of osseous metastases. Experimental observations. *Clin Radiol* 1967;18:158–62.
- Terpos E, Mouloupoulos LA, Dimopoulos MA. Advances in imaging and the management of myeloma bone disease. *J Clin Oncol* 2011;29:1907–15.
- Helms CA, Genant HK. Computed tomography in the early detection of skeletal involvement with multiple myeloma. *JAMA* 1982;248:2886–7.
- Baur-Melnyk A, Buhmann S, Becker C, Schoenberg SO, Lang N, Bartl R, et al. Whole-body MRI versus whole-body MDCT for staging of multiple myeloma. *AJR Am J Roentgenol* 2008;190:1097–104.
- Regelink JC, Minnema MC, Terpos E, Kamphuis MH, Rajmakers PG, Pieters-van den Bos IC, et al. Comparison of modern and conventional imaging techniques in establishing multiple myeloma-related bone disease: a systematic review. *Br J Haematol* 2013;162:50–61.
- Walker R, Barlogie B, Haessler J, Tricot G, Anaissie E, Shaughnessy JD Jr, et al. Magnetic resonance imaging in multiple myeloma: diagnostic and clinical implications. *J Clin Oncol* 2007;25:1121–8.
- Schreiman JS, McLeod RA, Kyle RA, Beabout JW. Multiple myeloma: evaluation by CT. *Radiology* 1985;154:483–6.
- Horger M, Claussen CD, Bross-Bach U, Vonthein R, Trabold T, Heuschmid M, et al. Whole-body low-dose multidetector row-CT in the diagnosis of multiple myeloma: an alternative to conventional radiography. *Eur J Radiol* 2005;54:289–97.
- Kropil P, Fenk R, Fritz LB, Blondin D, Kobbe G, Modder U, et al. Comparison of whole-body 64-slice multidetector computed tomography and conventional radiography in staging of multiple myeloma. *European Radiol* 2008;18:51–8.
- Gleeson TG, Moriarty J, Shortt CP, Gleeson JP, Fitzpatrick P, Byrne B, et al. Accuracy of whole-body low-dose multidetector CT (WBLDCT) versus skeletal survey in the detection of myelomatous lesions, and correlation of disease distribution with whole-body MRI (WBMRI). *Skeletal Radiol* 2009;38:225–36.
- Princewill K, Kyere S, Awan O, Mulligan M. Multiple myeloma lesion detection with whole body CT versus radiographic skeletal survey. *Cancer Invest* 2013;31:206–11.
- Kloth JK, Hillengass J, Listl K, Kilk K, Hielscher T, Landgren O, et al. Appearance of monoclonal plasma cell diseases in whole-body magnetic resonance imaging and correlation with parameters of disease activity. *Int J Cancer* 2014;135:2380–6.
- Caers J, Withofs N, Hillengass J, Simoni P, Zamagni E, Hustinx R, et al. The role of positron emission tomography-computed tomography and magnetic resonance imaging in diagnosis and follow up of multiple myeloma. *Haematologica* 2014;99:629–37.
- Hillengass J, Landgren O. Challenges and opportunities of novel imaging techniques in monoclonal plasma cell disorders: imaging "early myeloma". *Leuk Lymphoma* 2013;54:1355–63.
- Hillengass J, Weber MA, Kilk K, Listl K, Wagner-Gund B, Hillengass M, et al. Prognostic significance of whole-body MRI in patients with monoclonal gammopathy of undetermined significance. *Leukemia* 2014;28:174–8.
- Lutje S, de Rooy JW, Croockewit S, Koedam E, Oyen WJ, Raymakers RA. Role of radiography, MRI and FDG-PET/CT in diagnosing, staging and therapeutical evaluation of patients with multiple myeloma. *Ann Hematol* 2009;88:1161–8.
- Zamagni E, Cavo M. The role of imaging techniques in the management of multiple myeloma. *Br J Haematol* 2012;159:499–513.
- Castellani M, Carletto M, Baldini L, Calori R, Longari V, Soligo D, et al. The prognostic value of F-18 fluorodeoxyglucose bone marrow uptake in patients with recent diagnosis of multiple myeloma: a comparative study with Tc-99m sestamibi. *Clinical Nucl Med* 2010;35:1–5.
- Haznedar R, Aki SZ, Akdemir OU, Ozkurt ZN, Celeni O, Yagci M, et al. Value of 18F-fluorodeoxyglucose uptake in positron emission tomography/computed tomography in predicting survival in multiple myeloma. *Eur J Nucl Med Mol Imaging* 2011;38:1046–53.
- Cook GJ, Wegner EA, Fogelman I. Pitfalls and artifacts in 18FDG PET and PET/CT oncologic imaging. *Semin Nucl Med* 2004;34:122–33.
- Healy CF, Murray JG, Eustace SJ, Madewell J, O'Gorman PJ, O'Sullivan P. Multiple myeloma: a review of imaging features and radiological techniques. *Bone Marrow Research* 2011;2011:583439.
- Zamagni E, Nanni C, Patriarca F, Englaro E, Castellucci P, Geatti O, et al. A prospective comparison of 18F-fluorodeoxyglucose positron emission tomography-computed tomography, magnetic resonance imaging and whole-body planar radiographs in the assessment of bone disease in newly diagnosed multiple myeloma. *Haematologica* 2007;92:50–5.
- Dankerl A, Liebisch P, Glatting G, Friesen C, Blumstein NM, Kocot D, et al. Multiple myeloma: molecular imaging with 11C-methionine PET/CT—initial experience. *Radiology* 2007;242:498–508.
- Agool A, Schot BW, Jager PL, Vellenga E. 18F-FLT PET in hematologic disorders: a novel technique to analyze the bone marrow compartment. *J Nucl Med* 2006;47:1592–8.
- Bartel TB, Haessler J, Brown TL, Shaughnessy JD Jr, van Rhee F, Anaissie E, et al. F18-fluorodeoxyglucose positron emission tomography in the context of other imaging techniques and prognostic factors in multiple myeloma. *Blood* 2009;114:2068–76.
- Horger M, Kanz L, Denecke B, Vonthein R, Pereira P, Claussen CD, et al. The benefit of using whole-body, low-dose, nonenhanced, multidetector computed tomography for follow-up and therapy response monitoring in patients with multiple myeloma. *Cancer* 2007;109:1617–26.
- Mahnken AH, Wildberger JE, Gehbauer G, Schmitz-Rode T, Blaum M, Fabry U, et al. Multidetector CT of the spine in multiple myeloma: comparison with MR imaging and radiography. *AJR Am J Roentgenol* 2002;178:1429–36.
- Hillengass J, Fechtner K, Weber MA, Bauerle T, Ayyaz S, Heiss C, et al. Prognostic significance of focal lesions in whole-body magnetic resonance imaging in patients with asymptomatic multiple myeloma. *J Clin Oncol* 2010;28:1606–10.
- Mulligan ME, Badros AZ. PET/CT and MR imaging in myeloma. *Skeletal Radiol* 2007;36:5–16.
- Usmani SZ, Heuck C, Mitchell A, Szymonifka J, Nair B, Hoering A, et al. Extramedullary disease portends poor prognosis in multiple myeloma and is over-represented in high-risk disease even in the era of novel agents. *Haematologica* 2012;97:1761–7.
- Wu P, Davies FE, Boyd K, Thomas K, Dines S, Saso RM, et al. The impact of extramedullary disease at presentation on the outcome of myeloma. *Leuk Lymphoma* 2009;50:230–5.
- Durie BG, Kyle RA, Belch A, Bensinger W, Blade J, Boccadoro M, et al. Myeloma management guidelines: a consensus report from the Scientific Advisors of the International Myeloma Foundation. *Hematol J* 2003;4:379–98.
- Spira D, Weisel K, Brodoefel H, Schulze M, Kaufmann S, Horger M. Can whole-body low-dose multidetector CT exclude the presence of myeloma bone disease in patients with monoclonal gammopathy of undetermined significance (MGUS)? *Acad Radiol* 2012;19:89–94.
- Mateos MV, Hernandez MT, Giraldo P, de la Rubia J, de Arriba F, Lopez Corral L, et al. Lenalidomide plus dexamethasone for high-risk smoldering multiple myeloma. *N Engl J Med* 2013;369:438–47.

40. Nanni C, Rubello D, Zamagni E, Castellucci P, Ambrosini V, Montini G, et al. 18F-FDG PET/CT in myeloma with presumed solitary plasmocytoma of bone. *In Vivo* 2008;22:513-7.
41. Nanni C, Zamagni E, Farsad M, Castellucci P, Tosi P, Cangini D, et al. Role of 18F-FDG PET/CT in the assessment of bone involvement in newly diagnosed multiple myeloma: preliminary results. *Eur J Nucl Med Mole Imaging* 2006;33:525-31.
42. Baur A, Stabler A, Nagel D, Lamerz R, Bartl R, Hiller E, et al. Magnetic resonance imaging as a supplement for the clinical staging system of Durie and Salmon? *Cancer* 2002;95:1334-45.
43. Lecouvet FE, Malghem J, Michaux L, Maldague B, Ferrant A, Michaux JL, et al. Skeletal survey in advanced multiple myeloma: radiographic versus MR imaging survey. *Br J Haematol* 1999;106:35-9.
44. Agren B, Rudberg U, Isberg B, Svensson L, Aspelin P. MR imaging of multiple myeloma patients with bone-marrow transplants. *Acta Radiol* 1998;39:36-42.
45. Kusumoto S, Jinnai I, Itoh K, Kawai N, Sakata T, Matsuda A, et al. Magnetic resonance imaging patterns in patients with multiple myeloma. *Br J Haematol* 1997;99:649-55.
46. Tertti R, Alanen A, Remes K. The value of magnetic resonance imaging in screening myeloma lesions of the lumbar spine. *Br J Haematol* 1995;91:658-60.
47. Ludwig H, Fruhwald F, Tscholakoff D, Rasoul S, Neuhold A, Fritz E. Magnetic resonance imaging of the spine in multiple myeloma. *Lancet* 1987;2:364-6.
48. Ghanem N, Lohrmann C, Engelhardt M, Pache G, Uhl M, Saueressig U, et al. Whole-body MRI in the detection of bone marrow infiltration in patients with plasma cell neoplasms in comparison to the radiological skeletal survey. *Eur Radiol* 2006;16:1005-14.
49. Bredella MA, Steinbach L, Caputo G, Segall G, Hawkins R. Value of FDG PET in the assessment of patients with multiple myeloma. *AJR Am J Roentgenol* 2005;184:1199-204.
50. Hur J, Yoon CS, Ryu YH, Yun MJ, Suh JS. Efficacy of multidetector row computed tomography of the spine in patients with multiple myeloma: comparison with magnetic resonance imaging and fluorodeoxyglucose-positron emission tomography. *J Comput Assist Tomogr* 2007;31:342-7.
51. Horger M, Pereira P, Claussen CD, Kanz L, Vonthein R, Denecke B, et al. Hyperattenuating bone marrow abnormalities in myeloma patients using whole-body non-enhanced low-dose MDCT: correlation with haematological parameters. *Br J Radiol* 2008;81:386-96.
52. Ippolito D, Besostri V, Bonaffini PA, Rossini F, Di Lelio A, Sironi S. Diagnostic value of whole-body low-dose computed tomography (WBLDCT) in bone lesions detection in patients with multiple myeloma (multiple myeloma). *Eur J Radiol* 2013;82:2322-7.