

Dithizone Staining of Myeloid Granules

By WILLIAM F. McNARY, JR.

IN 1953 Mager, McNary and Lionetti published a histochemical method for the detection of zinc.^{1, 2} The technic is based on the ability of a chelating agent, dithizone, to form colored complexes with metals and has been applied to investigate the pancreatic islets³ and the prostate gland.⁴ The specificity of the method for zinc is controlled by a complex buffer. This buffer is essential to the technic as dithizone alone will react with 17 different metals. On the other hand, when a dithizone-acetone-water system is used for tissue staining most of the metallic ions present within the tissue are stained. This mixture, while not as specific as the dithizone-complex buffer mixture, has proven useful as a simple and rapid screening method. In a preliminary report from our laboratories, Chauncy et al.⁵ described a dithizone staining method applied to the formed elements of blood. In 1953 we were unable to confirm this report as in our hands neither the dithizone-acetone-water nor the dithizone-complex buffer solutions gave reproducible results when applied to air dried blood smears. The present investigation offers a simple, rapid and reproducible method by which leukocytes may be stained with dithizone.

METHODS AND MATERIALS

Human blood was obtained by finger puncture, smeared on chemically clean slides and rapidly air dried. Touch preparations were made from the popliteal lymph node of the rat and bone marrow obtained from the rat femur. Pieces of bone marrow and lymph node were fixed in formal-calcium and 95% alcohol, treated with increasing grades of alcohol and xylol, and embedded in paraffin. Sections were cut at 6 microns, floated on warm water, mounted on albuminized slides and dried 24 hours before use.

Required Solutions

A. 0.01% dithizone in absolute acetone (this solution may be stored in brown bottles in the refrigerator for a year or more).

B. Zinc-free water (distilled water extracted with dithizone in CCl₄ until all zinc is removed).

C. Complex-forming buffer.

Sodium thiosulfate pentahydrate..... 550 Gm.

Sodium acetate trihydrate..... 90 Gm.

Potassium cyanide..... 10 Gm.

Dissolve in

Zinc-free water..... 1000 ml.

Adjust to pH 5.5 with glacial acetic acid.

Add

Zinc-free water to make 2000 mls.

D. 1 N acetic acid.

E. 20% sodium potassium tartrate.

Staining solutions

Dithizone-acetone-water

Dilute 1.5 parts of solution A with 1 part of zinc-free water.

From the Department of Anatomy, Boston University Medical School.

Submitted Oct. 5, 1956; accepted for publication Jan. 27, 1957.

Dithizone-complex buffering solution

Solution A.....	24 ml.
Zinc-free water.....	18 ml.
Adjust to pH 3.7 with 1 N acetic acid.	
Solution C.....	5.8 ml.
Solution E.....	0.2 ml.

Staining method

1. Prepare fresh air-dried blood smears.
2. Dip quickly 2 to 3 times in distilled water and drain.
3. Place on staining rack and flood with staining solution (dithizone-acetone-water or dithizone-complex buffer).
4. Allow to stain until staining solution has changed from clear green to straw yellow.
5. Rinse in 3 changes of distilled water.
6. Stain 15 minutes in 0.1% aqueous azur II.
7. Mount in glycerolgel or kyro corn syrup.

RESULTS

A low power field of a normal blood smear stained with dithizone-acetone-water solution exhibited many scattered, golden-brown cells. Upon closer inspection these cells were seen to be polymorphonuclear and containing stained granules and cytoplasm. The number, size, shape and size of granules indicated that the great majority of these cells were neutrophils. When studied under oil immersion the neutrophil was generally rounded and contained yellow homogenous cytoplasm with bronze granules. The nucleus was stained light blue (fig. 1). An occasional eosinophil was encountered. The staining of this cell was somewhat similar to that of the neutrophil. The eosinophil, however, was larger and contained many large, round, refractile granules. Monocytes and lymphocytes were stained pale blue but contained no dithizone reactive material (fig. 2). If the dithizone stain was employed on air-dried smears before laking the erythrocytes in distilled water, the staining was erratic and often negative.

In 1953 Lillie et al.⁶ studied the neutrophil granule reaction to Sudan stains and the peroxidase staining methods. They distinguished the peroxidase staining of the cell from sudanophilia by employing a variety of chemical treatments. They were able to divide these chemicals into three groups, those which destroy sudanophilia, those which destroy peroxidase, and those which destroy both reactions. Using these results the dithizone staining of neutrophil granules was compared to sudanophilia and peroxidase staining. An examination of table 1 shows that dithizone staining differs from sudanophilia and peroxidase staining of the granules.

Touch preparations of bone marrow and lymph node were stained with dithizone-acetone-water. The bone marrow preparations exhibited a large population of stained cells ranging from large, sparsely granulated elements to smaller, densely granular cells. Lymph node preparations were negative except for an occasional eosinophil. Bone marrow sections were positive while sections of lymph node were essentially negative.

When dithizone-complex buffer solution was applied to air-dried, laked blood smears and bone marrow preparations, the neutrophils exhibited only light yellow-pink cytoplasm with negative granules.

Investigations concerning the presence of trace metals in leukocytes have shown that a high concentration of zinc is present in normal human leukocytes.⁷

Furthermore, the concentration of zinc has been found to be greatly reduced in leukemic leukocytes.⁸ For this reason, it was thought of interest to apply the dithizone staining methods to leukemic leukocytes. Blood smears were obtained from a case of chronic myelogenous leukemia (leukocyte count of 400,000 cu.

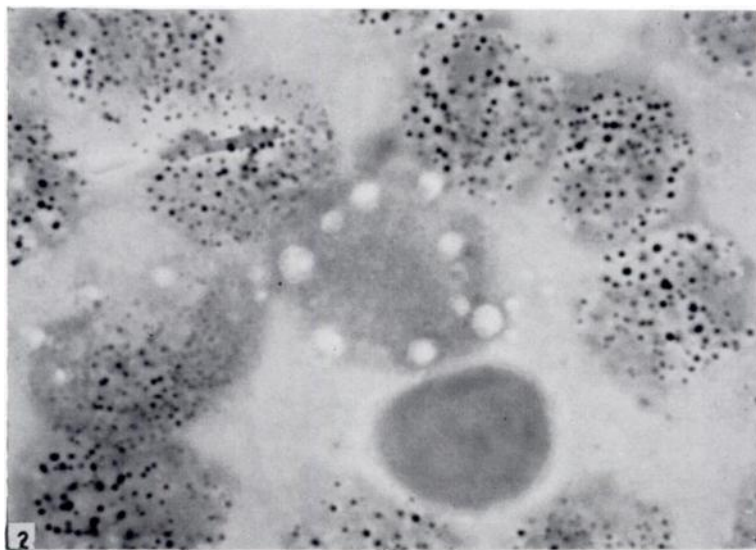
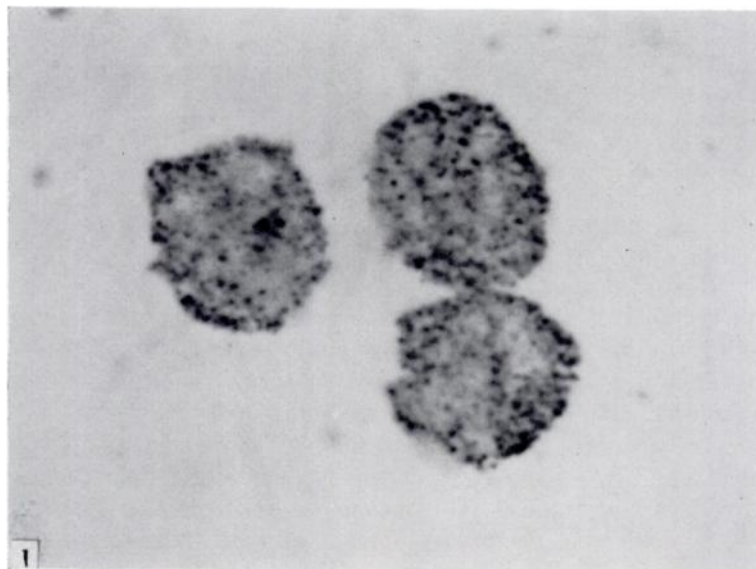


FIG. 1.—Three neutrophil leukocytes from a normal blood smear. Stained with dithizone-acetone-water. Note the regularity of the granules and the cytoplasmic staining. 1650 \times .

FIG. 2.—Neutrophil leukocytes of chronic myelogenous leukemia. Stained with dithizone-acetone-water. Note the irregularity of the granules and the lack of cytoplasmic staining. The vacuolate agranular cell and the lymphocyte contain no dithizone reactive material. 1650 \times .

TABLE 1.—*Effect of Various Chemical Treatments on Dithizone, Sudan and Peroxidase Staining of Neutrophil Granules*

Treatment	Dithizone	Sudanophilia	Peroxidase
Air-dried	+	+	+
75% ethanol (10 min.)	—	+	+
0.3% KCr ₂ O ₄ (1 hour)	—	—	±
Dioxane (1 hour)	—	—	—
10% Formal-calcium (1 day)	+	+	—
1% aq. Periodic acid (1 hour)	—	—	—
50% ethanol 60 C (1 hour)	—	+	—
H ₂ O (dist.) (1 hour)	+	+	±
10% Versene (10 min.)	—	+	—
1% HCl (2 min.)	—	+	—

mm). The cells in this type of leukemia exhibited large dithizone stained granules with no background cytoplasmic staining. Unlike those in normal leukocytes these granules were very variable in size, ranging from large, irregular structures to extremely fine granules. It was also apparent that there were fewer granules within each cell (fig. 2).

DISCUSSION

Dithizone may be used to stain the cytoplasmic granules in myeloid cells. This fact, alone, lends some importance to the staining method. It is at times necessary to distinguish myeloid cells from lymphoid cells in some leukemias and in spinal fluid examinations. The routine methods employed for this purpose have been the peroxidase methods. These methods, while reliable and tested, have the disadvantage of requiring special chemical solutions which must be freshly prepared. It is suggested that the dithizone method should be tried in these cases as it is simple, rapid and the chemical solutions may be stored under refrigeration up to a year or more.

The importance of laking the erythrocyte should be emphasized. It was found that, when dithizone was applied to air-dried blood smears without previously laking the erythrocytes, the color change of the stain occurred very rapidly and staining of the leukocytes was erratic or negative. It appears that laking the erythrocyte removes some substance which because of its reactivity is interfering with the dithizone-granule reaction. This substance could either be zinc associated with carbonic anhydrase or iron associated with hemoglobin. It is more likely a combination of these ions. Laking the erythrocyte removes a sufficient amount of the interfering substances to allow the dithizone-granule reaction to occur. This explains previous failures to stain the myeloid granules with the dithizone methods as laking the erythrocytes was not included in the original staining technics. It also explains the necessity of using fresh air-dried smears as the erythrocytes in older smears do not lake.

The results obtained using chemical solutions to compare the dithizone staining ability of the cell granules with sudanophilia and peroxidase staining indicate that the chemical treatments used either differentially removed the dithizone reactive substance or changed the physical and chemical properties of the granules rendering a change in staining characteristics.

Failure of the granules to stain with the dithizone-complex buffer solution eliminates zinc as the metallic ion staining with dithizone. On the other hand, a high concentration of zinc is known to occur in leukocytes. The cytoplasmic staining seen both with the dithizone-acetone-water and dithizone-complex buffer solutions indicates that the leukocyte zinc is cytoplasmic. To further substantiate this it has been shown that leukemic cells, which are known to be low in zinc, also fail to show cytoplasmic staining.

SUMMARY

A dithizone-acetone-water solution may be used to stain myeloid granules in blood smears and bone marrow preparations. It is necessary to lake the erythrocyte before staining in order to remove interfering substances. The results indicate that zinc, known to be present in leukocytes, is cytoplasmic and not associated with the myeloid granules. It is suggested that the method described may be of value to complement the peroxidase stain as it is rapid, simple, and utilizes solutions which may be stored for lengthy periods.

SUMMARIO IN INTERLINGUA

Un solution aquose de dithizona e acetona pote esser usate pro colorar granulos myeloide in frottis de sanguine e preparatos de medulla ossee. Il es necessari laccar le erythrocytos ante le coloration pro eliminar substantias obstructive. Le resultatos indica que zinc (que es cognoscite presente in leucocytos) es cytoplasmic e non associate con le granulos myeloide. Es formulate le opinion que iste methodo va possiblemente esser de valor como complemento del coloration a peroxidase, proque illo es rapide, simple, e distingue per le facto que le solutiones requirite in illo pote esser immagasinate durante longe periodos de tempore.

REFERENCES

- ¹ MAGER, M., McNARY, W. F., AND LIONETTI, F.: The histochemical detection of zinc. *J. Histochem. & Cytochem.* 1: 493, 1953.
- ² LILLIE, R. D.: *Histopathologic Technic and Practical Histochemistry*. New York, Blakiston, 1954.
- ³ McNARY, W. F.: Zinc-dithizone reaction of pancreatic islets. *J. Histochem. & Cytochem.* 2: 185, 1954.
- ⁴ GUNN, S. A., AND GOULD, T. C.: Difference between dorsal and lateral components of dorsolateral prostate of rat in Zn⁶⁵ uptake. *Proc. Soc. Exper. Biol. & Med.* 92: 17, 1956.
- ⁵ CHAUNCEY, H. H., AND LIONETTI, F.: Histochemical use of dithizone. *Fed. Proc.* 11: 196, 1952.
- ⁶ LILLIE, R. D., AND BURTNER, A. J.: Stable sudanophilia of human neutrophil leukocytes in relation to peroxidase and oxidase. *J. Histochem. & Cytochem.* 1: 8, 1953.
- ⁷ VALLEE, B. L., AND GIBSON, J. G.: The zinc content of whole blood, plasma, leukocytes and erythrocytes in the anemias. *Blood* 4: 455, 1949.
- ⁸ —, AND ALTSCHULE, M. D.: "Trace" metals in blood, with particular reference to zinc and carbonic anhydrase. *Blood* 4: 398, 1949.