

S100A6 Is Increased in a Stepwise Manner during Pancreatic Carcinogenesis: Clinical Value of Expression Analysis in 98 Pancreatic Juice Samples

Kenoki Ohuchida,¹ Kazuhiro Mizumoto,¹ Jun Yu,¹ Hiroshi Yamaguchi,² Hiroyuki Konomi,¹ Eishi Nagai,¹ Koji Yamaguchi,¹ Masazumi Tsuneyoshi,² and Masao Tanaka¹

¹Department of Surgery and Oncology and ²Department of Anatomic Pathology, Graduate School of Medical Sciences, Kyushu University, Fukuoka, Japan

Abstract

There are few reports describing the diagnostic significance of *S100A6* expression in clinical samples obtained from patients with pancreatic disease. In the present study, we measured *S100A6* expression in pancreatic tissues and juice to evaluate its involvement in pancreatic carcinogenesis. We did quantitative real-time reverse transcription-PCR to measure mRNA expression in microdissected cells and pancreatic juice samples. Microdissected invasive ductal carcinoma and intraductal papillary mucinous neoplasm (IPMN) cells expressed significantly higher levels of *S100A6* than did microdissected pancreatitis-affected epithelial and normal cells (all comparison; $P < 0.008$). Median levels of *S100A6* in invasive ductal carcinoma were higher than those in IPMN, and those in pancreatitis-affected epithelial cells tended to be higher than those in normal cells, although these differences were not statistically significant. In

analyses of pancreatic juice, IPMN and pancreatic cancer samples expressed significantly higher levels of *S100A6* than did chronic pancreatitis samples (both; $P < 0.017$), but levels in pancreatic cancer and IPMN samples did not differ from each other. Receiver operating characteristic (ROC) curve analysis revealed that measurement of *S100A6* was useful for discriminating cancer (area under the ROC curve, 0.864) or IPMN (area under the ROC curve, 0.749) from chronic pancreatitis. The present data suggest that expression of *S100A6* is increased in a stepwise manner during pancreatic carcinogenesis and may be a biomarker for evaluating malignant potential. Measurement of *S100A6* in pancreatic juice may be useful to detect early pancreatic cancer or identify individuals with high-risk lesions that may progress to pancreatic cancer. (Cancer Epidemiol Biomarkers Prev 2007;16(4):649–54)

Introduction

Pancreatic cancer is considered one of the most lethal forms of cancer because it is difficult to diagnose early and it is resistant to conventional therapies (1). The major symptoms at presentation are not sufficiently diagnostic because they are consistent with benign or inflammatory disease processes.

The importance of distinguishing pancreatic cancer and chronic pancreatitis is highlighted by reports that 5% to 10% of resected pancreatic tissues are eventually determined to be pancreatitis rather than pancreatic cancer (2). However, there is considerable overlap of the symptoms and clinical data for pancreatic cancer and pancreatitis. This overlap may in part reflect the potential for pancreatic cancer to arise in an environment of pancreatitis and the ability of pancreatic cancer to induce secondary inflammatory processes.

Cystic lesions of the pancreas are being detected with increasing frequency due to application of advanced diagnostic imaging technologies. Intraductal papillary mucinous neoplasm (IPMN) is the most common cystic neoplasm of the pancreas and was described initially by Ohhashi et al. (3) in 1982. IPMN is a precursor lesion of a subset of pancreatic cancer and is often associated with pancreatic cancer occurring as a separate lesion or as carcinoma derived from IPMN (4).

Thus, it is important to distinguish pancreatic cancer from IPMN as well as from chronic pancreatitis.

Despite improvements in diagnostic modalities, it is still difficult to distinguish a small, resectable pancreatic cancer from chronic pancreatitis or IPMN. Early detection and diagnosis of pancreatic cancer would certainly improve patient survival. Therefore, novel screening and diagnostic tools are needed.

We and other investigators reported that both *S100A6* mRNA and protein are overexpressed in pancreatic cancer (5–7), suggesting that *S100A6* may be a promising diagnostic marker of pancreatic cancer. Although the role of *S100A6* has yet to be clearly defined, it has been implicated in several cellular processes, such as cell proliferation and invasion (5, 8). In our previous study, we showed that *S100A6* is differentially expressed between normal epithelial ductal cells or pancreatic intraepithelial neoplasia (PanIN), which is a precursor lesion of pancreatic cancer (9), and invasive ductal carcinoma (IDC; ref. 5). In the present study, to refine our understanding of the involvement of *S100A6* in pancreatic carcinogenesis, we analyzed *S100A6* expression in IPMN and pancreatitis-affected epithelial (PAE) cells, only small percentage of which have the potential to progress to pancreatic cancer (10, 11). In addition, to clarify the clinical significance of *S100A6* mRNA expression in clinical samples, such as pancreatic juice, we used one-step quantitative real-time reverse transcription-PCR (RT-PCR) with gene-specific priming, short amplicons, and normalization to reference genes. It was reported recently that gene expression could be measured reliably from degraded RNA with this procedure (12–14). We successfully measured *S100A6* expression from degraded RNA in pancreatic juice samples from patients with IPMN and compared expression levels with those in pancreatic juice from patients with pancreatic cancer or chronic pancreatitis.

Received 2/27/06; revised 11/6/06; accepted 1/25/07.

Grant support: Grant-in-Aid from the Ministry of Education, Culture, Sports, Science and Technology of Japan, Japan Society for the Promotion of Science for Young Scientists Research Fellowships, and Japanese Foundation for Research and Promotion of Endoscopy grant.

The costs of publication of this article were defrayed in part by the payment of page charges. This article must therefore be hereby marked *advertisement* in accordance with 18 U.S.C. Section 1734 solely to indicate this fact.

Requests for reprints: Kazuhiro Mizumoto, Department of Surgery and Oncology, Graduate School of Medical Sciences, Kyushu University, 3-1-1 Maidashi, Fukuoka 812-8582, Japan. Phone: 81-92-642-5440; Fax: 81-92-642-5458. E-mail: mizumoto@med.kyushu-u.ac.jp

Copyright © 2007 American Association for Cancer Research.

doi:10.1158/1055-9965.EPI-06-0157

Materials and Methods

Pancreatic Tissues and Pancreatic Juice. Tissue samples were obtained from the primary tumor of each resected pancreas or from peripheral tissues away from the tumor at the time of surgery at Kyushu University Hospital (Fukuoka, Japan) as described previously (15). Experienced pathologists did histologic examination of all tissues adjacent to the specimens. Pancreatic juice samples were collected from 102 patients with various pancreatic diseases and 5 patients without pancreatic disease who underwent endoscopic retrograde cholangiopancreatography for suspected malignancy of the pancreas at Kyushu University Hospital between January 1, 2002 and August 31, 2005 as described previously (16). We used pellets of cellular material from pancreatic juice for preparation of RNAs. We eventually excluded the data of nine samples in the pancreatic juice analyses. Three of these nine samples were excluded because neither signals for *S100A6* nor β -actin was detected with real-time RT-PCR, possibly due to improper sampling, handling, or storage of samples. Two of the remaining six samples were excluded because of DNA contamination, which was confirmed by RT-minus experiments. The remaining four samples, which were from pancreatitis-affected pancreata, were excluded because *S100A6* could not be measured quantitatively, although β -actin expression was detected. Therefore, the final samples included 98 pancreatic juice specimens, including 26 from patients with pancreatic cancer, 37 from patients with nonmalignant IPMNs, 30 from patients with chronic pancreatitis, and 5 from patients who underwent endoscopic retrograde cholangiopancreatography to rule out pancreatic disease and were then diagnosed with diseases other than pancreatic disease. The diagnosis of pancreatic ductal adenocarcinoma was confirmed by histologic examination of resected specimens when available, but when the case was inoperable, a clinical diagnosis was made based on imaging findings and the subsequent outcome of the patient. Staging of pancreatic cancer was done according to the Japan Pancreas Society classification (17). Chronic pancreatitis or IPMN was diagnosed based on histologic examination of resected specimens or clinical findings at the time of the initial diagnosis and during a follow-up period of at least 12 months that included conventional diagnostic imaging. Cytologic examination was done by experienced cytologists according to the classification described previously (18). Class I comprised benign and nonneoplastic epithelium with no or only slight dysplasia. Class II comprised regenerative or neoplastic epithelium with slight dysplasia. Class III included neoplastic epithelium with mild dysplasia corresponding to adenoma. Class IV contained neoplastic epithelium with moderate dysplasia highly suggestive of adenocarcinoma. Class V was unequivocal malignant epithelium corresponding to adenocarcinoma. Written informed consent was obtained from all patients, and the study was approved by our institution's surveillance committee and conducted according to the Helsinki Declaration.

Isolation of Total RNA. Total RNA was extracted from cell pellets of pancreatic juice according to the standard acid guanidinium thiocyanate-phenol-chloroform protocol (19) with glycogen (Funakoshi, Tokyo, Japan) and from cells isolated by laser microdissection with a PicoPure RNA Isolation kit (Arcturus Bioscience, Mountain View, CA) with DNase I (Roche Diagnostics, Mannheim, Germany) treatment according to the manufacturers' instructions. RNA concentrations in extracts were measured in a NanoDrop ND-1000 spectrophotometer (NanoDrop Technologies, Inc., Rockland, DE), determining the absorbance at 260 and 280 nm ($A_{260/280}$). RNA integrity was assessed with an Agilent Bioanalyzer 2100 (Agilent, Palo Alto, CA).

Quantitative Analysis of *S100A6* mRNA Levels by One-step Real-time RT-PCR with Gene-Specific Priming. We used one-step quantitative real-time RT-PCR with gene-specific priming to examine mRNA levels in various types of clinical samples, which contain weakly or extensively fragmented RNA. A major advantage of this technology is its ability to measure gene expression reliably from fragmented RNA through synthesis of cDNA with gene-specific primers and utilization of short amplicons and normalization (12–14). We used specific primers for *S100A6* and β -actin as described previously (5). One-step quantitative real-time RT-PCR with gene-specific priming was done with a QuantiTect SYBR Green RT-PCR kit (Qiagen, Tokyo, Japan) with a LightCycler Quick System 350S (Roche Diagnostics). The reaction mixture was first incubated at 50°C for 15 min to allow for reverse transcription, where first-strand cDNA was synthesized with a gene-specific primer. PCR was initiated with one cycle of 95°C for 10 min to activate the modified Taq polymerase followed by 45 cycles of 94°C for 15 s, 55°C for 20 s, and 72°C for 10 s and one cycle of 95°C for 0 s, 65°C for 15 s, and +0.1°C/s to 95°C for melting analysis to visualize nonspecific PCR products because different fragments appear as separate distinct melting peaks. Each primer set used in the present study produced a single melting peak and a single prominent band of the expected size on microchip electrophoresis. To confirm the presence of DNA contamination, we did RT-PCR with or without reverse transcriptase. Each sample was run twice, and any sample showing a greater than 10% deviation in the RT-PCR value was tested a third time. Levels of mRNA in each sample were calculated from a standard curve generated with total RNA from Capan-1 human pancreatic cancer cells. Expression of *S100A6* mRNA was normalized to that of β -actin.

Microdissection-Based Quantitative Analysis of *S100A6* mRNA. Frozen tissue samples were cut into 8- μ m-thick sections. One section was stained with H&E for histologic examination. IDC cells from 21 sections, nonmalignant IPMN cells from 28 sections, PAE cells from 20 sections, and normal pancreatic epithelial cells from 19 sections were isolated selectively with a laser microdissection and pressure catapulting system (LMPC, PALM Microlaser Technologies, Bernried, Germany) per the manufacturer's protocols. After microdissection, total RNA was extracted from the selected cells and subjected to real-time RT-PCR for quantitative measurement of *S100A6* mRNA (19). Twenty-eight samples of nonmalignant IPMN cells microdissected in the present study were divided according to the WHO classification (20) into 20 samples of adenoma and 8 samples of borderline tumor (Table 1). Recently, a consensus nomenclature and criteria have been defined for classifying variants as distinctive IPMN subtypes, including gastric type, intestinal type, pancreaticobiliary type, and oncocytic type (21). The 20 samples of adenoma comprised 19 gastric-type IPMNs and 1 intestinal-type IPMN, and the 8 samples of borderline tumor comprised 4 intestinal-type IPMNs and 4 gastric-type IPMNs (Table 1). The proportion of IPMNs with a gastric versus pancreaticobiliary or intestinal phenotype in the present study was very high compared with

Table 1. Grade and type of microdissected nonmalignant IPMNs

Type*	Adenoma [†]	Borderline [†]
Gastric	19	4
Intestinal	1	4
Pancreaticobiliary	0	0
Oncocytic	0	0

*Type was according to classification of IPMN established at the international consensus meeting held in 2003 (21).

[†]Grade was according to the WHO classification (20).

that reported previously (22). In the present study, we used frozen sections, which were usually taken from an area away from the center of the main tumor because the main lesions were fixed with formalin for accurate diagnosis and clinical decision making. Therefore, formalin-fixed, paraffin-embedded, and frozen sections may show significant differences due to the locations within the tumor from which they are most likely taken. In addition, in studies of formalin-fixed and paraffin-embedded samples, most dysplastic lesions are typically selected from many sections, whereas the sections from frozen samples are very limited. Therefore, the studies with formalin-fixed and paraffin-embedded samples typically contain a greater proportion of higher-grade IPMNs than studies with frozen samples. This may underlie the differences in proportion of IPMN type because pancreaticobiliary or intestinal phenotypes are often correlated with high-grade atypia. In the present study, pancreaticobiliary-type and oncocytic-type IPMNs were not included because such samples were unavailable, possibly due to the rarity of such IPMN types in Japan or because we selected nonmalignant IPMN. Representative photomicrographs of gastric-type and intestinal-type IPMNs are shown in Fig. 1.

Statistical Analyses. Data were analyzed by Kruskal-Wallis test if comparisons involved three groups and by Mann-Whitney *U* test and Spearman rank correlation test if comparisons involved two groups because normal distributions were not obtained. Statistical significance was defined as $P < 0.05$. Because we did multiple comparisons, we used Bonferroni correction; therefore, the adjusted significance levels were $P < 0.008$ for microdissection data and $P < 0.017$ for pancreatic juice data. The patient distribution was examined by χ^2 test for categorical variables and by Kruskal-Wallis test for continuous variables. The optimal cutoff points for each marker for discriminating between pancreatic carcinoma or IPMN and chronic pancreatitis were sought by constructing receiver operating characteristic (ROC) curves, which were generated by calculating the sensitivities and specificities of data for each marker at several predetermined cutoff points with the MedCalc statistical software package, version 7.6 (MedCalc, Maria-kerke, Belgium; ref. 23).

Results

Quantitative Analysis of *S100A6* Expression in IDC Cells, Nonmalignant IPMN Cells, PAE Cells, and Normal Epithelial Cells. In our previous study, we evaluated *S100A6* expression in normal pancreas bulk tissues and microdissected

PanIN and normal ductal epithelial cells as counterparts of pancreatic cancer bulk tissues and microdissected IDC cells, respectively (5). Then, we found that pancreatic cancer bulk tissues expressed significantly higher levels of *S100A6* than did normal pancreas bulk tissues and also found that microdissected IDC, PanIN, and normal ductal cells expressed significantly different levels of *S100A6* (5).

In the clinical setting, however, it is important to distinguish pancreatic cancer from benign diseases, such as chronic pancreatitis and nonmalignant IPMN. IPMN and chronic pancreatitis samples frequently show changes in expression of tumor-related genes similar to those in pancreatic cancers (24-27). Thus, to determine whether *S100A6* is differentially expressed between pancreatic cancer, nonmalignant IPMN, and chronic pancreatitis, we did laser microdissection to isolate IDC cells, nonmalignant IPMN cells, PAE cells, and normal epithelial cells and quantified *S100A6* expression in each cell type with one-step quantitative real-time RT-PCR with gene-specific priming. As shown in Fig. 2, IDC cells and IPMN cells expressed significantly higher levels of *S100A6* than did PAE cells and normal epithelial cells (IDC or IPMN versus PAE cells or normal epithelial cells; $P < 0.0001$). IDC cells expressed higher levels of *S100A6* than did nonmalignant IPMN cells; however, this difference was not statistically significant. PAE cells expressed higher levels of *S100A6* than did normal epithelial cells, but this difference also was not statistically significant.

Nonmalignant IPMN is considered to be a precursor lesion of a subset of pancreatic cancer. It was reported that a subset of PAE cells has the potential to progress to pancreatic cancer, although this is very rare (10, 11). PanIN is also a common precursor lesion of pancreatic cancer (9). We reported previously that PanIN cells expressed higher levels of *S100A6* than did normal epithelial cells and lower levels than did IDC cells (5), which was consistent with the results of an immunohistochemical study reported by Vimalachandran et al. (6). Taken together, these data suggest that alteration of *S100A6* expression occurs at a very early stage of pancreatic carcinogenesis and that expression of *S100A6* increases in a stepwise manner during carcinogenesis.

Quantitative Analysis of *S100A6* mRNA Expression in Pancreatic Juice. The results of our microdissection-based analyses of isolated cells suggest that *S100A6* is a promising diagnostic marker to distinguish pancreatic cancer from chronic pancreatitis and nonmalignant IPMN. We analyzed *S100A6* mRNA levels in 93 pancreatic juice samples from patients with various pancreatic diseases. The baseline characteristics of the patients included in the present study are shown in Table 2. The distribution of patients did not

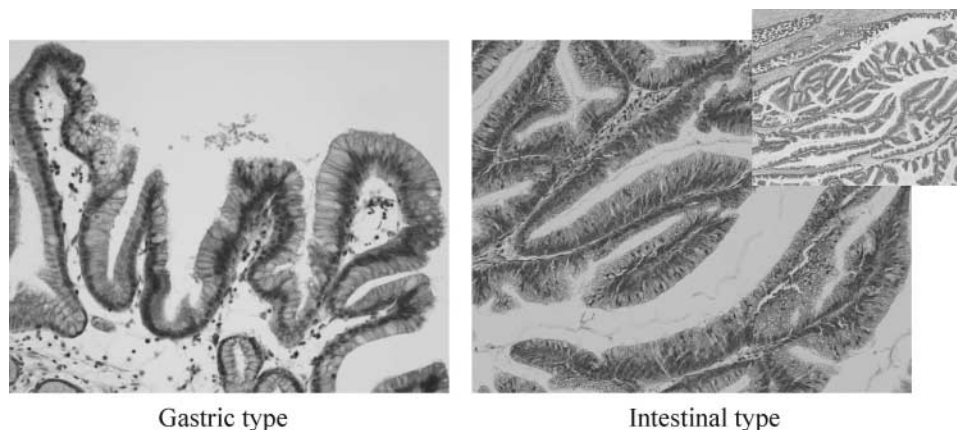


Figure 1. Representative photomicrographs of gastric-type and intestinal-type IPMN. H&E stain. *Inset*, lower magnification.

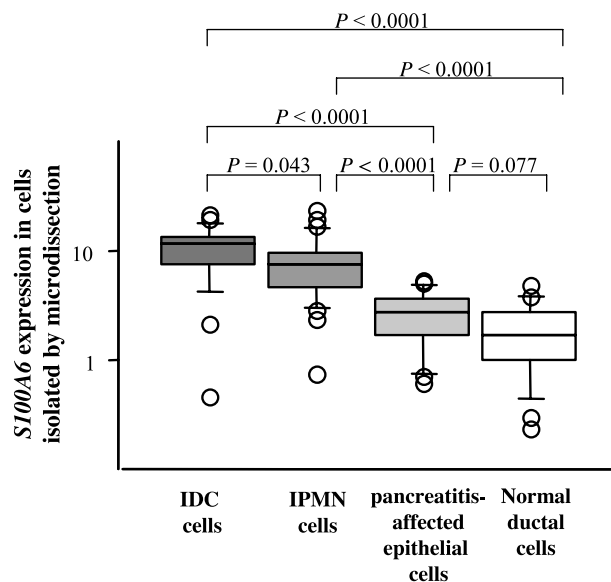


Figure 2. Microdissection-based quantitative analysis of *S100A6*. We isolated IDC cells, nonmalignant IPMN cells, PAE cells, and normal epithelial cells from frozen sections by microdissection and did one-step quantitative real-time RT-PCR with gene-specific priming to analyze expression of *S100A6* in these cells. Expression of *S100A6* was normalized to that of β -actin. We found that IDC cells and IPMN cells express significantly higher levels of *S100A6* than do PAE cells and normal ductal epithelial cells. The median value of *S100A6* in IDC cells was higher than that in IPMN cells, although the difference was not statistically significant ($P = 0.043$). The median value of *S100A6* in PAE cells was higher than that in normal epithelial cells; however, the difference was not statistically significant ($P = 0.077$).

differ significantly for age, sex, or comorbid conditions between patients with pancreatic cancer, nonmalignant IPMN, and chronic pancreatitis. Expression of *S100A6* was significantly higher in pancreatic cancer and IPMN samples than in chronic pancreatitis samples after Bonferroni correction ($P < 0.0001$ for pancreatic cancer versus chronic pancreatitis; $P = 0.0015$ for IPMN versus chronic pancreatitis; Fig. 3). However, *S100A6* expression did not differ significantly between

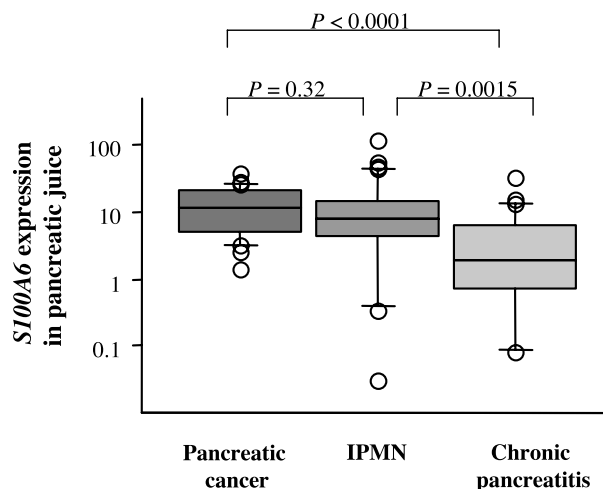


Figure 3. Quantification of *S100A6* mRNA expression in pancreatic juice. Expression of *S100A6* in pancreatic juice samples was analyzed by one-step quantitative real-time RT-PCR with gene-specific priming and short amplicons and normalized to that of β -actin. *S100A6* expression differed significantly between pancreatic juice from patients with cancer and those with chronic pancreatitis ($P < 0.0001$) and between pancreatic juice samples from patients with IPMN and those with chronic pancreatitis ($P = 0.0015$) after Bonferroni correction (*, $P < 0.017$). However, *S100A6* expression did not differ significantly between pancreatic juice samples from patients with cancer and those with IPMN ($P = 0.32$).

pancreatic cancer and IPMN samples ($P = 0.32$; Fig. 3). To investigate *S100A6* mRNA levels in pancreatic juice from normal pancreata, we analyzed five pancreatic juice samples from patients with pancreata, which were confirmed to be normal by endoscopic retrograde cholangiopancreatography, endoscopic ultrasound, and/or computer tomography. We found that *S100A6* mRNA levels were undetectable or extremely low in pancreatic juice samples from normal pancreata compared with levels in neoplastic samples. *S100A6* mRNA levels in normal pancreatic juice were similar to those of pancreatic juice samples from pancreatitis-affected pancreata (data not shown).

Table 2. Baseline characteristics of the study population

	Pancreatic cancer	Nonmalignant IPMN*	Chronic pancreatitis	P^{\dagger}
Age (25%-median-75%), y	57-66-73	55-68-71	54-64.5-75	0.6
Sex (M/F ratio)	1.36	1.06	3.00	0.4
Comorbid conditions (%)				
Cardiovascular disease	19.2	22.9	17.8	0.88
Diabetes	23.1	28.5	21.4	0.79
Pulmonary disease	15.4	11.4	10.7	0.8
Cytology [‡] (%)				
I-II	53.8	90.9	100	<0.0001
III	34.6	9.1	0	
IV-V	11.5	0	0	
Stage [§] of pancreatic cancer (%)				
I-III	19.2			
IVa and IVb	80.7			
Etiology of pancreatitis (%)				
Alcoholic			42.9	
Idiopathic			32.1	
Other			25	
Relative expression of <i>S100A6</i> (25%-median-75%)	5.2-11.3-21.0	4.2-8.2-14.8	0.7-1.7-4.1	<0.0001

*Intraductal papillary mucinous neoplasm.

[†]For continuous variables: P for Kruskal-Wallis test. For categorical variables: P for χ^2 test.

[‡]Cytologic classification was as described in previously (18).

[§]Pancreatic cancer was staged according to Japan Pancreas Society Classification (17).

As shown in Table 2, our pancreatic juice analyses included 5 (19.2%) samples from patients with stage I, II, or III pancreatic cancers and 21 (80.7%) samples from patients with stage IVa and IVb pancreatic cancers. This study also included pancreatic juice samples from patients with chronic pancreatitis with different etiologies (Table 2). However, there were no significant differences in *S100A6* expression between different stages of pancreatic cancers ($P = 0.45$) or between different etiologies of chronic pancreatitis ($P = 0.36$). In the present study, cytologic class IV or V was considered positive for a diagnosis of malignancy. The cytologic sensitivity for diagnosis of pancreatic cancer was only 11.5%, although the specificity was 100% (Table 2). The distribution of atypical grades, including class I or II, class III, and class IV or V, was significantly different between patients with pancreatic cancer, nonmalignant IPMN, and chronic pancreatitis ($P < 0.0001$; Table 2). The distribution of atypical grades was significantly different between patients with pancreatic cancer and those with chronic pancreatitis ($P = 0.0003$) and between patients with pancreatic cancer and those with nonmalignant IPMN ($P = 0.004$). However, there was no significant difference in the distribution of atypical grades between patients with nonmalignant IPMN and chronic pancreatitis ($P = 0.11$). We also examined the correlation between *S100A6* expression and cytologic evaluation and found no significant correlation ($P = 0.31$).

ROC curves for *S100A6* expressions are shown in Fig. 4. The sensitivity of the *S100A6* was determined at several specificity levels. The area under the ROC curve was 0.864 for pancreatic cancer versus chronic pancreatitis [95% confidence interval (95% CI), 0.746-0.941] and 0.749 for IPMN versus chronic pancreatitis (95% CI, 0.615-0.855). The area under the ROC curve was 0.555 for pancreatic cancer versus IPMN (95% CI, 0.416-0.688). In particular, a significant difference between the areas for pancreatic cancer versus chronic pancreatitis and pancreatic cancer versus IPMN was observed (difference between areas, 0.309; 95% CI, 0.178-0.440; $P < 0.001$). These data indicate that measurements of *S100A6* mRNA levels in pancreatic juice may provide some advantage in discriminating pancreatic cancer or IPMN from chronic pancreatitis but not in discriminating pancreatic cancer from IPMN.

Discussion

In the present study, microdissection-based analyses revealed that IDC, nonmalignant IPMN, PAE, and normal epithelial cells expressed different levels of *S100A6*. Previously, we reported that IDC, PanIN, and normal epithelial cells expressed different levels of *S100A6* (5). These data suggest that expression of *S100A6* is increased in a stepwise manner during pancreatic carcinogenesis. The present pancreatic juice analyses revealed that the levels of *S100A6* in pancreatic cancer and IPMN juice samples were significantly higher than those in chronic pancreatitis-juice samples. However, the levels of *S100A6* in pancreatic juice did not differ between pancreatic cancer and IPMN juice samples, which was inconsistent with the results of the present microdissection-based analyses. Apparently, contamination of pancreatic cancer juice samples with premalignant cells could reduce *S100A6* levels measured in total cell pellets from pancreatic juice samples. Thus, to examine the true levels of *S100A6* in highly dysplastic cells in pancreatic juice samples, microdissection of cell pellets from pancreatic juice samples is needed. Such studies are presently under way in our laboratory.

Several pancreatic juice markers, including *k-ras* mutations, telomerase activity, and *hTERT* mRNA, have been reported (16, 28, 29). Recently, mutations of *k-ras* in pancreatitis-affected pancreata and pancreatic cancer were reported (30). Because *k-ras* mutation analysis is qualitative, it may be difficult to

monitor the progression of carcinogenesis, whereas the present *S100A6* mRNA analysis is quantitative. We reported previously that quantitative analysis of telomerase activity is useful for differentiation of pancreatic cancer from nonmalignant IPMN or chronic pancreatitis (16, 29). However, there is no way to check sample quality for telomerase activity assays; therefore, it is difficult to use this assay in routine clinical settings. We also reported that quantitative analysis of *hTERT* mRNA, which is a subunit of telomerase, is useful for distinguishing pancreatic cancer from nonmalignant IPMN (31). Although we can easily check the quality of RNAs, our results suggested that *hTERT* analysis is not useful for distinguishing pancreatic cancer from chronic pancreatitis because relatively high levels of *hTERT* mRNA are expressed by activated lymphocytes in chronic pancreatitis-related pancreatic juice. In the present study, we found that pancreatic cancer and nonmalignant IPMN expressed significantly higher levels of *S100A6* than did chronic pancreatitis-related pancreatic juice samples. Apparently, activation of telomerase or overexpression of *hTERT* mRNA occurs at a later stage of pancreatic carcinogenesis, whereas overexpression of *S100A6* may occur at an early stage of pancreatic carcinogenesis and may increase in a stepwise manner during the progression of pancreatic carcinogenesis. Therefore, compared with telomerase activity and *hTERT* mRNA assays, quantitative analysis of *S100A6* is especially useful for monitoring the progression of carcinogenesis in individuals with high risk of pancreatic cancer, such as those with a familial history or chronic pancreatitis, or for screening individuals with high-risk lesions that may progress to pancreatic cancer.

To date, no single biomarker has been proven to have sufficient diagnostic accuracy to serve as a stand-alone means for early detection and diagnosis of cancer. Thus, biomarkers can be of significant clinical value by providing evidence to

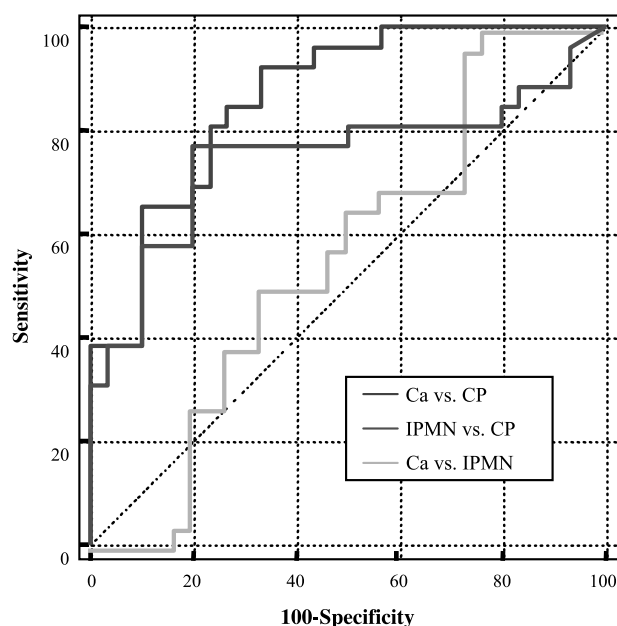


Figure 4. ROC curve analyses of *S100A6* expression in pancreatic juice samples. Sensitivity of *S100A6* analysis was determined at several specificity levels. The areas under the ROC curve were 0.864 for pancreatic cancer versus chronic pancreatitis (95% CI, 0.746-0.941) and 0.749 for IPMN versus chronic pancreatitis (95% CI, 0.615-0.855). The area under the ROC curve was 0.555 for pancreatic cancer versus IPMN (95% CI, 0.416-0.688). The results of ROC curve analyses suggest that *S100A6* expression status can be used to differentiate pancreatic cancer or IPMN from chronic pancreatitis. *Ca*, pancreatic cancer; *CP*, chronic pancreatitis.

suspect cancer or, when combined with other clinical data, to aid in differential diagnosis. In the present study, the *S100A6* analyses of pancreatic juice yielded statistically significant differences between neoplastic samples, such as pancreatic cancer and nonmalignant IPMN and chronic pancreatitis samples, and our microdissection analyses revealed that expression of *S100A6* is increased in a stepwise manner during pancreatic carcinogenesis. Therefore, *S100A6* analysis of pancreatic juice may aid in differential diagnosis if combined with other clinical data and may have some advantages to detect or screen for pancreatic cancer and to follow up with individuals with high-risk factors, such as familial pancreatic cancer.

Acknowledgments

We thank M. Ohta (Department of Clinical Pathology, Kyushu University) for skillful cytologic examination and analysis.

References

- Jemal A, Murray T, Samuels A, Ghafoor A, Ward E, Thun MJ. Cancer statistics, 2003. *CA Cancer J Clin* 2003;53:5–26.
- Taylor B. Carcinoma of the head of the pancreas versus chronic pancreatitis: diagnostic dilemma with significant consequences. *World J Surg* 2003;27:1249–57.
- Ohhashi K, Murakami F, Maruyama M, et al. Four cases of mucous secreting pancreatic cancer [in Japanese with English abstract]. *Prog Dig Endosc* 1982;203:348–351.
- Yamaguchi K, Ohuchida J, Ohtsuka T, Nakano K, Tanaka M. Intraductal papillary-mucinous tumor of the pancreas concomitant with ductal carcinoma of the pancreas. *Pancreatol* 2002;2:484–90.
- Ohuchida K, Mizumoto K, Ishikawa N, et al. The role of *S100A6* in pancreatic cancer development and its clinical implication as a diagnostic marker and therapeutic target. *Clin Cancer Res* 2005;11:7785–93.
- Vimalachandran D, Greenhalf W, Thompson C, et al. High nuclear *S100A6* (calcyclin) is significantly associated with poor survival in pancreatic cancer patients. *Cancer Res* 2005;65:3218–25.
- Logsdon CD, Simeone DM, Binkley C, et al. Molecular profiling of pancreatic adenocarcinoma and chronic pancreatitis identifies multiple genes differentially regulated in pancreatic cancer. *Cancer Res* 2003;63:2649–57.
- Breen EC, Tang K. Calcyclin (*S100A6*) regulates pulmonary fibroblast proliferation, morphology, and cytoskeletal organization *in vitro*. *J Cell Biochem* 2003;88:848–54.
- Hruban RH, Adsay NV, Albores-Saavedra J, et al. Pancreatic intraepithelial neoplasia: a new nomenclature and classification system for pancreatic duct lesions. *Am J Surg Pathol* 2001;25:579–86.
- Lowenfels AB, Maisonneuve P, Cavallini G, et al. Pancreatitis and the risk of pancreatic cancer. International Pancreatitis Study Group. *N Engl J Med* 1993;328:1433–7.
- Karlson BM, Ekblom A, Josefsson S, McLaughlin JK, Fraumeni JF, Jr., Nyren O. The risk of pancreatic cancer following pancreatitis: an association due to confounding? *Gastroenterology* 1997;113:587–92.
- Antonov J, Goldstein DR, Oberli A, et al. Reliable gene expression measurements from degraded RNA by quantitative real-time PCR depend on short amplicons and a proper normalization. *Lab Invest* 2005;85:1040–50.
- Lekanne Deprez RH, Fijnvandraat AC, Ruijter JM, Moorman AF. Sensitivity and accuracy of quantitative real-time polymerase chain reaction using SYBR Green I depends on cDNA synthesis conditions. *Anal Biochem* 2002;307:63–9.
- Lewis F, Maughan NJ, Smith V, Hillan K, Quirke P. Unlocking the archive—gene expression in paraffin-embedded tissue. *J Pathol* 2001;195:66–71.
- Ohuchida K, Mizumoto K, Yamada D, et al. Quantitative analysis of MUC1 and MUC5AC mRNA in pancreatic juice for preoperative diagnosis of pancreatic cancer. *Int J Cancer* 2006;118:405–11.
- Ohuchida K, Mizumoto K, Ogura Y, et al. Quantitative assessment of telomerase activity and human telomerase reverse transcriptase messenger RNA levels in pancreatic juice samples for the diagnosis of pancreatic cancer. *Clin Cancer Res* 2005;11:2285–92.
- Japan Pancreas Society. Classification of pancreatic carcinoma. Second English Edition. Tokyo: Kanehara & Co., Ltd.; 2003.
- Yamaguchi K, Nakamura M, Shirahane K, et al. Pancreatic juice cytology in IPMN of the pancreas. *Pancreatol* 2005;5:416–21; discussion 21.
- Tachikawa T, Irie T. A new molecular biology approach in morphology: basic method and application of laser microdissection. *Med Electron Microsc* 2004;37:82–8.
- World Health Organization classification of tumors: pathology and genetics of tumors of the digestive system. Lyon: IARC Press; 2000.
- Furukawa T, Kloppel G, Volkan Adsay N, et al. Classification of types of intraductal papillary-mucinous neoplasm of the pancreas: a consensus study. *Virchows Arch* 2005;447:794–9.
- Adsay NV, Merati K, Basturk O, et al. Pathologically and biologically distinct types of epithelium in intraductal papillary mucinous neoplasms: delineation of an “intestinal” pathway of carcinogenesis in the pancreas. *Am J Surg Pathol* 2004;28:839–48.
- Zweig MH, Campbell G. Receiver-operating characteristic (ROC) plots: a fundamental evaluation tool in clinical medicine. *Clin Chem* 1993;39:561–77.
- Biankin AV, Biankin SA, Kench JG, et al. Aberrant p16(INK4A) and DPC4/Smad4 expression in intraductal papillary mucinous tumours of the pancreas is associated with invasive ductal adenocarcinoma. *Gut* 2002;50:861–8.
- Soldini D, Gugger M, Burckhardt E, Kappeler A, Laissue JA, Mazzucchelli L. Progressive genomic alterations in intraductal papillary mucinous tumours of the pancreas and morphologically similar lesions of the pancreatic ducts. *J Pathol* 2003;199:453–61.
- Hermanova M, Nenutil R, Kren L, Feit J, Pavlovsky Z, Dite P. Proliferative activity in pancreatic intraepithelial neoplasias of chronic pancreatitis resection specimens: detection of a high-risk lesion. *Neoplasia* 2004;51:400–4.
- Rosty C, Geradts J, Sato N, et al. p16 Inactivation in pancreatic intraepithelial neoplasias (PanINs) arising in patients with chronic pancreatitis. *Am J Surg Pathol* 2003;27:1495–501.
- Tada M, Omata M, Kawai S, et al. Detection of ras gene mutations in pancreatic juice and peripheral blood of patients with pancreatic adenocarcinoma. *Cancer Res* 1993;53:2472–4.
- Ohuchida K, Mizumoto K, Ishikawa N, et al. A highly sensitive and quantitative telomerase activity assay with pancreatic juice is useful for diagnosis of pancreatic carcinoma without problems due to polymerase chain reaction inhibitors: analysis of 100 samples of pancreatic juice from consecutive patients. *Cancer* 2004;101:2309–17.
- Tada M, Ohashi M, Shiratori Y, et al. Analysis of K-ras gene mutation in hyperplastic duct cells of the pancreas without pancreatic disease. *Gastroenterology* 1996;110:227–31.
- Ohuchida K, Mizumoto K, Yamada D, et al. Quantitative analysis of human telomerase reverse transcriptase in pancreatic cancer. *Clin Cancer Res* 2006;12:2066–9.