

The Evolving Modern Management of Brain Metastasis

Peter E. Fecci^{1,2}, Cosette D. Champion^{1,2}, Jacob Hoj³, Courtney M. McKernan³, C. Rory Goodwin^{1,2}, John P. Kirkpatrick^{1,2,4}, Carey K. Anders⁵, Ann Marie Pendergast³, and John H. Sampson^{1,2}



Abstract

The incidence of brain metastases is increasing as cancer therapies improve and patients live longer, providing new challenges to the multidisciplinary teams that care for these patients. Brain metastatic cancer cells possess unique characteristics that allow them to penetrate the blood–brain barrier, colonize the brain parenchyma, and persist in the intracranial environment. In addition, brain metastases subvert the innate and adaptive immune system, permitting evasion of the

antitumor immune response. Better understanding of the above mechanisms will allow for development and delivery of more effective therapies for brain metastases. In this review, we outline the molecular mechanisms underlying development, survival, and immunosuppression of brain metastases. We also discuss current and emerging treatment strategies, including surgery, radiation, disease-specific and mutation-targeted systemic therapy, and immunotherapy.

Introduction

Brain metastases are the most common intracranial tumors in adults, and portend significant morbidity and mortality (1). Depending on the primary tumor, median survival ranges from just 2 to 27 months (2). The most common cancers metastasizing to brain include lung (~50%), breast (15%–20%), melanoma (5%–10%), kidney (7%), and colon (4%–6%). Ironically, as cancer therapies improve and patients live longer with their primary tumors, the incidence of brain metastases is increasing and now approaches 200,000 per year in the United States (3).

Patients harboring brain metastases often present with neurologic symptoms such as headache, cognitive impairment, seizures, and focal deficits, all precipitating declines in quality of life and survival (1). Effective therapies are limited by poor understanding of metastasis tropism, growth, and survival in the brain microenvironment. Furthermore, many systemic therapies fail to penetrate the blood–brain barrier (BBB) and therefore do not accumulate at therapeutic doses (4). A new focus on brain-specific considerations and therapies is warranted.

In this review, we outline the molecular mechanisms favoring brain metastasis and the peculiarities of the brain immune environment that allow metastases to persist and immunothera-

pies to suffer. Finally, we outline the most current treatment strategies, including surgery, radiation, and systemic therapies.

Molecular Pathways Favoring Brain Metastasis

Cancer cells metastasizing to brain are often molecularly and phylogenetically distinct from their primary tumor source (5), possessing added capacities for penetrating the BBB and colonizing the brain microenvironment. Mechanistic considerations are outlined below.

Extravasation and traversing the BBB

The BBB is composed of endothelial cells, pericytes, basement membrane proteins, and astrocytes. To cross the BBB, metastatic cells employ diverse processes, including proteolysis of tight junction proteins by cathepsins and matrix metalloproteinases (Fig. 1; ref. 6). Alternatively, metastatic cells elaborate inflammatory cytokines, chemokines, and soluble factors to disrupt intercellular junctions. These include TGFβ, IL1β, VEGF, and basic fibroblast growth factor (Fig. 1; ref. 7). Finally, some metastatic cells disrupt the BBB by inducing endothelial cell death (8).

Following BBB disruption, metastatic cells primarily employ paracellular migration to enter the brain parenchyma (9). Studies using a cranial window mouse model coupled with multiphoton laser scanning microscopy have permitted visualization of the process (10). Essential steps include the following: (i) size-restricted arrest of tumor cells at vascular branch points; (ii) active extravasation by the tumor cell from the abluminal vessel surface into the perivascular space; (iii) positional maintenance of the tumor cell within the perivascular space; and (iv) angiogenic growth (lung cancer cells and renal cell carcinoma) or vascular cooption (breast cancer cells and melanoma; refs. 10, 11).

Mouse models of brain metastasis have identified several molecules required for tumor cell extravasation, including

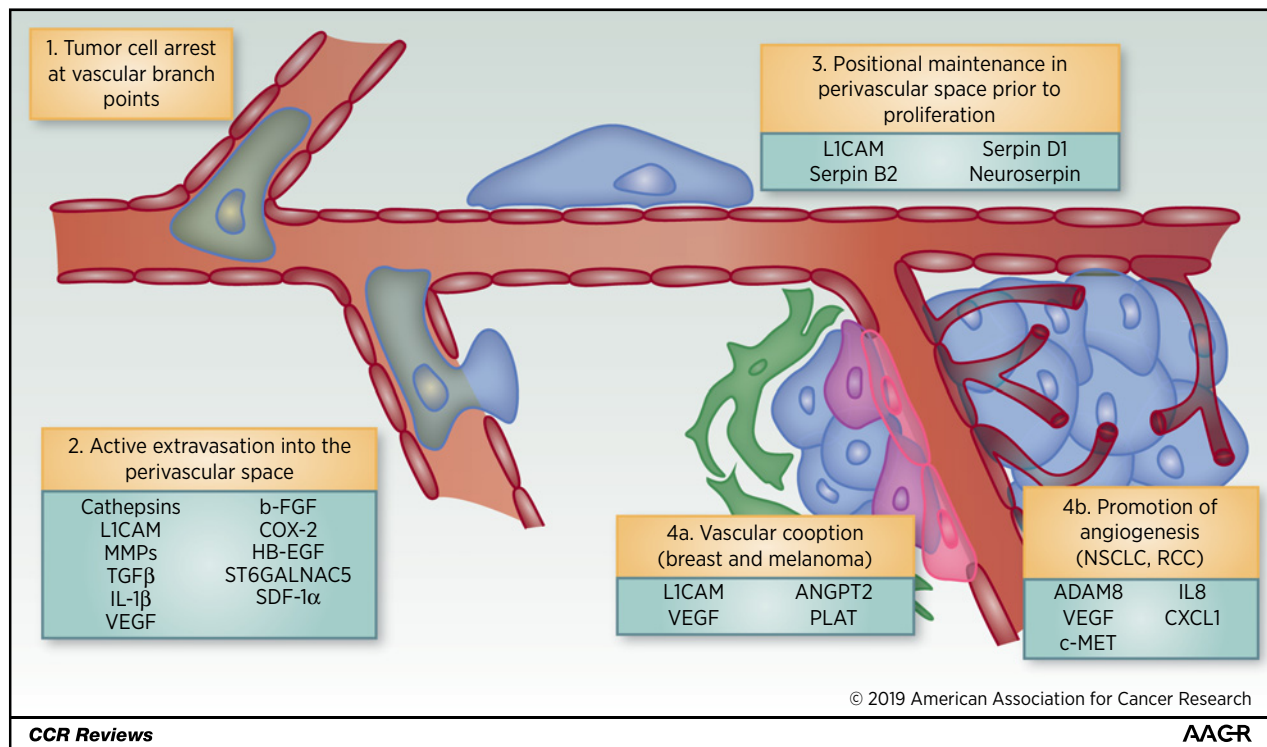
¹Department of Neurosurgery, Duke University Medical Center, Durham, North Carolina. ²Duke Center for Brain and Spinal Metastases, Duke University Medical Center, Durham, North Carolina. ³Department of Pharmacology and Cancer Biology, Duke University School of Medicine, Durham, North Carolina. ⁴Department of Radiation Oncology, Duke University Medical Center, Durham, North Carolina. ⁵Duke Cancer Institute, Division of Medical Oncology, Duke University Medical Center, Durham, North Carolina.

Corresponding Author: John H. Sampson, Duke University Medical Center, DUMC Box 3271, Durham, NC 27710. Phone: 919-684-1043; Fax: 919-684-9045; E-mail: john.sampson@duke.edu

Clin Cancer Res 2019;25:6570–80

doi: 10.1158/1078-0432.CCR-18-1624

©2019 American Association for Cancer Research.

**Figure 1.**

Several steps are required for the initiation and maintenance of brain metastasis of lung cancer, breast cancer, melanoma, and renal cell cancer. Molecules involved at each step are indicated.

L1-Cell Adhesion Molecule (L1CAM), a protein implicated in axon guidance. Elevated expression of L1CAM by arrested tumor cells within the abluminal space of the brain microvasculature promotes tumor cell adhesion to endothelial cells and facilitates vascular cooption (Fig. 1; Table 1; ref. 12). Through vascular cooption, cancer cells interact with the preexisting vasculature, permitting access to angiogenic factors, nutrients, and oxygen. Studies using mouse models suggest that the cancer cells remaining near the perivascular space after extravasation predominantly give rise to proliferating metastases (10).

ADAM9, a member of the disintegrin and metalloprotease family, regulates lung cancer brain metastasis by targeting vascular remodeling at the BBB through regulation of *VEGFA*, *ANGPT2*, and *PLAT* expression (13). Increased ADAM8 expression in triple-negative breast cancer (TNBC) stimulates angiogenesis through the release of VEGF and increases transendothelial migration by activating β1-integrin (14). Activation of the c-MET receptor tyrosine kinase in brain metastatic breast cancer cells promotes perivascular adhesion and neoangiogenesis, in part, through increased expression of IL8 and CXCL1 (15). Cyclooxygenase-2 (COX-2), HB-EGF ligand, and ST6 N-Acetylgalactosaminide Alpha 2,6 Sialyltransferase 5 (ST6GALNAC5) promote breast cancer cell migration across the BBB (Fig. 1; Table 1; ref. 16). Factors secreted by activated brain microvascular endothelial cells such as angiopoietin-2 (Ang-2) disrupt tight junctions and increase BBB permeability to breast cancer cells in mouse models (17). Thus, inhibition of Ang-2 can enhance BBB function and impair progression of brain metastases. Similarly, signaling by the chemokine stro-

mal cell-derived factor 1α (SDF-1α; also known as CXCL12) and its receptor CXCR4 promotes migration of breast cancer cells across the BBB. Treatment with AMD3100, a small-molecule antagonist of SDF-1α, inhibited lung cancer brain metastasis by protecting the BBB (18).

Despite these insights, many questions remain. The majority of the mechanistic studies described above have focused on breast carcinoma and non-small cell lung cancer (NSCLC) as little is known regarding the mechanisms employed by other commonly metastasizing tumor types, including melanoma, renal cell carcinoma, and small-cell lung cancer. Future research may reveal new targets for preventing extravasation of metastatic cells into the brain parenchyma. Moreover, future studies are needed to develop drugs that can effectively cross the BBB, which remains a therapeutic delivery barrier despite the partial opening observed by the intracranial accumulation of small molecules such as gadolinium and other contrast agents. Drug delivery to brain metastases may be prevented, in part, by the abnormal and heterogeneous blood vessels surrounding the metastases and increased tumor interstitial hypertension leading to decreased perfusion thereby impairing drug accumulation at the metastatic sites (19).

Role of astrocytes

Colonization and outgrowth of cancer cells requires adaptation to the brain microenvironment. Such adaptation is mediated by dynamic intercellular interactions between metastatic cells and neighboring astrocytes, which normally function to prevent neuronal damage. Reactive astrocytes destroy metastatic cells by

Table 1. Molecular targets of brain metastasis and their functions

Target	Function	Cancer type	Reference
ST6GALNAC5, COX2, HBEGF	Adhesion to brain endothelial cells and extravasation	Breast	16
SDF-1/CXCR4	Migration, extravasation, and BBB permeability	Lung, breast	18
Serpins, L1CAM	Vascular cooption and survival	Breast, lung	12
PCDH7, Cx43	Forms tumor cell-astrocyte gap junctions, promotes outgrowth	Breast, lung, melanoma	23
Notch signaling	Self-renewal of cancer stem cells in brain	Breast	22
Astrocyte-secreted exosomes	Myeloid recruitment, proliferation, outgrowth	Breast, melanoma	32
ACSS2	Outgrowth in brain	Breast, lung, melanoma	28
cMET	Adhesion to brain endothelial cells, angiogenesis	Breast, lung	15
ADAM9	Migration, angiogenesis	Lung	13
ADAM8	Transendothelial migration, angiogenesis	Breast	14
Endothelin receptors	Promotes survival and interaction with brain microenvironment	Breast, lung, melanoma	24
Angiopoietin-2	Disrupt BBB	Breast, lung	17
STAT3 signaling	Immune cell expansion and activation	Breast, lung, melanoma	20
Hexokinase 2	Outgrowth in brain	Breast	26

producing plasminogen activators (tPA and uPA) that convert plasminogen into plasmin, a protease that can induce Fas ligand (FasL)-mediated apoptosis of cancer cells (12). Plasmin also inactivates L1CAM, restricting vascular cooption by metastases. Metastatic cells, in turn, counteract the effects of plasmin by expressing serpins (neuroserpin and serpin B2) thereby facilitating metastatic colonization (Table 1; Fig. 2; ref. 12).

While astrocytes can indeed restrict brain metastases, they also induce growth-promoting survival pathways within cancer cells, including via STAT3 expression (20). Inactivating STAT3 signaling in reactive astrocytes can decrease brain metastasis in mouse models and humans (Fig. 2; Table 1). Astrocytes also promote proliferation of breast cancer cells through increased expression of Reelin, a secreted glycoprotein that regulates neuronal migration and growth (21). Likewise, activation of c-MET in breast cancer cells promotes brain metastasis, eliciting bidirectional signaling with astrocytes (15). Enhanced tumor cell IL1 β secretion following c-MET activation promotes neighboring astrocytes to secrete HGF, the c-MET ligand, enhancing metastatic cell growth and colonization (Fig. 2; Table 1). IL1 β also elicits enhanced expression of Jagged-1 (JAG1), a Notch ligand (22). Interaction of JAG1 in astrocytes and Notch in breast cancer stem-like cells enhances self-renewal and promotes brain metastasis in mouse models (Fig. 2; ref. 22).

Astrocytes may also protect brain metastases from chemotherapy. Metastatic breast and lung cancer cells engage directly with astrocytes by establishing gap junctions through upregulation of protocadherin 7 and connexin 43 (23). Gap junctions are usurped to transfer c-GAMP to astrocytes, stimulating production of IFN γ and TNF. These cytokines activate transcription factors NF- κ B and STAT1 in brain metastatic cells, resulting in enhanced tumor growth and chemoresistance (Fig. 2; Table 1; ref. 23). Finally,

gap junction signaling between breast cancer cells and astrocytes enhances production of IL6 and IL8 in cancer cells, upregulating endothelin-1 (ET-1) production by astrocytes and leading to chemoprotection (Table 1; ref. 24).

Adaptation of metastatic cells to the brain microenvironment

Survival and growth of brain metastases require adaptations to the unique microenvironment of the brain. Cancer cells must effectively compete with neurons for oxygen and nutrients, often by acquiring neuronal characteristics. To maintain sufficient oxygenation, metastatic cells employ vascular cooption or neoangiogenesis, a target of antiangiogenic therapies (25). Compared with primary tumors, some brain metastases express high levels of hexokinase-2 (HK2), an enzyme that phosphorylates glucose to generate glucose-6-phosphate (26). Brain metastatic cells originating from lung and breast tumors can acquire metabolic adaptations characteristic of neuronal cells including increased expression of the gamma-aminobutyric acid (GABA) transporter and use of GABA as a metabolite to promote metastatic cell growth (27). Brain metastatic cells also upregulate acetyl-CoA synthetase enzyme 2 (ACSS2) to use acetate as a carbon energy source allowing for increased growth in the brain parenchyma (28). Likewise, similar to neurons and glial cells, some metastatic cancer cells release glutamate and uptake glutamine, resulting in an enhanced ability to colonize the brain (29).

Immune Evasion

Intracranial tumors, including metastases, offer unique challenges to the antitumor immune response. A deeper understanding of these challenges can help alter the balance from tumor immune-evasion to tumor destruction.

Primary brain tumors subvert the innate immune response by secreting cytokines that skew glioma-associated macrophages/microglia (GAM) toward the M2 phenotype and suppress the M1 phenotype (30). Brain metastases can elicit a similar phenomenon to create a tumor-permissive environment. In the presence of lung cancer brain metastases, microglia often lack inducible nitric oxide synthase (iNOS) and TNF α , rendering them unable to facilitate phagocytosis and antigen presentation (31). Meanwhile, astrocytes release exosomes containing miR-19a, which can decrease expression of the PTEN tumor suppressor in cancer cells (Fig. 2; Table 1). Metastatic cells lacking PTEN release CCL2, recruiting Iba1⁺ macrophages that promote cancer cell proliferation and survival (32).

T lymphocytes are the mainstay of cancer immunosurveillance and are subject to profound disturbances within the intracranial tumor environment. Regulatory T cells predominate in the tumor microenvironment in patients and mice with melanoma, breast, or colon cancer brain metastases as well as with primary tumors (33, 34). Reactive astrocytes with activated STAT3 signaling restrict T-cell activities during brain metastasis, impairing their activation through secreted factors that decrease immune function (20).

Bone marrow sequestration is a recently characterized phenomenon involving trapping of T cells in the bone marrow in the setting of intracranial tumors specifically, both primary and metastatic (35). Sequestered T cells cannot traffic to the brain and exert their antitumor function. Such sequestration follows loss of the receptor S1P1 from the T-cell surface. In mouse

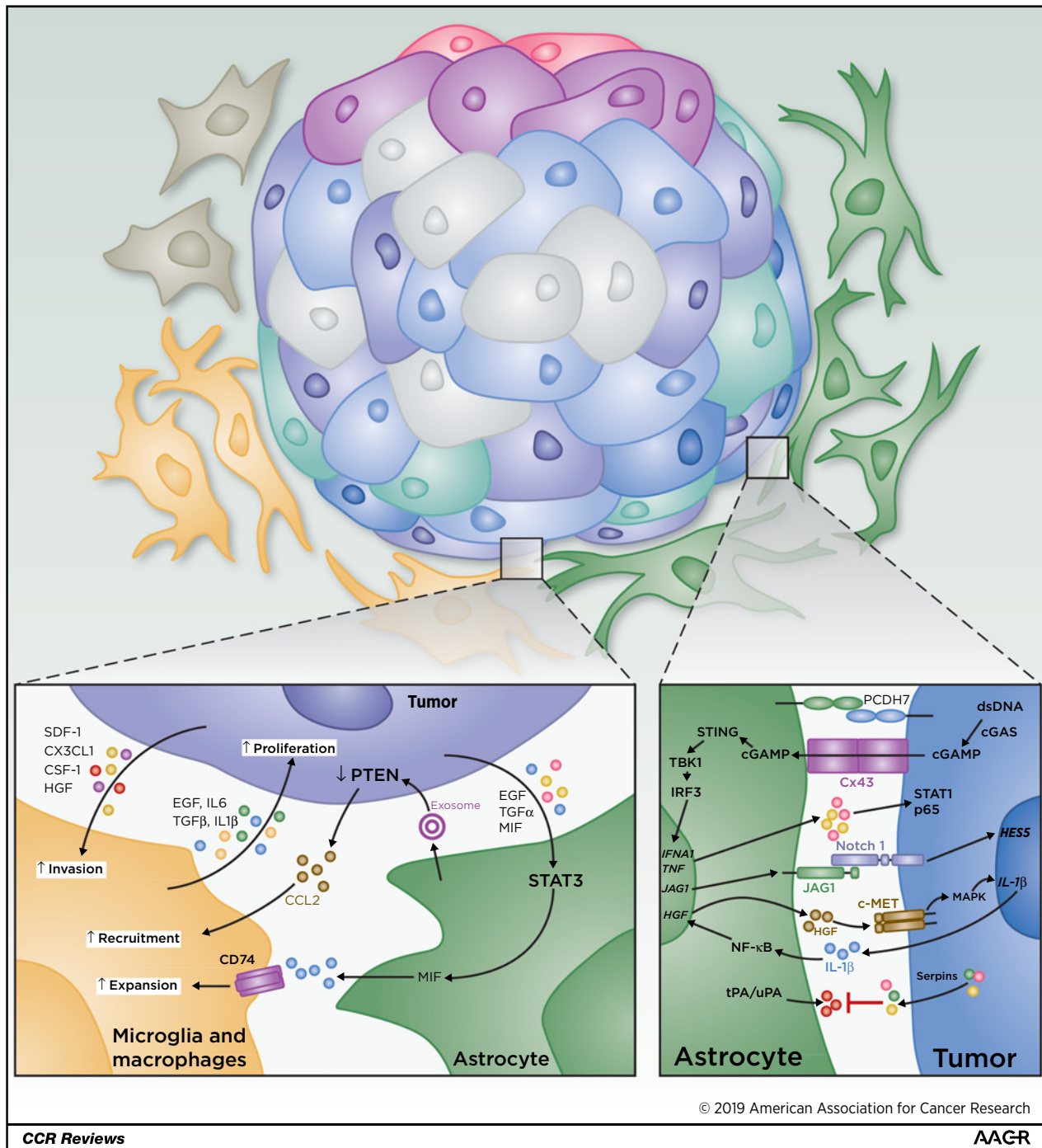


Figure 2. Intercellular cross-talk between tumor cells, astrocytes, microglia, and macrophages in the brain parenchyma regulates metastatic outgrowth. Signaling pathways in each interaction are indicated.

models, stabilization of T-cell S1P1 abrogates sequestration, licensing immunotherapies targeting intracranial tumors. Sequestration occurs in experimental models of glioma, as well of intracranial breast, melanoma, and lung cancers (35), suggesting this phenomenon hampers the immune response to brain metastases.

T-cell exhaustion is a hypofunctional state that follows chronic, suboptimal antigen exposure and is characterized by expression of multiple alternative immune checkpoints on the T-cell surface (36). It has now been described in the setting of gliomas and intracranial metastases (37). A more robust understanding of the prevalence and mechanisms of T-cell dysfunction in brain

metastases will permit development of more rationally designed immunotherapies in this setting.

Brain Metastases: Adjusting our Approach to Treatment

A diagnosis of metastatic cancer, particularly involving the central nervous system (CNS), was formerly considered to signal imminent end of life, with expected survival of less than six months. Advances to the treatment of disseminated cancer, however, are substantially extending survival and challenging the often nihilistic attitudes of patients and providers. For example, a recent single-armed phase II trial of ipilimumab/nivolumab for patients with untreated melanoma brain metastases touted median survivals that had not been reached at 30 months. Furthermore, overall survival (OS) at 12 months was 81.5% (38). Likewise, a number of recent studies demonstrate high rates of "freedom from local recurrence," with these extending over years (39, 40). While these numbers are perhaps not yet broadly representative, the implication is clear—close attention must be paid to treatment regimens for these patients that control disease while preserving neurocognition and quality of life. Current treatment approaches toward brain metastases often utilize a local therapy [surgery, stereotactic radiosurgery (SRS), or a combination of the two] to aggressively control discrete lesions and avoid the deleterious effects of whole-brain radiotherapy (WBRT), recognizing that the omission of WBRT increases the risk of developing new brain lesions. Various modalities, specific clinical scenarios, and histologic considerations are discussed below. Selecting the patients most likely to benefit from initial operative management is important, and factors contributing to decision-making include age, Karnofsky performance status (KPS); the number, size, location, and histology of intracranial lesions; symptoms; and the distinction between new disease, recurrent disease, and radiation necrosis (41).

Approach: Modalities

Radiotherapy

Radiotherapy, either alone or following resection, remains the mainstay of treatment for brain metastases. Historically, WBRT was utilized to treat both the lesions and the "normal" brain parenchyma at risk for subclinical micrometastatic disease. WBRT, however, is associated with neurocognitive decline and even dementia in some cases (42–44). Nonetheless, the complications of WBRT were frequently deemed preferable to uncontrolled or new brain metastases, given the limited survival of patients with metastatic cancer. Initially, SRS was utilized as a means of improving local control in patients with brain metastases treated with WBRT. RTOG 9508, a large, randomized trial of WBRT with or without immediate SRS in patients, demonstrated improved survival with the addition of SRS for select patients with one brain metastasis, high performance status, or a favorable histology (45).

SRS as monotherapy for treatment of brain metastases, however, has become increasingly popular over the past 15 years. Several studies comparing SRS alone versus SRS with WBRT showed no disadvantage in OS when WBRT was omitted, although there was an increase in the rate of new brain metastases (46–48). A small, randomized study from MD Anderson Cancer Center (Houston, TX) suggested a decrease in cogni-

tive decline when SRS monotherapy was employed rather than the combination with WBRT (47). More recently, a multi-institutional randomized trial of SRS alone versus SRS and WBRT revealed significantly better retention of neurocognitive ability in the SRS monotherapy arm (20 vs. 51% deterioration in delayed recall at 3 months post treatment, $P < 0.001$; ref. 49). As part of its "Choosing Wisely" initiative, the American Society of Radiation Oncology now suggests that WBRT NOT be routinely add to SRS for the treatment of limited numbers of brain metastases.

Twenty years ago, Patchell and colleagues showed that WBRT following resection of a single brain metastasis significantly reduced the rate of local and distant brain recurrence compared with postoperative observation alone (50). In combination with surgical resection, SRS is also effective at reducing local recurrences, either when administered postoperatively to the resection cavity or preoperatively to an intact lesion (40, 51–53). For example, Mahajan and colleagues demonstrated a significant improvement in local control in a randomized trial of "SRS alone" versus "no radiotherapy" to the resection cavity (40). In addition, a randomized trial of SRS versus WBRT to resection cavities by Brown and colleagues showed that the risk of neurocognitive decline was substantially higher in those patients treated with WBRT (52 vs. 85% 6 months postradiotherapy, $P < 0.0003$; ref. 52). None of these trials demonstrated a significant difference in OS between the study arms.

While the above studies were limited to a few (<4) brain metastases, SRS monotherapy may be appropriate for larger number of brain metastases, as well. A large study by Yamamoto and colleagues of patients undergoing SRS for up to 10 brain metastases revealed no difference in OS compared with those being treated for 2–4 tumors, and only slightly worse OS than those harboring a solitary metastasis (54). An additional study by our group revealed that the aggregate volume of lesions is a more important predictor of outcome than total number of lesions undergoing SRS, with 10 cc representing an important demarcation (55). Single-fraction SRS is clearly limited in its ability to treat large metastases with an acceptable balance of toxicity and efficacy, however, as shown in RTOG 9005 (56). In such situations, treatment via SRS in a few large fractions (termed "hypofractionated SRS") appears to offer effective local control with minimal damage to normal brain parenchyma (57, 58).

WBRT is still preferred in the setting of numerous brain metastases, carcinomatous meningitis, or primary histologies prone to micrometastatic disease (e.g., small-cell lung cancer), as SRS in these instances often cannot effectively target all of the disease visualized on MRI and/or any disease that is present but not observed. Strategies to comprehensively irradiate the brain while protecting neurocognitive function via hippocampal sparing (59) or via the use of neuroprotectants (60) are being explored. For example, a recently opened trial at our institution administering a novel superoxide dismutase is evaluating the ability of this compound to preserve neurocognition in patients with more than 10 brain metastases receiving WBRT (61, 62).

Surgery

The role of surgery for brain metastases is well established by a variety of now largely historical studies (63–67). Surgery confers several long-recognized benefits, including the unique ability to expediently relieve debilitating or life-threatening mass effect and/or CSF obstruction. Lesions larger than 3 cm or those causing symptoms from local compression benefit from surgical

resection (68). Furthermore, surgery confers the capacity to obtain tissue, ever important in the growing age of molecular and precision medicine. Tumor markers and mutations elucidated from surgical pathology specimens frequently guide the selection of targeted therapies, with one study finding that 53% of patients had a clinically actionable mutation in a brain metastasis that was not present in their primary tumor (5).

Importantly, early studies highlighting the role of resection generally proffered recommendations for surgery as an adjunct to WBRT when lesions were solitary, large, and/or symptomatic in patients with good functional status (65, 66, 69). The classic trial by Patchell and colleagues in 1990 (65), for instance, enrolled 48 patients with a solitary brain metastasis, and KPS \geq 70. Patients were randomized to "surgical resection + postoperative WBRT" versus "WBRT alone." The surgical group survived significantly longer (40 vs. 15 weeks) and enjoyed longer periods of functional independence (KPS $>$ 70, 8.8 months vs. 1.8 months), freedom from death due to neurologic compromise, and time to brain recurrence. While unambiguously establishing surgical value, early studies advocating resection alongside WBRT are now seemingly passé, with the declining role for WBRT and ever-increasing role for SRS (discussed above). Likewise, any question of surgery's utility as a lone modality is equally moot, with local intracranial recurrence rates following resection alone proving unacceptable at 46%–68%. This was perhaps most definitively demonstrated in a 2017 publication by Mahajan and colleagues. In their prospective randomized controlled trial (RCT) examining local recurrence rates, patients undergoing resection alone attained freedom from local recurrence (FLR) rates of just 43% at 12 months; patients receiving postoperative SRS, however, achieved 12-month FLR rates of 72% (40).

More relevant questions in the current climates of SRS and aggressive therapy now surround the role for surgery in conjunction with SRS or in instances of multiple metastases. Regarding the former, while no trials have compared "surgery + SRS" to "SRS alone," as noted previously, various recent RCTs have established the inarguable value of postoperative SRS versus both observation (40) and WBRT (52). The latter question of multiple metastases is somewhat more weakly addressed by studies that are now more than a decade old (70–72). Consensus therefore remains unreached, and newer studies are needed (73). No randomized studies have evaluated the role of surgery in this population, as they were historically excluded from trials due to a shorter life expectancy and presumed limited benefit to treatment. Given the improving survival in this group, however, resection of multiple metastases likely does provide benefit in the appropriately selected patient. In perhaps the most pertinent study examining the topic, Paek and colleagues reviewed 208 patients with either solitary or multiple brain metastases treated at a single institution. They uncovered no difference in survival between patients operated for one metastasis versus 2–3, and neurologic symptoms were stabilized in each group. Factors impacting survival were instead KPS and RPA class I assignment (71). In general, then, when surgically approaching multiple metastases, the best evidence to date is that traditional principles apply: in patients with good functional status and multiple lesions; resection of large, dominant, symptomatic metastases (up to 2–3) may benefit performance status without worsening survival.

Systemic therapy

While the initial treatment of brain metastases relies heavily on local therapies (radiation and/or resection), systemic therapy plays a role in multimodality care for CNS recurrence. Studies illustrate improved survival amidst brain metastases for those who receive subsequent systemic therapy compared with those who do not (74). Critical goals of systemic therapy, agnostic of tumor histology, include extracranial disease control and prevention of cancer seeding the untreated brain. For intracranial progression following local therapy, brain-permeable systemic compounds are preferred. For those experiencing life-threatening extracranial disease progression, systemic therapy may be indicated prior to local therapies to stabilize extracranial disease. In each of these clinical scenarios, well-coordinated, multidisciplinary care involving neurosurgical, radiation, and medical oncology partners is paramount.

The BBB remains a challenge to effective systemic therapy for brain metastases, and novel delivery platforms to overcome this barrier are eagerly anticipated. Preclinical studies in breast cancer show brain metastases accumulate higher concentrations of 14 C-paclitaxel and 14 C-doxorubicin than normal brain, yet far below that within extracranial metastases (75). This has led to the classification of the BBB as a blood–tumor barrier (BTB) in the setting of metastases. One strategy to bypass the BTB is the encapsulation of standard chemotherapeutics, their prodrugs or active metabolites, into nanoparticles or liposomes to enhance accumulation in brain metastases. This has been implemented with several cytotoxics including doxorubicin, irinotecan, and taxanes (76), and clinical translation is ongoing in several early-phase trials (NCT02915744 and NCT01770353). Transcytosis across the BTB via receptor-mediated interactions is another strategy to enhance intratumoral concentrations. ANG-1005 is a novel drug conjugate consisting of three molecules of paclitaxel covalently linked to Angiopep-2, designed to cross the BTB via endocytosis after binding to LRP-1. Results from a phase II study of ANG-1005 for breast cancer brain metastases and/or leptomeningeal disease illustrate clinical benefit of 71%, with partial responses in 14% (8/58) of patients with brain metastases, and 22% (5/23) with leptomeningeal disease (77).

In the current era, a discussion of systemic therapies must include the role of immunotherapy, particularly checkpoint blockade. Employment of mAbs against CTLA-4 (ipilimumab) and PD-1 (nivolumab, pembrolizumab) function to remove inhibition of the antitumor immune response and have been approved for use in melanoma and NSCLC (78, 79). While patients with intracranial metastases were historically excluded from systemic and immunotherapy trials, intracranial responses are increasingly observed following checkpoint blockade, prompting newer interest in harnessing immunotherapy for these patients. For instance, a meta-analysis of studies for melanoma brain metastases found treatment with SRS + ipilimumab increased survival compared with SRS alone (80). In dedicated prospective studies, a recent phase II study found nivolumab to be effective alone or in combination with ipilimumab for patients with untreated asymptomatic melanoma brain metastases, with 46% of patients in the combination group and 20% of the patients on nivolumab alone showing intracranial responses (81). Another landmark phase II study found 52% of patients with previously untreated melanoma metastases obtained an objective intracranial response following combination therapy;

interestingly, extracranial response was similar at 47%. At 6 months, rates of intracranial progression-free survival were somewhat lower at 64.2% than extracranial progression-free survival at 75.9%. OS in this study was 81.5% at 12 months, and median survival had not been reached at 30 months (38). Meanwhile, an early combined analysis of patients with both lung and melanoma brain metastasis from a further phase II study illustrated intracranial response rates to pembrolizumab monotherapy of 33% and 22%, respectively, again with near identical extracranial response rates (82). These dramatic results may shift the paradigm for systemic therapies to one of up front rather than salvage therapy, as a number of these studies were conducted in patients receiving no prior therapy for their intracranial disease, and high concordance between intracranial and extracranial disease is notable. Numerous studies are ongoing to continue to define the role and timing (pre-, post-, or concurrent with radiation) of immunotherapy in solid tumor brain metastases (NCT02696993, NCT02886585; Table 2). A recent review outlines additional considerations for generating antitumor immunity against brain metastases (83).

Approach: Specific Clinical Scenarios

Recurrent metastases

Radiographic progression following radiation generally indicates one of two diagnoses: recurrent/progressive disease, or radiation necrosis, a delayed inflammatory process that involves apoptosis of endothelial cells, peritumoral edema, chronic tissue hypoxia, and disruption of the blood-brain barrier (84). While it is impossible to distinguish between these pathologies on imaging alone, the distinction is important, as recurrent disease necessitates further radiation, whereas radiation necrosis contraindicates it. A recent retrospective study examined 35 patients with radiographic progression of previously irradiated brain metastases who underwent biopsy. When radiographic progression occurred within 9 months of SRS, approximately 50% of biopsies identified disease recurrence. When radiographic progression occurred after 9 months, however, greater than 90% of

the biopsied lesions proved to be radiation necrosis (85). Radiation necrosis is pervasive, particularly at later time points after radiation, and it is critical to distinguish it from true disease progression. In addition to distinguishing disease progression from radiation necrosis, biopsy allows for the detection of actionable mutations in the brain metastasis, which are often distinct from the primary tumor (5).

Surgical resection for previously resected recurrent brain metastases prolongs survival in RPA class 1 patients (86) and can be considered for recurrent lesions that are accessible and symptomatic. However, one of the most promising emergent strategies, effective for both recurrent disease and radiation necrosis, is laser interstitial thermal therapy (LITT). LITT uses a robotically controlled laser probe introduced through a small incision to propagate thermal energy and cause cellular damage, including protein denaturation and coagulative necrosis (87). Temperature data is calculated from phase change data obtained from a continuously running MRI. The minimally invasive approach is useful in patients or brain areas that may be less amenable to open resection, and it avoids problems with wound healing plaguing previously irradiated areas. Furthermore, biopsy is obtained simultaneously to distinguish between recurrent disease and radiation necrosis. Limitations to LITT include a lesional size limitation per trajectory of approximately 3 cm diameter, as well as morbidity associated with LITT-induced edema. Ali and colleagues recently published their results using LITT in 23 patients with recurrent brain metastases following SRS and found that when >80% of the lesion is ablated, no additional tumor growth was observed (88). While further prospective, randomized studies are clearly needed, LITT offers significant promise for patients with progressive metastases or radiation necrosis.

Approach: Disease-Specific Therapeutic Considerations

NSCLC

Present standard of care involves molecular testing to include *EGFR* and anaplastic lymphoma kinase (*ALK*) at

Table 2. Therapies for brain metastasis

Cancer type	Drug/target	Clinical trial	Clinical trial outcome	References
Lung	Osimertinib (EGFR)	FLAURA	PFS = 18.9 months; HR 0.46; 95% CI, 0.37–0.57	90
Lung	Alectinib (ALK)	Global ALEX	CNS RR = 81%; response duration = 17.3 months	92
Lung	Ceritinib (ALK)	ASCEND-4	PFS = 10.7 months; HR = 0.70; 95% CI, 0.44–1.12	93
Lung	Lorlatinib (ALK)		IC-ORR = 40%–75%	94
Melanoma	Dabrafenib+trametinib (BRAF)	COMBI-MB	IC-ORR = 59%	96
Melanoma	Vemurafenib (BRAF)		IC-ORR = 15%; PFS 4.0 months; OS 9.6 months	97
Breast	Abemaciclib (CDK4/6)	NCT02308020	In progress	98
Breast	Pertuzumab +trastuzumab +docetaxel (HER2)	CLEOPATRA	OS = 34.4 months	99
Breast	Trastuzumab emtansine (HER2)	EMILIA	OS = 26.8 months	101
Breast	Tucatinib + capecitabine + trastuzumab (HER2)	HER2CLIMB	In progress	
Breast (TNBC)	Cisplatin ± veliparib	NCT02595905	In progress	
Breast	Etirinotecan pegol (NKTR-102)	NCT02915744	In progress	
Melanoma	Ipilimumab + nivolumab (CTLA-4+PD-1)	NCT02374242	Intracranial ORR = 46%	81
Lung, melanoma	Pembrolizumab (PD-1)	NCT02085070	Intracranial RR = 33% for NSCLC; intracranial RR = 22% for melanoma	82
NSCLC	Nivolumab ± Ipilimumab +radiation (PD-1, CTLA4)	NCT02696993	In progress	
Brain mets (any solid tumor)	Pembrolizumab (PD-1)	NCT02886585	In progress	

NOTE: Several clinical trials are underway to investigate disease-specific therapies for brain metastasis, as well as checkpoint blockade for brain metastasis. When available, outcomes are summarized.

diagnosis of lung adenocarcinoma, as multiple targeted therapies are approved. The incidence of brain metastases among those whose NSCLC harbors a mutation in *EGFR* or *ALK* is approximately half, while a third of those with *ROS-1* positive NSCLC will recur in the CNS.

While several targeted agents are approved in NSCLC harboring an *EGFR* mutation, resistance emerges through the *T790M* mutation (89). Osimertinib, a second-generation *EGFR* tyrosine kinase inhibitor, has activity against the *T790M EGFR* mutation and crosses the BBB. In the phase III FLAURA trial, over 500 patients with activating *EGFR* exon 19 deletions or exon 21 *L858R* mutations were randomized to osimertinib versus gefitinib or erlotinib. PFS favored osimertinib (18.9 months vs. 10.2 months), and PFS benefit was consistent across patients with and without brain metastases (Table 2; ref. 90). Osimertinib is approved in the front-line treatment of *EGFR*-mutant NSCLC regardless of *T790M EGFR* mutation status and is favored among those with brain metastases.

The identification of *ALK* and *ROS-1* translocations and activity of *ALK* inhibition in this molecular subset of NSCLC led to approval of crizotinib (91). Newer second-generation *ALK* inhibitors have shown superior activity compared with crizotinib and enhanced brain permeability. Alectinib, a brain permeable second-generation *ALK* inhibitor, illustrates improved PFS and time to CNS progression compared with crizotinib, with a more favorable toxicity profile (92). Another second-generation *ALK* inhibitor, ceritinib, improves PFS over platinum-based chemotherapy for those with brain metastases (10.7 vs. 6.7 months; ref. 93). Finally, lorlatinib is a third-generation, CNS-permeable *ALK/ROS1* inhibitor with FDA breakthrough designation designed to overcome *ALK* resistance mutations. Intracranial response rates for *ALK*-inhibitor-pretreated patients is approximately 45%–60% (Table 2; ref. 94). Specific to *ROS-1* mutations, crizotinib remains a mainstay of therapy, but has poor BBB permeability. Thus, in the setting of brain metastases, second- and third-generation *ALK/ROS-1* inhibitors including ceritinib and lorlatinib are favored (95).

Melanoma

Systemic therapy for melanoma has transformed over the past decade to include targeted and immunotherapeutic approaches. Targeted therapies utilizing combined inhibition of the MAPK pathway, namely *BRAF* and *MEK*, in *BRAF*-mutant melanoma yield improved outcomes. Combination dabrafenib and trametinib illustrated intracranial response rates of 58% for *BRAF V600E*-mutant, radiotherapy-naïve, melanoma brain metastases (96). In this analysis, the median extracranial response was more durable (10.2 months, 95% CI, 5.8–not estimable) compared with intracranial duration of response (6.5 months, 95% CI, 4.9–10.3). A newer generation *BRAF* inhibitor, vemurafenib, yields intracranial response rates of 25% for progressive, *BRAF*-mutant melanoma brain metastases (Table 2; ref. 97). As discussed above (re: immunotherapy in melanoma), combination therapy with ipilimumab and nivolumab yielded near-identical intracranial and extracranial response rates (52% and 47%, respectively), with 1-year OS rate of 81.5% in patients with metastatic melanoma (of which 57% harbored a mutation in *BRAF*; ref. 38). In the era of both targeted and immunotherapy for melanoma brain metastases, clinical trials addressing the most effective sequencing of these strategies, taking mutation status into account, are needed.

Breast cancer

Treatment for breast cancer brain metastases is subtype-dependent, based on hormone receptor (HR) and/or HER-2 expression. Inhibitors of cyclin-dependent kinase 4/6 (*CDK4/6*) have altered the approach to the treatment of HR-positive, metastatic breast cancer with significant improvements in PFS. Of the three approved agents (palbociclib, ribociclib, and abemaciclib), abemaciclib illustrates the greatest CNS permeability with intracranial response rates of 17% (98).

The incidence of brain metastases in advanced HER2-positive breast cancer is approximately 30%. While larger mAbs do not traverse an intact BBB, studies illustrate delayed time to CNS relapses by adding pertuzumab, a mAb targeting HER2–HER2 dimerization, to trastuzumab (99). Intracranial responses to the antibody drug conjugate, trastuzumab emtansine (TDM1), are observed in several small studies (100), and TDM1 was shown to significantly improve survival in patients with CNS metastases compared with capecitabine–lapatinib (101). Brain permeable small-molecule inhibitors targeting HER1 and HER2, lapatinib or neratinib, combined with capecitabine, yield intracranial response rates of 67% and 49%, respectively (102, 103). A newer generation, HER2-specific small-molecule inhibitor, tucatinib, is currently under investigation for treatment of metastatic HER2-positive breast cancer with and without brain metastases (NCT02614794; Table 2).

There are no approved targeted therapies to treat TNBC brain metastases, despite the fact that nearly half of those diagnosed with metastatic disease experience recurrence in the CNS. Systemic therapies under investigation include inhibition of PARP with DNA-damaging platinum chemotherapy (NCT02595905), and a pegylated prodrug of irinotecan (NKTR-102, NCT02915744; Table 2).

Future Perspectives

Brain metastases are an increasingly prevalent challenge confronting multiple disciplines. Development of effective therapies to treat brain metastases requires greater understanding of the means by which metastatic cells adapt to the distinct metabolic, chemical, and cellular composition of the brain microenvironment. Likewise, greater insight is needed into the mechanisms blocking passage of therapeutic agents across the BBB, as well as into the immunologic proclivities of the brain microenvironment and the immune-evasive strategies implemented by brain metastases. A new focus on these problems will be required to improve survival and quality of life for patients with brain metastases.

Disclosure of Potential Conflicts of Interest

P. E. Fecci reports receiving speakers bureau honoraria from and is a consultant/advisory board member for Monteris Medical. J. Kirkpatrick is Senior Editor at ASTRO, reports receiving commercial research grants from Varian Medical Systems, and holds ownership interest in ClearSight RT, LLP. C. K. Anders reports receiving commercial research grants from Novartis, Merrimack, PUMA, Lilly, Merck, Seattle Genetics, Nektar, Tesaro, and G1-Therapeutics, other commercial research support from UpToDate and Jones and Bartlett, and is a consultant/advisory board member for Merck, Novartis, Merrimack, Lilly, Nektar, Seattle Genetics, PUMA, Genentech, Eisai, and IPSEN. A. M. Pendergast reports receiving commercial research grants from Zeno Management and is a consultant/advisory board member for The Pew Charitable Trusts. J. H. Sampson has an equity interest in Annias Immunotherapeutics, which has licensed intellectual property from Duke

University related to the use of the pepCMV vaccine in the treatment of glioblastoma multiforme, an equity interest in Istari Oncology, which has licensed intellectual property from Duke related to the use of poliovirus and D2C7 in the treatment of glioblastoma, and is an inventor on patents related to PEP-CMV DC vaccine with tetanus, as well as poliovirus vaccine and D2C7 in the treatment of glioblastoma. No potential conflicts of interest were disclosed by the other authors.

Disclaimer

The funders had no role in the preparation of the manuscript or decision to publish.

References

- Nayak L, Lee EQ, Wen PY. Epidemiology of brain metastases. *Curr Oncol Rep* 2012;14:48–54.
- Sperduto PW, Chao ST, Sneed PK, Luo X, Suh J, Roberge D, et al. Diagnosis-specific prognostic factors, indexes, and treatment outcomes for patients with newly diagnosed brain metastases: a multi-institutional analysis of 4,259 patients. *Int J Radiat Oncol Biol Phys* 2010;77:655–61.
- American Cancer Society. Cancer Statistics Center. Atlanta, GA: American Cancer Society; 2018.
- Olson EM, Abdel-Rasoul M, Maly J, Wu CS, Lin NU, Shapiro CL. Incidence and risk of central nervous system metastases as site of first recurrence in patients with HER2-positive breast cancer treated with adjuvant trastuzumab. *Ann Oncol* 2013;24:1526–33.
- Brastianos PK, Carter SL, Santagata S, Cahill DP, Taylor-Weiner A, Jones RT, et al. Genomic characterization of brain metastases reveals branched evolution and potential therapeutic targets. *Cancer Discov* 2015;5:1164–77.
- Sevenich L, Bowman RL, Mason SD, Quail DF, Rapaport F, Elie BT, et al. Analysis of tumour- and stroma-supplied proteolytic networks reveals a brain-metastasis-promoting role for cathepsin S. *Nat Cell Biol* 2014;16:876–88.
- Stamatovic SM, Keep RF, Andjelkovic AV. Brain endothelial cell-cell junctions: how to "open" the blood brain barrier. *Curr Neuropharmacol* 2008;6:179–92.
- Strilic B, Yang L, Albarran-Juarez J, Wachsmuth L, Han K, Muller UC, et al. Tumour-cell-induced endothelial cell necroptosis via death receptor 6 promotes metastasis. *Nature* 2016;536:215–8.
- Strell C, Entschladen F. Extravasation of leukocytes in comparison to tumor cells. *Cell Commun Signal* 2008;6:10.
- Kienast Y, von Baumgarten L, Fuhrmann M, Klinkert WE, Goldbrunner R, Herms J, et al. Real-time imaging reveals the single steps of brain metastasis formation. *Nat Med* 2010;16:116–22.
- Berghoff AS, Ilhan-Mutlu A, Dinhof C, Magerle M, Hackl M, Widhalm G, et al. Differential role of angiogenesis and tumour cell proliferation in brain metastases according to primary tumour type: analysis of 639 cases. *Neuropathol Appl Neurobiol* 2015;41:e41–55.
- Valiente M, Obenaus AC, Jin X, Chen Q, Zhang XH, Lee DJ, et al. Serpins promote cancer cell survival and vascular co-option in brain metastasis. *Cell* 2014;156:1002–16.
- Lin CY, Cho CF, Bai ST, Liu JP, Kuo TT, Wang LJ, et al. ADAM9 promotes lung cancer progression through vascular remodeling by VEGFA, ANGPT2, and PLAT. *Sci Rep* 2017;7:15108.
- Romagnoli M, Mineva ND, Polmear M, Conrad C, Srinivasan S, Loussouarn D, et al. ADAM8 expression in invasive breast cancer promotes tumor dissemination and metastasis. *EMBO Mol Med* 2014;6:278–94.
- Xing F, Liu Y, Sharma S, Wu K, Chan MD, Lo HW, et al. Activation of the c-Met pathway mobilizes an inflammatory network in the brain microenvironment to promote brain metastasis of breast cancer. *Cancer Res* 2016;76:4970–80.
- Bos PD, Zhang XH, Nadal C, Shu W, Gomis RR, Nguyen DX, et al. Genes that mediate breast cancer metastasis to the brain. *Nature* 2009;459:1005–9.
- Avraham HK, Jiang S, Fu Y, Nakshatri H, Ovadia H, Avraham S. Angiopoietin-2 mediates blood-brain barrier impairment and colonization of triple-negative breast cancer cells in brain. *J Pathol* 2014;232:369–81.

Acknowledgments

The authors regret that due to space limitations, they could not directly cite the work of many investigators. This work was supported by grants from the NIH: R01-NS099463 (to J.H. Sampson), P50-CA190991 (to J.H. Sampson and A.M. Pendergast), P30-CA14236 (to J.H. Sampson), R01-CA177476 (to J.H. Sampson), P01-CA225622 (to J.H. Sampson), U01-NS090284 (to J.H. Sampson), R01-NS085412 (to J.H. Sampson), and R01 CA195549 (to A.M. Pendergast).

Received March 5, 2019; revised April 23, 2019; accepted June 13, 2019; published first June 18, 2019.

- Li H, Chen Y, Xu N, Yu M, Tu X, Chen Z, et al. AMD3100 inhibits brain-specific metastasis in lung cancer via suppressing the SDF-1/CXCR4 axis and protecting blood-brain barrier. *Am J Transl Res* 2017;9:5259–74.
- Fukumura D, Duda DG, Munn LL, Jain RK. Tumor microvasculature and microenvironment: novel insights through intravital imaging in pre-clinical models. *Microcirculation* 2010;17:206–25.
- Priego N, Zhu L, Monteiro C, Mulders M, Wasilewski D, Bindeman W, et al. STAT3 labels a subpopulation of reactive astrocytes required for brain metastasis. *Nat Med* 2018;24:1024–35.
- Jandial R, Choy C, Levy DM, Chen MY, Ansari KI. Astrocyte-induced Reelin expression drives proliferation of Her2(+) breast cancer metastases. *Clin Exp Metastasis* 2017;34:185–96.
- Xing F, Kobayashi A, Okuda H, Watabe M, Pai SK, Pandey PR, et al. Reactive astrocytes promote the metastatic growth of breast cancer stem-like cells by activating Notch signalling in brain. *EMBO Mol Med* 2013;5:384–96.
- Chen Q, Boire A, Jin X, Valiente M, Er EE, Lopez-Soto A, et al. Carcinoma-astrocyte gap junctions promote brain metastasis by cGAMP transfer. *Nature* 2016;533:493–8.
- Kim SW, Choi HJ, Lee HJ, He J, Wu Q, Langley RR, et al. Role of the endothelin axis in astrocyte- and endothelial cell-mediated chemoprotection of cancer cells. *Neuro Oncol* 2014;16:1585–98.
- Berghoff AS, Preusser M. Anti-angiogenic therapies in brain metastases. *Memo* 2018;11:14–7.
- Palmieri D, Fitzgerald D, Shreeve SM, Hua E, Bronder JL, Weil RJ, et al. Analyses of resected human brain metastases of breast cancer reveal the association between up-regulation of hexokinase 2 and poor prognosis. *Mol Cancer Res* 2009;7:1438–45.
- Neman J, Termini J, Wilczynski S, Vaidehi N, Choy C, Kowolik CM, et al. Human breast cancer metastases to the brain display GABAergic properties in the neural niche. *Proc Natl Acad Sci U S A* 2014;111:984–9.
- Mashimo T, Pichumani K, Vemireddy V, Hatanpaa KJ, Singh DK, Sira-sanagandla S, et al. Acetate is a bioenergetic substrate for human glioblastoma and brain metastases. *Cell* 2014;159:1603–14.
- Seidlitz EP, Sharma MK, Saikali Z, Ghert M, Singh G. Cancer cell lines release glutamate into the extracellular environment. *Clin Exp Metastasis* 2009;26:781–7.
- Wei J, Gabrusiewicz K, Heimberger A. The controversial role of microglia in malignant gliomas. *Clin Dev Immunol* 2013;2013:285246.
- He BP, Wang JJ, Zhang X, Wu Y, Wang M, Bay BH, et al. Differential reactions of microglia to brain metastasis of lung cancer. *Mol Med* 2006;12:161–70.
- Zhang L, Zhang S, Yao J, Lowery FJ, Zhang Q, Huang WC, et al. Micro-environment-induced PTEN loss by exosomal microRNA primes brain metastasis outgrowth. *Nature* 2015;527:100–4.
- Sugihara AQ, Rolle CE, Lesniak MS. Regulatory T cells actively infiltrate metastatic brain tumors. *Int J Oncol* 2009;34:1533–40.
- Fecci PE, Mitchell DA, Whitesides JF, Xie W, Friedman AH, Archer GE, et al. Increased regulatory T-cell fraction amidst a diminished CD4 compartment explains cellular immune defects in patients with malignant glioma. *Cancer Res* 2006;66:3294–302.
- Chongsathidkiet P, Jackson C, Koyama S, Loebel F, Cui X, Farber SH, et al. Sequestration of T cells in bone marrow in the setting of glioblastoma and other intracranial tumors. *Nat Med* 2018;24:1459–68.
- Wherry EJ. T cell exhaustion. *Nat Immunol* 2011;12:492–9.

37. Woroniecka K, Chongsathidkiet P, Rhodin KE, Kemeny HR, Dechant CA, Farber SH, et al. T cell exhaustion signatures vary with tumor type and are severe in glioblastoma. *Clin Cancer Res* 2018;24:4175–86.
38. Tawbi HA, Forsyth PA, Algazi A, Hamid O, Hodi FS, Moschos SJ, et al. Combined nivolumab and ipilimumab in melanoma metastatic to the brain. *N Engl J Med* 2018;379:722–30.
39. Kirkpatrick JP, Wang Z, Sampson JH, McSherry F, Herndon JE II, Allen KJ, et al. Defining the optimal planning target volume in image-guided stereotactic radiosurgery of brain metastases: results of a randomized trial. *Int J Radiat Oncol Biol Phys* 2015;91:100–8.
40. Mahajan A, Ahmed S, McAleer MF, Weinberg JS, Li J, Brown P, et al. Post-operative stereotactic radiosurgery versus observation for completely resected brain metastases: a single-centre, randomised, controlled, phase 3 trial. *Lancet Oncol* 2017;18:1040–8.
41. Sperduto PW, Berkey B, Gaspar LE, Mehta M, Curran W. A new prognostic index and comparison to three other indices for patients with brain metastases: an analysis of 1,960 patients in the RTOG database. *Int J Radiat Oncol Biol Phys* 2008;70:510–4.
42. DeAngelis LM, Delattre JY, Posner JB. Radiation-induced dementia in patients cured of brain metastases. *Neurology* 1989;39:789–96.
43. Greene-Schloesser D, Robbins ME, Peiffer AM, Shaw EG, Wheeler KT, Chan MD. Radiation-induced brain injury: a review. *Front Oncol* 2012;2:73.
44. Wefel JS, Parsons MW, Gondi V, Brown PD. Neurocognitive aspects of brain metastasis. *Handb Clin Neurol* 2018;149:155–65.
45. Andrews DW, Scott CB, Sperduto PW, Flanders AE, Gaspar LE, Schell MC, et al. Whole brain radiation therapy with or without stereotactic radiosurgery boost for patients with one to three brain metastases: phase III results of the RTOG 9508 randomised trial. *Lancet* 2004;363:1665–72.
46. Aoyama H, Shirato H, Tago M, Nakagawa K, Toyoda T, Hatano K, et al. Stereotactic radiosurgery plus whole-brain radiation therapy vs stereotactic radiosurgery alone for treatment of brain metastases: a randomized controlled trial. *JAMA* 2006;295:2483–91.
47. Chang EL, Wefel JS, Hess KR, Allen PK, Lang FF, Kornguth DG, et al. Neurocognition in patients with brain metastases treated with radiosurgery or radiosurgery plus whole-brain irradiation: a randomised controlled trial. *Lancet Oncol* 2009;10:1037–44.
48. Kocher M, Soffietti R, Abacioglu U, Villa S, Fauchon F, Baumert BG, et al. Adjuvant whole-brain radiotherapy versus observation after radiosurgery or surgical resection of one to three cerebral metastases: results of the EORTC 22952-26001 study. *J Clin Oncol* 2011;29:134–41.
49. Brown PD, Jaeckle K, Ballman KV, Farace E, Cerhan JH, Anderson SK, et al. Effect of radiosurgery alone vs radiosurgery with whole brain radiation therapy on cognitive function in patients with 1 to 3 brain metastases: a randomized clinical trial. *JAMA* 2016;316:401–9.
50. Patchell RA, Tibbs PA, Regine WF, Dempsey RJ, Mohiuddin M, Kryscio RJ, et al. Postoperative radiotherapy in the treatment of single metastases to the brain: a randomized trial. *JAMA* 1998;280:1485–9.
51. Asher AL, Burri SH, Wiggins WF, Kelly RP, Boltes MO, Mehrlich M, et al. A new treatment paradigm: neoadjuvant radiosurgery before surgical resection of brain metastases with analysis of local tumor recurrence. *Int J Radiat Oncol Biol Phys* 2014;88:899–906.
52. Brown PD, Ballman KV, Cerhan JH, Anderson SK, Carrero XW, Whitton AC, et al. Postoperative stereotactic radiosurgery compared with whole brain radiotherapy for resected metastatic brain disease (NCCTG N107C/CEC.3): a multicentre, randomised, controlled, phase 3 trial. *Lancet Oncol* 2017;18:1049–60.
53. Choi CY, Chang SD, Gibbs IC, Adler JR, Harsh GR, Liebersohn RE, et al. Stereotactic radiosurgery of the postoperative resection cavity for brain metastases: prospective evaluation of target margin on tumor control. *Int J Radiat Oncol Biol Phys* 2012;84:336–42.
54. Yamamoto M, Kawabe T, Sato Y, Higuchi Y, Nariai T, Watanabe S, et al. Stereotactic radiosurgery for patients with multiple brain metastases: a case-matched study comparing treatment results for patients with 2-9 versus 10 or more tumors. *J Neurosurg* 2014;121:16–25.
55. Limon D, McSherry F, Herndon J, Sampson J, Fecci P, Adamson J, et al. Single fraction stereotactic radiosurgery for multiple brain metastases. *Adv Radiat Oncol* 2017;2:555–63.
56. Shaw E, Scott C, Souhami L, Dinapoli R, Kline R, Loeffler J, et al. Single dose radiosurgical treatment of recurrent previously irradiated primary brain tumors and brain metastases: final report of RTOG protocol 90-05. *Int J Radiat Oncol Biol Phys* 2000;47:291–8.
57. Kirkpatrick JP, Soltys SC, Lo SS, Beal K, Shrieve DC, Brown PD. The radiosurgery fractionation quandary: single fraction or hypofractionation? *Neuro Oncol* 2017;19:ii38–ii49.
58. Minniti G, D'Angelillo RM, Scaringi C, Trodella LE, Clarke E, Matteucci P, et al. Fractionated stereotactic radiosurgery for patients with brain metastases. *J Neurooncol* 2014;117:295–301.
59. Gondi V, Pugh SL, Tome WA, Caine C, Corn B, Kanner A, et al. Preservation of memory with conformal avoidance of the hippocampal neural stem-cell compartment during whole-brain radiotherapy for brain metastases (RTOG 0933): a phase II multi-institutional trial. *J Clin Oncol* 2014;32:3810–6.
60. Brown PD, Pugh S, Laack NN, Wefel JS, Khuntia D, Meyers C, et al. Memantine for the prevention of cognitive dysfunction in patients receiving whole-brain radiotherapy: a randomized, double-blind, placebo-controlled trial. *Neuro Oncol* 2013;15:1429–37.
61. Batinic-Haberle I, Tovmasyan A, Ashcraft KA, Rajic Z, Leong KW, Spasojevic I. SOD therapeutics: latest insights into their structure-activity relationships and impact on the cellular redox-based signaling pathways. *Antioxid Redox Signal* 2014;20:2372–415.
62. Weitzel DH, Tovmasyan A, Ashcraft KA, Rajic Z, Weitner T, Liu C, et al. Radioprotection of the brain white matter by Mn(III) n-Butoxyethylpyridylporphyrin-based superoxide dismutase mimic MnTnBuOE-2-PyP5+. *Mol Cancer Ther* 2015;14:70–9.
63. Mintz AH, Kestle J, Rathbone MP, Gaspar L, Hugenholtz H, Fisher B, et al. A randomized trial to assess the efficacy of surgery in addition to radiotherapy in patients with a single cerebral metastasis. *Cancer* 1996;78:1470–6.
64. Noordijk EM, Vecht CJ, Haaxma-Reiche H, Padberg GW, Voormolen JH, Hoekstra FH, et al. The choice of treatment of single brain metastasis should be based on extracranial tumor activity and age. *Int J Radiat Oncol Biol Phys* 1994;29:711–7.
65. Patchell RA, Tibbs PA, Walsh JW, Dempsey RJ, Maruyama Y, Kryscio RJ, et al. A randomized trial of surgery in the treatment of single metastases to the brain. *N Engl J Med* 1990;322:494–500.
66. Vecht CJ, Haaxma-Reiche H, Noordijk EM, Padberg GW, Voormolen JH, Hoekstra FH, et al. Treatment of single brain metastasis: radiotherapy alone or combined with neurosurgery? *Ann Neurol* 1993;33:583–90.
67. Wronski M, Lederman G. A randomized trial to assess the efficacy of surgery in addition to radiotherapy in patients with a single cerebral metastasis. *Cancer* 1997;80:1002–4.
68. Schögl A, Kitz K, Reddy M, Wolfsberger S, Schneider B, Dieckmann K, et al. Defining the role of stereotactic radiosurgery versus microsurgery in the treatment of single brain metastases. *Acta Neurochir* 2000;142:621–6.
69. Hart MG, Grant R, Walker M, Dickinson H. Surgical resection and whole brain radiation therapy versus whole brain radiation therapy alone for single brain metastases. *Cochrane Database Syst Rev* 2005;1:CD003292.
70. Bindal RK, Sawaya R, Leavens ME, Lee JJ. Surgical treatment of multiple brain metastases. *J Neurosurg* 1993;79:210–6.
71. Paek SH, Audu PB, Sperling MR, Cho J, Andrews DW. Reevaluation of surgery for the treatment of brain metastases: review of 208 patients with single or multiple brain metastases treated at one institution with modern neurosurgical techniques. *Neurosurgery* 2005;56:1021–34.
72. Pollock BE, Brown PD, Foote RL, Stafford SL, Schomberg PJ. Properly selected patients with multiple brain metastases may benefit from aggressive treatment of their intracranial disease. *J Neurooncol* 2003;61:73–80.
73. Kalkanis SN, Kondziolka D, Gaspar LE, Burri SH, Asher AL, Cobbs CS, et al. The role of surgical resection in the management of newly diagnosed brain metastases: a systematic review and evidence-based clinical practice guideline. *J Neurooncol* 2010;96:33–43.
74. Niwinska A, Murawska M, Pogoda K. Breast cancer subtypes and response to systemic treatment after whole-brain radiotherapy in patients with brain metastases. *Cancer* 2010;116:4238–47.
75. Lockman PR, Mittapalli RK, Taskar KS, Rudraraju V, Gril B, Bohn KA, et al. Heterogeneous blood-tumor barrier permeability determines drug efficacy in experimental brain metastases of breast cancer. *Clin Cancer Res* 2010;16:5664–78.

76. Mohammad AS, Griffith JJ, Adkins CE, Shah N, Sechrest E, Dolan EL, et al. Liposomal irinotecan accumulates in metastatic lesions, crosses the blood-tumor barrier (BTB), and prolongs survival in an experimental model of brain metastases of triple negative breast cancer. *Pharm Res* 2018;35:31.
77. Kumthekar P, Tang S, Brenner AJ, Kescari S, Anders CK, Carrillo JA, et al. A phase II study of ANG1005, a novel BBB/BCB penetrant taxane in patients with recurrent brain metastases and leptomeningeal carcinomatosis from breast cancer. *Neuro Oncol* 2016;18:iv16.
78. Postow MA, Chesney J, Pavlick AC, Robert C, Grossmann K, McDermott D, et al. Nivolumab and ipilimumab versus ipilimumab in untreated melanoma. *N Engl J Med* 2015;372:2006–17.
79. Reck M, Rodriguez-Abreu D, Robinson AG, Hui R, Csoszi T, Fulop A, et al. Pembrolizumab versus chemotherapy for PD-L1-positive non-small-cell lung cancer. *N Engl J Med* 2016;375:1823–33.
80. Nguyen SM, Castellon A, Vaidis O, Johnson AE. Stereotactic radiosurgery and ipilimumab versus stereotactic radiosurgery alone in melanoma brain metastases. *Cureus* 2017;9:e1511.
81. Long GV, Atkinson V, Lo S, Sandhu S, Guminski AD, Brown MP, et al. Combination nivolumab and ipilimumab or nivolumab alone in melanoma brain metastases: a multicentre randomised phase 2 study. *Lancet Oncol* 2018;19:672–81.
82. Goldberg SB, Gettinger SN, Mahajan A, Chiang AC, Herbst RS, Sznol M, et al. Pembrolizumab for patients with melanoma or non-small-cell lung cancer and untreated brain metastases: early analysis of a non-randomised, open-label, phase 2 trial. *Lancet Oncol* 2016;17: 976–83.
83. Farber SH, Tsvankin V, Narloch JL, Kim GJ, Salama AK, Vlahovic G, et al. Embracing rejection: immunologic trends in brain metastasis. *Oncoimmunology* 2016;5:e1172153.
84. Siu A, Wind JJ, Iorgulescu JB, Chan TA, Yamada Y, Sherman JH. Radiation necrosis following treatment of high grade glioma—a review of the literature and current understanding. *Acta Neurochir* 2012;154: 191–201.
85. Narloch JL, Farber SH, Sammons S, McSherry F, Herndon JE, Hoang JK, et al. Biopsy of enlarging lesions after stereotactic radiosurgery for brain metastases frequently reveals radiation necrosis. *Neuro Oncol* 2017;19: 1391–7.
86. Arbit E, Wronski M, Burt M, Galicich JH. The treatment of patients with recurrent brain metastases. A retrospective analysis of 109 patients with non-small cell lung cancer. *Cancer* 1995;76:765–73.
87. Lagman C, Chung LK, Pelargos PE, Ung N, Bui TT, Lee SJ, et al. Laser neurosurgery: a systematic analysis of magnetic resonance-guided laser interstitial thermal therapies. *J Clin Neurosci* 2017;36:20–6.
88. Ali MA, Carroll KT, Rennett RC, Hamelin T, Chang L, Lemkuil BP, et al. Stereotactic laser ablation as treatment for brain metastases that recur after stereotactic radiosurgery: a multiinstitutional experience. *Neurosurg Focus* 2016;41:E11.
89. Zhou C, Wu YL, Chen G, Feng J, Liu XQ, Wang C, et al. Erlotinib versus chemotherapy as first-line treatment for patients with advanced EGFR mutation-positive non-small-cell lung cancer (OPTIMAL, CTONG-0802): a multicentre, open-label, randomised, phase 3 study. *Lancet Oncol* 2011;12:735–42.
90. Soria JC, Ohe Y, Vansteenkiste J, Reungwetwattana T, Chewaskulyong B, Lee KH, et al. Osimertinib in untreated EGFR-mutated advanced non-small-cell lung cancer. *N Engl J Med* 2018;378:113–25.
91. Solomon BJ, Mok T, Kim DW, Wu YL, Nakagawa K, Mekhail T, et al. First-line crizotinib versus chemotherapy in ALK-positive lung cancer. *N Engl J Med* 2014;371:2167–77.
92. Peters S, Camidge DR, Shaw AT, Gadgeel S, Ahn JS, Kim DW, et al. Alectinib versus crizotinib in untreated ALK-positive non-small-cell lung cancer. *N Engl J Med* 2017;377:829–38.
93. Soria JC, Tan DSW, Chiari R, Wu YL, Paz-Ares L, Wolf J, et al. First-line ceritinib versus platinum-based chemotherapy in advanced ALK-rearranged non-small-cell lung cancer (ASCEND-4): a randomised, open-label, phase 3 study. *Lancet* 2017;389:917–29.
94. Solomon BJ, Shaw AT, Ou SH, Besse B, Felip E, Bauer TM, et al. Phase 2 study of lorlatinib in patients with advanced ALK+/ROS1+ non-small-cell lung cancer. *J Thorac Oncol* 2017;12:S1756.
95. Ahn MJ, Cho BC, Drilon A, De Braud F, Krebs M, John T, et al. Entrectinib in patients with locally advanced or metastatic ROS1 fusion-positive non-small cell lung cancer (NSCLC). *J Thorac Oncol* 2017;12:S1783.
96. Davies MA, Saiag P, Robert C, Grob JJ, Flaherty KT, Arance A, et al. Dabrafenib plus trametinib in patients with BRAF(V600)-mutant melanoma brain metastases (COMBI-MB): a multicentre, multicohort, open-label, phase 2 trial. *Lancet Oncol* 2017;18:863–73.
97. McArthur GA, Maio M, Arance A, Nathan P, Blank C, Avril MF, et al. Vemurafenib in metastatic melanoma patients with brain metastases: an open-label, single-arm, phase 2, multicentre study. *Ann Oncol* 2017;28: 634–41.
98. Tolane SM, Lin N, Thornton D, Klise S, Costigan T, Turner K, et al. Abemaciclib for the treatment of brain metastases (BM) secondary to hormone receptor positive (HR+), HER2 negative breast cancer. *J Clin Oncol* 35:15s, 2017(suppl; abstr 1019).
99. Swain SM, Baselga J, Miles D, Im YH, Quah C, Lee LF, et al. Incidence of central nervous system metastases in patients with HER2-positive metastatic breast cancer treated with pertuzumab, trastuzumab, and docetaxel: results from the randomized phase III study CLEOPATRA. *Ann Oncol* 2014;25:1116–21.
100. Keith KC, Lee Y, Ewend MG, Zagar TM, Anders CK. Activity of trastuzumab-emtansine (Tdm1) in Her2-positive breast cancer brain metastases: a case series. *Cancer Treat Commun* 2016;7:43–6.
101. Krop IE, Lin NU, Blackwell K, Guardino E, Huober J, Lu M, et al. Trastuzumab emtansine (T-DM1) versus lapatinib plus capecitabine in patients with HER2-positive metastatic breast cancer and central nervous system metastases: a retrospective, exploratory analysis in EMILIA. *Ann Oncol* 2015;26:113–9.
102. Freedman RA, Gelman RS, Melisko ME, Anders CK, Moy B, Blackwell KL, et al. TBCRC 022: phase II trial of neratinib + capecitabine for patients (Pts) with human epidermal growth factor receptor 2 (HER2+) breast cancer and brain metastases (BCBM). *J Clin Oncol* 35:15s, 2017(suppl; abstr 1005).
103. Bachelot T, Romieu G, Campone M, Dieras V, Cropet C, Dalenc F, et al. Lapatinib plus capecitabine in patients with previously untreated brain metastases from HER2-positive metastatic breast cancer (LANDSCAPE): a single-group phase 2 study. *Lancet Oncol* 2013;14:64–71.