

Topical TLR7 Agonist Imiquimod Can Induce Immune-Mediated Rejection of Skin Metastases in Patients with Breast Cancer

Sylvia Adams¹, Lina Kozhaya², Frank Martiniuk¹, Tze-Chiang Meng⁷, Luis Chiriboga³, Leonard Liebes¹, Tsviva Hochman⁴, Nicholas Shuman¹, Deborah Axelrod⁵, James Speyer¹, Yelena Novik¹, Amy Tiersten¹, Judith D. Goldberg⁴, Silvia C. Formenti⁶, Nina Bhardwaj³, Derya Unutmaz², and Sandra Demaria³

Abstract

Purpose: Skin metastases of breast cancer remain a therapeutic challenge. Toll-like receptor 7 agonist imiquimod is an immune response modifier and can induce immune-mediated rejection of primary skin malignancies when topically applied. Here we tested the hypothesis that topical imiquimod stimulates local antitumor immunity and induces the regression of breast cancer skin metastases.

Experimental Design: A prospective clinical trial was designed to evaluate the local tumor response rate of breast cancer skin metastases treated with topical imiquimod, applied 5 d/wk for 8 weeks. Safety and immunologic correlates were secondary objectives.

Results: Ten patients were enrolled and completed the study. Imiquimod treatment was well tolerated, with only grade 1 to 2 transient local and systemic side effects consistent with imiquimod's immunomodulatory effects. Two patients achieved a partial response [20%; 95% confidence interval (CI), 3%–56%]. Responders showed histologic tumor regression with evidence of an immune-mediated response, showed by changes in the tumor lymphocytic infiltrate and locally produced cytokines.

Conclusion: Topical imiquimod is a beneficial treatment modality for breast cancer metastatic to skin/chest wall and is well tolerated. Importantly, imiquimod can promote a proimmunogenic tumor microenvironment in breast cancer. Preclinical data generated by our group suggest superior results with a combination of imiquimod and ionizing radiation and we are currently testing in patients whether the combination can further improve antitumor immune and clinical responses. *Clin Cancer Res*; 18(24); 6748–57. ©2012 AACR.

Introduction

Skin metastases of solid tumors remain a therapeutic challenge. Breast cancer is the second most common tumor, after melanoma, to metastasize to the skin (1, 2). Breast cancer skin recurrence most frequently manifest after mastectomy and can present as firm nodules, diffuse infiltration or ulcerative lesions, often in proximity of the mastectomy scar. Initial management of recurrences usually includes resection and radiation, but skin metastases tend to recur and herald diffuse metastatic spread. Furthermore, cutaneous metastases affect quality of life and

become a debilitating experience for the patient as progression of disease leads to chest wall ulceration, bleeding, and super-infection. Therefore, novel treatment approaches are warranted.

Imiquimod is a synthetic imidazoquinoline and Toll-like receptor (TLR)-7 agonist (3). TLRs are highly conserved pattern recognition receptors that alert the host to invading pathogens, thereby activating an innate immune response directly and an adaptive immune response, secondarily. TLR7 is located on endosomal membranes of antigen-presenting cells, including myeloid dendritic cells (mDCs) and plasmacytoid dendritic cells (pDCs), monocytes, and macrophages. TLR7 activation induces secretion of proinflammatory cytokines, predominantly interferon (IFN)- α , interleukin (IL)-12, and tumor necrosis factor- α , and enhances DC maturation and antigen presentation (4). This immunostimulatory ability can be harnessed to promote antitumor immunity, either by applying the TLR agonist locally onto cancers or administering it as an adjuvant for cancer vaccines. Therefore, TLR agonists are included in the ranked National Cancer Institute (NCI) list of immunotherapeutic agents with the highest potential to cure cancer (5, 6). Imiquimod is approved by the Food and

Authors' Affiliations: Departments of ¹Medicine, ²Microbiology, ³Pathology, ⁴Biostatistics, ⁵Surgery, and ⁶Radiation Oncology, New York University School of Medicine, New York, New York; and ⁷T. Meng Consulting, Lino Lakes, Minnesota

Note: Supplementary data for this article are available at Clinical Cancer Research Online (<http://clincancerres.aacrjournals.org/>).

Corresponding Author: Sylvia Adams, New York University Cancer Institute, 462 First Avenue, Bellevue C&D 556, New York, NY 10016. Phone: 212-263-6485; Fax: 212-263-8210; E-mail: sylvia.adams@nyumc.org

doi: 10.1158/1078-0432.CCR-12-1149

©2012 American Association for Cancer Research.

Translational Relevance

Skin metastases of solid tumors remain a therapeutic challenge. After melanoma, breast cancer is the most common tumor to metastasize to the skin. The toll-like receptor 7 agonist imiquimod, a U.S. Food and Drug Administration–approved imidazoquinoline, is highly effective in inducing immune-mediated rejection of primary skin malignancies when topically applied. Here we show in a prospective trial of refractory breast cancer that topical imiquimod can also stimulate local antitumor immunity within treated metastases and induce their regression. As treatment is easy to apply, well-tolerated, and can promote a proimmunogenic tumor microenvironment in metastases, imiquimod can be easily combined with other treatment modalities.

Drug Administration in a topical 5% formulation for the treatment of external genital warts, superficial basal cell carcinoma, and actinic keratosis. Topically applied, imiquimod exerts profound immunomodulatory effects on the tumor microenvironment leading to immune-mediated clearance of primary skin and mucosal malignancies (7, 8).

Based on imiquimod's efficacy in primary skin tumors and encouraged by anecdotal reports of antitumor efficacy in skin metastases of melanoma and breast cancer (9, 10), we tested the hypothesis that treatment with topical imiquimod could induce the regression of breast cancer skin metastases. In a prospective phase II trial, topical imiquimod 5% was applied to all cutaneous metastases and local antitumor activity and toxicity were measured after an 8-week treatment course. Tumor punch biopsies were obtained before and after imiquimod treatment from each patient to study the immunologic changes in the tumor microenvironment.

Materials and Methods

Patient eligibility

Women ≥ 18 years of age with biopsy-proven breast cancer and measurable skin metastases (chest wall recurrence or skin metastases) not suitable for definitive surgical resection and/or radiotherapy, Eastern Cooperative Oncology Group performance status of 0 to 1, adequate bone marrow, and organ function were eligible. Concurrent systemic cancer therapy (hormones, biologics, or chemotherapy) was allowed to continue only if, on a stable regimen for ≥ 12 weeks, skin metastases did not respond. The trial required completion of prior radiotherapy and hyperthermia to the target area >4 and >10 weeks respectively, before the study entry. Systemic disease assessment by CT/PET-CT imaging pre- and posttreatment was not required by protocol and was left to the discretion of the treating physician. All patients provided a written informed consent for participation in this IRB-approved study (clinicaltrials.gov identifier NCT00899574).

Trial design

The primary objective of this trial was to determine the local antitumor effect of topical TLR7 agonist imiquimod 5% cream in breast cancer patients with skin metastases. Secondary objectives were to assess toxicity and to study the immunologic effects in the tumor microenvironment induced by imiquimod treatment. The trial was designed as an open label, single-arm study to test the null hypothesis that the local antitumor effect (CCR and PR) was $P \leq 0.05$ versus the alternative that $P \geq 0.20$. An optimal 2-stage Simon design was used, in which 10 patients were to be enrolled in stage 1, with an expansion to stage 2 with an additional 19 patients if there was at least 1 responder in stage 1. The overall α level for this design was 0.047 with power of 0.801. At study entry, patient demographic and tumor characteristics [pathology, grade of differentiation, hormone receptor, and human epidermal growth factor receptor (Her)-2 status], metastatic sites and treatment history were collected.

Treatment

Imiquimod 5% cream (Aldara™) was donated by Graceway Pharmaceuticals, LLC. The cream was self-applied by patients to all clinically apparent skin metastases for 5 d/wk for 8 weeks (1 cycle). Additional treatment cycles were left to the discretion of patient and treating physician. The cream was thinly spread onto the lesions, remained on the skin for approximately 8 hours overnight, and was washed off the following morning. One single use packet (containing 250 mg of the cream) was used to cover areas up to 100 cm²; another packet was used for each additional treatment area of 100 cm², up to a maximum of 6 packets per day. These dose determinations were based on extrapolation from clinical experience with dosing of up to 6 packets per application in patients with actinic keratoses (11, 12). Imiquimod application was recorded by means of patient diaries and compliance was encouraged and monitored by weekly phone calls of study personnel to patients.

Response evaluation

Tumor assessment was carried out by physical examination at baseline and after the 8-week treatment course; visible and/or palpable cutaneous metastases were outlined on transparent film and uploaded into the Image J computer program (version 1.42q, provided by the National Institutes of Health, USA) for digital calculation of the affected surface area (region of interest, ROI). Computer-aided image analysis of the ROI was compared before and after treatment to assess response. As chest wall/skin lesions can be multifocal, confluent, and highly irregular, response criteria for this study were chosen based on criteria established for chest wall tumors by the European Organisation for Research and Treatment of Cancer modified from assessment of Kaposi's sarcoma skin lesions (13). These response criteria are defined as follows: complete clinical response (CCR, absence of any detectable residual disease), partial response (PR, residual disease less than 50% of original tumor size), stable disease (SD, 50–99% of original tumor

size), no response (NR, 100–124% of original tumor size), and progressive disease (PD, 125% or greater of original tumor size or new skin lesions).

Tumor biopsies and immune analyses

Tumor biopsies (4-mm-diameter punch) were obtained at baseline and after imiquimod treatment (3–5 days after completing an 8-week treatment cycle) from each patient. Each biopsy specimen was bisected; one half was processed into paraffin-embedded tissue for subsequent immunohistochemical staining and the other half was cultured for analysis of tumor supernatant as well as for characterization of tumor infiltrating lymphocytes (TILs).

Immunohistochemistry. Immunohistochemistry (IHC) was carried out on formalin fixed, paraffin embedded tumor tissues. Tissue sections (thickness 4 μ m) were deparaffinized and rinsed in distilled water. Heat induced epitope retrieval was carried out in 10 mmol/L citrate buffer pH 6.0. CD3, CD4, and CD8 antibodies (Ventana Medical Systems) were ready to use and undiluted; Forkhead Box Protein P3 antibody (FoxP3, Ebiosciences) was diluted 1:100 and incubations were carried out at 37°C or overnight, respectively. Detection was carried out on a NEXes instrument (Ventana Medical Systems) using the manufacturer's reagent buffer and detection kits. Upon completion, slides were washed in distilled water, counterstained with hematoxylin, dehydrated, and mounted with permanent media. Appropriate positive and negative controls were included with the study sections. IHC-positive cells were counted manually in 5 representative high-power fields (HPF, 400 \times), to derive the average number per HPF, by a pathologist blinded to the treatment assignment.

Luminex. To assess the intratumoral immune milieu, cytokines were measured in the tumor supernatant by Luminex 200 (Luminex Corp.). Tumor samples were minced and placed in a 4 mL tube with 1 mL media (10% FBS/RPMI 1640; Life Technologies) at a constant tissue weight per milliliter. After incubation in a 5% CO₂ incubator for 24 hours, supernatant was collected by centrifugation (2,000 rpm, 10 minutes, 4°C), divided in several aliquots and stored in polypropylene tubes at –80°C until analysis. IFN- γ , IFN- α 2, IL-1b, regulated upon activation, normal T cell expressed and secreted (RANTES), IL-6, IL-10, and IL17 were measured by Luminex assay, carried out in duplicate with the appropriate panel of cytokines (Human Cytokine/Chemokine Panel, Premixed 14 Plex) following manufacturer's instructions.

Lymphocyte phenotyping. Breast cancer tissue from biopsies before and after imiquimod treatment was cultured in 1 mL RPMI supplemented with 10% FBS, gentamicin and IL-2 (10 ng/mL) in 24-well plates at 37°C in a 5% CO₂ incubator, IL-2 media was replenished every 2 to 3 days. For comparison, peripheral blood mononuclear cells (PBMC) were purified from the blood of the same patient in parallel, drawn on the same day as the biopsy and cultured in the same culture conditions except that they were plated in 96-well plates at 10⁵ cells/100 μ L/well. Once TIL cultures were

successfully established, cells were collected at various days of culture and subjected to immune phenotyping using multiparameter flow cytometry. Cells were surface stained with the following antibodies: CD3-PerCP-Cy5.5, CD4-Alexa700 or PE, CD8-Pacific blue, CD25-PE, CD45RO-APC (Biolegend), CCR7-FITC (R&D Systems), and CCR6-biotin with Streptavidin-APC (BD Pharmingen). For FoxP3, surface staining was followed by intracellular staining using the FoxP3 Staining buffer set (Ebiosciences) and FoxP3-Alexa488 antibody (Biolegend). For intracellular cytokine staining, cells were stimulated for 5 hours at 37°C with PMA 20 ng/mL and Ionomycin 500 ng/mL (Sigma-Aldrich) and Golgistop (BD Biosciences). Cells were then fixed and permeabilized using the same FoxP3 Staining buffer set (Ebioscience) and stained with IFN γ -PeCy7, and IL-4-APC (Ebiosciences). Stained samples were acquired on an LSRII flow cytometer (BD Pharmingen). Flow cytometry data were analyzed using FlowJo software (version 8.8.7; Tree-Star Inc.).

Statistical analysis

Characteristics of patients are summarized using descriptive statistics including median and ranges for continuous variables and frequencies for categorical variables. Response rates (CCR+PR) were estimated at the conclusion of the first stage of the trial along with exact 95% confidence intervals. Safety data were summarized by body system and type and most severe Common Terminology Criteria for Adverse Events (CTCAE version 3.0) grade of individual events at the patient level. Changes in tumor supernatant cytokine values from pre- to posttreatment were evaluated using Wilcoxon non-parametric signed rank tests (2-sided).

Results

Ten women enrolled and completed the first stage of this 2 stage study. The median age was 50 years. Demographic and tumor characteristics as well as treatment history are shown in Table 1. Seven women presented with a chest wall recurrence, and 3 women presented with skin involvement of a large primary breast cancer in the setting of systemic metastases. All women had failed prior treatment for metastatic/recurrent disease, ranging from 1 to 3 lines of hormonal therapy (average 2) and 1 to 5 lines of chemotherapy (average 2.5). Based on the skin area involved, 6 patients applied 1 packet per day, whereas 4 applied more than 1 packet per day. A second treatment cycle was administered in 2 patients.

Patient compliance, defined as the number of administered applications divided by the number of prescribed applications during the entire study period, was excellent with 4 patients not missing any doses, and 6 patients having a compliance score of 95% or greater (1–2 missed doses).

Safety

The treatment was well tolerated with transient mild to moderate local and systemic adverse events (AEs) consistent with the expected immunomodulatory effects of

Table 1. Patient demographics, tumor characteristics at baseline and treatment history ($n = 10$)

		Number of patients (%)
Ethnicity	Caucasian	6 (60%)
	Asian	2 (20%)
	Black	1 (10%)
	Other	1 (10%)
Age	Range	44–71 years
	Median	50 years
Menopausal status	Premenopausal	2 (20%)
	Postmenopausal	8 (80%)
Pathology	Invasive ductal	9 (90%)
	Invasive lobular	1 (10%)
HR status	Positive	8 (80%)
	Negative	2 (20%)
Her2 status at entry	Positive	6 (60%)
	Negative	4 (40%)
Grade	Poorly differentiated	8 (80%)
	Moderately differentiated	2 (20%)
Disease presentation	Chest wall recurrence	7 (70%)
	Skin involvement of locally advanced breast cancer with distant metastases	3 (30%)
Site of metastases	Chest wall/skin only	2 (20%)
	Also extracutaneous metastases:	
	– Bone/lymph nodes	5 (50%)
Prior treatments for recurrent or metastatic disease	– Lung/pleura/adrenal	3 (30%)
	Yes	10 (100%)
	<ul style="list-style-type: none"> • Chemotherapy \pm anti-Her2 ($n = 7$) • Bevacizumab ($n = 4$) • Hormonal therapy \pm anti-Her2 ($n = 8$) • Surgery ($n = 4$) • Radiotherapy ($n = 5$) • Hyperthermia ($n = 2$) • Investigational compounds ($n = 2$) 	
Concurrent therapy (without prior response)	None	3 (30%)
	Chemotherapy \pm anti-Her2	2 (20%)
	Hormonal \pm anti-Her2	5 (50%)

Abbreviations: HR, hormone receptor; Her2, human epidermal growth factor receptor 2.

imiquimod. There were no serious, life-threatening, or severe grade AEs and no patient required permanent treatment discontinuation because of AEs. Systemic AEs occurred in 4 of 10 patients (40%), with flu-like symptoms being the most frequent (Table 2). One patient who received 6 packets per day experienced fever, fatigue, and depression on treatment, similar to symptoms observed with systemic interferon α treatment (14). The increase of intratumoral as well as circulating IFN- α 2 concentrations (from 7 to 19 pg/mL in plasma) with imiquimod treatment in this patient suggests a systemic spillover effect of locally induced cytokines.

The most frequently observed AEs were local, at the application site, and were experienced by 7 of 10 patients (Table 2). Symptoms included itching, burning, and pain at the target site, whereas signs included erythema, desquamation, and infection. Topical antibiotics were administered for superficial infection at the treatment site, as indicated.

Patient discomfort because of local or systemic AEs, regardless of grade, was successfully managed with temporary dosing interruptions (1 patient for 3 weeks) and subsequent reduction of the application frequency from 5 \times to 3 \times per week (3 patients).

Table 2. Numbers of patients with one or more possibly, probably or definitely related adverse events (only highest grade per patient shown)

Adverse event	CTCAE v 3.0		
	Grade I	Grade II	Grade III/IV
Dermatologic (local at tumor site)			
Local pain	2	1	0
Inflammation/redness	2	1	0
Infection	1	0	0
Itching	3	0	0
Burning	1	0	0
Desquamation/ulceration with oozing	2	1	0
Summary of patients with 1 or more dermatologic adverse events	5	2	0
Systemic (constitutional, mood, gastrointestinal)			
Depressed mood	0	1	0
Fatigue	0	1	0
Myalgias	1	1	0
Arthralgias	1	0	0
Fever/chills	1	1	0
Lymphadenopathy	1	0	0
Nausea/vomiting	0	1	0
Dehydration	0	1	0
Summary of patients with 1 or more systemic adverse events	2	2	0
Summary of patients with 1 or more adverse event of any type	4	4	0

Tumor response

Local tumor response after an 8-week cycle of imiquimod treatment was observed in 2 patients (20%; exact 95% CI 3%–56%), both of whom achieved a clinical PR at the chest wall (Table 3). Five patients maintained SD, 1 had a NR, and 2 had PD (development of new cutaneous lesions outside of the treatment field during the study).

The decision to close the single-agent trial, even though the criterion for moving to the second stage was met with a response rate of 20% in stage 1, was based on the fact that a new combination trial of imiquimod and local radiotherapy was designed, reflecting promising preclinical findings of a combination of imiquimod and local radiotherapy (companion manuscript submitted). The decision to conclude the trial after stage 1 was supported by the NYUCI Data Safety Monitoring Committee because the achieved

response rate of 20% with its 95% CI was reassuring that imiquimod as single agent has efficacy.

Interestingly, 2 of the 10 patients treated in this study (both with local SD on study) experienced a complete clinical remission upon treatment with a subsequent systemic regimen (fulvestrant). In both women, the complete remission in the skin lesion was associated with a systemic complete response (pulmonary and osseous in 1 patient, mediastinal lymph node, and adrenal metastases in the second patient) and have been maintained for over 1 year (details are being reported separately).

Immune correlates

To monitor the immune response at the tumor site, we examined TILs in paraffin-embedded tissue sections (Fig. 1) and *in vitro* cultures as well as local cytokines in tumor

Table 3. Local antitumor response

Response	ROI ^{change} = (ROI ^{posttreatment} /ROI ^{pretreatment}) × 100%	Patients (%)
CCR	Absence of any detectable residual disease	None
PR	>0% to <50%	2 (20%)
SD	≥50% to <100%	5 (50%)
NR	≥100% to <125%	1 (10%)
PD	≥125% or new skin lesions	2 (20%)

NOTE: Percentage change in ROI after 8-week imiquimod treatment (*n* = 10).
Abbreviations: ROI, region of interest; CCR, complete clinical response; PR, partial response; SD, stable disease; NR, no response; PD, progressive disease.

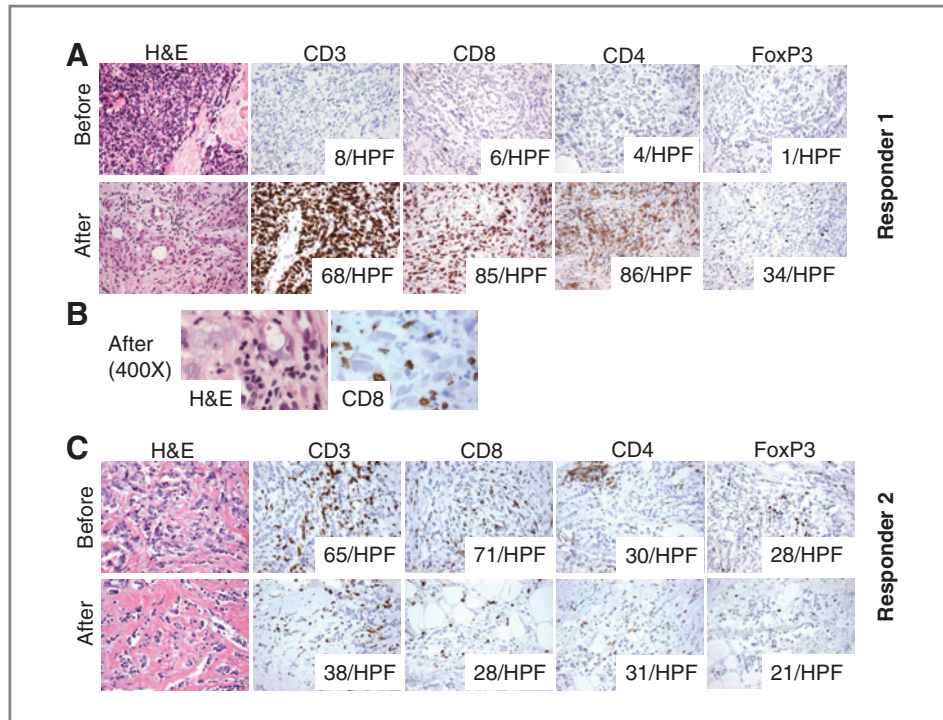


Figure 1. *In situ* immune changes with imiquimod treatment in the 2 responders. A (responder 1), *in situ* TILs analysis by IHC shows minimal T-cell infiltrate before treatment but a marked increase in CD8+ and CD4+ T cells infiltrating the tumor cell nests posttreatment and histologic evidence of tumor regression after 8 weeks of topical imiquimod treatment (H&E stain and IHC for CD3, CD4, CD8, and FoxP3, 200 \times). Numbers in the boxes indicate the number of cells positive for the indicated marker in 1 HPF (average of 5 HPF, 400 \times). B, high power microphotographs showing lymphocytes, many positive for CD8, in close contact with cancer cells in the posttreatment biopsy. C (responder 2), *in situ* TILs analysis by IHC shows a moderate T-cell infiltrate before imiquimod treatment. After an 8-week imiquimod treatment course, there is a reduction in CD8+ T cells and FoxP3+ T cells, whereas CD4+ T cells remain unchanged (H&E stain and IHC for CD3, CD4, CD8, and FoxP3, 200 \times). Numbers in the boxes indicate the number of cells positive for the indicated marker in 1 HPF (average of 5 HPF, 400 \times).

supernatants (Fig. 2). Viable tumor punch biopsies were successfully obtained from all patients before and after treatment. The supernatant after 24 hours *ex vivo* culture was obtained from all samples, and TIL cultures were successfully grown from 7/20 punch biopsy specimens.

Histologic evaluation revealed tumor involvement of skin for all patients before and after imiquimod treatment, with diffuse infiltration extending from the superficial dermis to the subcutis, and variable density of tumor cells occupying from 10% to 80% of the tissue examined. No significant differences were observed in vascularity or degree of apoptotic changes when pretreatment biopsies were compared with posttreatment ones. Intratumoral T-cell infiltrates were present in all specimens at baseline, varying from a sparse infiltrate (<5 CD3+ cells per HPF) to strong infiltration (65 CD3+ cells per HPF). Although it was feasible to culture TILs from small tumor punch biopsy specimens, the rate of success in establishing *ex vivo* TIL cultures was related to lymphocyte density: 7 cultures were established from 14 tumors that had >12 CD3+ cells per HPF, although none could be grown from the 6 tumors with <12 CD3+ cells infiltrating the metastasis. TILs commonly displayed a CCR7 $^-$ /CD45RO $^+$ effector memory and CCR6 $^+$ phenotype compared with PBMC, as shown in an example (Fig. 3A).

Across all patients, quantitative assessment of TILs and pDCs by IHC in tumor sections failed to show consistent trends pre- to posttreatment. In addition, levels of IFN- γ , IFN- α 2, IL-1b, RANTES, IL-6, and IL-10, as measured in tumor supernatants after 24 hours *ex vivo* culture, did not show a significant change with imiquimod treatment ($P > 0.05$; Fig. 2A). Circulating IL-10 was only detectable in 4 of 10 patients (Fig. 2B).

The 2 clinical responders, however, showed *in situ* changes consistent with an immune-mediated response. In responder 1, the minimal pretreatment T-cell infiltrate changed to a brisk infiltrate posttreatment, composed of both CD4 and CD8 T cells (Fig. 1A). Importantly, there was histologic evidence of tumor regression with marked reduction in tumor cell density (from 60% to 15%) and CD8 T cells found in direct contact with tumor cells (Fig. 1B). Consistent with the induced TILs infiltrate and the histologic appearance of tumor rejection, TILs could be successfully cultured only posttreatment in this patient and were composed of Th1 and cytolytic T cells, of effector memory phenotype, capable of secreting IFN- γ (Fig. 3B). IFN- α 2 markedly increased in the tumor supernatants posttreatment, and IFN- γ became detectable, albeit at a low level (Fig. 2A).

In contrast, responder 2 displayed a substantial T-cell infiltrate pretreatment. TILs evaluated by IHC included

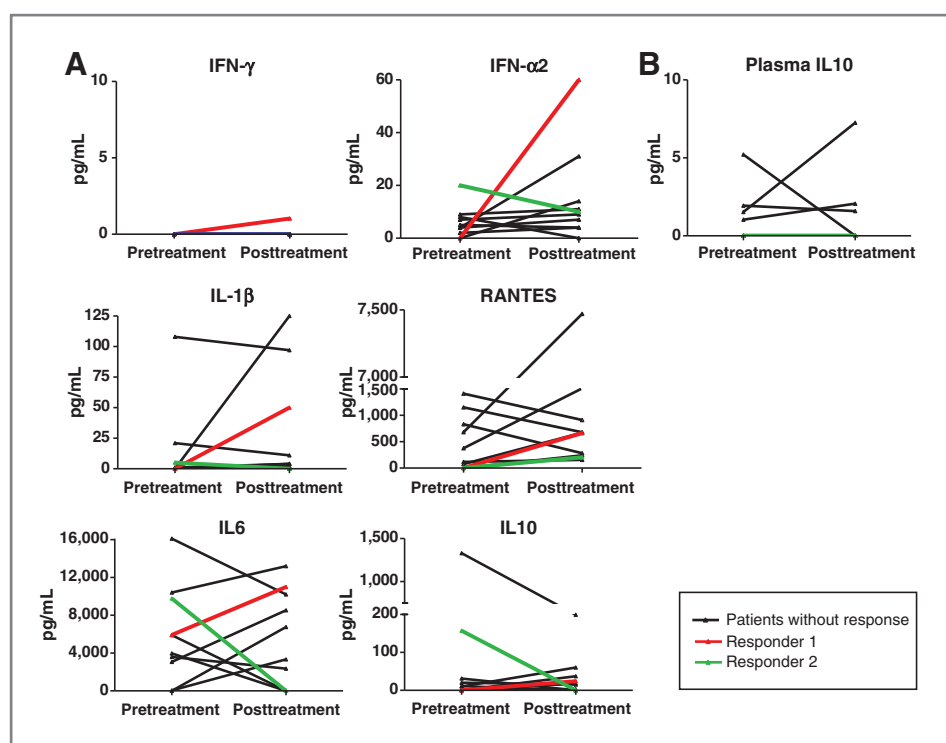


Figure 2. Changes in the intratumoral cytokine milieu after imiquimod treatment and plasma IL-10 levels in all patients. A, cytokine analysis of tumor supernatants before and after an 8-week imiquimod cycle is shown for all patients. Supernatants were obtained by 24-hour culture of the tumor samples in medium at a constant tissue mg/mL. Variability among patients is noticeable, as well as a marked increase in proinflammatory cytokines in responder 1 (red lines) and decrease of counter-regulatory cytokines in responder 2 (green lines). IFN- γ was only detectable in responder 1 after treatment; levels were below assay detection sensitivity for all other patients. IL-17 was not detectable in pre- and posttreatment supernatants of any patient. B, IL-10 levels in plasma are shown for all patients with detectable levels in only 4 of 10 patients.

CD8+ T cells, and an approximately equal number of CD4+ and FoxP3+ T cells (Fig. 1C). TILs were successfully cultured only pretreatment and included a large percentage of CD4+ T cells coexpressing CD25 and FoxP3, consistent with a regulatory T-cell phenotype as well as a subset of IL-4-producing CD4+ T cells (Fig. 3C). Posttreatment IHC sections showed a reduction in tumor cell density (from 40% to 20%) accompanied by an overall reduction in T cells. Interestingly, posttreatment tumor supernatants showed decreased concentrations of IL-6 and IL-10, suggesting the reversal of an immune-suppressive milieu (Fig. 2A). Overall, these data suggest that the response to imiquimod may be achieved by activation of Th1 and Tc1 T-cell responses, and/or by decrease in immunoregulatory cells/cytokines, depending on the preexisting tumor microenvironment.

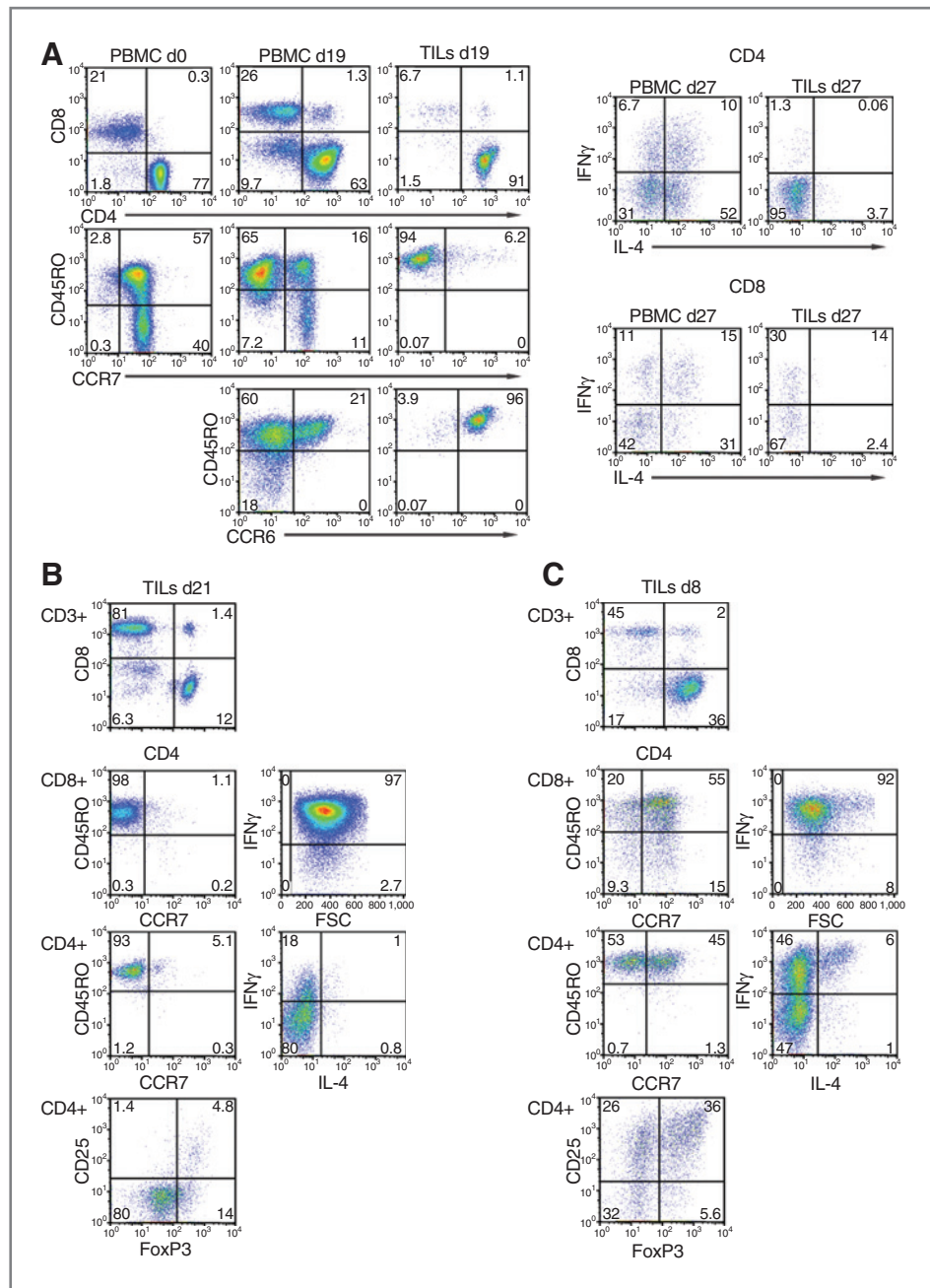
Discussion

This is the first report on the efficacy of topical imiquimod in breast cancer skin metastases in patients studied in a prospective trial. Despite the fact that the 10 women accrued were heavily pretreated and had refractory breast cancer skin metastases, the response rate was 20%, with a partial response achieved in 2 patients. Imiquimod 5% was applied 5 \times per week, the dosing frequency used for the treatment of superficial basal cell carcinoma (sBCC) and in a report of 2 breast cancer patients who experienced a CR at 6 months (9). Our trial showed feasibility and excellent compliance with self-administration of imiquimod. The safety profile of imiquimod was consistent with the previously published experience in the treatment of sBCC, main-

ly limited to transient application site reactions and flu-like symptoms.

Immunohistochemical and gene expression analyses suggest that imiquimod-induced regression in *primary* skin tumors (melanoma, BCC, squamous cell carcinoma) is characterized by significant upregulation of IFN- α and IFN- γ signaling, enhanced Th1 skewing and CD8 T cell homing to the tumor, reversal of T regulatory cell (Treg) function and modulation of the vasculature facilitating cellular infiltration, although the direct induction of apoptosis in superficial tumors as well as mDC- and pDC-mediated toxicity have also been described (7, 15–20). Until now, data from cutaneous *metastases* treated in prospective studies with topical imiquimod alone were lacking. In this study, preexisting lymphocytic infiltrates within the cutaneous metastases were highly variable and ranged from sparse to diffuse. Biopsies after an 8-week treatment course of imiquimod showed lack of consistent quantitative changes of the infiltrate. Furthermore, no increases in pDCs were seen posttreatment (not shown). These observations are in contrast to both our prior study showing that percutaneous stimulation of TLR7 *via* imiquimod in healthy skin (without immune cell infiltrates pretreatment) attracts pDCs and induces an inflammatory infiltrate mainly composed of T cells (21), and to the results of a recent study of preoperative imiquimod treatment of primary malignant melanoma showing an increase in T-cell infiltrates (15). Effects of imiquimod may depend on the preexisting tumor microenvironment, although the timing of biopsy in our trial compared with the other 2 studies (after 8 weeks vs. 1–2

Figure 3. Example of TILs profiles following *ex vivo* culture (from 3 patients). **A** (patient with SD, posttreatment), breast cancer biopsies and PBMCs (purified from the blood, drawn on the day of the tumor biopsy) were cultured in IL-2 containing media. Cells were collected at the indicated days of culture and subjected to immune phenotyping. FACS plots show the proportions of CD4+ and CD8+ T cells in PBMCs and TILs, the different subsets of CD4+ T cells based on the surface expression of CD45RO, CCR7, and CCR6 (left), and the intracellular cytokine profile of CD4+ and CD8+ T cells (right). **B** (responder 1, posttreatment), phenotype of TILs. Cells were collected at the indicated days of culture in IL-2 and subjected to immune phenotyping. FACS plots show the percentages of CD4+ and CD8+ T cells, their expression of CCR7, CD45RO, and FoxP3, as well as their intracellular cytokine profile. **C** (responder 2, pre-treatment), phenotype of TILs. Cells were collected at the indicated days of culture in IL-2 and subjected to immune phenotyping. FACS plots show the percentages of CD4+ and CD8+ T cells, their expression of CCR7, CD45RO, and FoxP3, as well as their intracellular cytokine profile.



weeks of imiquimod application) might also have contributed to the difference.

The biopsied metastases of the 2 responders displayed posttreatment changes highly suggestive of a local anti-tumor immune response induced by imiquimod, even though the tumors greatly differed in the extent of the preexisting lymphocytic infiltrate and local cytokine milieu as well as in their response to treatment with imiquimod. In responder 1 without a preexisting lymphocytic infiltrate, imiquimod treatment was associated with development of a Th1-polarized immune response. In responder 2 with a baseline lymphocytic infiltrate

including a substantial percentage of Treg and evidence of Th2 polarization, imiquimod response was associated with a reduction in immunosuppression. The extent of chest wall involvement and bone and lymph node metastases was similar in the 2 patients, only tumor histology was different: responder 1 had an infiltrating ductal carcinoma (IDC), whereas responder 2 had an infiltrating lobular carcinoma (ILC; Supplementary Table S1). This difference may have contributed to the disparate response, as we have previously observed differences between IDC and ILC in their interaction with the local immune system (22). Overall, the variability of TILs

Downloaded from <http://aacrjournals.org/clinccancerres/article-pdf/18/24/6749/20094326/748.pdf> by guest on 12 December 2024

infiltrates (Supplementary Fig. S1) and local cytokine milieu among all patients after and even before treatment points to the complexity of the interactions between tumor and host immune system in the setting of skin metastases. Genetic features of the patient may contribute to the differential response. Single-nucleotide polymorphisms have been described for TLR7 including alleles that are associated with treatment outcomes for viral infections (23). Similarly, a TLR4 loss-of-function allele has been shown to impact outcome of breast cancer patients posttreatment (24), suggesting that genetic variation might account for the diverse response to TLR agonists.

Limitations of this study are the small number of patients which precludes the identification of significant differences between responders and nonresponders, the single-arm design without a comparator group as well as the option for patients to continue on a systemic regimen concurrently (if no prior response in skin), which may have affected the immunological response.

As mentioned, 2 patients who had SD on imiquimod and were subsequently switched to fulvestrant, an estrogen receptor antagonist, had a complete clinical response to that regimen. Because CRs were rarely seen in a phase III trial of fulvestrant (only 4 of 362 women) (25), it is reasonable to hypothesize that immune effects of imiquimod may have contributed to their outcome. Unexpectedly higher response rates to chemotherapy have been reported in several solid tumors, when chemotherapy was preceded by cancer vaccination (26–30). Recent evidence that antitumor immunity contributes to the response to chemotherapy (24) raise the possibility that immunotherapy may condition the host immune system to achieve an antitumor effect synergistic with at least some cytotoxic treatments.

Activation of TLRs not only induces inflammatory cytokines but can also trigger negative regulatory circuits, for example by promoting the secretion of IL-10 (31, 32), as recently showed in the neu-transgenic mouse model of breast cancer in which IL-10 upregulation was shown to limit imiquimod's therapeutic effect (33). In our series, local levels of IL-10, as measured in tumor supernatants, did not show a significant change with imiquimod treatment, although a decrease was seen in 2 patients including responder 2 (Fig. 2A). Circulating IL-10 was detectable in 4 of 10 patients, but there was no trend to increase with imiquimod treatment (Fig. 2B).

In summary, we have shown that topical imiquimod can be a useful treatment modality for breast cancer metastatic to skin or chest wall. Importantly, data indicate that imiquimod is able to promote a proimmuno-

genic tumor microenvironment in metastatic breast cancer. To improve the efficacy of topical imiquimod, we have studied a combinatorial approach with local radiotherapy in the TSA murine model of breast cancer with cutaneous involvement. Radiotherapy is a frequently used treatment modality for chest wall recurrences and has been shown to synergize with immunotherapies (34, 35). In this preclinical model, the combination with topical imiquimod and local RT showed synergistic anti-tumor efficacy, with complete regressions, prolonged survival and improved systemic tumor control. A combination clinical trial is ongoing (clinicaltrials.gov identifier NCT01421017).

Disclosure of Potential Conflicts of Interest

T.-C. Meng is a consultant for, and was previously an employee of, Graceway Pharmaceuticals, the manufacturer of imiquimod 5% cream, as the Executive Director, Medical Affairs. No potential conflicts of interest were disclosed by the other authors.

Authors' Contributions

Conception and design: S. Adams, F. Martiniuk, T.-C. Meng, Y. Novik, J.D. Goldberg, S.C. Formenti, N. Bhardwaj, D. Unutmaz, S. Demaria

Development of methodology: S. Adams, L. Kozhaya, F. Martiniuk, L. Liebes, Y. Novik, A. Tiersten, J.D. Goldberg, S.C. Formenti

Acquisition of data (provided animals, acquired and managed patients, provided facilities, etc.): S. Adams, L. Kozhaya, F. Martiniuk, L. Chiriboga, N. Shuman, Y. Novik, A. Tiersten

Analysis and interpretation of data (e.g., statistical analysis, biostatistics, computational analysis): S. Adams, T. Hochman, N. Shuman, Y. Novik, J.D. Goldberg, S.C. Formenti, D. Unutmaz, S. Demaria

Writing, review, and/or revision of the manuscript: S. Adams, F. Martiniuk, T.-C. Meng, L. Chiriboga, L. Liebes, T. Hochman, N. Shuman, D. Axelrod, Y. Novik, A. Tiersten, J.D. Goldberg, S.C. Formenti, N. Bhardwaj, S. Demaria

Administrative, technical, or material support (i.e., reporting or organizing data, constructing databases): S. Adams, F. Martiniuk, S.C. Formenti

Study supervision: S. Adams, L. Liebes, N. Shuman, Y. Novik, S.C. Formenti

Provision of funding: S. Adams

Facilitation of clinical supplies: T.-C. Meng

Mentoring: N. Bhardwaj

Interpretation of histopathology and immunohistochemistry: S. Demaria

Acknowledgments

The authors thank all participating patients and research teams at the New York University and Bellevue Cancer Centers.

Grant Support

The work was supported by the National Cancer Institute [5P30 CA16087-31 (NYUCI Center Support Grant), K23CA125205P50 (S. Adams), NIH 5PCA016087-29 (Translational Pilot grant, S. Adams), and NIH R01 CA113851 (S. Demaria)] and in part by a grant from the CTSI grant-NCRR-NIH 1UL1RR029893 and The Chemotherapy Foundation (S. Demaria).

The costs of publication of this article were defrayed in part by the payment of page charges. This article must therefore be hereby marked *advertisement* in accordance with 18 U.S.C. Section 1734 solely to indicate this fact.

Received April 6, 2012; revised June 7, 2012; accepted June 20, 2012; published OnlineFirst July 5, 2012.

References

- Krathen RA, Orengo IF, Rosen T. Cutaneous metastasis: a meta-analysis of data. *South Med J* 2003;96:164–7.
- Lookingbill DP, Spangler N, Helm KF. Cutaneous metastases in patients with metastatic carcinoma: a retrospective study of 4020 patients. *J Am Acad Dermatol* 1993;29:228–36.
- Hemmi H, Kaisho T, Takeuchi O, Sato S, Sanjo H, Hoshino K, et al. Small antiviral compounds activate immune cells via the TLR7 MyD88-dependent signaling pathway. *Nat Immunol* 2002;3:196–200.
- Takeda K, Akira S. TLR signaling pathways. *Semin Immunol* 2004; 16:3–9.

5. Cheever MA. Twelve immunotherapy drugs that could cure cancers. *Immunol Rev* 2008;222:357–68.
6. Adams S. Toll-like receptor agonists in cancer therapy. *Immunotherapy* 2009;1:949–64.
7. Panelli MC, Stashower ME, Slade HB, Smith K, Norwood C, Abati A, et al. Sequential gene profiling of basal cell carcinomas treated with imiquimod in a placebo-controlled study defines the requirements for tissue rejection. *Genome Biol* 2007;8:R8.
8. Schon MP, Schon M. TLR7 and TLR8 as targets in cancer therapy. *Oncogene* 2008;27:190–9.
9. Hengge UR, Roth S, Tannapfel A. Topical imiquimod to treat recurrent breast cancer. *Breast Cancer Res Treat* 2005;94:93–4.
10. Heber G, Helbig D, Ponitzsch I, Wetzig T, Harth W, Simon JC. Complete remission of cutaneous and subcutaneous melanoma metastases of the scalp with imiquimod therapy. *J Dtsch Dermatol Ges* 2009;7:534–6.
11. Harrison LJ, Skinner SL, Marbury TC, Owens ML, Kurup S, McKane S, et al. Pharmacokinetics and safety of imiquimod 5% cream in the treatment of actinic keratoses of the face, scalp, or hands and arms. *Arch Dermatol Res* 2004;296:6–11.
12. Del Rosso JQ, Sofen H, Leshin B, Meng T, Kulp J, Levy S. Safety and efficacy of multiple 16-week courses of topical imiquimod for the treatment of large areas of skin involved with actinic keratoses. *J Clin Aesthet Dermatol* 2009;2:20–8.
13. Kouloulis VE, Dardoufas CE, Kouvaris JR, Gennatas CS, Polyzos AK, Gogas HJ, et al. Liposomal doxorubicin in conjunction with reirradiation and local hyperthermia treatment in recurrent breast cancer: a phase I/II trial. *Clin Cancer Res* 2002;8:374–82.
14. Kirkwood JM, Bender C, Agarwala S, Tarhini A, Shipe-Spotloe J, Smelko B, et al. Mechanisms and management of toxicities associated with high-dose interferon alfa-2b therapy. *J Clin Oncol* 2002;20:3703–18.
15. Narayan R, Nguyen H, Bentow JJ, Moy L, Lee DK, Greger S, et al. Immunomodulation by imiquimod in patients with high-risk primary melanoma. *J Invest Dermatol* 2012;132:163–9.
16. Wenzel J, Uerlich M, Haller O, Bieber T, Tueting T. Enhanced type I interferon signaling and recruitment of chemokine receptor CXCR3-expressing lymphocytes into the skin following treatment with the TLR7-agonist imiquimod. *J Cutan Pathol* 2005;32:257–62.
17. Clark RA, Huang SJ, Murphy GF, Mollet IG, Hijnen D, Muthukuru M, et al. Human squamous cell carcinomas evade the immune response by down-regulation of vascular E-selectin and recruitment of regulatory T cells. *J Exp Med* 2008;205:2221–34.
18. Schon M, Bong AB, Drewniok C, Herz J, Geilen CC, Reifenberger J, et al. Tumor-selective induction of apoptosis and the small-molecule immune response modifier imiquimod. *J Natl Cancer Inst* 2003;95:1138–49.
19. Drobits B, Holcman M, Amberg N, Swiecki M, Grundtner R, Hammer M, et al. Imiquimod clears tumors in mice independent of adaptive immunity by converting pDCs into tumor-killing effector cells. *J Clin Invest* 2012;122:575–85.
20. Stary G, Bangert C, Tauber M, Strohal R, Kopp T, Stingl G. Tumoricidal activity of TLR7/8-activated inflammatory dendritic cells. *J Exp Med* 2007;204:1441–51.
21. Adams S, O'Neill DW, Nonaka D, Hardin E, Chiriboga L, Siu K, et al. Immunization of malignant melanoma patients with full-length NY-ESO-1 protein using TLR7 agonist imiquimod as vaccine adjuvant. *J Immunol* 2008;181:776–84.
22. Gupta R, Babb JS, Singh B, Chiriboga L, Liebes L, Adams S, et al. The numbers of FoxP3+ lymphocytes in sentinel lymph nodes of breast cancer patients correlate with primary tumor size but not nodal status. *Cancer Invest* 2011;29:419–25.
23. Schott E, Witt H, Neumann K, Bergk A, Halangk J, Weich V, et al. Association of TLR7 single nucleotide polymorphisms with chronic HCV-infection and response to interferon- α -based therapy. *J Viral Hepat* 2008;15:71–8.
24. Apetoh L, Ghiringhelli F, Tesniere A, Obeid M, Ortiz C, Criollo A, et al. Toll-like receptor 4-dependent contribution of the immune system to anticancer chemotherapy and radiotherapy. *Nat Med* 2007;13:1050–9.
25. Di Leo A, Jerusalem G, Petruzella L, Torres R, Bondarenko IN, Khasanov R, et al. Results of the CONFIRM phase III trial comparing fulvestrant 250 mg with fulvestrant 500 mg in postmenopausal women with estrogen receptor-positive advanced breast cancer. *J Clin Oncol* 2010;28:4594–600.
26. Chiappori AA, Soliman H, Janssen WE, Antonia SJ, Gabrilovich DL. INGN-225: a dendritic cell-based p53 vaccine (Ad.p53-DC) in small cell lung cancer: observed association between immune response and enhanced chemotherapy effect. *Expert Opin Biol Ther* 2010;10:983–91.
27. Wheeler CJ, Das A, Liu G, Yu JS, Black KL. Clinical responsiveness of glioblastoma multiforme to chemotherapy after vaccination. *Clin Cancer Res* 2004;10:5316–26.
28. Gribben JG, Ryan DP, Boyajian R, Urban RG, Hedley ML, Beach K, et al. Unexpected association between induction of immunity to the universal tumor antigen CYP1B1 and response to next therapy. *Clin Cancer Res* 2005;11:4430–6.
29. Radfar S, Wang Y, Khong HT. Activated CD4+ T cells dramatically enhance chemotherapeutic tumor responses *in vitro* and *in vivo*. *J Immunol* 2009;183:6800–7.
30. Arlen PM, Gulley JL, Parker C, Skarupa L, Pazdur M, Panicali D, et al. A randomized phase II study of concurrent docetaxel plus vaccine versus vaccine alone in metastatic androgen-independent prostate cancer. *Clin Cancer Res* 2006;12:1260–9.
31. Saraiva M, O'Garra A. The regulation of IL-10 production by immune cells. *Nat Rev Immunol* 2010;10:170–81.
32. Bogunovic D, Manches O, Godefroy E, Yewdall A, Gallois A, Salazar AM, et al. TLR4 engagement during TLR3-induced proinflammatory signaling in dendritic cells promotes IL-10-mediated suppression of antitumor immunity. *Cancer Res* 2011;71:5467–76.
33. Lu H, Wagner WM, Gad E, Yang Y, Duan H, Amon LM, et al. Treatment failure of a TLR-7 agonist occurs due to self-regulation of acute inflammation and can be overcome by IL-10 blockade. *J Immunol* 2010;184:5360–7.
34. Demaria S, Kawashima N, Yang AM, Devitt ML, Babb JS, Allison JP, et al. Immune-mediated inhibition of metastases after treatment with local radiation and CTLA-4 blockade in a mouse model of breast cancer. *Clin Cancer Res* 2005;11:728–34.
35. Formenti SC, Demaria S. Systemic effects of local radiotherapy. *Lancet Oncol* 2009;10:718–26.