

Genomic Characterization of Vulvar (Pre)cancers Identifies Distinct Molecular Subtypes with Prognostic Significance



Linda S. Nooij^{1,2}, Natalja T. ter Haar¹, Dina Ruano¹, Natalia Rakislova³, Tom van Wezel¹, Vincent T.H.B.M. Smit¹, Baptist J.B.M.Z. Trimbos², Jaume Ordi³, Mariette I.E. van Poelgeest², and Tjalling Bosse¹

Abstract

Purpose: Vulvar cancer (VC) can be subclassified by human papillomavirus (HPV) status. HPV-negative VCs frequently harbor *TP53* mutations; however, in-depth analysis of other potential molecular genetic alterations is lacking. We comprehensively assessed somatic mutations in a large series of vulvar (pre)cancers.

Experimental Design: We performed targeted next-generation sequencing (17 genes), p53 immunohistochemistry and HPV testing on 36 VC and 82 precursors (sequencing cohort). Subsequently, the prognostic significance of the three subtypes identified in the sequencing cohort was assessed in a series of 236 VC patients (follow-up cohort).

Results: Frequent recurrent mutations were identified in HPV-negative vulvar (pre)cancers in *TP53* (42% and 68%), *NOTCH1* (28% and 41%), and *HRAS* (20% and 31%). Mutation frequency in HPV-positive vulvar (pre)cancers was significantly lower ($P = 0.001$). Furthermore, a substantial subset of the HPV-negative

precursors (35/60, 58.3%) and VC (10/29, 34.5%) were *TP53* wild-type (wt), suggesting a third, not-previously described, molecular subtype. Clinical outcomes in the three different subtypes (HPV⁺, HPV⁻/p53wt, HPV⁻/p53abn) were evaluated in a follow-up cohort consisting of 236 VC patients. Local recurrence rate was 5.3% for HPV⁺, 16.3% for HPV⁻/p53wt and 22.6% for HPV⁻/p53abn tumors ($P = 0.044$). HPV positivity remained an independent prognostic factor for favorable outcome in the multivariable analysis ($P = 0.020$).

Conclusions: HPV⁻ and HPV⁺ vulvar (pre)cancers display striking differences in somatic mutation patterns. HPV⁻/p53wt VC appear to be a distinct clinicopathologic subgroup with frequent *NOTCH1* mutations. HPV⁺ VC have a significantly lower local recurrence rate, independent of clinicopathological variables, opening opportunities for reducing overtreatment in VC. *Clin Cancer Res*; 23(22); 6781–9. ©2017 AACR.

Introduction

Traditionally, vulvar cancers (VC), of which the majority consists of squamous cell carcinomas, are subclassified depending on the presence or absence of human papillomavirus (HPV). HPV-positive (HPV⁺) VCs (about 30% of cases) originate in high-grade squamous intraepithelial lesions (HSIL), formerly referred to as vulvar intraepithelial neoplasia of usual type (uVIN; refs. 1, 2). In Europe, approximately 80% of VCs are HPV negative (HPV⁻), occur in older women, and are frequently associated with lichen sclerosus (LS; refs. 1, 3). This subtype has been shown to frequently harbor *TP53* mutations. Differentiated vulvar intraepithelial neoplasia (dVIN) has been

suggested to be the precancerous lesion preceding this subtype (3). dVIN has a high rate of malignant progression, which is estimated to be as high as 80% (1, 4). Other poorly characterized but putative HPV⁻ VC precursors are verruciform lichen simplex chronicus (VLSC) and vulvar acanthosis with altered differentiation (VAAD; ref. 5).

Few studies have investigated genetic alterations in VCs and its precursor lesions beyond HPV status (6–11). These studies have analyzed a limited selection of genes using Sanger sequencing or small panel hotspot approaches (8, 10, 11). Thus far, a more comprehensive assessment of molecular alterations in VC and its precursors is lacking (12). Recent large-scale next-generation sequencing (NGS) projects on other tumor types have delivered novel insights with clinical relevance (13–17). For head and neck cancer (HNC), a cancer with many clinicopathological similarities to VC, large-scale NGS studies (13, 14) have showed that HPV⁺ and HPV⁻ are molecularly distinct subtypes. Furthermore, these studies have advanced our understanding by identifying novel findings, such as a high frequency of *NOTCH1* mutations in HPV⁻ tumors (13, 14).

The aim of the current study was to characterize the molecular landscape of VCs and their precursor lesions. We have taken advantage of the resemblance between HNC and VC by designing a targeted NGS approach including genes in pathways that have proven to be relevant in HNC. Our NGS results

¹Department of Pathology, Leiden University Medical Center, The Netherlands.

²Department of Gynaecology, Leiden University Medical Center, The Netherlands. ³Department of Pathology, Barcelona Centre for International Health Research (CRESIB), Hospital Clinic, Universitat de Barcelona, Barcelona, Spain.

Note: Supplementary data for this article are available at Clinical Cancer Research Online (<http://clincancerres.aacrjournals.org/>).

Corresponding Author: Tjalling Bosse, Leiden University Medical Center, PO Box 9600, Postzone L1-Q, 2300 RC Leiden, The Netherlands. Phone: 31-715269111; Fax: 31-715266952; E-mail: t.bosse@lumc.nl

doi: 10.1158/1078-0432.CCR-17-1302

©2017 American Association for Cancer Research.

Translational Relevance

With this comprehensive assessment of molecular alterations in vulvar cancer and its precursor lesions, a third pathway in the carcinogenesis of vulvar cancer is suggested. Previous research has identified HPV-related and *TP53*-related vulvar cancers. This study confirms these findings, but also identified a possible third group of vulvar cancers that are *TP53* wild-type and not associated with HPV. A driver behind this third pathway may be dysregulation of *NOTCH1*, a transmembrane receptor involved in many different cell functions: differentiation, proliferation, and apoptosis. The identification of this third molecular subclass carries relevance for risk refinement and offers novel treatment avenues for vulvar cancer patients.

suggest that VCs can be classified into three categories: HPV⁺, HPV⁻ with a *TP53* mutation, and HPV⁻ with wild-type *TP53*. To investigate the clinical significance of this categorization, we also examined the clinical behavior of these groups in a large cohort of 236 patients with VC in whom clinical follow-up was available.

Materials and Methods

Sequencing cohort

Tissue samples. VC samples and precursor lesions (dVIN, LS, VAAD, and HSIL) were collected from the pathology department in the Leiden University Medical Center. Sample selection was based on original diagnosis described in the pathology report and on the size of the available samples. Non-squamous vulvar cancers were excluded. From 8 VC patients, adjacent precursor lesions were available and from 1 VC patient, sequential biopsies were included in the sample collection. In order to enrich for HPV-independent precursor lesions, an additional nationwide search for the HPV-independent precursor lesion dVIN was performed through the "nationwide network and registry of histo- and cytopathology in the Netherlands (PALGA)" (18). Sample collection was approved by the medical ethics committee of the LUMC (reference number B16.024). All hematoxylin-eosin (H&E)-stained slides were reevaluated by an expert gynecologic pathologist (T. Bosse) blinded to molecular or immunohistochemical results.

Development of the targeted vulvar NGS panel. A targeted NGS panel (the VC NGS panel) was designed using previously published data on somatic mutations in VC, its precursors (12), and in HNC (13, 14, 19–21). The panel consists of 176 amplicons covering 97% of the coding region of 17 genes with a role in critical cellular pathways, such as differentiation, proliferation, and apoptosis. The selected genes are *BRAF*, *CASP8*, *CDKN2A*, *EZH2*, *FAT1*, *HRAS*, *KMT2C*, *KMT2D*, *KRAS*, *NOTCH1*, *NOTCH2*, *PIK3CA*, *SYNE1*, *SYNE2*, *NSD1*, *TP53* (covering exons 2–12), and *TP63*. The primer sequences were synthesized by Integrated DNA Technology (IDT) and are available upon request.

DNA extraction. H&E slides were reviewed by an expert gynecologic pathologist (T. Bosse) who annotated the area, enriching for lesional cells. Unstained 10- μ m sections (4 when the tumor was

larger than 1 cm and 8 when the tumor was smaller than 1 cm) were cut from FFPE tissue blocks and dried at 37°C overnight. The sections were deparaffinized in xylol, rehydrated, and stained with hematoxylin, after which the tumor tissue was manually microdissected based upon the previous annotation on the H&E slide. When possible, associated normal tissue was microdissected separately. After proteinase K digestion overnight, DNA was extracted according to the manufacturer's protocol (Nucleospin DNA FFPE XS, Macherey-Nagel). The obtained DNA was quantified using the Qubit dsDNA broad range assay kit (Life Technologies). A minimum of 50 ng DNA was necessary in order to perform the targeted NGS.

Library preparation and sequencing. For library construction, 50 ng of DNA was amplified using the primer pool from the designed targeted NGS panel. The samples were barcoded with an adapter and a patient specific barcode in a second round of PCR. After each round of PCR, purification with AmpureXP beads took place. Final sample pooling was based upon the Cq-values acquired with quality PCR. After sample pooling, size selection was performed, and final concentration was measured with LabOnAChip. Next, emulsion PCR and loading of the chip on the Ion Chef System was done. Subsequently, targeted NGS was performed with the Ion Proton System according to the manufacturer's instructions.

Mutation calling. The generated reads were aligned to the human genome (hg19) using the Burrows-Wheeler aligner (BWA, version 0.7.5a; ref. 22). SNP and indel calling was carried out using VarScan software (version v2.3.6) with the following arguments: minimum read depth = 50, minimum number of reads with the alternative allele = 2, minimum base quality = 20, minimum variant allele frequency = 0.10 and $P < 0.01$.

Variants were functionally annotated using ANNOVAR (23). We then selected the ones more likely to have a deleterious effect, which was done by focusing on nonsense, frameshift variants and variants known to be of clinical significance or with a cadd_phred score higher 15. Variants with a population frequency higher than 1% in the 1000 Genomes project (24) were removed, because they are more likely to be germline. The called mutations were visually inspected using Integrative Genomics Viewer (IGV) software by LN and DR (<http://software.broadinstitute.org/software/igv/>).

Follow-up cohort

Follow-up data, HPV status, and p53 immunohistochemical data were available from a follow-up cohort consisting of 236 patients with VC. These patients were consecutively treated for primary VC in the LUMC (147 patients) and the Hospital Clinic de Barcelona (89 patients) between 1983 and 2012. A local recurrence was defined as a histologically confirmed recurrence within 2 years after primary treatment. In the LUMC cohort, only recurrences on the ipsilateral side of the vulva were considered a local recurrence.

HPV analysis. DNA extracted from two 10- μ m whole tissue sections was used for HPV analysis. To prevent contamination and to serve as a negative control, sections of a paraffin block without tissue were cut before each tumor sample. We performed the SPF-10 PCR from the INNO-LiPA HPV Genotyping Extra Amp kit (Innogenetics) according to the manufacture's protocol to

investigate whether or not HPV was present. All blank paraffin sections were negative for HPV in the final PCR analysis. HPV⁺ cases were further genotyped using a reverse hybridization line probe assay (LiPA; Innogenetics) through which 25 individual genotypes could be identified. Only samples infected with high-risk HPV were designated as HPV⁺.

P53 immunohistochemistry. P53 expression in the VC was evaluated by immunohistochemistry. Mutational data for comparison were limited to the sequencing cohort, and not available for the follow-up cohort. Sections of 4 μm thickness were cut from formalin-fixed paraffin-embedded specimen blocks and dried overnight at 37°C. Tissue sections were stained as described previously (25) using a monoclonal mouse antibody to p53 (Thermo scientific; 1:2,000 dilution; clone DO-7). Two pathologists (V. Smit and T. Bosse) performed all the scoring and interpretations of the IHC stains. Consensus meetings were held for the samples that were interpreted differently. P53 staining on VC was scored as "wild-type" (p53wt) when nuclei of tumor cells stained weak to moderately, comparable with adjacent normal epithelium. Three patterns of staining were defined as "p53 abnormal (p53abn)": (i) strong overexpression of all tumor cells, (ii) overexpression in the invasive tumor front or the undifferentiated/non-keratinized basal and parabasal cells at the interface with stroma, regardless of the location of the nests within the tumor mass, and (iii) completely absent staining in the tumor cells, with positive internal control showing a wild-type pattern (26).

Statistical analysis. Statistical analysis was performed with SPSS version 20.0. We divided the patient groups into HPV⁺, HPV⁻ with a p53 wild-type staining pattern (HPV⁻/p53wt) and HPV⁻ with a p53-abnormal staining pattern (HPV⁻/p53abn). The χ^2 test was used to compare baseline characteristics between groups. Kaplan–Meier analysis was performed to estimate local recurrence risk and overall survival. Multivariable analysis was performed

with the Cox proportional hazard model and included age, tumor size, depth of invasion, and lymph node status.

Results

Sequencing cohort

Sample characteristics. One hundred sixty-six samples were collected for genetic characterization. It was possible to isolate at least 50 ng of DNA for evaluation with targeted NGS from 125 samples. After library preparation and sequencing, a total of 119 samples could be analyzed (Fig. 1). One sample was excluded from the final results due to repeating outlier results. Pathology review (HE only) showed high concordance with local pathology: in 108 of 118 (92%). Ten cases were discordant, of which 8 dVIN (reclassified to VAAD, 5 cases; or LS, 3 cases), one HSIL (reclassified to dVIN) and one LS (reclassified to VAAD). After revision, the cohort for sequencing included 118 samples: 40 dVIN, 7 VAAD, 16 LS, 19 HSIL, and 36 VC samples. The diagnosis after review was used for all further analyses.

Sequence coverage. For the 118 samples analyzed, the mean read length of each sequence was 162 bp, and the average sequence was 147.7 Mb per sample. There was an average of 5,177 reads per amplicon (range, 0–496,101). A total of 165 of 176 (93.8%) amplicons succeeded and 150 of 176 (85.2%) amplicons had an average of at least 50 reads. *CDKN2A* and *TP63* were removed from the final data analysis due to poor sequence coverage.

Mutational spectrum of precursor lesions and VC in relation to HPV status. The HPV status and somatic mutations found by NGS in relation to the histology are visually represented in a mutational heatmap in Fig. 2A (precursor lesions) and 2B (VC). Targeted NGS was performed and analyzed on 82 precursor lesions: 22 of 82 (27%) were HPV⁺ and 60 of 82 (73%) were HPV⁻. Somatic mutations were significantly less frequent in HPV⁺ (7/22, 31.8%)

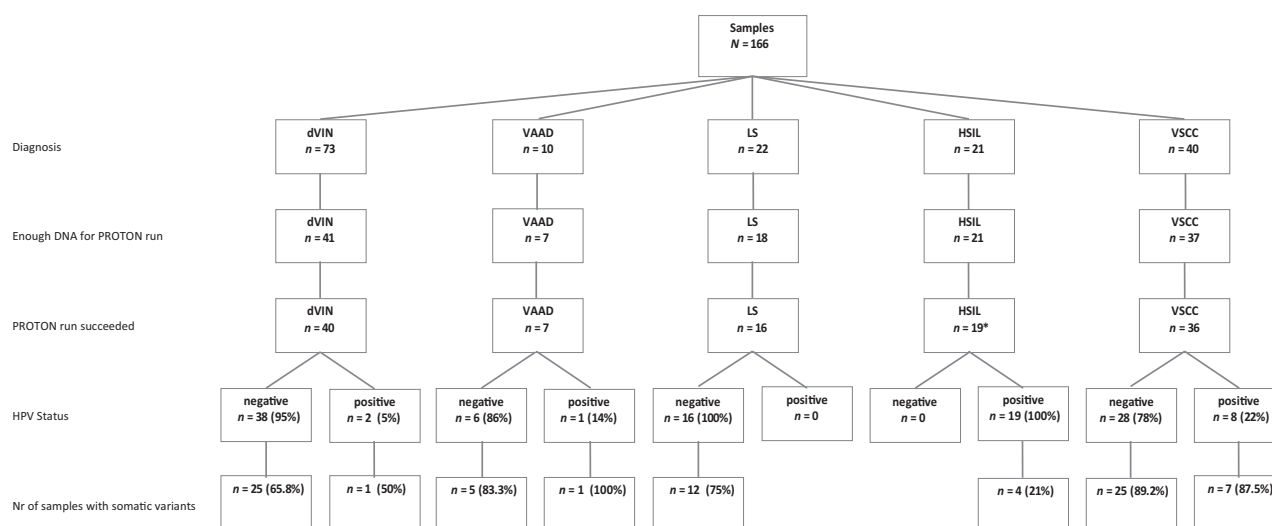


Figure 1.

Flowchart sequencing cohort. dVIN, differentiated vulvar intraepithelial neoplasia; VAAD, vulvar acanthosis with altered differentiation; LS, lichen sclerosis; HSIL, high-grade squamous intraepithelial lesion; VSCC, vulvar squamous cell carcinoma; HPV, human papilloma virus; *, one sample was excluded from the final analysis due to outlying results.

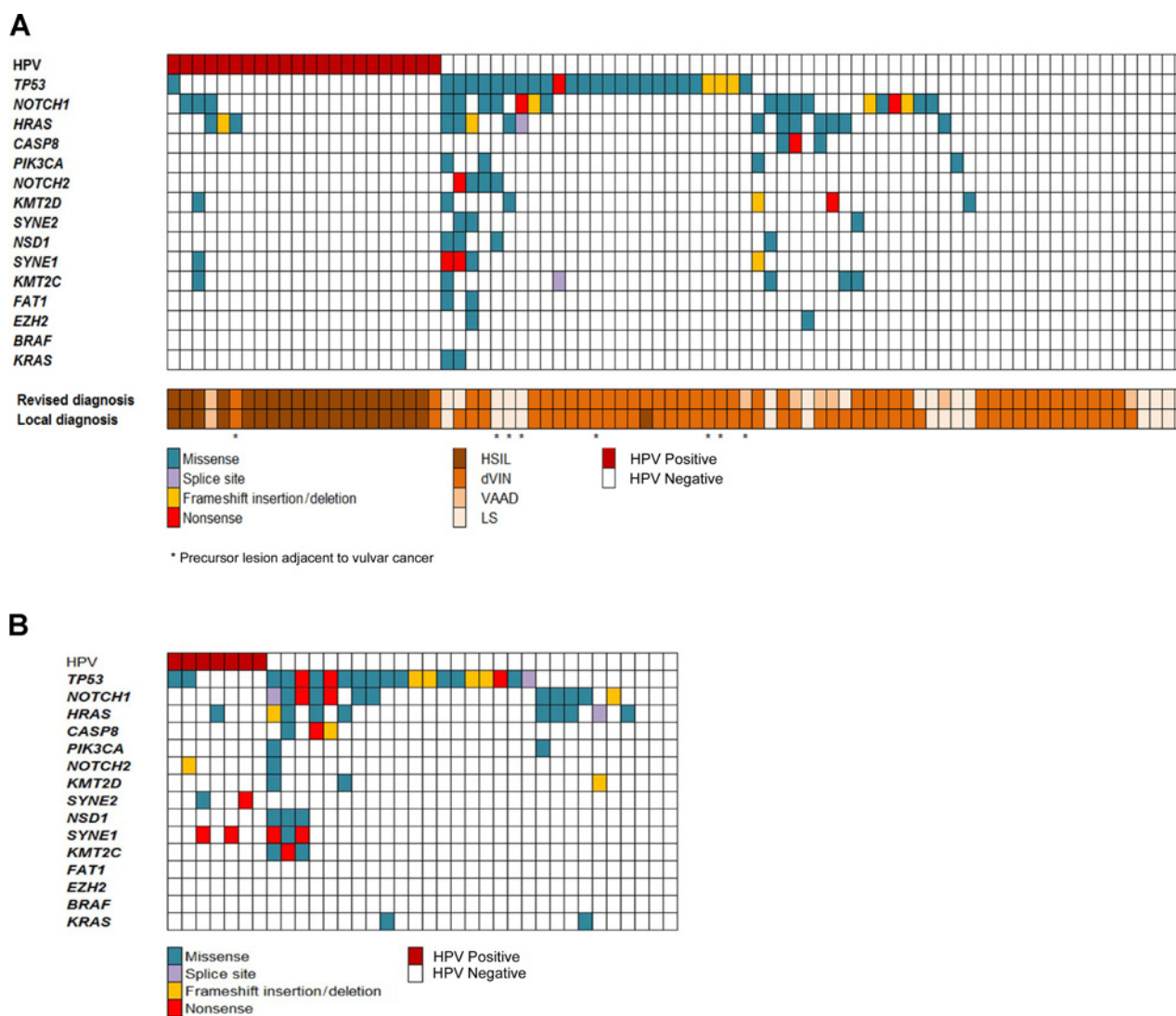


Figure 2. **A**, Mutational spectrum of precursor lesions. HPV, human papillomavirus; HSIL, high-grade squamous intraepithelial lesion; dVIN, differentiated vulvar intraepithelial neoplasia; LS, lichen sclerosus. *, Precursor lesion adjacent to VC. **B**, Mutational spectrum of vulvar cancers.

than HPV⁻ precursor lesions (43/60, 71.7%, $P = 0.001$; Fig. 2A, Table 1 and Supplementary Table S1). The most commonly mutated gene is *TP53* (26/82, 32% all sequenced precursor lesions; 1/22, 5% HPV⁺ and 25/60, 42% HPV⁻), followed by *NOTCH1* (20/82, 24% all sequenced precursor lesions; 3/22, 14% HPV⁺ and 17/60, 28% HPV⁻) and *HRAS* (15/82, 18% all sequenced precursor lesions; 3/22, 14% HPV⁺ and 12/60, 20% HPV⁻). In the HPV⁻ precursor lesions, 35 of 60 (58%) were *TP53* wild-type. A somatic mutation in *NOTCH1* was found in 10 of 35 (29%) and in *HRAS* in 7 of 35 (20%) of these HPV⁻, *TP53* wild-type precursor lesions. Most HPV⁺ cases were histologically classified as HSIL (19/22, 86%). Two of the HPV⁺ cases were diagnosed as dVIN. These cases retrospectively probably represent HSILs with superimposed inflammatory changes, mimicking dVIN. One HPV⁺ case was diagnosed as VAAD (2/40, 5% and 1/7, 14%, respectively). None of the LS cases included in this study was HPV⁺. Somatic mutations were significantly more common

in the dVIN (65%), VAAD (86%), and LS (75%) samples, compared with HSIL (25%). Mutations in *TP53* were found in 19 of 40 (47.5%) dVIN, 1 of 7 (14.3%) VAAD, 5 of 16 LS (31.3%), and 2 of 19 HSIL (10.5%). Mutations in *NOTCH1* and *HRAS* were found in 8 of 40 (20%) and 4 of 40 (10%) dVIN, 2 of 7 (28.6%) and 5 of 7 (71.4%) VAAD, 8/16 (50%) and 5 of 16 (31.3%) LS and 2 of 19 (10.5%) and 1 of 19 (5.3%) HSIL samples, respectively. Finally, genes with lower mutational frequencies were *MLL2* (7/82, 8.5%), *MLL3* (5/82, 6.1%), *NSD1* (4/82, 4.9%), *NOTCH2* (4/82, 4.9%), and *SYNE1* (5/82, 6.1). Thirty-six VC samples were available for targeted NGS, 7 (19%) were HPV⁺ and 29 (81%) were HPV⁻. Somatic mutations were found in 32 of 36 (89%) of all VC samples (Fig. 2B; Table 1 and Supplementary Table S1). The frequency of somatic mutations was the same for HPV⁺ (6/7, 85.7%) as for HPV⁻ (26/29, 89.7%) VCs. Multiple somatic mutations were less frequent in HPV⁺ than HPV⁻ VCs (2/7, 28.5% HPV⁺ and 14/29, 48.2% HPV⁻). In the total cohort, most

Table 1. Number of samples with somatic mutations found with the vulvar targeted NGS panel

	TP53	BRAF	CASP8	EZH2	FAT1	HRAS	MLL2 (KMT2D)	MLL3 (KMT2C)	KRAS	NOTCH1	NOTCH2	NSD1	PIK3CA	SYNE1	SYNE2
dVIN (n = 40)	19 (47.5%)	0 (0%)	1 (2.5%)	1 (2.5%)	1 (2.5%)	4 (10%)	2 (5%)	1 (2.5%)	0 (0%)	8 (20%)	2 (5%)	0 (0%)	2 (5.0%)	2 (5%)	2 (5%)
VAAD (n = 7)	1 (14.3%)	0 (0%)	2 (28.6%)	0 (0%)	0 (0%)	5 (71.4%)	1 (14.3%)	0 (0%)	0 (0%)	2 (28.6%)	0 (0%)	0 (0%)	0 (0%)	0 (0%)	0 (0%)
LS (n = 16)	5 (31.3%)	0 (0%)	0 (0%)	1 (6.3%)	1 (6.3%)	5 (31.3%)	3 (18.8%)	3 (18.8%)	2 (12.5%)	8 (50%)	2 (12.5%)	4 (25%)	2 (12.5%)	2 (12.5%)	1 (6.3%)
HSIL (n = 19)	1 (5.3%)	0 (0%)	0 (0%)	0 (0%)	0 (0%)	1 (5.3%)	1 (5.3%)	1 (5.3%)	0 (0%)	2 (10.5%)	0 (0%)	0 (0%)	0 (0%)	1 (5.3%)	0 (0%)
VC (n = 36)	21 (58.3%)	0 (0%)	3 (8.3%)	0 (0%)	0 (0%)	10 (27.8%)	3 (8.3%)	4 (11.1%)	2 (5.6%)	12 (33.3%)	2 (5.6%)	3 (8.3%)	2 (5.6%)	5 (13.9%)	2 (5.6%)
HPV ⁻ (n = 29)	19 (65.5%)	0 (0%)	3 (10.3%)	0 (0%)	0 (0%)	9 (31.0%)	3 (10.3%)	4 (13.8%)	2 (6.9%)	12 (41.4%)	1 (3.4%)	3 (10.3%)	2 (6.9%)	3 (10.3%)	0 (0%)
HPV ⁺ (n = 7)	2 (28.6%)	0 (0%)	0 (0%)	0 (0%)	0 (0%)	1 (14.3%)	0 (0%)	0 (0%)	0 (0%)	0 (0%)	1 (14.3%)	0 (0%)	0 (0%)	2 (28.6%)	2 (28.6%)
P	0.001	NA	0.024	0.522	0.522	0.001	0.500	0.227	0.142	0.071	0.520	0.005	0.520	0.522	0.823

Abbreviations: dVIN, differentiated vulvar intraepithelial neoplasia; HPV, human papillomavirus; HSIL, high grade squamous intraepithelial lesion; LS, lichen sclerosus; NA, not available; VAAD, vulvar acanthosis with altered differentiation; VC, vulvar cancer.

mutations were found in *TP53* (21/36, 58.3%). To investigate the potential utility of p53 immunohistochemistry as a surrogate marker for the identification of *TP53* mutational status, we performed p53-IHC on this sequencing cohort (Supplementary Fig. S3). In 31 of 36 VC, the results were concordant, resulting in a kappa of 0.72 (substantial agreement).

Other frequently mutated genes were *NOTCH1* (12/36, 33.3%) and *HRAS* (10/33, 27.8%). Finally, genes with lower mutational frequencies were *CASP8* (3/36, 8.3%), *MLL2* (3/36, 8.3%), *MLL3* (4/36, 11.1%), *NOTCH2* (2/36, 5.6%), *SYNE1* (5/36, 13.9%), and *SYNE2* (2/36, 5.6%). From 8 VC patients included in our sequencing cohort, adjacent precursor lesions (5 directly adjacent, and 3 distant but in same specimen) could be analyzed. The results of these patients are shown in Supplementary Fig. S1. An identical *TP53* mutation was identified in 3 of 5 precursor lesions directly adjacent to the VC. Interestingly, the somatic mutations in the remaining paired cases were distinctly different from the VC, suggesting that precursor lesions in these cases, despite the close proximity to the VCs, are likely unrelated (Supplementary Fig. S1A).

From 1 patient, interval biopsies and material from a tumor positive lymph node were available. This patient had VC on the right labium in 2001, which was treated surgically (no material available). In 2010, she had a local excision of a lesion from the left side of the vulva that showed a dVIN with possible micro-invasion (sample 1; Supplementary Fig. S1B). In August 2011, she developed a dVIN lesion with possible microinvasion on the right side of the vulva, which was surgically removed (sample 2). In October 2012, the patient developed VC in the midline of the vulva (sample 3). She underwent local excision combined with a resection of an enlarged left inguinal lymph node (sample 4). The same *NOTCH1* mutation was found in samples 2 and 3. Samples 3 and 4 contained the same mutation in *TP53*. These cases illustrate how the mutational profile may change during tumor progression.

Follow-up cohort

Prognostic implication of VC subtypes. Because our NGS results appear to suggest three distinct genetic subtypes of VC: (i) HPV⁺ VC, (ii) HPV⁻/p53wt VC, and (iii) HPV⁻/p53abn VC, we sought to determine the clinical outcome of this subclassification. For this, we analyzed a second cohort of 236 VC patients for the presence of HPV and the expression of p53 by immunohistochemistry (follow-up cohort). Patient characteristics from the follow-up cohort are described in Table 2. HPV was positive in 38 of 236 (16.1%) patients and negative in 198 of 236 (83.9%) patients. In the HPV⁻ group 43 of 198 (21.7%) had a wild-type p53 expression pattern and 155 of 198 (78.2%) an abnormal p53 expression pattern. Two of the 38 patients with HPV⁺ tumors (5.3%) developed a local recurrence, whereas 7 of 43 (16.3%) of the patients with HPV⁻/p53wt tumors and 35/155 (22.6%) of the patients with HPV⁻/p53abn tumors developed a local recurrence (Fig. 3A, *P* = 0.044). The HPV⁺ patients were younger, had a lower FIGO stage, and less often had tumor positive lymph nodes. When comparing the HPV⁻/p53wt and HPV⁻/p53abn groups with each other no clinical or tumor characteristics remained significantly different. There was no difference in local recurrence rate between the HPV⁻/p53wt and HPV⁻/p53abn groups (*P* = 0.246). Five-year survival was 75% for the patients with HPV⁺ tumors, 67.2% for the patients with HPV⁻/p53wt tumors and 56.3%

Table 2. Patient characteristics (n = 236)

	HPV ⁺ (n = 38)	HPV ⁻ /p53wt (n = 43)	HPV ⁻ /p53abn (n = 155)	P
Age (mean in years)	62 (25-92)	68 (36-93)	74 (37-96)	<0.001
FIGO 2009				0.043
Stage I	27 (71.1%)	28 (65.1%)	76 (49%)	
Stage II	4 (10.5%)	1 (2.3%)	10 (6.5%)	
Stage III	6 (15.8%)	13 (30.2%)	67 (43.2%)	
Stage IV	1 (2.6%)	1 (2.3%)	2 (1.3%)	
Tumor size				0.083
≤40 mm	30 (78.9%)	33 (76.8%)	103 (66.5%)	
>40 mm	5 (13.2%)	9 (20.9%)	47 (30.3%)	
Missing	3 (7.9%)	1 (2.3%)	5 (3.2%)	
Depth of invasion				0.253
≤4 mm	17 (44.7%)	17 (39.5%)	49 (31.6%)	
>4 mm	21 (55.3%)	26 (60.5%)	106 (68.4%)	
Primary treatment vulva				<0.001
Radical local excision	19 (50%)	26 (60.5%)	42 (27.1%)	
Vulvectomy	19 (50%)	17 (39.5%)	113 (72.9%)	
Tumor-positive lymph nodes in the groin(s)	7 (18.4%)	15 (34.9%)	68 (45.6%)	0.012
Local recurrence	2 (5.3%)	7 (16.3%)	35 (22.6%)	0.044
Current patient status				0.043
Alive	26 (68.4%)	26 (60.5%)	84 (54.1%)	
Death	12 (21.6%)	17 (39.5%)	71 (45.9%)	
Median follow-up time (months)	57 (2-174)	54 (6-172)	50 (0-206)	0.707

Abbreviation: HPV, human papillomavirus.

for the patients with HPV⁻/P53abn tumors (Supplementary Fig. S2, *P* = 0.296). Disease-specific survival was better for patients with HPV⁺ tumors compared with patients with

HPV⁻ tumors (Fig. 3B, *P* = 0.049). HPV⁺ status remained an independent favorable prognostic factor in multivariable analysis (Table 3, *P* = 0.020).

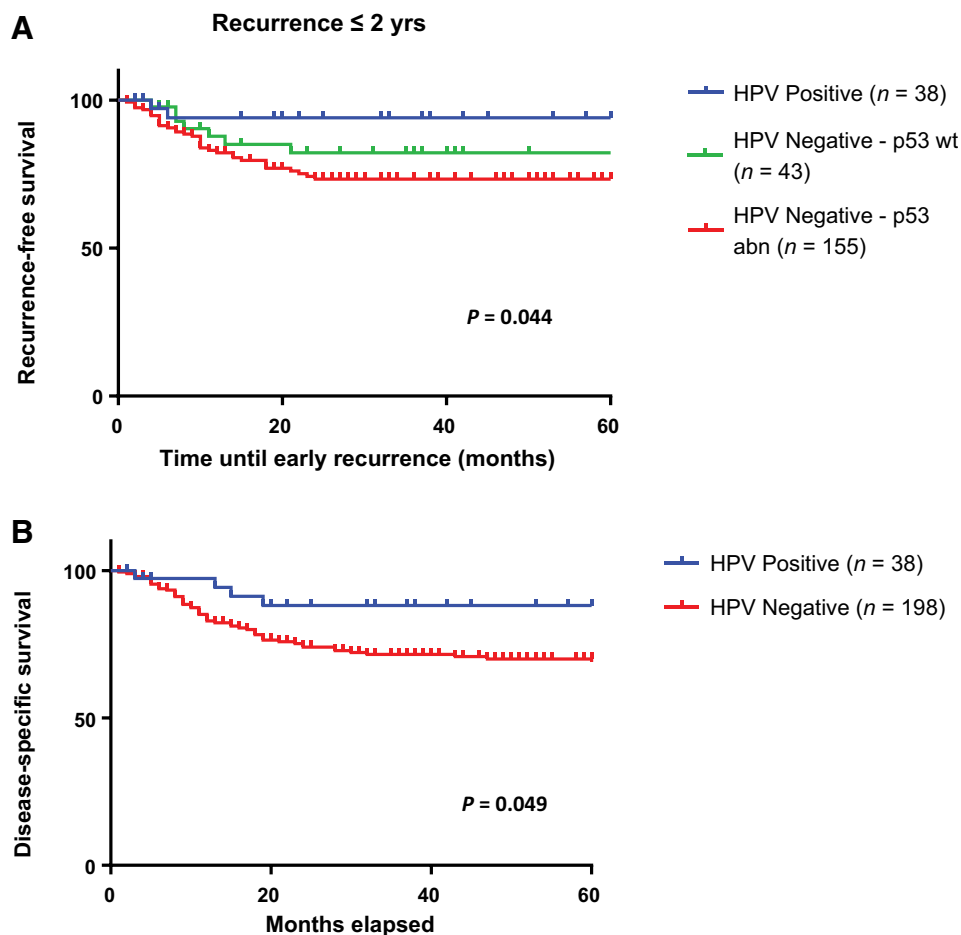


Figure 3. **A**, Kaplan-Meier curves for local recurrence rate. **B**, Kaplan-Meier curves for disease-specific survival based on HPV status. HPV, human papillomavirus.

Downloaded from <http://aacrjournals.org/clinicalcancerres/article-pdf/23/22/6781/2043063/6781.pdf> by guest on 21 May 2025

Table 3. Multivariable analysis

Tumor characteristics	Hazard ratio (95% CI)	P
Age (mean in years)	1.024 (1.004-1.045)	0.021
Tumor size		
>40 mm vs. ≤40 mm	0.534 (0.291-0.981)	0.043
Depth of invasion		
>4 mm vs. ≤4 mm	2.077 (1.174-3.675)	0.012
Lymph node status		
Tumor positive yes vs. no	1.119 (0.675-1.856)	0.663
HPV status		
Positive vs. negative	0.287 (0.101-0.819)	0.020

Abbreviation: HPV, human papillomavirus.

Discussion

This is the first study using targeted NGS to describe the mutational landscape of vulvar precursor lesions ($n = 82$) and VC ($n = 36$). With this approach, we were able to describe a mutational landscape of vulvar precursor lesions and VC. We found frequent somatic mutations in *TP53*, *NOTCH1*, and *HRAS* in HPV⁻ precursors and VCs. This finding suggests a critical role for these genes in the early development of VC. This is the first report to identify frequent somatic mutations in *NOTCH1* in VC and its precursors. Mutations in *NOTCH1* co-occurred with *TP53* mutations, but were also identified in VCs and precursors that did not carry *TP53* mutations. The frequency of *NOTCH1* and/or *HRAS* mutations was the highest in the HPV⁻ VCs without a *TP53* mutation (7/10, 70%) compared with the HPV⁻ VCs with a *TP53* mutation (8/19, 42%) and HPV⁺ VCs (1/7, 14%). Similar differences in *TP53* mutational rate between HPV⁻ and HPV⁺ VCs were recently reported by Weberpals and colleagues (27). In our analysis of the precursor lesions, a strikingly similar pattern was observed, suggesting that *NOTCH1* and *HRAS* are likely drivers of vulvar carcinogenesis that can act independently of *TP53*. Therefore, these data support a third molecularly distinct subtype that is HPV independent and *TP53* wild-type. In a large follow-up cohort of 236 patients with VC we were able to identify these three subtypes using straightforward and clinically applicable methods. This approach resulted in significant differences in local recurrence rate in univariable ($P = 0.044$) and multivariable analysis ($P = 0.020$) for patients with HPV⁺ tumors compared with patients with HPV⁻ tumors.

The finding of somatic mutations in *NOTCH1* (32/118, 27.1%) in VC and precursor lesions is a novel finding of the current study. Interestingly, two recent studies that performed whole-exome and whole-genome sequencing on HNC also identified frequent *NOTCH1* mutations (13, 14). These studies focused on the genomic differences between HNCs with and without HPV, but did not stratify HPV⁻, *TP53* wild-type from HPV⁻, *TP53*-mutant HNCs. In light of our findings, we analyzed these publicly available HNC data for the relation between HPV, *TP53*, and *NOTCH1*. We found, similarly to our findings in VCs, that *NOTCH1* mutations in HNC are also predominantly found in HPV⁻, *TP53* wild-type tumors (12/36, 33.3%) compared with HPV⁻, *TP53*-mutant (37/185, 20%) or HPV⁺ (3/34, 8.8%, data not shown; ref. 13). All these data strongly suggest that aberrant Notch signaling is involved in the carcinogenesis of a subset of HPV⁻ squamous cell carcinomas from both vulvar and head and neck origin. Aberrant notch function has been found in many other tumor types (14, 28-31) and intriguingly is associated with both tumor

suppressor as well as an oncogenic function (29, 32). Previous studies found a clear association in HNCs between inactivating mutations in *NOTCH1* and carcinogenesis. This indicates that notch has a primary tumor suppressor function in this tumor type and likely also in VC (14, 21). In line with this, prediction models indicated that most *NOTCH1* mutations identified in our NGS cohort are predicted to be inactivating (data not shown). Furthermore, aberrant notch signaling is proposed to be an early event in mouse models of esophageal cancer (33). Interesting in this respect is our finding of several LS cases, carrying *NOTCH1* mutations. Although we did not have follow-up information on these cases, it is tempting to speculate *NOTCH1* mutations may predict for progression. Interesting studies on targeted therapies of notch in solid tumors have evolved in the last years; however, they have most often focused on inhibition of notch signaling. Early-stage clinical trials are investigating inhibition of notch through inhibition of g-secretase (the enzyme responsible for cleavage of notch receptors and downstream signaling) as a potential anticancer therapeutic strategy (34). It will be worth further investigating the exact role of *NOTCH1* in the carcinogenesis in VC, as it might be a novel opportunity for targeted therapy. Another frequently mutated gene worthy of further exploration in VC was *HRAS*. Previous work already identified somatic mutations in *HRAS* in HPV⁻ VCs and showed an association with a worse prognosis (6). *HRAS* is an oncogene involved in the RTK/RAS/PI(3)K pathway, and somatic mutations lead to cell proliferation (13, 14).

Previous studies have already noted upon the presence of HPV-negative VC that are wild-type for *TP53* (9, 10, 35-39). In the current study, an in-depth genomic analysis of these VCs further supports the concept of this third molecular group in VCs. The finding that this third group is also present in HNCs and in vulvar precursor lesions favors this proposed 3-tiered classification. Molecularly, this subgroup has the highest frequency of *NOTCH1* and *HRAS* mutations, but also other mutations in other genes were identified. Morphologically most of the HPV⁻, *TP53* wild-type precursors were diagnosed as dVIN and VAAD. A recent report, supportive of our findings, also identified HPV⁻ and *TP53* wild-type VCs and describe frequent activating *PIK3CA* mutations (73%) in this subset of cancers (40). We identified two *PIK3CA* mutations in our VCs (2/28, 7.1%). To further delineate the molecular characteristics of this HPV⁻, *TP53* wild-type subgroup of VCs more in-depth analysis, such as whole-exome sequencing, will be required. In the follow-up cohort, the HPV⁻/p53wt group appeared to have an intermediate risk of recurrence; however, this did not reach statistical significance when comparing this to the HPV⁻/p53abn group ($P = 0.264$, data not shown). A possible explanation is that we were underpowered to detect an effect. Therefore, future larger studies will be required to establish whether the HPV⁻/p53wt VCs are not only a separate molecular group, but also clinically distinct.

Previous studies on the influence of HPV on prognosis in patients with VC found contradictory results. Some found no difference in local recurrence rate and overall survival (41-43), whereas others were able to find a prognostic benefit for HPV in univariate analysis (44-46). HPV remained a favorable prognosticator in multivariable analysis in only two other studies (45, 46). Although our study does not fulfill all criteria for a biomarker study (REMARK criteria; ref. 47), it is the largest

series of VC patients to date and shows the prognostic benefit of HPV in multivariable analysis. This finding is supported by a recently published study by McAlpine and colleagues, who found a superior progression-free survival and disease-specific survival for patients with HPV⁺ VC in a cohort treated after 1995. Taken together the results of these studies, we can now put this discussion to rest and can conclude the HPV⁺ VC have a significant better clinical behavior. Next, we need to discuss whether these findings should have consequences for the treatment of patients with VC. Interestingly, McAlpine and colleagues noted that HPV status in a cohort treated before 1995 did not show a difference in outcome. This may suggest that the more conservative surgical approach that has been developed in the course of the years has led to worse outcomes for patients with HPV⁻ VC (48). Currently, all patients with VC, irrespective of HPV status, are treated similarly, with surgery being the first choice of treatment (49). The outcome of the present study raises the question whether HPV testing (or p16 IHC, as an excellent surrogate, ref. 48) should be performed on all VC biopsies to identify patients with HPV⁻ tumors with a high risk of recurrence. A possible clinical implication might be to perform a more radical surgical procedure when HPV is not detected, followed by a more stringent follow-up scheme due to the higher chance of developing a local recurrence. Furthermore, HPV status might also be utilized as a predictive marker for response to adjuvant treatment (48, 50). For HNC, where the favorable prognosis of HPV⁺ cancers also has been established (51, 52), prospective studies are ongoing to investigate whether adjuvant chemotherapy can be omitted in HPV⁺ tumors (53, 54).

Of course, this study also has its limitations; our targeted NGS design relies on the parallels between VC and HNC. This leads to a directed search for somatic mutations but of course limits the discovery of novel gene mutations. Additionally, we were dealing with small biopsies of vulvar precursor lesions, limiting the extent of the DNA analysis. Unfortunately, we had to remove *CDKN2A* from our panel due to poor sequencing coverage. We were therefore unable to report on the frequency of *CDKN2A* mutations. Finally, we were not able to associate our molecular findings of the precursor lesions with clinical follow-up. Future studies should be designed to determine the possible prognostic capacity of somatic mutations in the progression to VCs.

References

- van de Nieuwenhof HP, van der Avoort IA, de Hullu JA. Review of squamous premalignant vulvar lesions. *Crit Rev Oncol Hematol* 2008;68:131–56.
- Del Pino M, Rodriguez-Carunchio L, Ordi J. Pathways of vulvar intraepithelial neoplasia and squamous cell carcinoma. *Histopathology* 2013;62:161–75.
- van der Avoort IA, Shirango H, Hoevenaars BM, Grefte JM, de Hullu JA, de Wilde PC, et al. Vulvar squamous cell carcinoma is a multifactorial disease following two separate and independent pathways. *Int J Gynecol Pathol* 2006;25:22–9.
- McAlpine JN, Kim SY, Akbari A, Eshragh S, Reuschenbach M, von Knebel Doeberitz M, et al. HPV-independent Differentiated Vulvar Intraepithelial Neoplasia (dVIN) is associated with an aggressive clinical course. *Int J Gynecol Pathol* 2017.
- Nascimento AF, Granter SR, Cviko A, Yuan L, Hecht JL, Crum CP. Vulvar acanthosis with altered differentiation: a precursor to verrucous carcinoma? *Am J Surg Pathol* 2004;28:638–43.
- Trietsch MD, Spaans VM, ter Haar NT, Osse EM, Peters AA, Gaarenstroom KN, et al. *CDKN2A*(p16) and *HRAS* are frequently mutated in vulvar squamous cell carcinoma. *Gynecol Oncol* 2014;135:149–55.
- Rolfe KJ, MacLean AB, Crow JC, Benjamin E, Reid WM, Perrett CW. TP53 mutations in vulvar lichen sclerosus adjacent to squamous cell carcinoma of the vulva. *Br J Cancer* 2003;89:2249–53.
- Soufir N, Queille S, Liboutet M, Thibaudeau O, Bachelier F, Delestaing G, et al. Inactivation of the *CDKN2A* and the p53 tumour suppressor genes in external genital carcinomas and their precursors. *Br J Dermatol* 2007;156:448–53.
- Pinto AP, Miron A, Yassin Y, Monte N, Woo TY, Mehra KK, et al. Differentiated vulvar intraepithelial neoplasia contains Tp53 mutations and is genetically linked to vulvar squamous cell carcinoma. *Mod Pathol* 2010;23:404–12.
- Choschzick M, Hantaredja W, Tennstedt P, Gieseking F, Wolber L, Simon R. Role of TP53 mutations in vulvar carcinomas. *Int J Gynecol Pathol* 2011;30:497–504.

In conclusion, this report is the first to establish a genetic landscape of a large cohort of VCs and precursors using targeted NGS. We identified a distinct mutational profile in HPV⁺ VCs and gave a molecular description of a group of HPV-independent VCs without *TP53* mutations. This third molecular subtype of VC shows a high frequency of *NOTCH1* and *HRAS* mutations and appears to have its own precancerous lesions, morphologically in the spectrum of dVIN and VAAD. Using a large cohort of patients with VC with long-term follow-up, we were able to identify HPV as a significant favorable prognostic factor. P53 status seems to further refine local recurrence risk in the HPV-independent VCs. The recognition that VCs can be classified in at least three distinct molecular subgroups using clinically applicable markers represents a promise for risk stratification and opens opportunities for precision medicine for patients with VC.

Disclosure of Potential Conflicts of Interest

No potential conflicts of interest were disclosed.

Authors' Contributions

Conception and design: L.S. Nooij, V.T.H.B.M. Smit, M.I.E. van Poelgeest, T. Bosse

Development of methodology: L.S. Nooij, M.I.E. van Poelgeest, T. Bosse
Acquisition of data (provided animals, acquired and managed patients, provided facilities, etc.): L.S. Nooij, N.T. ter Haar, J. Ordi, T. Bosse
Analysis and interpretation of data (e.g., statistical analysis, biostatistics, computational analysis): L.S. Nooij, N.T. ter Haar, D. Ruano, N. Rakislova, V.T.H.B.M. Smit, J. Ordi, M.I.E. van Poelgeest, T. Bosse, T. van Wezel

Writing, review, and/or revision of the manuscript: L.S. Nooij, V.T.H.B.M. Smit, J. Ordi, M.I.E. van Poelgeest, T. Bosse

Administrative, technical, or material support (i.e., reporting or organizing data, constructing databases): L.S. Nooij, N.T. ter Haar, T. Bosse

Study supervision: V.T.H.B.M. Smit, J.B.M.Z. Trimbos, M.I.E. van Poelgeest, T. Bosse

The costs of publication of this article were defrayed in part by the payment of page charges. This article must therefore be hereby marked *advertisement* in accordance with 18 U.S.C. Section 1734 solely to indicate this fact.

Received May 7, 2017; revised July 18, 2017; accepted September 1, 2017; published OnlineFirst September 12, 2017.

11. Holway AH, Rieger-Christ KM, Miner WR, Cain JW, Dugan JM, Pezza JA, et al. Somatic mutation of PTEN in vulvar cancer. *Clin Cancer Res* 2000;6:3228–35.
12. Trietsch MD, Nooij LS, Gaarenstroom KN, van Poelgeest MI. Genetic and epigenetic changes in vulvar squamous cell carcinoma and its precursor lesions: a review of the current literature. *Gynecol Oncol* 2015;136:143–57.
13. Cancer Genome Atlas Research N. Comprehensive genomic characterization of head and neck squamous cell carcinomas. *Nature* 2015;517:576–82.
14. Stransky N, Egloff AM, Tward AD, Kostic AD, Cibulskis K, Sivachenko A, et al. The mutational landscape of head and neck squamous cell carcinoma. *Science* 2011;333:1157–60.
15. Cancer Genome Atlas Research N, Kandoth C, Schultz N, Cherniack AD, Akbani R, Liu Y. Integrated genomic characterization of endometrial carcinoma. *Nature* 2013;497:67–73.
16. McDaniel AS, Stall JN, Hovelson DH, Cani AK, Liu CJ, Tomlins SA, et al. Next-generation sequencing of tubal intraepithelial carcinomas. *JAMA Oncol* 2015;1:1128–32.
17. Dallol A, Buhmeida A, Al-Ahwal MS, Al-Maghrabi J, Bajouth O, Al-Khayyat S, et al. Clinical significance of frequent somatic mutations detected by high-throughput targeted sequencing in archived colorectal cancer samples. *J Transl Med* 2016;14:118.
18. Casparie M, Tiebosch AT, Burger G, Blauwgeers H, van de Pol A, van Krieken JH, et al. Pathology databanking and biobanking in The Netherlands, a central role for PALGA, the nationwide histopathology and cytopathology data network and archive. *Cell Oncol* 2007;29:19–24.
19. Gaykalova DA, Mambo E, Choudhary A, Houghton J, Buddavarapu K, Sanford T, et al. Novel insight into mutational landscape of head and neck squamous cell carcinoma. *PLoS One* 2014;9:e93102.
20. Pickering CR, Zhang J, Yoo SY, Bengtsson L, Moorthy S, Neskey DM, et al. Integrative genomic characterization of oral squamous cell carcinoma identifies frequent somatic drivers. *Cancer Discov* 2013;3:770–81.
21. Agrawal N, Frederick MJ, Pickering CR, Bettgowda C, Chang K, Li RJ, et al. Exome sequencing of head and neck squamous cell carcinoma reveals inactivating mutations in NOTCH1. *Science* 2011;333:1154–7.
22. Koboldt DC, Zhang Q, Larson DE, Shen D, McLellan MD, Lin L, et al. VarScan 2: somatic mutation and copy number alteration discovery in cancer by exome sequencing. *Genome Res* 2012;22:568–76.
23. Wang K, Li M, Hakonarson H. ANNOVAR: functional annotation of genetic variants from high-throughput sequencing data. *Nucleic Acids Res* 2010;38:e164.
24. Genomes Project C, Auton A, Brooks LD, Durbin RM, Garrison EP, Kang HM. A global reference for human genetic variation. *Nature* 2015;526:68–74.
25. Nooij LS, Dreef EJ, Smit VT, van Poelgeest MI, Bosse T. Stathmin is a highly sensitive and specific biomarker for vulvar high-grade squamous intraepithelial lesions. *J Clin Pathol* 2016;69:1070–5.
26. McCluggage WG, Soslow RA, Gilks CB. Patterns of p53 immunoreactivity in endometrial carcinomas: 'all or nothing' staining is of importance. *Histopathology* 2011;59:786–8.
27. Weberpals JL, Lo B, Duciaume MM, Spaans JN, Clancy AA, Dimitroulakos J, et al. Vulvar squamous cell carcinoma (VSCC) as two diseases: HPV status identifies distinct mutational profiles including oncogenic fibroblast growth factor receptor 3. *Clin Cancer Res* 2017;23:4501–10.
28. Maliekal TT, Bajaj J, Giri V, Subramanyam D, Krishna S. The role of Notch signaling in human cervical cancer: implications for solid tumors. *Oncogene* 2008;27:5110–4.
29. Rettig EM, Chung CH, Bishop JA, Howard JD, Sharma R, Li RJ, et al. Cleaved NOTCH1 expression pattern in head and neck squamous cell carcinoma is associated with NOTCH1 mutation, HPV status, and high-risk features. *Cancer Prev Res (Phila)* 2015;8:287–95.
30. Agrawal N, Jiao Y, Bettgowda C, Hutfless SM, Wang Y, David S, et al. Comparative genomic analysis of esophageal adenocarcinoma and squamous cell carcinoma. *Cancer Discov* 2012;2:899–905.
31. Sakamoto K, Fujii T, Kawachi H, Miki Y, Omura K, Morita K, et al. Reduction of NOTCH1 expression pertains to maturation abnormalities of keratinocytes in squamous neoplasms. *Lab Invest* 2012;92:688–702.
32. Yap LF, Lee D, Khairuddin A, Pairan MF, Puspita B, Siar CH, et al. The opposing roles of NOTCH signalling in head and neck cancer: a mini review. *Oral Dis* 2015;21:850–7.
33. Nowell CS, Radtke F. Notch as a tumour suppressor. *Nat Rev Cancer* 2017;17:145–59.
34. Weaver AN, Burch MB, Cooper TS, Della Manna DL, Wei S, Ojesina AI, et al. Notch signaling activation is associated with patient mortality and increased FGF1-mediated invasion in squamous cell carcinoma of the oral cavity. *Mol Cancer Res* 2016;14:883–91.
35. Lee YY, Wilczynski SP, Chumakov A, Chih D, Koeffler HP. Carcinoma of the vulva: HPV and p53 mutations. *Oncogene* 1994;9:1655–9.
36. Pilotti S, D'Amato L, Della TG, Donghi R, Longoni A, Giarola M, et al. Papillomavirus, p53 alteration, and primary carcinoma of the vulva. *Diagn Mol Pathol* 1995;4:239–48.
37. Kim YT, Thomas NF, Kessis TD, Wilkinson EJ, Hedrick L, Cho KR. p53 mutations and clonality in vulvar carcinomas and squamous hyperplasias: evidence suggesting that squamous hyperplasias do not serve as direct precursors of human papillomavirus-negative vulvar carcinomas. *Hum Pathol* 1996;27:389–95.
38. Flowers LC, Wistuba II, Scurry J, Muller CY, Ashfaq R, Miller DS, et al. Genetic changes during the multistage pathogenesis of human papillomavirus positive and negative vulvar carcinomas. *J Soc Gynecol Investig* 1999;6:213–21.
39. Kashofer K, Regauer S. Analysis of full coding sequence of the TP53 gene in invasive vulvar cancers: Implications for therapy. *Gynecol Oncol* 2017;146:314–8.
40. Watkins JC, Howitt BE, Horowitz NS, Ritterhouse LL, Dong F, MacConaill LE, et al. Differentiated exophytic vulvar intraepithelial lesions are genetically distinct from keratinizing squamous cell carcinomas and contain mutations in PIK3CA. *Mod Pathol* 2017;30:448–58.
41. Alonso I, Fuste V, Del PM, Castillo P, Torne A, Fuste P, et al. Does human papillomavirus infection imply a different prognosis in vulvar squamous cell carcinoma? *Gynecol Oncol* 2011;122:509–14.
42. Pinto AP, Schlecht NF, Pintos J, Kaiano J, Franco EL, Crum CP, et al. Prognostic significance of lymph node variables and human papillomavirus DNA in invasive vulvar carcinoma. *Gynecol Oncol* 2004;92:856–65.
43. van de Nieuwenhof HP, van Kempen LC, de Hullu JA, Bekkers RL, Bulten J, Melchers WJ, et al. The etiologic role of HPV in vulvar squamous cell carcinoma fine tuned. *Cancer Epidemiol Biomarkers Prev* 2009;18:2061–7.
44. Hay CM, Lachance JA, Lucas FL, Smith KA, Jones MA. Biomarkers p16, human papillomavirus and p53 predict recurrence and survival in early stage squamous cell carcinoma of the vulva. *J Low Genit Tract Dis* 2016;20:252–6.
45. Lindell G, Nasman A, Jonsson C, Ehrsson RJ, Jacobsson H, Danielsson KG, et al. Presence of human papillomavirus (HPV) in vulvar squamous cell carcinoma (VSCC) and sentinel node. *Gynecol Oncol* 2010;117:312–6.
46. Monk BJ, Burger RA, Lin F, Parham G, Vasilev SA, Wilczynski SP. Prognostic significance of human papillomavirus DNA in vulvar carcinoma. *Obstet-Gynecol* 1995;85(5 Pt 1):709–15.
47. Simon RM, Paik S, Hayes DF. Use of archived specimens in evaluation of prognostic and predictive biomarkers. *J Natl Cancer Inst* 2009;101:1446–52.
48. McAlpine JN, Leung S, Cheng A, Miller D, Talhouk A, Gilks CB, et al. HPV-independent vulvar squamous cell carcinoma has a worse prognosis than HPV-associated disease: a retrospective cohort study. *Histopathology* 2017;71:238–46.
49. Hacker NF, Eifel PJ, van der Velden V. Cancer of the vulva. *Int J Gynaecol Obstet* 2012;119 Suppl 2:S90–S6.
50. Lee LJ, Howitt B, Catalano P, Tanaka C, Murphy R, Cimbak N, et al. Prognostic importance of human papillomavirus (HPV) and p16 positivity in squamous cell carcinoma of the vulva treated with radiotherapy. *Gynecol Oncol* 2016;142:293–8.
51. Ragin CC, Taioli E. Survival of squamous cell carcinoma of the head and neck in relation to human papillomavirus infection: review and meta-analysis. *Int J Cancer* 2007;121:1813–20.
52. Fakhry C, Westra WH, Li S, Cmelak A, Ridge JA, Pinto H, et al. Improved survival of patients with human papillomavirus-positive head and neck squamous cell carcinoma in a prospective clinical trial. *J Natl Cancer Inst* 2008;100:261–9.
53. Su W, Liu J, Miles BA, Genden EM, Misiukiewicz KJ, Posner M, et al. Adjuvant radiation therapy alone for HPV related oropharyngeal cancers with high risk features. *PLoS One* 2016;11:e0168061.
54. Dietz A, Wichmann G, Wiegand S. Should We De-escalate the Treatment for HPV-Positive Tumors? *Recent Results Cancer Res* 2017;206:173–81.